

Attention for insertion of temporary cardiac pacemaker in liver transplant patients

Volkan Ince,¹ Hakan Tasolar,² Sezai Yilmaz¹

¹Department of General Surgery, Inonu University Liver Transplantation Institute, Malatya, Turkey

²Department of Cardiology, Inonu University Faculty of Medicine, Malatya, Turkey

To the Editor,

Cardiac pacing is a lifesaving procedure for severe arrhythmias. Here, we would like to draw attention to the insertion of cardiac pacing via superior vena cava for a liver transplant (LT) candidate.

A 59-year-old male patient was diagnosed with multifocal hepatocellular carcinoma (HCC) (four nodules, dominant tumor 7 cm diameter, AFP: 7.1 ng/ml, no macrovascular invasion, and no extrahepatic spread) with cirrhosis due to hepatitis B infection (CHILD class B, MELD score 11). He had no cardiovascular complaint or concomitant disease. Live donor liver transplantation (LDLT) planned and preoperative evaluation for cardiac and pulmonary disease were uneventful. His son was suitable to be a live donor. With the start of the operation, hemodynamic instability of the patient began. A consultant cardiologist was called to the operating room and the operation was canceled due to the requirement for further cardiac evaluation. Because the patient had symptomatic bradycardia unresponsive to medical treatment, he was then transferred to the coronary intensive care, and a temporary cardiac pacemaker was inserted through the right femoral vein in the coronary angiography laboratory. The patient was stable hemodynamically and 4 days later he was transferred to the operating room again for LDLT. This time he was stable. The VCI clamped on suprarenal and subdiaphragmatic level and total hepatectomy performed. After removal of the cirrhotic liver, oozing hemorrhage from the opening of hepatic veins started due to the suprarenal clamp not having been closed properly. A second clamp was inserted and the hemorrhage was controlled. When the cavotomy performed we realized the cardiac pacemaker catheter was in the VCI (Fig. 1). Fortunately, cardiac pacing worked

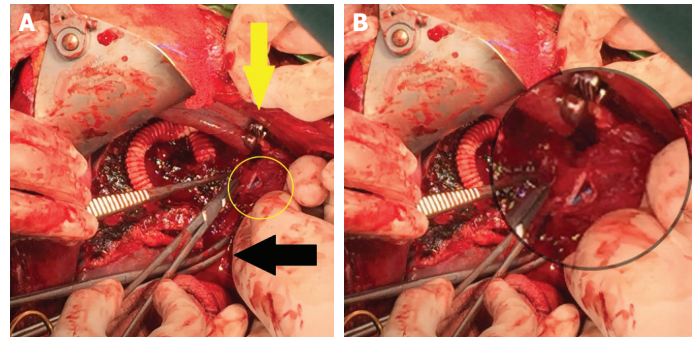


FIGURE 1. (A) Yellow circle shows the pacemaker, the blue color, catheter in the vena cava inferior. Yellow arrow shows the clamp on subdiaphragmatic level of VCI. Black arrow shows the double clamp on suprarenal level of VCI. (B) Zoomed view of the pacemaker catheter.

although double clamped and was not cut and the operation was completed uneventfully and there was no need for blood product transfusion. On postoperative day (POD) 1, the temporary cardiac pace removed and the recipient was discharged on POD 18, donor was discharged POD 7. The recipient is currently in the 31st postoperative month and lives without hepatitis B virus or HCC recurrence. During this period, his cardiac function decreased (ejection fraction from 60% to 40%).

The need for temporary cardiac pacing in LT patients was reported previously and it is an effective treatment for severe arrhythmias [1–3] but mostly performed in the post-transplant period. We draw attention to the risks of using the femoral vein for insertion of the pacemaker catheter in LT candidates during the perioperative period. Cardiologists should keep in mind not to use the femoral vein. In patients who are candidates for LT, a temporary cardiac pacemaker may have to be inserted into the superior vena cava via the jugular or subclavian vein. The use of vascular clamps can cut the catheter which is inserted through the femoral vein or make it dysfunctional and cause severe complications. This report is a good example of why there is a need for a multidisciplinary approach in LT procedure both for cardiologists and for surgeons. Surgeons should be as familiar as cardiologists with the cardiac procedure, and cardiologists should be as familiar as surgeons with LT procedure. Management of this kind of condition should be maintained in coordination with each discipline.

Cite this article as: Ince V, Tasolar H, Yilmaz S. Attention for insertion of temporary cardiac pacemaker in liver transplant patients. *North Clin Istanbul* 2021;8(5):543–544.

Conflict of Interest: No conflict of interest was declared by the authors.

Financial Disclosure: The authors declared that this study has received no financial support.

Authorship Contributions: Concept – VI; Design – VI; Supervision – SY; Data collection and/or processing – VI, HT; Analysis and/or interpretation – VI, HT; Literature review – VI; Writing – VI; Critical review – VI, HT, SY.

REFERENCES

1. Kobayashi T, Sato Y, Yamamoto S, Oya H, Takeishi T, Kokai H, et al. Temporary cardiac pacing for fatal arrhythmia in living-donor liver transplantation: three case reports. *Transplant Proc* 2008;40:2818–20.
2. Ramos J, Pai SL, Perry DK, Blackshear JL, Aniskevich S. Atrioventricular sequential pacing for hypertrophic cardiomyopathy during liver transplantation. *A A Case Rep* 2015;5:134–8.
3. Murata H, Inoue H, Sumikawa K. Anesthetic management of a patient undergoing liver transplantation who had previous coronary artery bypass grafting using an in situ right gastroepiploic artery. *J Anesth* 2010;24:264–7.

Correspondence: Volkan INCE, MD. Genel Cerrahi Anabilim Dalı, Inonu Universitesi, Karaciger Nakli Enstitüsü, Malatya, Turkey.

Tel: +90 422 3410660/6301 e-mail: volkanince@outlook.com

doi: 10.14744/nci.2020.59354

© Copyright 2021 by Istanbul Provincial Directorate of Health - Available online at www.northclinist.com



ICU admission and favipiravir

Rujittika Mungmunpantipantip,¹ **Viroj Wiwanitkit²**

¹Private Academic Consultant, Bangkok Thailand

²Honorary professor, Dr. DY Patil University Pune, India

To the Editor,

We would like to share ideas on “ICU admission rates in Istanbul following the addition of favipiravir to the national COVID-19 treatment protocol” [1]. Guner et al. [1] concluded that “The addition of favipiravir to the national

COVID-19 treatment protocol may explain this rapid decrease in the rate of ICU admissions and intubation”. The favipiravir is the new hope for COVID-19 outbreak containment. However, the insufficiency and unavailability are main problems in many developing countries.

The decreased ICU described by Guner et al. [2] might be an effect of favipiravir use. However, it might also be the effect by other factors such as other infectious disease control process, a good supportive treatment, and seasonal fluctuation of disease incidence. Finally, a recent report also showed that an additional use of hydroxychloroquine plus favipiravir can provide a better outcome than favipiravir alone.

Cite this article as: Mungmunpantipantip R, Wiwanitkit V. ICU admission and favipiravir. *North Clin Istanbul* 2021;8(5):544.

Conflict of Interest: No conflict of interest was declared by the authors.

Financial Disclosure: The authors declared that this study has received no financial support.

Authorship Contributions: Concept – RM, VW?; Design – RM, VW; Supervision – RM, VW; Funding – RM, VW; Materials – RM, VW; Data collection and/or processing – RM, VW; Analysis and/or interpretation – RM, VW; Literature review – RM, VW; Writing – RM, VW; Critical review – RM, VW.

REFERENCES

1. Guner AE, Surmeli A, Kural K, Yilmaz H, Kocayigit E, Sahin E, et al. ICU admission rates in Istanbul following the addition of favipiravir to the national COVID-19 treatment protocol. *North Clin Istanbul* 2021;8:119–23.
2. Guner R, Hasanoglu I, Kayaaslan B, Aypak A, Akinci E, Bodur H, et al. Comparing ICU admission rates of mild/moderate COVID-19 patients treated with hydroxychloroquine, favipiravir, and hydroxychloroquine plus favipiravir. *J Infect Public Health* 2021;14:365–70.

Received: April 27, 2021 **Accepted:** July 13, 2021

Online: October 22, 2021

Correspondence: Rujittika MUNGmunPUNTIPANTIP, MD. Private Academic Consultant, Bangkok, Thailand.

Tel: +90 66247656787 e-mail: rujittika@gmail.com

doi: 10.14744/nci.2021.60234

© Copyright 2021 by Istanbul Provincial Directorate of Health - Available online at www.northclinist.com

