

# Histopathologic Composition of Cerebral Thrombi of Acute Stroke Patients Is Correlated with Stroke Subtype and Thrombus Attenuation

Joris M. Niesten<sup>1\*</sup>, Irene C. van der Schaaf<sup>1</sup>, Lievay van Dam<sup>1</sup>, Aryan Vink<sup>2</sup>, Jan Albert Vos<sup>3</sup>, Wouter J. Schonewille<sup>4</sup>, Peter C. de Bruin<sup>5</sup>, Willem P. T. M. Mali<sup>1</sup>, Birgitta K. Velthuis<sup>1</sup>

**1** Department of Radiology, University Medical Center Utrecht, Utrecht, The Netherlands, **2** Department of Pathology, University Medical Center Utrecht, Utrecht, The Netherlands, **3** Department of Radiology, St. Antonius Hospital, Nieuwegein, The Netherlands, **4** Department of Neurology, St. Antonius Hospital, Nieuwegein, The Netherlands, **5** Department of Pathology, St. Antonius Hospital, Nieuwegein, The Netherlands

## Abstract

**Introduction:** We related composition of cerebral thrombi to stroke subtype and attenuation on non-contrast CT (NCCT) to gain more insight in etiopathogenesis and to validate thrombus attenuation as a new imaging biomarker for acute stroke.

**Methods:** We histopathologically investigated 22 thrombi retrieved after mechanical thrombectomy in acute stroke patients. First, thrombi were classified as fresh, lytic or organized. Second, percentages of red blood cells (RBCs), platelets and fibrin and number of red, white (respectively RBCs or platelets outnumbering other components with  $\geq 15\%$ ) or mixed thrombi were compared between large artery atherosclerosis (LAA), cardioembolism, dissection and unknown subtype. Third, correlation between attenuation and RBCs, platelets and fibrin was calculated using Pearson's correlation coefficients ( $r$ ).

**Results:** Thrombi were fresh in 73% ( $n=16$ ), lytic in 18% ( $n=4$ ) and organized in 9% ( $n=2$ ). The stroke cause was LAA in eight (36%), cardioembolism in six (27%), dissection in three (14%), and unknown in five (23%) patients. LAA thrombi showed the highest percentage RBCs (median 50 (range 35–90)), followed by dissection (35 (20–40),  $p=0.05$ ), cardioembolism (35 (5–45),  $p=0.013$ ) and unknown subtype (25 (2–40),  $p=0.006$ ). No differences in platelets ( $p=0.16$ ) and fibrin ( $p=0.52$ ) between subtypes were found. LAA thrombi were classified as red or mixed (both  $n=4$ ), cardioembolisms as mixed ( $n=5$ ) or white ( $n=1$ ) and dissection as mixed ( $n=3$ ). There was a moderate positive correlation between attenuation and RBCs ( $r=0.401$ ,  $p=0.049$ ), and weak negative correlations with platelets ( $r=-0.368$ ,  $p=0.09$ ) and fibrin ( $r=-0.073$ ,  $p=0.75$ ).

**Conclusions:** The majority of cerebral thrombi is fresh. There are no differences in age of thrombi between subtypes. LAA thrombi have highest percentages RBCs, cardioembolism and unknown subtype lowest. No relationship exists between subtype and platelets or fibrin percentages. We found a correlation between the RBC-component and thrombus attenuation, which improves validation of thrombus attenuation on NCCT as an imaging biomarker for stroke management.

**Citation:** Niesten JM, van der Schaaf IC, van Dam L, Vink A, Vos JA, et al. (2014) Histopathologic Composition of Cerebral Thrombi of Acute Stroke Patients Is Correlated with Stroke Subtype and Thrombus Attenuation. PLoS ONE 9(2): e88882. doi:10.1371/journal.pone.0088882

**Editor:** Jean-Claude Baron, INSERM U894, Centre de Psychiatrie et Neurosciences, Hopital Sainte-Anne and Université Paris 5, France

**Received:** November 13, 2013; **Accepted:** January 13, 2014; **Published:** February 11, 2014

**Copyright:** © 2014 Niesten et al. This is an open-access article distributed under the terms of the Creative Commons Attribution License, which permits unrestricted use, distribution, and reproduction in any medium, provided the original author and source are credited.

**Funding:** Grants were provided by Dutch Heart Foundation (grant 2008T034), NutsOhra Foundation (grant 0903-012). The funders had no role in study design, data collection and analysis, decision to publish, or preparation of the manuscript.

**Competing Interests:** The authors have declared that no competing interests exist.

\* E-mail: jmniensten@gmail.com

## Introduction

Thromboembolism is the cause of ischemic stroke in the majority of acute stroke patients [1]. These thrombi originate mainly from large artery atherosclerosis (LAA) and cardioembolisms, and more infrequently from dissection [2–4].

The use of mechanical thrombectomy devices allows retrieval of cerebral thrombi from the intracranial vessels and subsequent histopathologic analysis. The first histopathologic studies showed that the architecture of cerebral thrombi is variable with different main components such as fibrin, red blood cells (RBC) and platelets [5–7]. The composition of thrombi may influence the efficacy of thrombolysis with recombinant tissue plasminogen

activator (rtPA) since RBC-rich or red thrombi are described to be more vulnerable for current thrombolysis compared to platelet-rich or white thrombi [8–10].

Furthermore, the age of thrombi could also play a role in success rate of thrombolysis, which is only about 50% with current IV-rtPA therapy. Recanalisation depends on the time from stroke onset to intravenous (IV) rtPA-treatment, hence it may be more effective in fresh than old thrombi [11].

On non-contrast CT (NCCT) platelet-rich thrombi have lower attenuation than RBC-rich thrombi since the attenuation has a linear correlation with the concentration of hemoglobin [9,12–14]. Recent studies found that the attenuation is also related to stroke

subtype [15,16] and could be helpful in predicting the rate of recanalisation after rtPA [17,18].

Improved knowledge about thrombus age and composition and its relation with stroke subtypes and attenuation could help to gain more insight in the etiopathogenesis of stroke. The aims of this study were to relate the age and histopathologic composition of thrombi to the stroke subtype and to thrombus attenuation on NCCT.

## Methods

### Patient population

We histopathologically investigated thrombi retrieved after mechanical thrombectomy of acute stroke patients admitted to the University Medical Center Utrecht or the St. Antonius Hospital Nieuwegein, between December 2010 and April 2013. Inclusion criteria were: age  $\geq 18$  years, National Institutes of Health Stroke Scale (NIHSS)  $\geq 2$ , acute stroke patients with an intracranial thrombus on CT-Angiography (CTA) eligible for thrombectomy, retrieval of thrombus material available for histopathologic analysis. Exclusion criteria were the collection of thrombus material that was unsuitable for histopathologic analyses and a poor quality NCCT that was unsuitable for thrombus density measurements.

The following baseline data were collected: demographic features, cardiovascular risk factors (hypertension, diabetes mellitus, smoking), NIHSS on admission, location of the thrombus, and onset time to CT-imaging, to IV-rtPA treatment and thrombus retrieval.

LAA was defined as imaging findings of either significant ( $>50\%$ ) stenosis or occlusion of a major cervical (carotid or vertebral) artery or intracranial artery on CTA ipsilateral to the symptomatic hemisphere, presumed to be due to atherosclerosis according to the Trial of Org 10172 in Acute Stroke Treatment (TOAST) criteria [19] if other diagnostic studies had excluded potential sources of cardiac embolism. Cardioembolism was defined as at least one cardiac source for an embolus identified in the absence of significant ipsilateral stenosis ( $>50\%$ ) of ipsilateral large extracranial arteries or atherosclerosis. Criteria for diagnosing dissection as the cause of stroke were a narrowed eccentric lumen surrounded by crescent-shaped mural thickening or tapered occlusion with associated increase in external vessel diameter on CTA [20,21].

### Ethics statement

The medical ethics committee of the University Medical Center Utrecht approved the study. If patients had the capacity to consent, written informed consent was obtained from themselves. If this was not the case, written informed consent was obtained from their nearest relative(s).

### Treatment prior to thrombectomy

Based on clinical and imaging information IV-rtPA was administered to patients when considered eligible by a team of experienced neuroradiologists and neurologists. If IV-rtPA failed or could not be administered due to contra-indications, the administration of intra-arterial (IA) rtPA followed by thrombectomy or thrombectomy alone was done, in all cases under systemic heparin. The heparin was given IV at a dose of 2500 IU.

### Thrombectomy Procedure

Informed consent was obtained prior to the procedure. Mechanical thrombectomy was performed in accordance with local guidelines. All patients had heparin administered during the

percutaneous intervention. The occlusion was reached using a guiding catheter through the femoral artery. The thrombus was removed by a Merci retriever, a Trevo retriever or a Solitaire stent and thrombus material was collected in a formalin equipped bottle.

### Histopathologic Procedure

Specimens were embedded in paraffin and 4 consecutive 5- $\mu\text{m}$  thick slices were cut. All thrombi were stained with hematoxylin and eosin, Mallory's phosphotungstic acid-hematoxylin (identifying fibrin), glycophorin A (identifying RBCs) and CD31 (identifying platelets) immunostains.

Subsequently, thrombi were histopathologic analysed by an experienced vascular pathologist (A.V.) together with two other investigators (J.N. and L.v.D.) on all 4 slices. Histological analysis was conducted in a blinded fashion without any knowledge of patient and stroke characteristics. First, all thrombi were classified as fresh ( $<1$  day), lytic (1–5 days) or organized ( $>5$  days), based on previously published definitions of thrombus age [22]. Thrombi were classified according to the age of the largest part of the thrombus. Second, percentages of RBCs, platelets and fibrin were quantitatively determined in consensus. Subsequently, thrombi were classified as red if RBCs outnumbered platelets and fibrin by at least 15% and as white if platelets outnumbered RBCs and fibrin with at least 15% difference. If this was not the case, thrombi were classified as mixed. Furthermore, we also investigated the presence of other components (white blood cells, atheromatous material, calcification) in the thrombi.

### Scan protocol and attenuation measurements

All imaging studies were performed using 64- or 256-slice MDCT-scanner (Philips, Philips Healthcare, Best, the Netherlands). CT parameters of the NCCT were: 120 kVp, 300 mAs, and 3-mm reconstructed slice thickness. For the CTA 65–70 ml of contrast agent (300 mg Iopromide/mL) was injected into the antecubital vein (18-gauge needle) at a rate of 6 mL/s followed by a 40-mL saline flush at the same rate.

The attenuation of the thrombus was measured on 3-mm NCCT in Hounsfield Units (HU) by two independent observers, both blinded for any data except localization of the thrombus on CTA. Within the thrombus a standardised small round region of interest was drawn three separate times and mean HU-values were used for analysis. The same measurements were performed in the corresponding contralateral vessel and by calculating the relative HU (HU thrombus/HU contralateral) we corrected for hematocrit. If the thrombus was situated in the basilar artery, a more proximal non-thrombosed portion of the basilar artery was used for the control measurements. If the proximal end was not open, the supraclinoid ICA was used ( $n = 3$ ).

### Statistical Analyses

Baseline characteristics were summarised as means (with standard deviation (SD)), medians (with range) or frequency counts and proportions.

First, the percentages of RBCs, platelets and fibrin were compared between the subtypes of stroke by the Kruskal-Wallis test. Significant group differences were further analysed by the Mann-Whitney U test to determine individual differences.

Intraclass correlation coefficients (ICCs) were used to evaluate the interobserver variation in HU-measurements of the thrombus. We considered ICC values  $<0.20$  as poor, 0.21–0.40 as fair, 0.41–0.60 as moderate, 0.61–0.80 as good, and 0.81–1.00 as excellent. The correlation between attenuation and percentages of RBCs, platelets and fibrin was calculated using Pearson's correlation with

a coefficient ( $r$ ) of 0.90–1 as very strong; 0.70–0.89 as strong; 0.40–0.69 as moderate; 0.20–0.39 as weak and 0.01–0.19 as a negligible relationship. Statistical analysis was performed using SPSS (version 20.0, SPSS Inc., Chicago). Results were considered statistically significant if P-values were  $<0.05$ .

## Results

A total of 22 thrombi were retrieved from 22 patients with an average age of 60 years ( $\pm 13$ ) and 50% female (Table 1). No patients had to be excluded. The median time from onset to thrombus retrieval was 287 minutes (125–455). The mean NIHSS was 14, with a minimum of 5 and a maximum of 35. In 17 patients (77%) IV-rtPA was administered with a median time of 88 minutes from onset. Only 2 patients (9%) were on chronic anticoagulation medication and 3 patients (14%) received IA-rtPA prior to mechanical thrombectomy. The cause of stroke was classified as LAA in eight (36%), cardioembolism in six (27%), dissection in three (14%), and as unknown in five (23%) patients.

Thrombi were fresh in 73% ( $n = 16$ ), as lytic in 18% ( $n = 4$ ) and as organized in 9% ( $n = 2$ ). No significant differences were found in the age of thrombi between the different subtypes ( $p = 0.54$ ). All lytic and organized thrombi also revealed a component of the thrombus that was fresh. All thrombi that were fresh did not have any organized parts and only a very few fresh thrombi showed minimal lytic parts.

The median (range) percentages of components across all thrombi were 40% (2–90%) RBCs, 40% (5–80%) platelets, and 20% (5–65%) fibrin (Figure 1).

**Table 1. Patient characteristics.**

|   |                                 |
|---|---------------------------------|
| <b>Age in years, mean (<math>\pm</math>SD)</b>            | <b>60 (<math>\pm 13</math>)</b> |
| <b>Sex (female), n (%)</b>                                | <b>11 (50)</b>                  |
| <b>Subtype, n (%)</b>                                     |                                 |
| Large artery atherosclerosis                              | 8 (36)                          |
| Cardioembolism  | 6 (27)                          |
| Dissection  | 3 (14)                          |
| Unknown   | 5 (23)                          |
| <b>Cardiovascular risk factors, n (%)</b>                 |                                 |
| Current smoking   | 10 (45)                         |
| Hypertension  | 9 (41)                          |
| Diabetes Mellitus   | 1 (5)                           |
| Chronic anti-coagulation use, n (%)                       | 2, (9)                          |
| <b>Baseline NIHSS, median (range)</b>                     | <b>14 (5–35)</b>                |
| <b>Intravenous thrombolysis (rtPA), n (%)</b>             | <b>17 (77)</b>                  |
| <b>Intra-arterial thrombolysis (rtPA), n (%)</b>          | <b>3 (14)</b>                   |
| <b>Location thrombus, n (%)</b>                           |                                 |
| Middle Cerebral Artery                                    | 14 (64)                         |
| Basilar Artery  | 7 (32)                          |
| Internal Carotid Artery                                   | 1 (5)                           |
| <b>Onset time to CT in minutes, median (range)</b>        | <b>107 (20–386)</b>             |
| <b>Onset time to retrieval in minutes, median (range)</b> | <b>287 (125–455)</b>            |
| <b>Onset time to IV-rtPA in minutes, median (range)*</b>  | <b>88 (35–290)</b>              |

\* based on 17 patients received IV-rtPA  
SD: standard deviation, NIHSS: National Institutes of Health Stroke Scale, rtPA: recombinant tissue plasminogen activator, CT: Computed Tomography.  
doi:10.1371/journal.pone.0088882.t001

The median percentages of RBCs differed significantly between the different stroke subtypes as a group ( $p = 0.010$ ) while there were no significant differences in the median percentages of platelets ( $p = 0.16$ ) and fibrin ( $p = 0.52$ ) between the different subtypes (table 2 and figure 2). Comparing the individual stroke subtypes; thrombi originating from LAA showed the highest percentage of RBCs (median 50% (35–90%)), which was not significantly different from the dissection subtype (median 35% (20–40%),  $p = 0.05$ ) but was significantly higher than thrombi from cardioembolisms (median 35% (5–45%),  $p = 0.013$ ) and unknown subtype (median 25% (2–40%),  $p = 0.006$ ). The median percentages of RBCs in thrombi from dissection and cardioembolisms ( $p = 0.82$ ), dissection and unknown subtype ( $p = 0.33$ ) and cardioembolism and unknown ( $p = 0.39$ ) were comparable (Figure 2). White blood cells were present in most thrombi but in very small amounts only, in one thrombus a small volume of atheromatous material was seen and calcification was not visible in any thrombus.

Thrombi were defined as red (RBC-rich) in 4 (18%), as white (platelet-rich) in 4 (18%) and as mixed in 14 (64%) cases (figure 3). Thrombi from LAA were classified as red in half of the cases ( $n = 4$ ) and as mixed in the other half. Cardioembolic thrombi were defined 5 times (83%) as mixed and once as white (17%). All 3 dissection thrombi were classified as mixed, while the unknown subtype contained 3 white (60%) and 2 mixed thrombi (40%). No white thrombi were found in LAA and none of the cardioembolic, dissection, or unknown subtype thrombi were classified as red. Thrombi in patients with LAA had a significantly higher proportion of red thrombi than in cardioembolisms ( $p = 0.04$ ), and significantly less white thrombi than the unknown subtype ( $p = 0.012$ ) while differences between all other subtypes in number of red and white thrombi were insignificant ( $p > 0.06$ ).

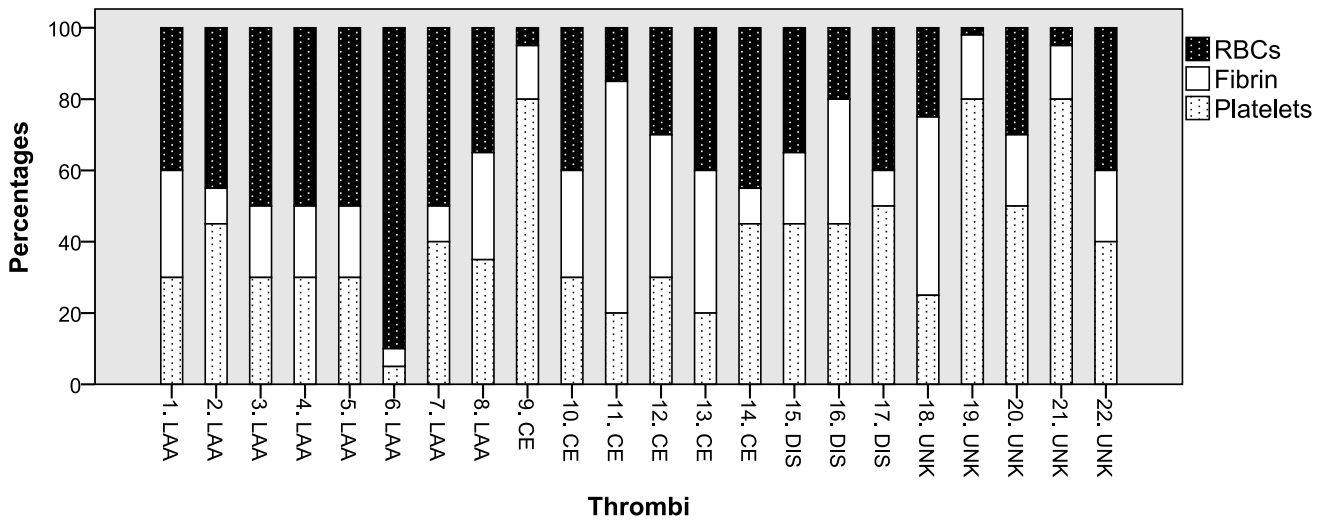
The interobserver reliability for the HU-measurements was excellent (ICC = 0.98). There was a moderate linear correlation between the attenuation and percentage of RBCs ( $r = 0.401$ ,  $p = 0.049$ ), a weak negative linear correlation between attenuation and platelets ( $r = -0.368$ ,  $p = 0.09$ ) and a negligible negative linear correlation for fibrin ( $r = -0.073$ ,  $p = 0.75$ , table 2).

## Discussion

We found that most cerebral thrombi were fresh and that thrombi originating from LAA had the highest percentage of RBCs and were the only stroke subtype with red thrombi. There was a moderate correlation between the percentage of RBCs and the attenuation on NCCT.

Traditional teaching emphasizes that fresh red thrombi, containing mixtures of fibrin and RBCs, originate from low flow-regions while white thrombi, existing mainly out of platelets and fibrin, arise in regions of fast moving blood [23,24]. In cerebral stroke, thrombi from LAA are thought to originate from regions of fast moving blood, while most cardioembolic thrombi are assumed to develop from low flow-regions, such as the left atrial appendage. However, histopathology examination of cerebral stroke thrombi is limited and interpretations about the pathophysiology of cerebral thrombi have mainly been derived from coronary circulation studies.

Thrombi causing myocardial infarction originate from a local coronary artery occlusion due to the atherosclerotic process. In this process RBCs were formerly described to be of little importance [25]. However, more recently the influence of RBCs in coronary atherosclerosis has been described as major, especially in the transition from a stable to an unstable lesion causing occlusions [26–29]. It is therefore more likely that thrombi



**Figure 1. Histopathologic composition of all thrombi. RBC: Red blood cell.**  
doi:10.1371/journal.pone.0088882.g001

originating from (unstable) atherosclerotic plaques have a high RBC-component, especially in cerebral thrombi where the majority of atherosclerotic thrombi are due to acute thromboembolic events immediately after intraplaque hemorrhage [30–32].

In regard to the composition of cardioembolic thrombi, only one study investigated the histopathology of in vivo derived cardioembolic thrombi from patients with atrial fibrillation by either extraction from atrial thrombi during cardiac valve surgery (11 patients) or by removal of embolized cardioembolic thrombi from ilio-femoral and subclavian-brachial arteries during vascular surgery (11 patients) [33]. They found that all cardiac thrombi consisted mainly out of fibrin, platelets and debris. Furthermore, an important difference between cardiac in situ thrombus and embolized thrombi was found; embolized thrombi showed twice as

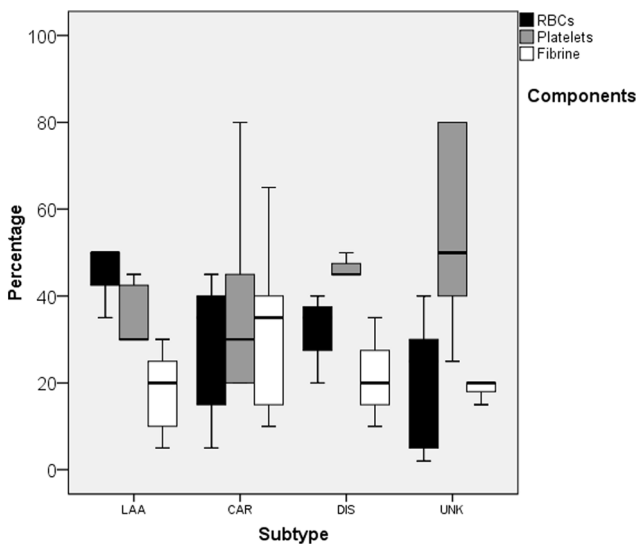
much platelet-rich domains (40% of total) compared to non-embolized atrial thrombus material (20%).

Our findings are not in line with the traditional assumption. We observed that thrombus from LAA contain the highest amount of RBCs and that all red thrombi originate from LAA and none from cardioembolisms.

Our findings are, however, to a great extent in line with the previous histopathologic studies investigating cerebral thrombi, which also found that the traditional assumption is not valid for stroke patients. To our knowledge only three histopathologic studies were performed on thrombi retrieved from cerebral arteries of patients having acute stroke [5–7]. The first two studies, performing histological analyses of thrombi retrieved from intracranial vessels in respectively 5 and 25 patients with ischemic stroke, showed no relation between thrombus composition and stroke subtype [6,7]. These investigators found similar cell components of thrombi derived from either arterial or cardiac sources and also demonstrated that atherosclerotic thrombi contain significant amounts of RBCs. The most recent histopathologic study measured the percentages RBCs, white blood cells and fibrin in 50 patients and related thrombus composition to stroke subtype [5]. They found a broad histopathologic distribution of thrombus composition, although white blood cells were consistently marginal and platelets were not investigated. They also mentioned that no relation between thrombus histopathology and stroke subtype was found. However, any other details about this relationship were not provided. In our study results we do not report percentages of white blood cells or other thrombus components because they were not or only in small amounts present.

Other than only one brief report on a thrombus from a single patient with a dissection, in which the histological examination was described as “serpentine” (fibrin:platelet bands interspersed with accumulations of nucleated cells and RBC-rich accumulations) [6], there are no studies available about the histology of strokes caused by dissection.

To our knowledge this is the first study investigating the age of thrombi in acute cerebral stroke patients. While the traditional assumption emphasizes that fresh thrombi originate mainly from cardioembolisms, we found no differences in age of thrombi between the stroke subtypes. Furthermore, we found a higher



**Figure 2. Boxplots of percentage red blood cells, platelets and fibrin of thrombi by subtype of stroke.** LAA: large artery atherosclerosis, CE: cardioembolism, DIS: dissection, UNK: unknown, RBC: Red blood cell.  
doi:10.1371/journal.pone.0088882.g002

**Table 2.** Thrombus components: relation with stroke subtypes and correlation with attenuation on non-contrast CT.

| Component | Stroke subtype |              |              |              |              |         | Correlation with attenuation |  |
|-----------|----------------|--------------|--------------|--------------|--------------|---------|------------------------------|--|
|           |                | LAA          | CE           | DIS          | UNK          | P-value | r (p-value)                  |  |
| RBC       | mean (range)   | 50% (35–90%) | 35% (5–45%)  | 35% (20–40%) | 25% (2–40%)  | 0.010   | r (p-value) 0.401 (0.049)    |  |
| Platelets | mean (range)   | 30% (5–45%)  | 30% (20–80%) | 45% (45–50%) | 50% (25–80%) | 0.16    | r (p-value) –0.368 (0.09)    |  |
| Fibrin    | mean (range)   | 20% (5–30%)  | 35% (10–65%) | 20% (10–35%) | 20% (15–50)  | 0.52    | r (p-value) –0.073 (0.75)    |  |

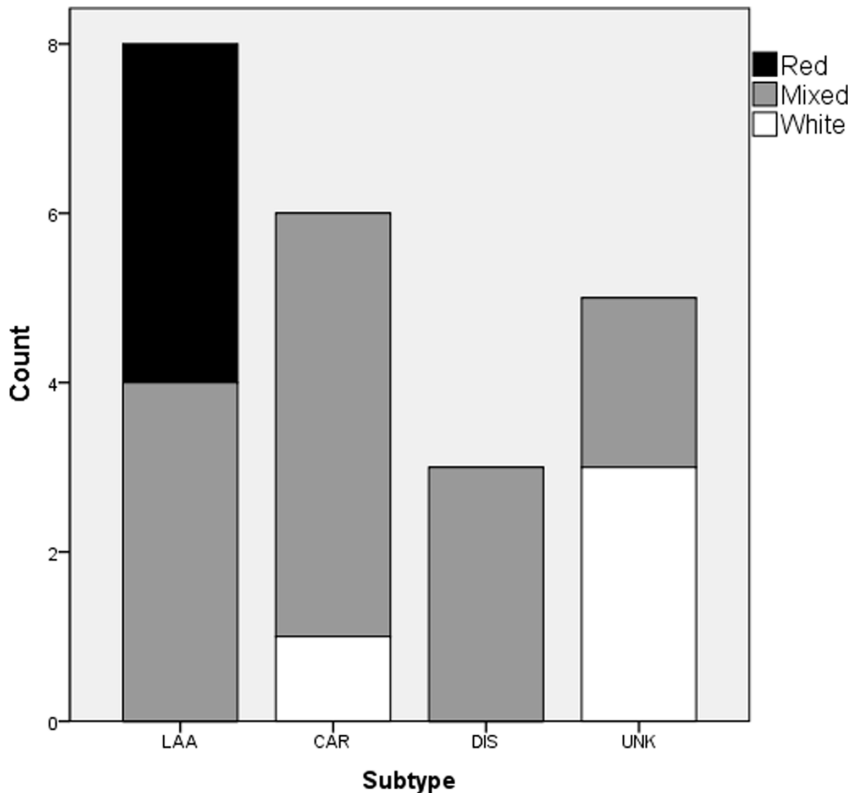
LAA: large artery atherosclerosis, CE: cardioembolism, DIS: dissection, UNK: unknown, RBC: Red blood cell.  
doi:10.1371/journal.pone.0088882.t002

percentage of fresh thrombi compared to studies of myocardial infarction patients, in which at least half of the cardiac thrombi were days or weeks old [22]. This discrepancy increases the thought that the pathogenesis of cardiac and cerebral thrombi may be different. We also found that all lytic and organised thrombi also contained a component that was fresh (less than one day old). Fresh thrombus may occur around the local plaque rupture or an organised thrombus can embolize to the brain, incompletely occlude a brain artery, and then acquire fresh thrombus elements which may ultimately lead to complete vessel thrombosis.

As mentioned, thrombus attenuation could be related to the constituents and composition of the thrombus. The concentration of hemoglobin is one of the determining factors as it has a linear correlation with the attenuation while platelets and atheromatous or cellular debris are known to decrease the attenuation of the thrombus on CT [9,12–14,34–36]. Studies on this topic, however, are experimental, animal studies, or investigations of the venous

sinus thrombus. Other than a recent histopathological study briefly mentioning that they did not find a significant relation between attenuation and composition [5], little is known about the relation between the attenuation of thrombi on NCCT and the histological composition of retrieved cerebral thrombi. We are the first study describing a correlation between the histopathological RBC-component of thrombi and the attenuation on NCCT. This correlation could be stronger in reality as attenuation was measured before IV-rtPA administration while most thrombi were histopathologically investigated after thrombolysis which could have influenced thrombus composition. As RBCs are more vulnerable for rtPA compared to platelets it is likely that the especially RBCs were influenced before histopathological examination.

There are some aspects that merit consideration. First, only a relative small number of thrombi were investigated, consequently making it hard to draw strong conclusions. Second, no clear



**Figure 3.** The number of red, white and mixed thrombi by subtypes. LAA: large artery atherosclerosis, CAR: cardioembolism, DIS: dissection, UNK: unknown.

doi:10.1371/journal.pone.0088882.g003

definition of “red” and “white” thrombi exists which is probably due to the fact that just a few studies have pathologically assessed cerebral thrombi in vivo. Most histopathologic studies based the division in red or white thrombi on “macroscopic evaluation” without any thresholds [5,6,37–40]. To increase the objectivity and reproducibility, we introduced a cut-off value to distinguish between red and white thrombi. Third, the majority of the histopathologically investigated thrombi were resistant to IV-rtPA and we could not investigate thrombi with successful recanalization on IV-rtPA. This may bias the percentage of thrombus composition but not the correlation between histopathology and thrombus attenuation. Fourth, besides the administration of IV-rtPA, the mechanism and timing of the procedures also varied and could have influenced the thrombus composition. Therefore we cannot assess the predictive value of thrombus composition, but this was not the purpose of the study. Fifth, attenuation measurement were performed on 3-mm slices, the thinnest slices available for evaluation. Partial volume effects may have influenced our attenuation results since some thrombi could be smaller than 3 mm or not completely included in one slice. However, this would have probably only led to less differences between subtypes and thus resulting in an underestimation of the results. Due to these considerations larger histopathologic studies of prospectively collected cerebral thrombi are needed to validate our findings. Ideally, the attenuation measurements will be performed

on thin slices and the predictive value of clot composition for recanalization after treatment will be determined.

## Conclusions

In our study with relatively small numbers important findings were seen: we found that the majority of cerebral thrombi is fresh and that there are no differences in age of thrombi between the stroke subtypes. Thrombi originating from large artery atherosclerosis have the highest percentages of red blood cells followed by thrombi due to dissection, while cardioembolic and unknown stroke subtype thrombi have the least red blood cells. A moderate correlation was found between the red blood cell-component and attenuation on non-contrast CT, improving the validation of thrombus attenuation on non-contrast CT as an imaging biomarker for acute ischemic stroke management. These findings will have to be validated in a larger study.

## Author Contributions

Conceived and designed the experiments: JN IvdS LvD BV. Performed the experiments: JN IvdS LvD AV BV. Analyzed the data: JN IvdS LvD AV BV JV WS PdB WM. Contributed reagents/materials/analysis tools: JN IvdS LvD AV BV JV WS PdB WM. Wrote the paper: JN IvdS LvD AV BV JV WS PdB WM.

## References

- Williams GR, Jiang JG, Matchar DB, Samsa GP (1999) Incidence and occurrence of total (first-ever and recurrent) stroke. *Stroke* 30: 2523–2528.
- Kolominsky-Rabas PL, Weber M, Gefeller O, Neundorfer B, Heuschmann PU (2001) Epidemiology of ischemic stroke subtypes according to TOAST criteria: incidence, recurrence, and long-term survival in ischemic stroke subtypes: a population-based study. *Stroke* 32: 2735–2740.
- Bejot Y, Caillier M, Ben Salem D, Couvreur G, Rouaud O, et al. (2008) Ischaemic stroke subtypes and associated risk factors: a French population based study. *J Neurol Neurosurg Psychiatry* 79: 1344–1348.
- Schulz UG, Rothwell PM (2003) Differences in vascular risk factors between etiological subtypes of ischemic stroke: importance of population-based studies. *Stroke* 34: 2050–2059.
- Liebeskind DS, Sanossian N, Yong WH, Starkman S, Tsang MP, et al. (2011) CT and MRI early vessel signs reflect clot composition in acute stroke. *Stroke* 42: 1237–1243.
- Marder VJ, Chute DJ, Starkman S, Abolian AM, Kidwell C, et al. (2006) Analysis of thrombi retrieved from cerebral arteries of patients with acute ischemic stroke. *Stroke* 37: 2086–2093.
- Almekhlafi MA, Hu WY, Hill MD, Auer RN (2008) Calcification and endothelialization of thrombi in acute stroke. *Ann Neurol* 64: 344–348.
- Niessen F, Hilger T, Hoehn M, Hossmann KA (2003) Differences in clot preparation determine outcome of recombinant tissue plasminogen activator treatment in experimental thromboembolic stroke. *Stroke* 34: 2019–2024.
- Kirchhof K, Welzel T, Mecke C, Zoubaa S, Sartor K (2003) Differentiation of white, mixed, and red thrombi: value of CT in estimation of the prognosis of thrombolysis phantom study. *Radiology* 228: 126–130.
- Zivin JA, Fisher M, DeGirolami U, Hemenway CC, Stashak JA (1985) Tissue plasminogen activator reduces neurological damage after cerebral embolism. *Science* 230: 1289–1292.
- Kimura K, Iguchi Y, Shibasaki K, Aoki J, Watanabe M, et al. (2010) Early stroke treatment with IV t-PA associated with early recanalization. *J Neurol Sci* 295: 53–57.
- New PF, Aronow S (1976) Attenuation measurements of whole blood and blood fractions in computed tomography. *Radiology* 121: 635–640.
- Lee SY, Cha SH, Lee SH, Shin DI (2013) Evaluation of the effect of hemoglobin or hematocrit level on dural sinus density using unenhanced computed tomography. *Yonsei Med J* 54: 28–33.
- Black DF, Rad AE, Gray LA, Campeau NG, Kallmes DF (2011) Cerebral venous sinus density on noncontrast CT correlates with hematocrit. *AJNR Am J Neuroradiol* 32: 1354–1357.
- Nielsen JM, van der Schaaf IC, Biessels GJ, van Otterloo AE, van Seters T, et al. (2013) Relationship between thrombus attenuation and different stroke subtypes. *Neuroradiology* 55: 1071–1079.
- Puig J, Pedraza S, Demchuk A, Dainis IEJ, Terres H, et al. (2012) Quantification of thrombus hounsfield units on noncontrast CT predicts stroke subtype and early recanalization after intravenous recombinant tissue plasminogen activator. *AJNR Am J Neuroradiol* 33: 90–96.
- Moftakhar P, English JD, Cooke DL, Kim WT, Stout C, et al. (2013) Density of Thrombus on Admission CT Predicts Revascularization Efficacy in Large Vessel Occlusion Acute Ischemic Stroke. *Stroke* 44: 243–245.
- Nam HS, Kim EY, Kim SH, Kim YD, Kim J, et al. (2012) Prediction of thrombus resolution after intravenous thrombolysis assessed by CT-based thrombus imaging. *Thromb Haemost* 107: 786–794.
- Adams HP Jr, Bendixen BH, Kappelle LJ, Biller J, Love BB, et al. (1993) Classification of subtype of acute ischemic stroke. Definitions for use in a multicenter clinical trial. TOAST. *Trial of Org 10172 in Acute Stroke Treatment*. *Stroke* 24: 35–41.
- Chen CJ, Tseng YC, Lee TH, Hsu HL, See LC (2004) Multisection CT angiography compared with catheter angiography in diagnosing vertebral artery dissection. *AJNR Am J Neuroradiol* 25: 769–774.
- Kim YK, Schulman S (2009) Cervical artery dissection: pathology, epidemiology and management. *Thromb Res* 123: 810–821.
- Rittersma SZ, van der Wal AC, Koch KT, Piek JJ, Henriques JP, et al. (2005) Plaque instability frequently occurs days or weeks before occlusive coronary thrombosis: a pathological thrombectomy study in primary percutaneous coronary intervention. *Circulation* 111: 1160–1165.
- Chaves CJ, Caplan LR (2000) Heparin and oral anticoagulants in the treatment of brain ischemia. *J Neurol Sci* 173: 3–9.
- Jerjes-Sanchez C (2005) Venous and arterial thrombosis: a continuous spectrum of the same disease? *Eur Heart J* 26: 3–4.
- Lin HL, Xu XS, Lu HX, Zhang L, Li CJ, et al. (2007) Pathological mechanisms and dose dependency of erythrocyte-induced vulnerability of atherosclerotic plaques. *J Mol Cell Cardiol* 43: 272–280.
- Rao DS, Goldin JG, Fishbein MC (2005) Determinants of plaque instability in atherosclerotic vascular disease. *Cardiovasc Pathol* 14: 285–293.
- Kolodgie FD, Gold HK, Burke AP, Fowler DR, Kruth HS, et al. (2003) Intraplaque hemorrhage and progression of coronary atheroma. *N Engl J Med* 349: 2316–2325.
- Kockx MM, Cromheeke KM, Knaapen MW, Bosmans JM, De Meyer GR, et al. (2003) Phagocytosis and macrophage activation associated with hemorrhagic microvessels in human atherosclerosis. *Arterioscler Thromb Vasc Biol* 23: 440–446.
- Takaya N, Yuan C, Chu B, Saam T, Polissar NL, et al. (2005) Presence of intraplaque hemorrhage stimulates progression of carotid atherosclerotic plaques: a high-resolution magnetic resonance imaging study. *Circulation* 111: 2768–2775.
- Sitzer M, Muller W, Siebler M, Hort W, Kniemeyer HW, et al. (1995) Plaque ulceration and lumen thrombus are the main sources of cerebral microemboli in high-grade internal carotid artery stenosis. *Stroke* 26: 1231–1233.
- Mathiesen EB, Bonna KH, Joakimsen O (2001) Echolucent plaques are associated with high risk of ischemic cerebrovascular events in carotid stenosis: the tromso study. *Circulation* 103: 2171–2175.
- Kim JS, Nah HW, Park SM, Kim SK, Cho KH, et al. (2012) Risk factors and stroke mechanisms in atherosclerotic stroke: intracranial compared with

- extracranial and anterior compared with posterior circulation disease. *Stroke* 43: 3313–3318.
33. Wysokinski WE, Owen WG, Fass DN, Patrzalek DD, Murphy L, et al. (2004) Atrial fibrillation and thrombosis: immunohistochemical differences between in situ and embolized thrombi. *J Thromb Haemost* 2: 1637–1644.
  34. Kim EY, Heo JH, Lee SK, Kim DJ, Suh SH, et al. (2006) Prediction of thrombolytic efficacy in acute ischemic stroke using thin-section noncontrast CT. *Neurology* 67: 1846–1848.
  35. Besachio DA, Quigley EP 3rd, Shah LM, Salzman KL (2013) Noncontrast computed tomographic Hounsfield unit evaluation of cerebral venous thrombosis: a quantitative evaluation. *Neuroradiology* 55: 941–945.
  36. Buyck PJ, De Keyser F, Vanneste D, Wilms G, Thijs V, et al. (2013) CT Density Measurement and H:H Ratio Are Useful in Diagnosing Acute Cerebral Venous Sinus Thrombosis. *AJNR Am J Neuroradiol* 34: 1568–1572.
  37. Uchida Y, Sakurai T, Kanai M, Shirai S, Morita T (2011) Characterization of coronary fibrin thrombus in patients with acute coronary syndrome using dye-staining angiography. *Arterioscler Thromb Vasc Biol* 31: 1452–1460.
  38. Okamoto K, Takano M, Sakai S, Ishibashi F, Uemura R, et al. (2004) Elevated troponin T levels and lesion characteristics in non-ST-elevation acute coronary syndromes. *Circulation* 109: 465–470.
  39. Tabata H, Mizuno K, Arakawa K, Satomura K, Shibuya T, et al. (1995) Angiographic identification of coronary thrombus in patients with postinfarction angina. *J Am Coll Cardiol* 25: 1282–1285.
  40. Quadros AS, Cambrozzi E, Sebben J, David RB, Abelin A, et al. (2012) Red versus white thrombi in patients with ST-elevation myocardial infarction undergoing primary percutaneous coronary intervention: clinical and angiographic outcomes. *Am Heart J* 164: 553–560.