

# Fracture and dislocation of lumbar vertebrae with entrapment of small bowel: A case report and literature review

Journal of International Medical Research

2019, Vol. 47(2) 1043–1051

© The Author(s) 2019

Article reuse guidelines:

[sagepub.com/journals-permissions](http://sagepub.com/journals-permissions)

DOI: 10.1177/0300060518816205

[journals.sagepub.com/home/imr](http://journals.sagepub.com/home/imr)

Xiaowei Jing<sup>1</sup> , Zhiyuan Gong<sup>1</sup>, Ning Zhang<sup>2</sup>,  
Gang Chen<sup>2</sup>, Fangcai Li<sup>2</sup>, Qixin Chen<sup>2</sup>,  
Zhengkuan Xu<sup>2</sup> and Rui Zhang<sup>1</sup>

## Abstract

Traumatic incarceration of the small bowel accompanied by vertebral fractures and dislocation is rare and usually misdiagnosed until laparotomy. This report presents a rare case of jejunum entrapment between lumbar spine fractures. A 43-year-old man was clamped between two railway tracks on the upper abdomen and lower back. Following ineffective conservative treatment, he underwent a laparotomy due to the development of guarding and rebound tenderness. Loss of vitality of the jejunal loop, which was incarcerated between the L3 and L4 vertebrae, was observed. The necrotic bowel was removed and end-to-end anastomosis was performed. When his condition was stable, anterior and posterior lumbar fixation surgery was performed. The patient had no abdominal complications and lower limb nerve function deficiency during the follow-up period. A review of the literature since 1979 on incarceration of the bowel associated with lumbar fracture and dislocation identified 12 cases: five patients showed persistent neurological symptoms, but none of the patients died as a result of their injuries. It should be borne in mind that patients with hyperextension or flexion-distraction injury of the lumbar spine could show symptoms of intestinal obstruction and bowel incarceration. Enhanced computed tomography or magnetic resonance imaging will be helpful for diagnosis.

<sup>1</sup>Department of Orthopaedic Surgery, Fourth Affiliated Hospital of Zhejiang University School of Medicine, Yiwu, Zhejiang Province, China

<sup>2</sup>Department of Orthopaedic Surgery, Second Affiliated Hospital of Zhejiang University School of Medicine, Hangzhou, Zhejiang Province, China

## Corresponding author:

Qixin Chen, Department of Orthopaedic Surgery, Second Affiliated Hospital of Zhejiang University School of Medicine, 88 Jiefang Road, Hangzhou 310000, Zhejiang Province, China.

Email: [zrcqx@zju.edu.cn](mailto:zrcqx@zju.edu.cn)



**Keywords**

Entrapment, incarceration, bowel, vertebral, fracture, lumbar

Date received: 30 July 2018; accepted: 5 November 2018

**Introduction**

While paralytic ileus associated with retroperitoneal haematoma caused by vertebral fractures is well known, mechanical intestinal obstruction caused by entrapment of the bowel between vertebral bodies has seldom been described.<sup>1,2</sup>

This report describes the case of entrapment of the jejunum in the space surrounded by the abdominal aorta, inferior vena cava and L3/L4 vertebrae, accompanied by an L4 fracture. The report also reviews pertinent published literature on the incarceration of the bowel associated with vertebral fractures.

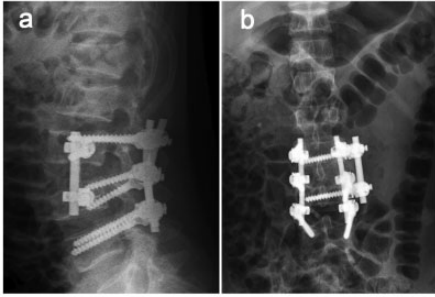
**Case report**

A 43-year-old man was clamped between two railway tracks on the upper abdomen and lower back on 15 May 2016. He was transferred to Xiaoshan District Hospital, Hangzhou, Zhejiang Province, China, 2 h later, where he complained of lower back pain. Lumbar anteroposterior and lateral radiographs showed a fracture of the L4 vertebra. He had no tenderness in the abdomen and neurological examination revealed no sensory deficit or muscle weakness. He received fasting and gastrointestinal decompression due to increasing bile-stained vomiting and aggravated abdominal distension. On the fourth day after the injury, guarding and rebound tenderness were found on abdominal examination. The leukocyte count increased from  $10.4 \times 10^9/l$  to  $22.9 \times 10^9/l$ . Abdominal contrast-enhanced computed tomography (CT) revealed a high

intestinal obstruction and 'para-vertebral haematoma', which was later shown to be the incarcerated jejunum at the laparotomy 6 days after the accident. The patient was transferred to the Department of Orthopaedic Surgery, Second Affiliated Hospital of Zhejiang University School of Medicine, Hangzhou, Zhejiang Province, China on 22 May 2016.

A laparotomy was performed to clear the cause of the obstruction. During surgical exploration, a distended upper jejunum 50 cm away from the Treitz ligament was found, disappearing behind the abdominal aorta through a 3 cm × 4 cm hole of the retroperitoneum at the level of the paraduodenal fossa. The distal collapsed loop was found emerging from the same point. A gap could be felt among the abdominal aorta, vertebral body of L3, and the disc of the L3/L4 space, with the anterior longitudinal ligament ruptured. The necrotic jejunum loop was tracked from the gap through lumbar hyperextension and distraction of the L3/L4 vertebral bodies. The loop was resected and end-to-end anastomosis was performed. The patient received open reduction and internal fixation through the posterior and anterior approach 2 weeks after laparotomy when his condition was stable (Figure 1). No signs of abdominal or surgical wound infection were found, and the patient showed no neurological damage.

This report was prepared in compliance with CARE guidelines<sup>3</sup> and was approved by the institutional review board of the Fourth Affiliated Hospital of Zhejiang University School of Medicine, Yiwu,



**Figure 1.** A 43-year-old male patient who had sustained an L4 vertebral fracture that resulted in entrapment of the jejunum subsequently received open reduction and internal fixation through the posterior and anterior approach 2 weeks after laparotomy when his condition was stable. Lumbar anteroposterior (a) and lateral radiographs (b) taken after the procedure.

Zhejiang Province, China. Written informed consent for participation was obtained from the patient.

## Discussion

Bowel entrapment between vertebral bodies is an extremely rare complication in patients with lumbar fracture or dislocation. It is not usually clearly diagnosed until laparotomy because of the gradual aggravation of the symptoms of intestinal obstruction. This current report describes a case of jejunum entrapment between the L3 and L4 vertebrae, along with a literature review of this rare complication. Only 12 cases from seven countries with detailed clinical information were reported between 1979 and 2016 (Table 1).<sup>2,4-14</sup> The mean age of the patients was 24.2 years. Among the patients, six were children, of whom the youngest was 3 weeks old.

### *Aetiology and mechanism of entrapment*

In this current literature review (Table 1), bowel entrapment between vertebral bodies was usually caused by trauma such as a vehicular accident in nine cases,<sup>2,4-11</sup> fall

from a 3-m height in one case<sup>12</sup> and a crash into hard objects on the back in one case.<sup>13</sup> However, in one case, no trauma history was reported, so lumbar degenerative changes were considered to be the possible cause.<sup>14</sup>

Four patients who sustained a hyperextension injury of the lumbar spine had jejunal incarceration between lumbar spine fracture fragments.<sup>5,6,9,13</sup> The proposed mechanism of injury was hyperextension injury of the lumbar spine, with anterior longitudinal ligament and posterior peritoneum tears. The intra-abdominal pressure increased almost at the same time, which lead to pinching and entrapment of the small intestine. Whether the small bowel is pushed into the intervertebral space or is drawn in by a vacuum created by the hyperextension injury remains to be determined.<sup>4,6,7</sup>

Incorrect use of seatbelts with just the lap belt being fastened was described in three cases; in two of these cases, the patients were children.<sup>5,8,11</sup> The three patients sustained a ‘lap-belt injury’, described as a special injury pattern frequently observed in motor vehicle collisions.<sup>15-21</sup> The sudden deceleration force results in compression of the intra-abdominal organs between the lap belt and the lumbar spine, and a hyperflexion-distraction injury known as a ‘Chance fracture’, which presents with impaction of the anterior components and distraction of the posterior components of the spine.<sup>22-24</sup> The most common intestinal injury is perforation and the most common site is the jejunum.<sup>19,21,25</sup> However, intestinal incarceration has never been associated with lap-belt injury, owing to its low incidence. Complete disruption of a Chance fracture of the lumbar spine induces rupture of the anterior longitudinal ligament and even the retroperitoneum, creating an ‘entrance’ for the bowel to herniate into the space created by fracture and dislocation.

The incidence of small bowel injury in blunt abdominal trauma of children is

**Table 1.** Cases of intestinal entrapment associated with lumbar spine fractures and dislocation reported in the published literature.<sup>2,4-14</sup>

Author and year	Age	Sex	Country of origin	Aetiology	Preoperative duration	Spinal segment	Section of bowel involved	Postoperative complications	Outcome
Vermassen et al. 1988 <sup>4</sup>	22 years	Male	Belgium	Car accident	3 days	L1, L2	Jejunum	Laparotomy wound infection	A motor paresis persisted in the L1-L4 region
Silver et al. 1988 <sup>5</sup>	3 weeks	Male	Canada	Car accident	Immediate surgery	L1, L2	Jejunum	None	No clinical symptoms
Davis et al. 2000 <sup>13</sup>	64 years	Male	America	Waist hit	6 days	L3, L4	Jejunum	<i>Candida albicans</i> infection and cortical infarcts	No clinical symptoms
Ford 1979 <sup>6</sup>	3 years	Male	Australia	Car accident	5 days	L2-L3	Jejunum	None	No clinical symptoms
Eldridge et al. 1993 <sup>7</sup>	37 years	Male	America	Motorcycle accident	Immediate surgery	L4, L5	Jejunum	Pneumonia and left femoral vein thrombosis	Numbness in the left lower extremity
Patterson et al. 1996 <sup>8</sup>	18 years	Male	Canada	Car accident	Immediate surgery	L5, S1	Middle ileum	Pulmonary embolism	Paralysed
Vidmar et al. 2002 <sup>12</sup>	44 years	Male	Germany	Fell down from a 3-m height	48 h	L4, L5	Jejunum	Retroperitoneal abscess	Slight lesion of the plexus
Metaizeau et al. 1980 <sup>9</sup>	8 years	Male	France	Road accident	9 days	L1, L2	Small bowel	None	No Clinical symptoms
Mollitt et al. 1980 <sup>10</sup>	4 years	Male	America	Ejected from a pick-up truck	2 days	L2, L3	Mid-jejunum	None	No Clinical symptoms
Rodger et al. 1991 <sup>2</sup>	1.4 years	Male	Canada	Car accident	13 days	L2	Jejunum	None	No Clinical symptoms
Ko et al. 2015 <sup>14</sup>	82 years	Male	Korea	Degeneration of the intervertebral disc	4 days	L5, S1	Sigmoid colon	None	No Clinical symptoms
PeSENTI et al. 2016 <sup>11</sup>	7 years	Male	France	Car accident	Immediate surgery	L3, L4	Jejunum	Cerebrospinal fluid leak	No neurological recovery

estimated to be between 1% and 7%.<sup>26</sup> A retrospective study that examined small bowel injuries in children reported that three patients were diagnosed with a Chance fracture of the lumbar spine without intestinal incarceration between the fractures.<sup>27</sup> However, of these patients, two also had a jejunal perforation and one had a mesenteric contusion.<sup>27</sup> Seat belts are designed for adults and the shoulder belt seems inappropriate for children; thus, children should remain in booster seats until they fit into adult seatbelts.<sup>28,29</sup>

Similar injuries involving the cervical or thoracic spine that lead to oesophageal injury have also been reported. For example, the most common injury is oesophageal perforation accompanied by cervical spine fracture and dislocation caused by severe hyperextension injury.<sup>30-33</sup> Oesophageal entrapment and occlusion within a cervical or thoracic spine fracture-dislocation is extremely rare, with only three reported cases in the literature.<sup>34-36</sup> Similar intestinal incarceration has also been recorded in sacral, iliac wing and acetabular fractures.<sup>37-43</sup> Oesophageal incarceration may have a similar mechanism to that of small intestinal entrapment and hollow viscera perforation. Even entrapment could be induced by a hyperextension injury of the axial skeleton.

Five intervertebral spaces were involved in the cases reported in the literature and the L1-L2 intervertebral space was the most frequently involved (three of 12 cases).<sup>2,4-14</sup> The jejunum, especially the upper jejunum, was found to be incarcerated in nine cases; the middle ileum in one case, the sigmoid colon in one case, and the small bowel in one case.

### *Diagnosis and treatment*

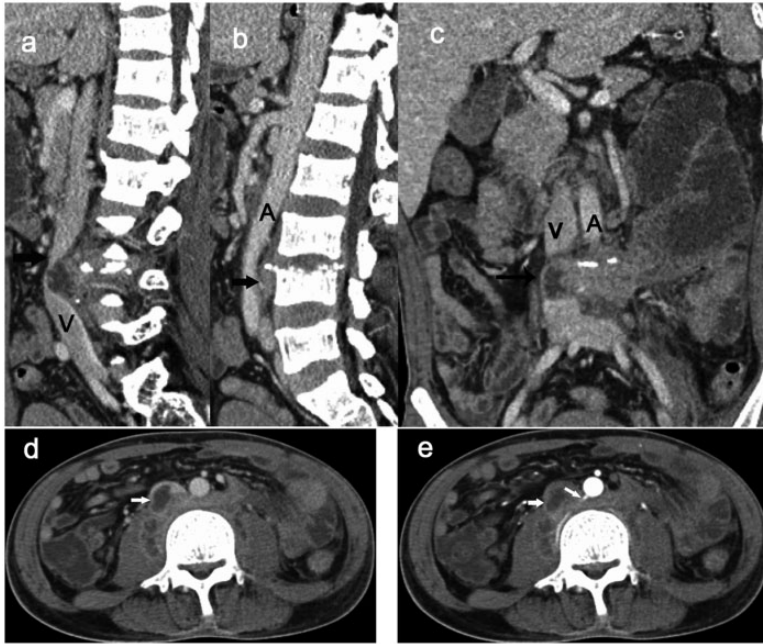
The preoperative diagnosis of bowel incarceration between vertebral bodies is difficult. Waist injury and lumbar fracture or

dislocation may be the first observable symptoms. Paralytic ileus caused by retroperitoneal haematoma accompanying vertebral injuries may be mistaken for the cause of nausea and vomiting. Ileus was considered to be induced by retroperitoneal haematoma in four of 12 cases.<sup>2,4,9,13</sup>

Four patients were discharged after initial assessment but rehospitalized due to severe vomiting.<sup>2,5,10,13</sup> Three reports described two cases of injury that showed collection of air in the spinal canal on CT scanning;<sup>5,13</sup> and one case of herniation of the small bowel loop into the spinal canal was confirmed by magnetic resonance imaging (MRI).<sup>11</sup> Seven cases had positive laparotomy findings, obtained on the basis of diagnostic peritoneal lavage,<sup>7,8</sup> barium meal<sup>4,6,7,10</sup> and sonography.<sup>12</sup>

In this current case, intravenous contrast-enhanced CT revealed that the enhanced intestinal wall was in an unusual location, behind the abdominal aorta and the inferior vena cava (Figure 2). However, the state of the bowel incarceration was not known before laparotomy, which was performed 6 days after the accident. CT scanning, especially contrast-enhanced CT scanning, and MRI can be used to visualize the intestine, which in this current case was remotely located, and thus could provide direct evidence for the need for laparotomy.

Once the diagnosis of intestinal incarceration is clear, laparotomy must be performed to release the incarcerated bowel as soon as possible. The incarcerated intestine could be released by gentle traction of the bowel, extension of the spine by bending the lumbar bridge of the operating table, and distraction of the spine using a vertebral spreader in a step-by-step manner. The incarcerated bowel was reset in all cases described in this report using these methods.<sup>2,4-14</sup> The authors of one study thought that posterior arthrodesis should be performed first to avoid iatrogenic



**Figure 2.** Intravenous contrast-enhanced computed tomography scans of a 43-year-old male patient who had sustained an L4 fracture revealed that the enhanced intestinal wall was in an unusual location, behind the abdominal aorta (A) and the inferior vena cava (V). (a) U-shaped loop incarcerated behind the inferior vena cava and abdominal aorta. (b) Jejunum incarcerated between the L3 and L4 vertebrae behind the abdominal aorta. (c) Jejunum incarcerated between the L3 and L4 vertebrae behind the inferior vena cava. (d) Arterial phase enhancement of the incarcerated intestinal wall (arrow: enhanced intestinal wall). (e) Venous phase enhancement of the incarcerated intestinal wall (arrows: enhanced intestinal wall).

nerve injuries while mobilizing the patient.<sup>11</sup> However, this approach may reduce the ability of lumbar hyperextension and make the resetting of the incarcerated bowel difficult. Considering this situation and the risk of infection, the laparotomy was performed before reduction and stabilization of the spine in the current case.

### Outcomes

During the postoperative course, some complications occurred in these 12 cases.<sup>2,4-14</sup> Pneumonia and left femoral vein thrombosis occurred in one patient;<sup>7</sup> *Candida albicans* infection and cortical infarcts in the distribution of the right middle cerebral artery occurred in one

patient;<sup>13</sup> laparotomy wound infection occurred in one patient;<sup>4</sup> pulmonary embolism occurred in one patient;<sup>8</sup> retroperitoneal abscess on the tenth postoperative day occurred in one patient;<sup>12</sup> and one patient experienced a cerebrospinal fluid leak.<sup>11</sup> Five of 12 patients had different degrees of nerve injury.<sup>4,7,8,11,12</sup> None of the 12 patients died as a result of their injuries.

### Conclusion

In the case of spinal hyperextension injuries accompanied by a blunt impact on the abdomen or hyperflexion-distraction injury, especially in children wearing an adult seatbelt during a head-on collision car accident, when there is an unexplained



progressively worsening intestinal obstruction, physicians should consider the possibility of intestinal incarceration in the spine fracture fragments. CT scanning, especially intravenous contrast-enhanced CT scanning, or MRI are useful for making an early diagnosis of intestinal incarceration-associated spinal injury. Laparotomy should be performed as soon as possible, preferably before necrosis of the incarcerated intestine. Stabilization of the spine fracture and dislocation should be performed after laparotomy when the risk of infection at the fracture site can be minimized effectively. Fixation could be achieved by posterior transpedicular screws with or without anterior vertebral screw fixation.

### Declaration of conflicting interest

The authors declare that there are no conflicts of interest.

### Funding

This work was supported by the Foundation of Zhejiang Educational Committee (grant no. Y201636268).

### ORCID iD

Xiaowei Jing  <http://orcid.org/0000-0001-7062-8088>

### References

- Daniels AH, Ritterman SA and Rubin LE. Paralytic ileus in the orthopaedic patient. *J Am Acad Orthop Surg* 2015; 23: 365–372.
- Rodger RM, Missiuna P and Ein S. Entrapment of bowel within a spinal fracture. *J Pediatr Orthop* 1991; 11: 783–785.
- The CARE Toolkit for Case Reports. Developed by an international group of experts. Designed to increase the accuracy, transparency, and usefulness of case reports, <http://www.care-statement.org/> (2016, accessed 6 December 2018).
- Vermassen F, Van Belleghem Y, Van Velthoven V, et al. Acute bowel entrapment between two lumbar vertebrae. *Injury* 1988; 19: 449–450.
- Silver SF, Nadel HR and Flodmark O. Pneumorrhachis after jejunal entrapment caused by a fracture dislocation of the lumbar spine. *AJR Am J Roentgenol* 1988; 150: 1129–1130.
- Ford WD. Traumatic incarceration of the jejunum between two lumbar vertebrae. *J Pediatr Surg* 1979; 14: 189–190.
- Eldridge TJ, McFall TM and Peoples JB. Traumatic incarceration of the small bowel: case report. *J Trauma* 1993; 35: 960–961.
- Patterson R, Temple WJ, Tranmer B, et al. Traumatic intervertebral incarceration of ileum: a unique lap belt injury. *Injury* 1996; 27: 596–598.
- Metaizeau JP, Prévot J, Schmitt M, et al. Intestinal strangulation between two vertebra following an axial dislocation of L1/L2. *J Pediatr Surg* 1980; 15: 193–194.
- Mollitt DL, Ballantine TV and DeRosa GP. Jejuno-renal injury following traumatic hyperextension. *J Trauma* 1980; 20: 996–998.
- Pesenti S, Blondel B, Faure A, et al. Small bowel entrapment and ureteropelvic junction disruption associated with L3 Chance fracture-dislocation. *World J Clin Cases* 2016; 4: 264–268.
- Vidmar J, Veselko M, Sever M, et al. Traumatic jejunal entrapment in a patient with Bechterew disease. *Unfallchirurg* 2002; 105: 63–64 [Article in German, English abstract].
- Davis RE, Mittal SK, Perdakis G, et al. Traumatic hyperextension/hyperflexion of the lumbar vertebrae with entrapment and strangulation of small bowel: case report. *J Trauma* 2000; 49: 958–959.
- Ko S, Park NK, Cho KJ, et al. Lower extremity radicular pain caused by entrapped sigmoid colon between L5 and S1 vertebrae. *Ann Rehabil Med* 2015; 39: 844–847.
- Garrett JW and Braunstein PW. The seat belt syndrome. *J Trauma* 1962; 2: 220–238.
- Torba M, Hijazi S, Gjata A, et al. Seat belt syndrome, a new pattern of injury in

- developing countries. Case report and review of literature\*. *G Chir* 2014; 35: 177–180.
17. Onu DO, Hunn AW and Bohmer RD. Seat belt syndrome with unstable Chance fracture dislocation of the second lumbar vertebra without neurological deficits. *BMJ Case Rep* 2014; 2014: bcr2013202412.
  18. Eberhardt CS, Zand T, Ceroni D, et al. The seatbelt syndrome – do we have a chance?: A report of 3 cases with review of literature. *Pediatr Emerg Care* 2016; 32: 318–322.
  19. Masudi T, McMahon HC, Scott JL, et al. Seat belt-related injuries: a surgical perspective. *J Emerg Trauma Shock* 2017; 10: 70–73.
  20. Anderson PA, Henley MB, Rivara FP, et al. Flexion distraction and chance injuries to the thoracolumbar spine. *J Orthop Trauma* 1991; 5: 153–160.
  21. Triantafyllou SJ and Gertzbein SD. Flexion distraction injuries of the thoracolumbar spine: a review. *Orthopedics* 1992; 15: 357–364.
  22. McGrath N, Fitzpatrick P, Okafor I, et al. Lap belt injuries in children. *Ir Med J* 2010; 103: 216–218.
  23. Schonfeld D and Lee LK. Blunt abdominal trauma in children. *Curr Opin Pediatr* 2012; 24: 314–318.
  24. Szadkowski MA and Bolte RG. Seatbelt syndrome in children. *Pediatr Emerg Care* 2017; 33: 120–125.
  25. Sivit CJ, Taylor GA, Newman KD, et al. Safety-belt injuries in children with lap-belt ecchymosis: CT findings in 61 patients. *AJR Am J Roentgenol* 1991; 157: 111–114.
  26. Mercer S, Legrand L, Stringel G, et al. Delay in diagnosing gastrointestinal injury after blunt abdominal trauma in children. *Can J Surg* 1985; 28: 138–140.
  27. Holland AJ, Cass DT, Glasson MJ, et al. Small bowel injuries in children. *J Paediatr Child Health* 2000; 36: 265–269.
  28. Winston FK, Durbin DR, Kallan MJ, et al. The danger of premature graduation to seat belts for young children. *Pediatrics* 2000; 105: 1179–1183.
  29. Committee on Injury and Poison Prevention; American Academy of Pediatrics. Selecting and using the most appropriate car safety seats for growing children: guidelines for counseling parents. *Pediatrics* 2002; 109: 550–553.
  30. Morrison A. Hyperextension injury of the cervical spine with rupture of the oesophagus. *J Bone Joint Surg Br* 1960; 42-B: 356–357.
  31. Latimer EA, Clevenger FW and Osler TM. Tear of the cervical esophagus following hyperextension from manual traction: case report. *J Trauma* 1991; 31: 1448–1449.
  32. Nerot C, Jeanneret B, Lardenois T, et al. Esophageal perforation after fracture of the cervical spine: case report and review of the literature. *J Spinal Disord Tech* 2002; 15: 513–518.
  33. Stringer WL, Kelly DL Jr, Johnston FR, et al. Hyperextension injury of the cervical spine with esophageal perforation. Case report. *J Neurosurg* 1980; 53: 541–543.
  34. Chiu WC, Rodriguez A, Greif WM, et al. Entrapment and obstruction of the esophagus from thoracic spine hyperextension-dislocation injury. *J Trauma* 1999; 46: 959–961.
  35. Delaphe RS Jr, Vattoth S and Sonavane SK. Esophageal entrapment with blunt thoracic spinal trauma. *Emerg Radiol* 2013; 20: 243–246.
  36. Maroney MJ, Mirvis SE and Shanmuganathan K. Esophageal occlusion caused by thoracic spine fracture or dislocation: CT diagnosis. *AJR Am J Roentgenol* 1996; 167: 714–715.
  37. Hurt AV, Ochsner JL and Schiller WR. Prolonged ileus after severe pelvic fracture. *Am J Surg* 1983; 146: 755–757.
  38. Lu MS, Peng KT, Chin CC, et al. Associated injury in pelvic fracture: colon herniation. *J Trauma* 2008; 64: 1144.
  39. Crowther AJ, McMaster JM, Abercrombie J, et al. Sacral fracture associated with small bowel entrapment: a case report. *J Orthop Trauma* 2006; 20: 580–583.
  40. Kekez T and Augustin G. Small bowel entrapment associated with pelvic fracture: a case report with review of the literature and differentiation of clinical picture. *Eur J Emerg Med* 2012; 19: 60–61.



41. Stubbart JR and Merkley M. Bowel entrapment within pelvic fractures: a case report and review of the literature. *J Orthop Trauma* 1999; 13: 145–148.
42. Tanaka R, Nagahara H, Maeda K, et al. A case of bowel perforation due to traumatic hernia at a pelvic fracture site: a case report and review of the literature. *BMC Surg* 2017; 17: 81.
43. Kim WY, Ryu JD, Choi MS, et al. Bowel herniation after traumatic symphysis pubis diastasis. *J Orthop Trauma* 2001; 15: 445–447.