

# Cervical Cancer Surgery: Current State of Affairs

Fan Chun Yang<sup>1</sup>, Wei Huang<sup>1</sup>, Weihong Yang<sup>1</sup>, Jie Liu<sup>1</sup>, Guihai Ai<sup>1</sup>, Ning Luo<sup>1</sup>, Jing Guo<sup>2</sup>, Peng Teng Chua<sup>3</sup>, Zhongping Cheng<sup>1,2\*</sup>

<sup>1</sup>Department of Obstetrics and Gynecology, Shanghai Tenth People's Hospital, Tongji University, <sup>2</sup>Gynecological Minimally Invasive Surgery Research Center, Tongji University School of Medicine, Shanghai, China, <sup>3</sup>Mahkota Medical Centre, Melaka, Malaysia

## Abstract

Cervical cancer surgery has a history of more than 100-years whereby it has transitioned from the open approach to minimally invasive surgery (MIS). From the era of clinical exploration and practice, minimally invasive gynecologic surgeons have never ceased to explore new frontiers in the field of gynecologic surgery. MIS has fewer postoperative complications, including reduction of treatment-related morbidity and length of hospital stay than laparotomy; this forms the mainstay of treatment for early-stage cervical cancer. However, in November 2018, the New England Journal of Medicine had published two clinical studies on cervical cancer surgery (Laparoscopic Approach to Cervical Cancer [LACC]). Following these publications, laparoscopic surgery for early-stage cervical cancer has come under intense scrutiny and negative perceptions. Many studies began to explore the concept of standardized surgery for early-stage cervical cancer. In this article, we performed a review of the history of cervical cancer surgery, outlined the standardization of cervical cancer surgery, and analyzed the current state of affairs revolving around cervical cancer surgery in the post-LACC era.

**Keywords:** Cervical cancer, laparoscopic surgery, radical hysterectomy

## INTRODUCTION

Cervical cancer is a common gynecologic malignancy, and mortality rates remain significantly high in developing countries.<sup>[1]</sup> Surgery, which can be performed by various approaches (laparotomy, vagina, and laparoscopy or robotic), is still the main treatment for early-stage cervical cancer.<sup>[2,3]</sup> For ease of discussion, we have divided the more than 100-year history of cervical cancer surgery into three stages, including the period of (1) clinical exploration and practice, (2) normalization and standardization, and (3) minimally invasive surgery (MIS).

For a considerable time, laparotomy has been the choice for cervical cancer surgery. Even though it is widely accepted as an effective treatment, laparotomy is highly invasive and is associated with an increased risk of patient morbidity, tissue trauma, complications, and longer hospital stay.<sup>[4]</sup>

MIS has shown excellent outcomes and has been successful in providing safe treatment for early-stage cervical cancer. Similar recurrence rates and patterns of recurrence have been shown in patients who had a laparoscopic or an open approach to radical hysterectomy by several retrospective studies. There is a reduction of overall postoperative complications, treatment-related morbidity, and length of hospital stay.<sup>[5]</sup>

However, studies by Ramirez *et al.* and Melamed *et al.* stated a reduction in overall survival (OS) of patients undergoing minimally invasive radical hysterectomy.<sup>[6,7]</sup> In the Laparoscopic Approach to Cervical Cancer (LACC) Trial, Outcomes were compared between MIS and open radical hysterectomy in 1:1 ratio, highlighting that the

### Article History:

Submitted: 7 June 2020

Revised: 21 July 2020

Accepted: 18 January 2021

Published: 30 April 2021

### Access this article online

Quick Response Code:



Website:  
www.e-gmit.com

DOI:  
10.4103/GMIT.GMIT\_81\_20

**Address for correspondence:** : Dr. Zhongping Cheng,

Department of Obstetrics and Gynecology, Shanghai Tenth People's Hospital, Tongji University, Shanghai, China.

Gynecological Minimally Invasive Surgery Research Center, Tongji University School of Medicine, Shanghai, China.

E mail: mdcheng18@263.net

This is an open access journal, and articles are distributed under the terms of the Creative Commons Attribution-NonCommercial-ShareAlike 4.0 License, which allows others to remix, tweak, and build upon the work non-commercially, as long as appropriate credit is given and the new creations are licensed under the identical terms.

**For reprints contact:** WKHLRPMedknow\_reprints@wolterskluwer.com

**How to cite this article:** Yang FC, Huang W, Yang W, Liu J, Ai G, Luo N, *et al.* Cervical cancer surgery: Current state of affairs. *Gynecol Minim Invasive Ther* 2021;10:75-83.

4.5-year disease-free survival rate and OS rate for MIS were inferior compared to Open radical hysterectomy, as well as higher rates of loco-regional recurrence. The survival rate for MIS versus open approach was reported to be 86% versus 96.5%.<sup>[6]</sup> Therefore, laparoscopic surgery for early-stage cervical cancer has come under intense scrutiny, leading to a big practice change, not in favor of MIS. It is imperative to note, however, that findings from the LACC trial have been questioned amid findings of bias and lack of standardization in surgeon technique and experience. Many centers worldwide performing MIS for cervical cancer has also produced good surgical outcome data in contrary to the LACC study. Brandt *et al.* compared oncologic and perioperative outcomes in patients who underwent MIS compared to laparotomy for newly diagnosed early-stage cervical carcinoma and found 5-year disease-free survival (DFS) rates were 87.0% in the MIS group and 86.6% in the laparotomy group, whereas 5-year disease-specific survival rates were 96.5% and 93.9%, respectively. In their review, the 5-year OS rates were 96.5% (MIS) and 87.4% (open), respectively. They concluded that MIS radical hysterectomy for cervical carcinoma did not confer worse oncologic outcomes.<sup>[8]</sup> Similarly, Diver *et al.* found that MIS radical hysterectomy did not compromise patient outcomes and has shown a reduction in morbidity.<sup>[9]</sup> The recent SUCCOR study in an international European cohort showed higher relapse and risk of death in the MIS group and interestingly the authors also found the use of uterine manipulator to be associated with poorer outcomes in patients, though agreeable with its technical advantage in performing a radical hysterectomy.<sup>[10]</sup> A detailed analysis of 53 cases of stage IA1-IB1 Cervical Cancer that underwent Laparoscopic Radical Hysterectomy from January 2009 to May 2014 in a tertiary MIS center has found an astounding 100 percent 5-year survival rate. The authors concluded that a “Tumour-Free” concept, coupled with a standardized surgical approach of adequate radicality and parametrial resection, performed by experienced surgeons with adequate case-load yielded the excellent outcomes.<sup>[11]</sup> It is obvious that many questions remain unanswered, and the shift of practice from MIS back to the old open approach is hasty to say the least. Standardization and adequacy of radicality in laparoscopic radical hysterectomy should be the main focus as surgical experience and skill are not the same as a drug being tested. In view of this, the Asia Pacific Association for Gynecologic Endoscopy and Minimally Invasive Therapy has released a statement and effort has been made in the MITOR Trial to research and answer this vital clinical question.<sup>[12]</sup> In this article, we reviewed the century-old-history of cervical cancer surgery, outlined the standardization of cervical cancer surgery, and analyzed the current state of affairs revolving around cervical cancer surgery in the post-LACC era.

## THE PERIOD OF CLINICAL EXPLORATION AND PRACTICE

The initial exploration of cervical cancer surgery was a long and arduous journey for many a gynecologist. The first successful abdominal extirpation of a cancerous uterus was performed in January 1878 by Wilhelm Alexander Freund, a German gynecologist. He put forward the view of clamping and systematic suturing of uterine arteries, suturing of the cardinal ligament, uterosacral ligament, and broad ligament during hysterectomy, which not only prompted the standardization of hysterectomy but also made gynecologic surgery a stand-alone field.<sup>[13]</sup> In 1895, Ries and Clark found that cervical cancer spreads to surrounding tissues and lymph nodes beyond the limits of excision of the standard hysterectomy. They proposed a more radical hysterectomy, removing more of the broad ligament, vagina, and associated pelvic lymph nodes.<sup>[13]</sup> In 1898, Wertheim performed the first radical hysterectomy in patients with cervical cancer. He corrected the misconception that cervical cancer metastasizes to surrounding tissues and lymph nodes only in late stages and put forward that surrounding tissues and pelvic lymph nodes metastases may also exist in the early stage.<sup>[14]</sup> He further described the details on radical hysterectomy and the extension of excision, including removing the uterus, parametrium, upper vaginal tissues, and pelvic lymph nodes.<sup>[13]</sup> This procedure has become the rudiment of the modern cervical cancer surgery and has contributed to the exploration of the standardized surgical treatment of cervical cancer. However, these surgical methods have high mortality rates, multiple complications, such as excessive intraoperative bleeding, and low 5-year survival rates. For example, Wertheim’s report in 1911 had reported that the surgical rate was 50%, the mortality rate was 18.6%, and the 5-year cure rate was 42.4% among 500 patients who underwent surgery.<sup>[13,15]</sup> Owing to high mortality and low survival rates, more scholars and gynecologists began to explore new innovations in surgery. In 1901, Schauta systematically performed a vaginal radical hysterectomy (RVH) on a 43-year-old woman, and later reported on 564 patients who underwent RVH with a 48.7% operability rate, 10.8% mortality rate, 39.7% 5-year cure rate, and 10.6% intraoperative bladder and rectal injury.<sup>[13,16]</sup> Afterward, the British doctor, Victor Bonney performed 500 Wertheim radical hysterectomies for cervical cancer and invented auxiliary hysterectomy forceps, vascular forceps, tissue forceps, and other devices, which greatly reduced many complications such as intraoperative bleeding and improved 5-year survival rate as well as reduced the mortality rate, contributing to the subsequent exploration of normalization and standardization of cervical cancer surgery.<sup>[17-19]</sup>

## THE PERIOD OF NORMALIZATION AND STANDARDIZATION

In 1944, Meigs devised a new surgical operation by performing bilateral pelvic lymph node dissection combined with Wertheim’s operation. He stated that pelvic lymphadenectomy

could improve the prognosis and emphasized that detailed anatomy and certain peri-operative procedures such as anemia correction and strengthening hospital care should be performed. The study reported the 5-year survival rate of patients with stage I was 81.1%, and with stage II was 61.8% of 100 patients. This study also demonstrated no surgical-related mortality and a positive lymph node rate of 17% in 47 patients.<sup>[13,20]</sup> In 1956, Meigs first reported in the literature that radical hysterectomy combined with pelvic lymphadenectomy, which is known as the Class III operation, should be the standardized procedure for the surgical treatment of cervical cancer and also contributed significantly to the development of the concept of standardization in Radical Hysterectomy.<sup>[21,22]</sup>

Meanwhile, Piver *et al.* proposed five classes of surgical treatment of cervical cancer that were widely used.<sup>[22]</sup> The proposal of this resulted in patients with different stages of cancer being stratified into respective class for hysterectomy. For example, patients in stage I-IIA can be adequately treated with type III surgery, which was also known as Meigs' operation. This operation included ligation of uterine artery at its origin from the internal iliac artery and cardinal ligament resected at the pelvic wall, the uterosacral ligaments excised at their sacral attachments, vesicocervical ligament excised at its bladder attachment, one-half of the vagina removed, and the pelvic lymphadenectomy as a routine. The Class IV operation is used for more extensive excision. It was suggested that based on the clinical stage, the appropriate class of surgical operation will improve the surgical outcome and reduce complications as well as mortality rates. At the same time, surgery combined with timely and appropriate administration of adjuvant treatment further reduces the risk of cervical cancer recurrence after surgery. Early administration of adjuvant treatments as illustrated in an animal study by Lee and Kay has demonstrated this.<sup>[23]</sup> However, this classification of surgery does not provide for nerve sparing and as a result, bladder dysfunction, atony, and various fistula remain a contentious problem postsurgery.

In order to solve the need for nerve retention and reduce intraoperative bleeding, Okabayashi improved the Wertheim operation at Kyoto Imperial University in 1921. The modified operation is characterized by removing more extensive parametrial tissue and separating the posterior leaf of the vesicouterine ligament to ensure the bladder branch to be isolated from the uterus, cervix, and vagina without injury. Meanwhile, he elucidated the importance of finely dissecting the anterior and posterior leaf of the vesicouterine ligament to avoid vascular injury and reduce the risk of intraoperative and postoperative bleeding.<sup>[24,25]</sup> He also proposed the concept of "Okabayashi Space," which consists of the peritoneum of the lateral rectal fossa (the apex of the space), the lateral wall of the rectum, the lateral side of the

uterosacral ligament (the medial side), and the internal iliac artery and its accompanying veins (the lateral side), the posterior wall which is the lateral rectal ligament (rectal column), the anterior wall which is the posterior wall of the cardinal ligament, and the uterine artery. Dissecting the space to separate the paravesical space and "Okabayashi Space," and opening the ureteric tunnel to dissect and free the pelvic plexus nerve to avoid bladder branch injury.<sup>[24-26]</sup> Afterward, Yabuki systematically described the concept of nerve-sparing radical hysterectomy in 1991 for the first time.<sup>[27]</sup> This procedure involved the severance of round ligament and pelvic infundibular ligament, showing paravesical and pararectal space, separation and severance of the uterine artery, isolation of the ureter, and exposing the lamina consisting of the cardinal ligament (containing uterine artery and vein), lateral ligaments (containing middle rectal artery and vein) and pelvic splanchnic nerve. Then the fine exposure and separation of the deep uterine vein and lateral ligament in their entirety, in order to extirpate the cardinal ligament and performed an extensive nerve-sparing hysterectomy. This method reduced blood loss and prevented brisk bleeding from the venous plexuses. Afterward, Shingo Fujii *et al.* clarified the anatomic identification and functional outcomes of the nerve-sparing Okabayashi radical hysterectomy<sup>[28]</sup> They emphasized the importance of the separation of vascular part and connective tissues to preserve one of the branches of the pelvic splanchnic nerves during the division of the parametrial tissues, and further separating the hypogastric nerve, the pelvic splanchnic nerve, and by the separation of the inferior vesical vein in the posterior leaf of the vesicouterine ligament, the bladder branch from the inferior hypogastric plexus can be identified and preserved. In 2008, Fujii observed Okabayashi's surgery videos and confirmed this point once again.<sup>[26]</sup> In this technique, there is a significant reduction in the incidence of postoperative bladder dysfunction after radical hysterectomy for cervical cancer. This was shown in the reduction of incidence of urinary retention and an increase in patient satisfaction of micturition. In 2009, Sabrina *et al.* conducted a retrospective study, analyzing the data from 124 patients with cervical cancer of stages IA to IIA that were performed on the non-nerve-sparing radical hysterectomy group (1994–1999) and 122 patients with stages IA to IIA in the group where nerve-sparing was the intention-to-treat (2001–2005). They found that nerve-sparing surgery not only reduced postoperative complications but was also not an independent prognostic factor affecting local recurrence.<sup>[29]</sup>

## THE PERIOD OF MINIMALLY INVASIVE SURGERY

MIS for cervical cancer has undergone a series of processes. French gynecologist Dargent first performed laparoscopic

vaginal radical trachelectomy (LVRT) in 1984. For early cervical cancer with cervical tumor lesions  $\leq 2$  cm; patients' reproductive function were preserved; and eight cases of pregnancy were reported in 1994, one of which successfully delivered, creating a new era of fertility-preserving surgery for early cervical cancer.<sup>[30]</sup> However, it did not describe the presence of lymph node metastases, lymphovascular space invasion, and other high-risk factors in these patients and whether this operation could be adopted to preserve fertility under the condition of these high-risk factors mentioned above for the tumor lesion  $\leq 2$  cm or more than 2 cm, but it promoted subsequent research. There was considerable interest in the MIS approach since then, leading up to when Marchiole *et al.* compared the effects of laparoscopic-assisted radical vaginal trachelectomy (LARVT or Dargent's operation) with laparoscopic-assisted vaginal radical hysterectomy (LARVH) on patients' intraoperative and postoperative mortality and recurrence. They compared the intraoperative and postoperative complications and tumor recurrence of 118 patients undergoing LARVT or Dargent's operation and 139 patients undergoing LARVH. The results showed no significant statistical difference between the two groups in terms of intraoperative and postoperative complications and tumor recurrence. In addition, this study showed that tumoral size, presence/absence of lymph node metastases, and lymphovascular space invasion (LVSI) as well as the depth of invasion were the determinant factors affecting prognosis and recurrence. LARVT, which is worthy of application, is still a safe operation for women with stage IA2-IB1 (tumor size  $<2$  cm, negative pelvic lymph nodes and LVSI, and depth of tumor  $\leq 10$  mm) and can preserve fertility without increasing mortality and risk of tumor recurrence.<sup>[31]</sup> For tumor size  $<2$  cm, some surgeons suggest that a 2 cm cutoff may be used for vaginal trachelectomy, whereas a 4 cm cutoff may be used for abdominal trachelectomy.<sup>[32]</sup> The 2020 National Comprehensive Cancer Network (NCCN) guideline points out that tumors that are 2–4 cm have to be carefully selected for a fertility-sparing approach as many of these patients may require postoperative adjuvant therapy due to pathologic risk factors (e.g., positive nodes).<sup>[33]</sup> However, for nonfertility-sparing surgery for cervical cancer, it has experienced some processes. The first laparoscopic radical hysterectomies were performed in 1992/1993 by Nezhat, Querleu, Lee in the US, Europe, and Asia, respectively.<sup>[34]</sup> In 1992, Nezhat reported a patient with stage IA2 cervical cancer who underwent laparoscopic radical hysterectomy combined with pelvic and para-aortic lymph node dissection. This procedure firstly removed the pelvic lymph nodes and the para-aortic lymph nodes, and then the uterus. It was not reported in detail, whether all pelvic and para-aortic lymph nodes have been removed, and whether this operation is

a standard cervical cancer procedure but required further research.<sup>[34]</sup> In 2006, Sert firstly reported robot-assisted extensive hysterectomy and showed that robotic surgical procedure was more precise than traditional laparoscopic radical hysterectomy. This report has increased the popularity and application of robotic surgery in the future.<sup>[35]</sup> In 2008, Querleu and Morrow put forward a new classification, called the Querleu–Morrow Classification of Radical Hysterectomy. The classification is based only on lateral extent of resection and included four types of radical hysterectomy (A–D: Type A: Minimum resection of paracervix; Type B: Transection of paracervix at the ureter; Type C: Transection of paracervix at the junction with the internal iliac vascular system and Type D: Laterally extended resection), which guided surgical standards and procedures for patients with different clinical stages, making the surgical treatment of cervical cancer a more unified approach. Meanwhile, this is also the formal way of presentation of the standardization of laparoscopic radical hysterectomy for cervical cancer, which has profound significance.<sup>[36]</sup> Nevertheless, this type of classification has not been able to provide a more precise and accurate anatomical guide, since there were problems such as lack of lymph node dissection details. For example, there is the limit between paracervical lymphadenectomy and that of internal Iliac lymph-node dissection and has neglected the removal of lateral external iliac nodes. In order to improve on this deficiency, Querleu *et al.* updated the classification in 2017. The new Querleu–Morrow Classification of Radical Hysterectomy in 2017 has provided a more accurate anatomical guide and emphasized a finer resection range, such as clarifying the extent and range of lateral cervical resection, the minimum length of the vaginal resection, and the range of the dorsal and ventral parametrium resections. Meanwhile, it has emphasized excision of the central tumor with clear margins and removal of any potential sites of nodal metastasis. So, this classification has become more popular and its application in the surgical community has reached a worldwide acceptance.<sup>[37]</sup>

## THE POST LAPAROSCOPIC APPROACH TO CERVICAL CANCER ERA

In 2018, the New England Journal of Medicine published two studies on early-stage cervical cancer. One of which was from MD Anderson Cancer Center's LACC trial; they analyzed 319 patients in the minimally invasive group and 312 patients in the abdominal group and found that MIS was associated with a lower rate of OS (3-year rate, 93.8% vs. 99.0%) and DFS (4.5-year rate, 86.0% vs. 96.5%).<sup>[6]</sup> Alexander Melamed *et al.* found that over a median follow-up of 45 months, the 4-year mortality was 9.1% among women who underwent MIS and 5.3% among

those who underwent open surgery by analyzing the data from the National Cancer Database and the Surveillance, Epidemiology, and End Results 18-registry database. In the period of 2006–2010, MIS coincided with a decline in the 4-year relative survival rate of 0.8% with the gradual increase in the rate of MIS.<sup>[7]</sup> These two studies revealed that open surgery may be better than the MIS to treat early-stage cervical cancer. What's more, a secondary endpoint of the LACC trial is to use quality-of-life and symptom assessments (12-item Short-Form Health Survey, Functional Assessment of Cancer Therapy-sysc Ap [FACT-Cx], EuroQoL-5D, and MD Anderson Symptom Inventory) before surgery and at 1 and 6 weeks and 3 and 6 months after surgery (FACT-Cx was also completed at additional time points up to 54 months after surgery) to assess the quality of life (QoL). The results showed that women with early-stage cervical cancer had similar postoperative QoL 6 weeks after surgery and beyond regardless of whether they had an open or minimally invasive radical hysterectomy. The authors concluded that open radical hysterectomy should be recommended for patients with early-stage cervical cancer.<sup>[38]</sup>

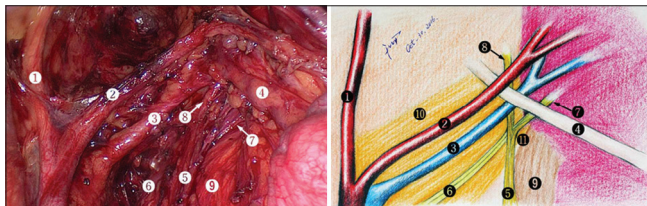
2020 NCCN Guidelines for Cervical Cancer also point out that Stage IA1 surgery can be performed by vaginal or laparotomy or MIS approach. However, for stage IA1 with LVSI and IA2 or stage IB1-IB2 as well as selected stage IB3-IIA1, it should be performed by laparotomy rather than the MIS.<sup>[33]</sup> So, scholars began to explore the effect of MIS and open surgery for cervical cancer, focusing on the logic and rationality of laparoscopic surgery. Most of these studies have shown that MIS is better than abdominal surgery in terms of postoperative morbidity (bleeding, intraoperative and postoperative complications, and length of hospital stay). It is worthy to note that many studies have shown that tumor size, surgical volume, surgery approach (the use of Uterine manipulator, colpotomy, circulating CO<sub>2</sub>, squeezing the cervix), the standardization of surgery, whether cervical cancer surgery was performed by qualified doctors, etc., affected the outcomes of surgery and OS as well as DFS.<sup>[3,12,39-52]</sup> For example, Magrina *et al.* first compared the perioperative results of patients undergoing radical hysterectomy by robotics, laparoscopy, and laparotomy and found that there was no significant difference in the mean number of removed lymph nodes among the three surgery approaches.<sup>[4]</sup> Querleu *et al.* retrospectively analyzed patients undergoing radical hysterectomy from 2004 to 2008 and found that surgery at high-volume centers is associated with decreased local recurrence risk, lower overall mortality, and improved survival.<sup>[36]</sup> Alfonso *et al.* retrospectively analyzed the OS and DFS of 236 patients with stage IA1-IB who underwent laparotomy and correspondingly 628 patients who underwent

robotic surgery from January 2011 to December 2017. The results showed that there was no significant difference between open and robotic surgery and the recurrence pattern was similar in both groups. In addition, tumor size and Grade 3 were found to be independent significant risk factors.<sup>[53]</sup> Lee *et al.* retrospectively identified stage IB1-IIA2 patients who underwent either laparoscopic (158 patients) or open radical hysterectomy (435 patients) to compare survival outcomes between 2000 and 2018, and found that MIS was an independent poor prognostic factor for the patient with PFS and MIS has a higher recurrence rate than laparotomy.<sup>[3]</sup> However, MIS does not affect the PFS of patients with stage IB1 cervical cancer with a tumor diameter  $\leq 2$  cm, which also supported that the feasibility and safety of MIS surgery for tumor size smaller than 2 cm.<sup>[3,5,40]</sup> At the same time, studies have found that MIS preserving fertility for patients with tumor diameters  $< 2$  cm was also safe and feasible.<sup>[54]</sup> The above literature also proved the deficiencies in the LACC trial. The results of this trial did not in particular evaluate patients with “low-risk” cervical cancer (including tumor size,  $< 2$  cm, no LVSI; depth of invasion  $< 10$  mm; and no lymph-node involvement) because the trial was not powered to evaluate the oncologic outcomes of “low-risk” patients under the two surgical approaches.<sup>[6]</sup> Nevertheless, some scholars have found that in terms of OS or DFS, for tumors diameter  $> 2$  cm, such as 2–4 cm in diameter, laparotomy was better than MIS.<sup>[3,55]</sup> This suggests that tumor size affects the outcomes of laparotomy and MIS. Hence, as illustrated in various studies and also the APAGE-MIT 12-point statement, careful patient selection, standardization of technique, the performance of surgery by experienced Endoscopic Surgeons utilizing the “Tumour-Free” concept should be the principle in cervical cancer surgery.<sup>[12]</sup>

As the results of a secondary endpoint – QOL, of the LACC trial shows that MIS was not superior to open surgery,<sup>[38]</sup> researchers found the long learning curve MIS, the use of uterine manipulator and intraperitoneal colpotomy maybe the cause of tumor exposure to the circulating CO<sub>2</sub>, leading to an increased risk of recurrence after surgery.<sup>[41-43,48]</sup> Lee *et al.* put forward that the learning curve, standardization of radical hysterectomy, the surgeon's surgical skills, capability and qualification, surgical instruments, follow-up period, etc., impacted the outcomes of MIS for cervical cancer. They emphasized that the surgeon's performance of radical hysterectomy should be standardized, especially the standardized excision of the parametrial tissues. Surgeons need to learn, train, and be qualified, and careful selection of patients is crucial to produce good outcomes. When counseling patients for MIS, patient concerns should be addressed by applying data from qualified MIS centers and the result of the LACC trial treated with caution.<sup>[53]</sup> Kanao

et al. applied the “no-look no-touch” technique in total laparoscopic radical hysterectomy (TLRH). This technique incorporates 4 specific measures consisting of creating a vagina cuff, avoidance of a uterine manipulator, minimal handling of the uterine cervix, and bagging of the specimen to prevent tumor spillage. Overall, the no-look no-touch technique reduced the risk of intraoperative tumor spillage during TLRH for early-stage cervical cancer and ensured the feasibility and safety of MIS.<sup>[41]</sup>

In 2009 and 2017, our team established the concept of “Cheng’s triangular area” and “Cheng’s Cross” to accurately dissect uterine arteries and parametrium tissues, which has been used in laparoscopic radical hysterectomy (LRH). The triangular area consists of the uterine round ligament, infundibulopelvic ligament, and the external iliac vessels. We can quickly dissect the uterine artery and ureter from this area [Figure 1]. It can reduce complications such as intraoperative bleeding and postoperative ureteral injury by taking advantage of these anatomical landmarks as well as can improving the quality of surgery and patient prognosis.<sup>[56,57]</sup> Based on Clinical Stage of Cervical Cancer (FIGO, 2009 vs. 2018), Steven Piver Classification/ Querleu-Morrow Classification of Radical Hysterectomy, the “tumor-free” concept, and the laparoscopic dissection to expose “the para-cervical precision anatomy”, we present a concept, known as “Laparoscopic Regional Radical Hysterectomy, LRRH” [Figures 2 and 3].<sup>[58]</sup> We dissected the cardinal ligament, the vesico-cervical ligament, and the pelvic autonomic nerve plexus through the “Cheng’s triangular area” and “Cheng’s Cross” approaches, exposed the paracervical tissue, and then completed regional radical hysterectomy in 5 key steps: (1) cutting the cardinal ligament to the pelvic sidewall-the internal iliac vessels (transection to the edge); cutting the cardinal ligament to the bottom-Pelvic floor muscle fascia (vertical excision to the pelvic floor muscle fascia) [Figures 3 and 4]; (2) cutting the vesico-cervical ligament near/from the bladder (ureter papillary) [Figure 4]; (3) the uterosacral ligaments are

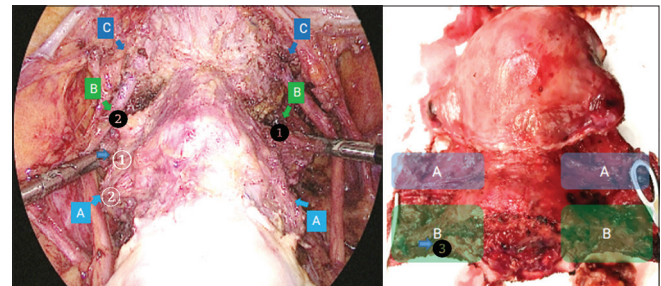


**Figure 1:** Cheng’s triangle and Cheng’s Cross (from reference<sup>[56,57]</sup>) dissection of uterine branch of pelvic plexus and Cheng’s Cross. 1 = Internal iliac artery; 2 = uterine artery; 3 = deep uterine vein; 4 = ureter; 5 = hypogastric nerve; 6 = pelvic splanchnic nerves from S2 to S4 sacral roots; 7 = uterine branch of pelvic plexus; 8 = bladder branch of pelvic plexus; 9 = uterosacral ligament; 10 = cardinal ligament; 11 = cardinal-uterosacral confluence

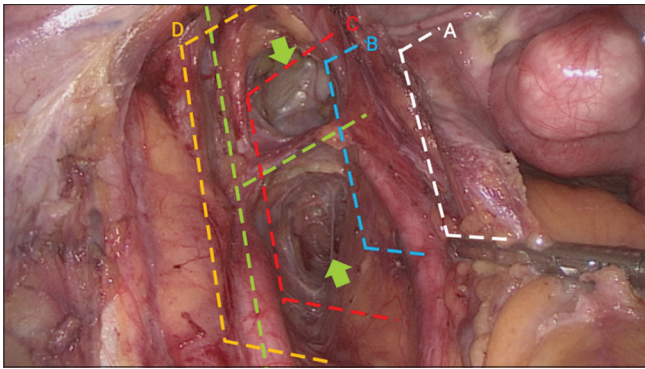
excised at their sacral attachment (2–3 cm) [Figure 3]; (4) cutting the branch of the uterine autonomic nerve (dissection of the space of Okabayashi) [Figure 3]; (5) resection of the upper one-half of the vagina (15–20 mm of vagina and para-vagina from the tumor or cervix) [Figure 3]. LRRH for cervical cancer can resect more extensively the para-cervical tissues and can be used as a standard of MIS for early-stage cervical cancer. Despite the controversy surrounding MIS for early-stage cervical cancer, MIS and its continued application should go on, pending a larger scale study involving centers of excellence in MIS, with surgery performed by qualified endoscopic surgeons (the upcoming MITOR trial).<sup>[12,59]</sup>

### CONCLUSION AND PROSPECT

At present, the detection rate of cervical cancer is ever increasing due to better diagnostic modalities and more women seek treatment, due to the improvement of cervical cancer screening methods. In terms of treatment of the early-stage cervical cancer, surgery is the mainstay. The various approaches of abdominal, vaginal, and MIS each have a role to play in patient management with its’ own pros and cons. For example, the advantage of transabdominal surgery is that it may have a higher OS and DFS, but it increased intraoperative bleeding, the incidence of postoperative fever, and adhesion. Transvaginal radical hysterectomy can be applied to difficult operations in open surgery or patients with obesity or cardiovascular disease. However, the disadvantages of this operation are that it is not possible to dissect the pelvic lymph nodes and the field of surgery is deficient. Compared with them, MIS can reduce intraoperative and postoperative complications as well as can be combined with transvaginal surgery. MIS also has the significant advantage of smaller incisions, faster recovery, and a shorter interval before starting adjuvant therapy.<sup>[23]</sup>

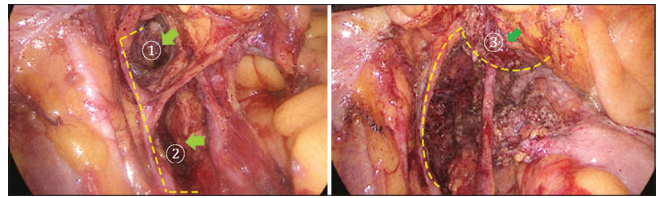


**Figure 2:** Laparoscopic regional radical hysterectomy (LRRH) (from reference<sup>[58]</sup>) A region: ① the cardinal ligament–the part of the uterine artery; ② Vesico-cervical ligament has been cut off (ventral leaf), in front of the ureter. B region: ① the cardinal ligament–the part of uterine Venous system and connective tissue; ② Vesico-cervical ligament (dorsal leaf), behind ureter; ③ the uterosacral ligament. Region A the complete removal of the cardinal ligament; Region B the complete removal of the paravaginal tissue; Region C the enough boundary of vaginal resection



**Figure 3:** Laparoscopic regional radical hysterectomy. (a) Limited radical hysterectomy (paracervix or lateral parametrium is excised halfway between the ureter and the cervix; ventral/dorsal parametrium is minimal excision; vaginal resection is minimal, routinely <10 mm). (b) Resection of the paracervix at the ureter (partial resection of the uterosacral peritoneal fold of the rectouterine ligament (dorsal parametrium) and the vesicouterine (ventral parametrium) ligament also is a standard component of this resection. The vesicovaginal ligament is not resected). (c) Transection of the paracervix at its junction with the internal iliac vascular system (transection of the rectovaginal and rectouterine ligaments is performed at the rectum. Transection of the ventral parametrium ligament is performed at the bladder. Both the vesicouterine and vesicovaginal ligaments are resected. Cutting the cardinal ligament to the pelvic sidewall - The internal iliac vessel and cutting the cardinal ligament to the bottom - Pelvic floor muscle fascia as well as cutting the vesico-cervical ligament near the bladder. The ureter is completely mobilized and lateralized. The length of the vaginal cuff is adjusted to the vaginal extent of the tumor. This resection includes nerve-preserving and no preservation of autonomic nerves radical hysterectomy). (d) Laterally extended resection (paracervix or lateral parametrium is resected at the pelvic wall, including resection of the internal iliac vessels and/or components of the pelvic sidewall; ventral parametrium is resected at the bladder and not applicable if part of exenteration; dorsal parametrium is resected at the sacrum and not applicable if part of exenteration)

For MIS, there is an urgent need to clarify the issue of lack of standardization as well as rigorously evaluating surgeon performance before drawing conclusions. Studies have suggested a learning curve of at least 50 cases of MIS radical hysterectomy before a surgeon can be proficient and produce excellent outcomes for cervical cancer surgery. The “tumour-free” concept, should be uniform and evaluated further. The long-standing issue of tumor spread and loco-regional recurrence due to uterine manipulator has been repeatedly questioned, as some researches have shown that excellent outcomes can be achieved despite its’ use. It is likely that a standardized use of Uterine Manipulator will help answer this doubt. Similar to the practice of MIS in the field of General and Colo-Rectal Surgery, progress and change are inevitable. We should not regress back to the practice of open surgery for Gynecologic Cancers more than 120 years ago, but instead, policies should be inclusive, and various approaches to Cervical Cancer surgery should be given its own merits and demerits, with the ultimate aim of providing excellent patient outcomes.<sup>[12,60]</sup>



**Figure 4:** Procedures to cut the cardinal ligament (from reference<sup>[58]</sup>) (cut the cardinal ligament to the pelvic sidewall - The internal iliac vessels; Cut the cardinal ligament to the bottom - pelvic floor muscle fascia; Cut the vesico-cervical ligament near the bladder). The dotted line represents the extent that transection of the paracervix at its junction with the Internal iliac Vascular System. Green arrows: ① lateral vesical space; ② lateral rectal space; ③ Resection of the anterior, lateral, and posterior leaf of the vesico-cervical ligament near the bladder (ureter papillary)

### Financial support and sponsorship

Nil.

### Conflicts of interest

Dr. Zhongping Cheng, an editorial board member at *Gynecology and Minimally Invasive Therapy*, had no role in the peer review process of or decision to publish this article. The other authors declared no conflicts of interest in writing this paper.

### REFERENCES

- Vu M, Yu J, Awolude OA, Chuang L. Cervical cancer worldwide. *Curr Probl Cancer* 2018;42:457-65.
- Koh WJ, Greer BE, Abu-Rustum NR, Apte SM, Campos SM, Cho KR, et al. Cervical cancer, version 2.2015. *J Natl Compr Canc Netw* 2015;13:395-404.
- Kim SI, Cho JH, Seol A, Kim YI, Lee M, Kim HS, et al. Comparison of survival outcomes between minimally invasive surgery and conventional open surgery for radical hysterectomy as primary treatment in patients with stage IB1–IIA2 cervical cancer. *Gynecol Oncol* 2019;153:3-12.
- Magrina JF, Kho RM, Weaver AL, Montero RP, Magtibay PM. Robotic radical hysterectomy: Comparison with laparoscopy and laparotomy. *Gynecol Oncol* 2008;109:86-91.
- Kim JH, Kim K, Park SJ, Lee JY, Kim K, Lim MC, et al. Comparative effectiveness of abdominal versus laparoscopic radical hysterectomy for cervical cancer in the postdissemination Era. *Cancer Res Treat* 2019;51:788-96.
- Ramirez PT, Frumovitz M, Pareja R, Lopez A, Vieira M, Ribeiro R, et al. Minimally invasive versus abdominal radical hysterectomy for cervical cancer. *N Engl J Med* 2018;379:1895-904.
- Melamed A, Margul DJ, Chen L, Keating NL, Carman MG, Yang J, et al. Survival after minimally invasive radical hysterectomy for early-stage cervical cancer. *N Engl J Med* 2018;379:1905-14.
- Brandt B, Sioulas V, Basaran D, Kuhn T, LaVigne K, Gardner GJ, et al. Minimally invasive surgery versus laparotomy for radical hysterectomy in the management of early-stage cervical cancer: Survival outcomes. *Gynecol Oncol* 2020;156:591-7.
- Diver E, Hinchcliff E, Gockley A, Melamed A, Contrino L, Feldman S, et al. Minimally invasive radical hysterectomy for cervical cancer is associated with reduced morbidity and similar survival outcomes compared with laparotomy. *J Minim Invasive Gynecol* 2017;24:402-6.
- Chiva L, Zanagnolo V, Querleu D, Martin-Calvo N, Arévalo-Serrano J, Căpîlna ME, et al. SUCCOR study: An international European cohort observational study comparing minimally invasive surgery versus open abdominal radical hysterectomy in patients with stage IB1 cervical cancer. *Int J Gynecol Cancer* 2020;30:1269-77.
- Lee CL, Huang KG, Chua PT. Minimally invasive surgery in radical

- hysterectomy for cervical cancer. *Eur J Gynaecol Oncol* 2020;41:852-7.
12. Lee CL, Huang KG, Nam JH, Lim PC, Shun FWW, Lee KW, *et al.* The statement of the Asia-pacific association for gynecologic endoscopy and minimally invasive therapy for LACC study. *Gynecol Minim Invasive Ther* 2019;8:91-3.
  13. Polat Dursun M, Gultekin M. The history of radical hysterectomy. *J Low Genit Tract Dis* 2011;15:235-45.
  14. Baskett TF. Hysterectomy: Evolution and trends. *Best Pract Res Clin Obstet Gynaecol* 2005;19:295-305.
  15. Wertheim E. Die erweiterte Abdominale Operation bei Carcinoma Colli Uteri; (auf Grund von 500 Fallen). Berlin: Urban & Schwarzenberg; 1911.
  16. Marin F, Plesca M, Bordea CI, Moga MA, Blidaru A. Types of radical hysterectomies: From thoma ionescu and wertheim to present day. *J Med Life* 2014;7:172-6.
  17. Bonney V. The results of 500 cases of Wertheim's operation for carcinoma of the cervix. *J Obstet Gynaecol Brit Emp* 1941;48:421-35.
  18. Macleod D. Then and now; A tribute to Victor Bonney. *Proc R Soc Med* 1959;52:223-30.
  19. Powell JL. Powell's pearls William Francis Victor Bonney, MD (1872—1953). *Obstet Gynecol Surv* 2005;60:337-40.
  20. Navratil E. Joe Vincent Meigs (1892-1963). *CA Cancer J Clin* 1975;25:31-2.
  21. Meigs JV. Radical hysterectomy with bilateral dissection of the pelvic lymph nodes for cancer of the cervix. *Surg Clin N Am* 1956;36:1083-116.
  22. Piver MS, Rutledge F, Smith JP. Five classes of extended hysterectomy for women with cervical cancer. *Obstet Gynecol* 1974;44:265-72.
  23. Lee CL, Kay N. Inhibition of ovarian cancer growth and implantation by paclitaxel after laparoscopic surgery in a mouse model. *Am J Obstet Gynecol* 2006;195:1278-81.
  24. Okabayashi H. Radical abdominal hysterectomy for cancer of the cervix uteri, modification of the Takayama operation. *Surg Gynecol Obstet* 1921;33:335-41.
  25. Fujii S. Original film of the Okabayashi's radical hysterectomy by Okabayashi himself in 1932, and two films of the precise anatomy necessary for nerve-sparing Okabayashi's radical hysterectomy clarified by Shingo Fujii. *Int J Gynecol Cancer* 2008;18:383-5.
  26. Yabuki Y, Asamoto A, Hoshiba T, Nishimoto H, Nishikawa Y, Nakajima T. Radical hysterectomy: An anatomic evaluation of parametrial dissection. *Gynecol Oncol* 2000;77:155-63.
  27. Yabuki Y, Asamoto A, Hoshiba T, Nishimoto H, Kitamura S. Dissection of the cardinal ligament in radical hysterectomy for cervical cancer with emphasis on the lateral ligament. *Am J Obstet Gynecol* 1991;164:7-14.
  28. Fujii S, Takakura K, Matsumura N, Higuchi T, Yura S, Mandai M, *et al.* Anatomic identification and functional outcomes of the nerve sparing Okabayashi radical hysterectomy. *Gynecol Oncol* 2007;107:4-13.
  29. van den Tillaart SA, Kenter GG, Peters AA, Dekker FW, Gaarenstroom KN, Fleuren GJ, *et al.* Nerve-sparing radical hysterectomy: Local recurrence rate, feasibility, and safety in cervical cancer patients stage IA to IIA. *Int J Gynecol Cancer* 2009;19:39-45.
  30. Dargent D, Bmn JL, Remy I. Pregnancies following radical trachelectomy for invasive cervical cancer. *Gynecol Oncol* 1994;52:105-8.
  31. Marchiole P, Benchaib M, Buenerd A, Lazlo E, Dargent D, Mathevet P. Oncological safety of laparoscopic-assisted vaginal radical trachelectomy (LARVT or Dargent's operation): A comparative study with laparoscopic-assisted vaginal radical hysterectomy (LARVH). *Gynecol Oncol* 2007;106:132-41.
  32. Li J, Wu X, Li X, Ju X. Abdominal radical trachelectomy: Is it safe for IBI cervical cancer with tumors  $\geq 2$  cm? *Gynecol Oncol* 2013;131:87-92.
  33. Abu-Rustum NR, Yashar CM, Bean S, Bradley K, Campos SM, Chon HS, *et al.* NCCN guidelines insights: Cervical cancer, version 1.2020. *J Natl Compr Cancer Netw* 2020;18:660-6.
  34. Nezhat CR, Burrell MO, Nezhat FR, Benigno BB, Welander CE. Laparoscopic radical hysterectomy with paraaortic and pelvic node dissection. *Am J Obstet Gynecol* 1992;166:864-5.
  35. Sert BM, Abeler VM. Robotic-assisted laparoscopic radical hysterectomy (Piver type III) with pelvic node dissection – Case report. *Eur J Gynaecol Oncol* 2006;27:531-3.
  36. Querleu D, Morrow CP. Classification of radical hysterectomy. *Lancet Oncol* 2008;9:297-303.
  37. Querleu D, Cibula D, Abu-Rustum NR. 2017 update on the Querleu – Morrow classification of radical hysterectomy. *Ann Surg Oncol* 2017;24:3406-12.
  38. Frumovitz M, Obermair A, Coleman RL, Pareja R, Lopez A, Ribero R, *et al.* Quality of life in patients with cervical cancer after open versus minimally invasive radical hysterectomy (LACC): A secondary outcome of a multicentre, randomised, open-label, phase 3, non-inferiority trial. *Lancet Oncol* 2020;21:851-60.
  39. Matsuo K, Shimada M, Yamaguchi S, Matoda M, Nakanishi T, Kikkawa F, *et al.* Association of Radical Hysterectomy Surgical Volume and Survival for Early-Stage Cervical Cancer. *Am. J. Obstet. Gynecol.* 2019;133:1086-98.
  40. Chen C, Liu P, Ni Y, Tang L, Xu Y, Bin X, *et al.* Laparoscopic versus abdominal radical hysterectomy for stage IBI cervical cancer patients with tumor size  $\leq 2$  cm: A case-matched control study. *Int J Clin Oncol* 2020;25:937-47.
  41. Kanao H, Matsuo K, Aoki Y, Tanigawa T, Nomura H, Okamoto S, *et al.* Feasibility and outcome of total laparoscopic radical hysterectomy with no-look no-touch technique for FIGO IBI cervical cancer. *J Gynecol Oncol* 2019;30:e71.
  42. Yuan P, Liu Z, Qi J, Yang X, Hu T, Tan H. Laparoscopic radical hysterectomy with enclosed colpotomy and without the use of uterine manipulator for early-stage cervical cancer. *J Minim Invasive Gynecol* 2019;26:1193-8.
  43. Kanao H, Aoki Y, Takeshima N. Unexpected result of minimally invasive surgery for cervical cancer. *J Gynecol Oncol* 2018;29:e73.
  44. Tjalma WA. The survival after a radical hysterectomy for cervical cancer by open surgery is significantly better then after minimal invasive surgery: Evidence beats gut feeling! *Eur J Obstet Gynecol Reprod Biol* 2018;229:1-3.
  45. van der Velden J, Mom CH. Tailoring radicality in early cervical cancer: How far can we go? *J Gynecol Oncol* 2019;30:e30.
  46. Pennington KP, Urban RR, Gray HJ. Revisiting minimally invasive surgery in the management of early-stage cervical cancer. *J Natl Compr Canc Netw* 2019;17:86-90.
  47. Hillemanns P, Brucke S, Holthaus B, Kimmig R, Lampe B, Runnebaum I, *et al.* Updated Opinion of the Uterus Commission of the Gynecological Oncology Working Group (AGO) and the Gynecological Endoscopy Working Group (AGE) of the German Society of Gynecology and Obstetrics (DGGO) on the Randomized Study Comparing Minimally Invasive with Abdominal Radical Hysterectomy for Early-stage Cervical Cancer (LACC). *Geburtsh Frauenheilk* 2019;79:145-7.
  48. Pyeon SY, Hur YJ, Lee JM. Rethinking the next step after unexpected results associated with minimally invasive radical hysterectomy for early cervical cancer. *J Gynecol Oncol* 2019;30:e43.
  49. Leitao MM. The change in landscape after a new landmark is constructed: Radical hysterectomy for early cervical cancer and Minimally Invasive Surgery. *Gynecol Oncol* 2019;153:1-2.
  50. Kim M, Kong TW, Kim S, Kim SC, Kim YB, Kim JW, *et al.* Minimally invasive surgery for radical hysterectomy in women with cervical cancer: Korean Society of Gynecologic Oncology, Korean Society of Obstetrics and Gynecology, and Korean Society of Gynecologic Endoscopy and Minimally Invasive Surgery position statement. *J Gynecol Oncol* 2019;30:e104.
  51. Melamed A, Rauh-Hain JA, Ramirez PT. Minimally invasive radical hysterectomy for cervical cancer: When adoption of a novel treatment precedes prospective, randomized evidence. *J Clin Oncol* 2019;37:3069-74.
  52. Tewari KS. Minimally invasive surgery for early-stage cervical carcinoma: Interpreting the laparoscopic approach to cervical cancer trial results. *J Clin Oncol* 2019;37:3075-80.
  53. Alfonzo E, Wallin E, Ekdahl L, Staf C, Radestad AF, Reynisson P, *et al.* No survival difference between robotic and open radical hysterectomy for women with early-stage cervical cancer: Results from a nationwide population-based cohort study. *Eur J Cancer* 2019;116:169-77.
  54. Bixel KL, Fowler JM. Fertility-sparing surgery for early-stage cervical cancer: Does surgical approach have an impact on disease outcomes? *Am J Obstet Gynecol* 2019;220:417-9.
  55. Kim SI, Lee M, Lee S, Sch DH, Kim HS, Kim K, *et al.* Impact of



- laparoscopic radical hysterectomy on survival outcome in patients with FIGO stage IB cervical cancer: A matching study of two institutional hospitals in Korea. *Gynecol Oncol* 2019;155:75-82.
56. Yang W, Liu M, Liu L, Jiang C, Chen L, Qu X, *et al.* Uterine-sparing laparoscopic pelvic plexus ablation, uterine artery occlusion, and partial adenomyomectomy for adenomyosis. *J Minim Invasive Gynecol* 2017;24:940-5.
  57. Kang L, Gong J, Cheng Z, Dai H, Liping H. Clinical application and midterm results of laparoscopic partial resection of symptomatic adenomyosis combined with uterine artery occlusion. *J Minim Invasive Gynecol* 2009;16:169-73.
  58. Yang W, Chen R, Li C, Li L, Luo N, Cheng Z, *et al.* Laparoscopic regional radical hysterectomy showed promising clinical outcomes in early-stage cervical cancer. *Gynecol Minim Invasive Ther* 2020;94:220-6.
  59. Chua PT, Lee CL, Huang KG. 100% 5-year survival rate in laparoscopic radical hysterectomy for early-stage cervical cancer is an achievable task. *Gynecol Minim Invasive Ther* 2020;9:53.
  60. Chong GO, Park NY, Hong DG, Cho YL, Park IS, Lee YS. Learning curve of laparoscopic radical hysterectomy with pelvic and/or para-aortic lymphadenectomy in the early and locally advanced cervical cancer: Comparison of the first 50 and second 50 cases. *Int J Gynecol Cancer* 2009;19:1459-64.