

# Magnetic resonance imaging findings in patients with initial manifestations of perianal fistulas

Khawaja Bilal Waheed,<sup>a</sup> Waseem Jan Shah,<sup>b</sup> Bilal Altaf,<sup>c</sup> Muhammad Amjad,<sup>d</sup> Fawad Hameed,<sup>c</sup> Sana Wasim,<sup>e</sup> Muhammad Zia UlHassan,<sup>a</sup> Zahra Mohammed Abuabdullah,<sup>a</sup> Selvin Nesaraj Rajamonickam,<sup>a</sup> Zechriah Jebakumar Arulanatham<sup>f</sup>

From the <sup>a</sup>Department of Radiology, <sup>b</sup>Department of Pediatric Surgery, <sup>c</sup>Department of General Surgery, and <sup>d</sup>Department of Internal Medicine, King Fahd Military Medical Complex, Dhahran, Saudi Arabia; <sup>e</sup>Department of Radiology, Rawalpindi Medical College, Rawalpindi, Pakistan, and <sup>f</sup>Research Unit, Prince Sultan Military College of Health Sciences, Dammam, Saudi Arabia

**Correspondence:** Dr. Khawaja Bilal Waheed · Department of Radiology, King Fahd Military Medical Complex, Dhahran 31932, Saudi Arabia · T: 966-13-8440000 ext: 3222 · khawaja@kfmmc.med.sa · ORCID: <https://orcid.org/0000-0001-6340-3139>

**Citation:** Waheed KB, Shah WJ, Altaf B, Amjad M, Hameed F, Wasim S, et al. Magnetic resonance imaging in patients with initial manifestations of perianal fistulas. *Ann Saudi Med* 2020; 40(1): 42-48. DOI: 10.5144/0256-4947.2020.42

**Received:** June 8, 2019

**Accepted:** October 8, 2019

**Published:** February 6, 2020

**Copyright:** Copyright © 2020, Annals of Saudi Medicine, Saudi Arabia. This is an open access article under the Creative Commons Attribution-NonCommercial-NoDerivatives 4.0 International License (CC BY-NC-ND). The details of which can be accessed at <http://creativecommons.org/licenses/by-nc-nd/4.0/>

**Funding:** None.

**BACKGROUND:** Crohn's disease (CD) is a serious cause of perianal disease and the incidence is increasing in Saudi Arabia. MR imaging may document specific features that may help to foresee Crohn's disease in patients making an initial presentation.

**OBJECTIVE:** Present MR imaging findings of perianal fistulas in patients making an initial presentation.

**DESIGN:** Retrospective, observational.

**SETTING:** Radiology clinic in Dhahran.

**PATIENTS AND METHODS:** All previously undiagnosed and untreated patients who presented for the first time to the outpatient clinics from September 2015-2018 with perianal fistulas were retrospectively evaluated. Previously diagnosed CD patients, post-surgical or intervention cases were excluded. Fistulas were categorized as low or high anal, simple or complex, and were graded per St. James University Hospital Classification. Imaging was interpreted by two experienced readers based on the Van Assche score.

**MAIN OUTCOME MEASURES:** Fistula features on MR imaging and diagnosis of CD.

**SAMPLE SIZE:** 171 patients.

**RESULTS:** Of 171 patients, 139 (81.3%) were males with mean age of 37.2 (12.7) years; the 32 females had a mean age of 35.8 (10.6) years. Twenty-one patients (12.3%) had CD. Fourteen (40.4%) patients with complex fistulas had CD in comparison to only 5 (4.8%) simple fistula patients ( $P=.0005$ ). More than half of patients with complex and high anal fistulas had CD ( $P=.0005$ ). Females were more affected than males ( $P=.0005$ ).

**CONCLUSION:** Complex or high anal fistula on MR imaging may be the initial presentation of CD and warrant further work up to establish the diagnosis.

**LIMITATIONS:** Retrospective, small sample, single center, and short duration study.

**CONFLICT OF INTEREST:** None.

Perianal disease comprises complications that occur in the rectum or anus. It is crucial to identify serious causes of perianal disease.<sup>1</sup> Crohn's Disease (CD) is one of such etiologies, the incidence of which is increasing in Saudi Arabia.<sup>2,3</sup> The exact cause of CD remains unknown.<sup>4</sup> Currently, hereditary/ genetic, immunologic and environmental factors have been suggested to play a role in its development.<sup>4</sup> Risk factors include young age, ethnicity (whites and Ashkenazi Jewish descent), positive family history, cigarette smoking, use of non-steroidal anti-inflammatory drugs, environmental (urban living) and certain diets (high fat or refined foods).<sup>5</sup> It is known that a significant number of patients with CD develop perianal disease, and it can also be their first presentation to hospital before any luminal diagnosis.<sup>5,6</sup> While there is no definitive cure for CD, medical therapies can greatly reduce symptoms and achieve early remission. Surgery may be an option in refractory or difficult cases.<sup>7</sup>

A perianal fistula (or fistula-in-ano) is frequently the result of an anal abscess. Both clinical and imaging-based classifications are used to describe perianal fistulas. These classifications are important in helping the surgeon make treatment decisions. Park's classification<sup>4</sup> is familiar to most colorectal surgeons; this anatomic classification describes perianal fistulas based on the relationship of the fistulous tract to the anal sphincter (**Figure 1**). Magnetic resonance (MR) imaging plays a key role in detection and characterization of perianal fistulas and to delineate their extent,<sup>8,9</sup> that may be surgically occult or need drainage prior to medical (immunosuppressive) treatment. Saint James University Hospital classification is based on radiologic anatomy on MR imaging that describes fistulous tracts under five grades, including both primary tract and secondary extensions or side-branches and associated abscesses.<sup>4</sup> Such imaging may allow accurate prediction of clinical outcome than information obtained at the time of surgery.

Although many studies have addressed the complications and management of CD,<sup>4,5,7</sup> few have focused on its initial presentation as perianal fistula or explained the role of MR imaging in documenting specific features that may help to foresee CD in such patients. Therefore, we present the features of perianal fistulas as seen on MR imaging during initial presentation in undiagnosed patients, and correlate those features with subsequent diagnoses of CD.

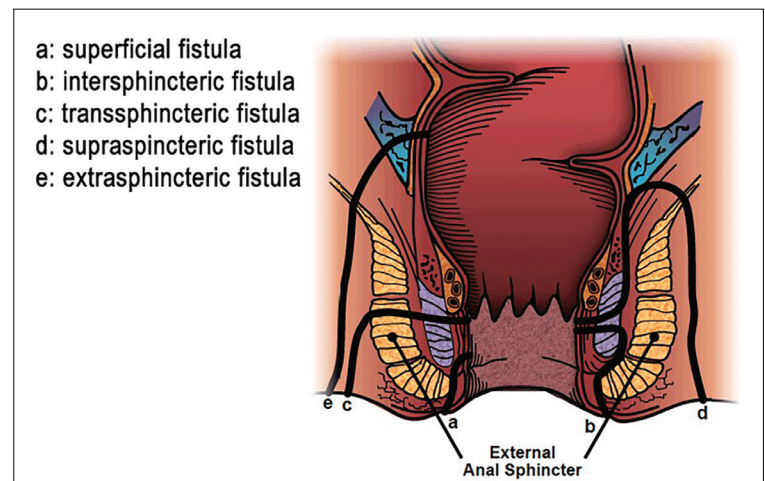
## PATIENTS AND METHODS

This retrospective observational study was conducted in the radiology department, King Fahd Military

Medical Complex in Dhahran from September 2015 to September 2018. All previously undiagnosed and untreated patients who presented for the first time with perianal fistulas to outpatient clinics were evaluated for presence, type, location and grade of perianal fistulas on MR imaging studies. Patients already diagnosed with Crohn's disease, post-surgical or intervention cases, and those with a contraindication to MR imaging were excluded.

As the study was retrospective and did not involve disclosure of any patient information and privacy, the ethics committee waived the need for patient consent. The study was conducted in accordance with the Helsinki Declaration. All clinical and radiologic information were kept strictly confidential. A literature review was performed by an electronic search (Google Scholar, PubMed). Demographic information was collected. Clinical information and MR imaging findings were acquired through patients' clinical notes and the hospital information system and radiology information system/picture archiving and communication system. Information on clinical presentation and follow up were recorded from the clinical notes on the system.

All MR imaging studies were performed on a 1.5 Tesla scanner (General Electric/ GE, Optima 450 W GEM, 2013, Florence, South Carolina, USA), using gadolinium-based contrast agent (Dotarem, 0.1 mmol/kg; Guerbet, France). Imaging included sagittal (SAG) T2-weighted (T2W) high resolution (HR) sequence (4mm slice thickness, 1mm spacing), SAG T2 3D CUBE (1.6mm thickness), axial (Ax) T2 Fat Sat oblique (OBL) sequence (4mm slice thickness, 1mm spacing), Ax T2 HR OBL (4mm slice thickness, 1 mm spacing), Ax Diffusion



**Figure 1.** Locations and types of perianal fistulas. Source: Image courtesy of American Society of Colon and Rectal Surgery (ASCRS).

Weighted (DW) sequence (if needed, in case of suspicion of collection or abscess), coronal (COR) T2 Fat Sat OBL (4mm slice thickness, 1mm spacing), pre-contrast Ax LAVA (Liver Acquisition with Volume Acceleration) T1 OBL Fat Sat in-phase and out-phase sequences (3-mm thickness, 0-mm spacing), post-contrast Ax T1 Fat Sat LAVA OBL (3-mm thickness, 0-mm spacing), and COR T1 Fat Sat LAVA OBL (3-mm thickness, 0-mm spacing) sequences. Oblique images were acquired perpendicular to long axis of anal canal.

An abnormal perianal T2 hyperintense enhancing tract with internal (anal) and external (skin) openings was defined as a fistula on MR imaging. Diffusion restriction was considered to identify any suspected collection. Fistulas were categorized as low (superficial) or high anal (extra-sphincteric and supra-sphincteric), simple (linear, non-branching, low anal, single opening, no associated abscess) or as complex (high anal, associated branch, sinus or abscess, multiple external openings, associated rectovaginal fistula, or active rectal disease) and their grading as per St. James University Hospital Classification.<sup>4</sup> Extrasphincteric fistulas were labelled when these penetrated the levator muscle, while supra-sphincteric fistulas were labelled when these travelled through the internal and external sphincters over the puborectalis muscle (**Figure 2**).

Imaging was interpreted by two experienced general radiologists (each having more than 7 years of experience) based on the Van Assche score,<sup>10</sup> and final imaging diagnoses were made by consensus reporting. The final diagnosis of CD was confirmed on clinical, endoscopic (histopathologic e.g., terminal ileal biopsy), serology (Anti-Saccharomyces cerevisiae antibodies, perinuclear antineutrophil cytoplasmic, fecal calprotectin, and C-reactive protein). Patients were diagnosed within 1-2 months of initial referral to MR imaging. The statistical analysis was carried out using IBM SPSS version 22 for

Windows (Armonk, NY, USA). The chi-square test was used to determine association, and *P* values less than .05 were considered statistically significant.

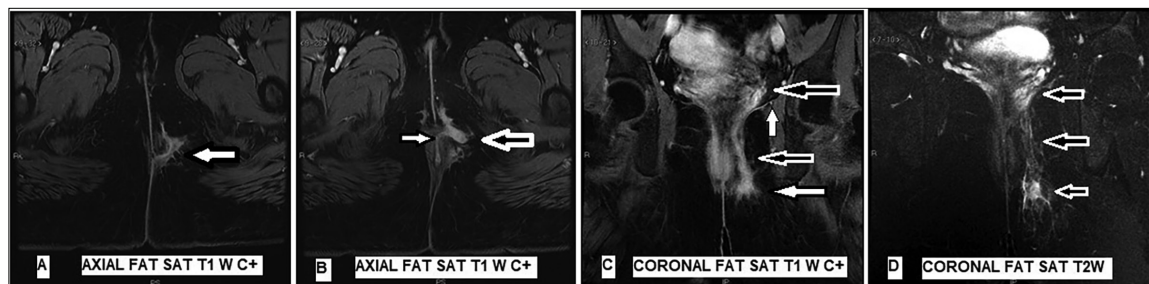
## RESULTS

Of 171 patients, the majority were males (81.3%) with a mean (SD) age of 37.2 (12.7) years (range: 5-73 years). The mean (SD) age of the 31 females was 35.8 (10.6) years. Twenty-one patients (12.3%) had Crohn's disease (**Figure 3**). Two of 26 fistula negative patients and 19 of 124 fistula positive patients had CD. Fourteen (14 of 40, 40.4%) patients with complex fistulas had CD in comparison to only 4.8% (5 of 104) of simple fistula patients ( $P=.0005$ ). More than half of patients with high anal fistulas (6 of 11, 54.5%) had CD ( $P=.0005$ ). Six of 27 grade-II fistula patients and 5 of 21 grade-IV fistula patients had CD. Females more often had CD ( $P=.0005$ ) (**Table 1**).

## DISCUSSION

Perianal disease can be debilitating if caused by a serious condition like Crohn's disease (CD). Patients with CD often manifest initially as perianal disease.<sup>11</sup> Studies have shown that perianal fistulas develop in approximately 13% to 27% of CD patients. About 20% of perianal fistulas manifest before CD diagnosis.<sup>4,7</sup> Georgiadou et al found a 3.4% prevalence of perianal fistula in CD.<sup>12</sup> Twelve percent of patients presenting for MR fistula imaging had a diagnosis of Crohn's disease in our study. However, it should be noted that not every patient with perianal disease chooses to undergo MR imaging. Some may have a contraindication to imaging or contrast and some are claustrophobic, thereby limiting the actual population for MR imaging. Therefore, the results of our study may not represent a true estimate of the actual population that could have been affected by CD in their clinical course.

The presence of perianal fistulas as an initial



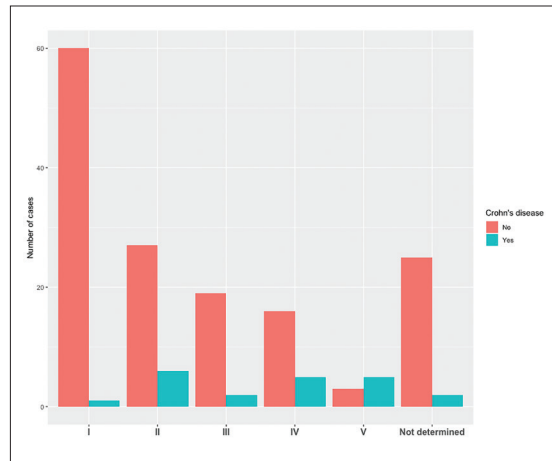
**Figure 2.** Axial (A and B) and coronal (C and D) images of a 24 year old patient (who later on found to have CD) show an enhancing (A, B and C) complex branching (image B) trans-sphincteric fistula with skin opening at 5 o'clock (image A), coursing anteriorly and superiorly to reach above levator ani sling (vertical arrow in image C depicting levator ani muscle, horizontal arrows in image C showing tract course) demonstrating a high-anal opening. The fistulous tract is seen as a T2-hyperintense (related to inflammation and edema) structure (image D). Fat Sat (fat saturation), C+ (contrast enhanced).

**Table 1.** Demographic, clinical and MR imaging characteristics (N=171).

	Crohn's disease diagnosis	
	Yes (n=21, 12.3%)	No (n=150, 87.8%)
<b>Sex</b>		
Male	10 (7.2)	129 (92.8)
Female	11 (35.5)	21 (67.7)
<b>Diagnosis by MRI findings</b>		
Negative	2 (7.1)	26 (92.9)
Positive	19 (13.3)	124 (86.7)
<b>Fistula type</b>		
High anal	6 (54.5)	5 (45.5)
Low anal	13 (9.8)	120 (90.2)
Not determined	2 (7.4)	25 (92.6)
Complex	14 (40.4)	26 (59.6)
Simple	5 (5.8)	99 (94.2)
Not determined	2 (7.4)	25 (92.6)
<b>Fistula grade</b>		
I	1 (1.6)	60 (98.4)
II	6 (18.2)	27 (81.8)
III	2 (9.5)	19 (90.5)
IV	5 (62.5)	16 (76.2)
V	5 (62.5)	3 (37.5)
Not determined	2 (7.4)	25 (92.6)

Data are number (%). Females vs males ( $P=.0005$ ). High anal vs low anal by CD diagnosis ( $P=.0005$ ). Complex vs simple by CD diagnosis ( $P=.0005$ ).

presentation appears to be a risk factor for disabling CD (chronic relapsing, refractory to medicines, requiring immunosuppressive therapy, hospitalizations, surgical interventions).<sup>5</sup> Colorectal disease is a well-known risk factor for development of perianal fistulas.<sup>7</sup> Studies have estimated that only 15% of ileocolonic CD patients have perianal fistulas compared to 41% with colonic involvement and 92% with rectal involvement.<sup>4</sup> Perianal disease usually occurs simultaneously with luminal disease but may precede it. We found 61% of patients (13 of 21) with ileocolonic disease and the remainder had either isolated rectal or colonic disease. Two of our fistula negative patients had sinus tracts on initial MR imaging, but later developed fistulas on follow-up imaging after 6 months, developing low-grade fistulas with isolated rectal disease.

**Figure 3.** Distribution of cases by St. James University Hospital Classification by confirmed diagnosis of Crohn's disease.

Imaging is crucial to assess fistula anatomy and extent, to rule out complications, plan treatment, and monitor therapeutic response.<sup>13</sup> Maconi and colleagues reviewed 12 studies (565 patients) for detection of perianal fistulas by transperineal ultrasound (TPUS), and found a high yield with a sensitivity of 86%.<sup>14</sup> Lee and colleagues also found a higher accuracy of combined TPUS with MR imaging versus colonoscopy and MR imaging in children.<sup>15</sup> Molteni et al recently found no statistically significant difference in relation to the number of fistulous trajectories detected on endoscopic ultrasonography, MR imaging and examination under anesthesia in the management of patients with perianal fistulizing Crohn's disease.<sup>16</sup> AlSabban et al noted a high sensitivity with MR enterography in detection of perianal disease in pediatric patients.<sup>17</sup> Pelvic MR imaging is currently the standard for imaging perianal CD.<sup>4</sup> More recently, Cattapan et al found that although contrast-enhanced MR studies could improve radiologist's confidence, non-contrast MR studies had similar diagnostic efficacy in identifying perianal fistulas and their complications.<sup>18</sup> However, adaptation of certain sequences in MR imaging may also improve diagnostic capability for fistula delineation. Wang et al evaluated the use of diffusion-weighted imaging (DWI) for evaluation of perianal fistulas in 55 CD patients, and found changes in the apparent diffusion coefficient that correlated well with fistula activity in diseased patients.<sup>19</sup> Also, DWI might be a good option for patients who have a contraindication to contrast. We did not use DWI for all patients, reserving it for cases having a suspicion of associated abscess. Feng et al found that T2-weighted and fat-suppressed T2-weighted imaging fusion technology improved image discriminability for the evaluation of anal fistulas.<sup>20</sup>

Classification of perianal fistulas is important in planning an optimal management strategy.<sup>7</sup> Garg compared the efficacy of the Parks, the St James Hospital University and the Standard Practice Task Force classifications in 198 fistula patients.<sup>21</sup> He found none of the classifications to be accurate in defining grade and complexity of the fistula, and stressed the need for a new classification of simple (grades I and II) and highly complex fistulas (grades III-V) for defining the surgical benefit of fistulotomy, which should only be attempted for simple fistulas.<sup>21</sup> Our study did not compare different classifications; however, we feel that future large-scale multicenter studies involving diagnostic strategy and clinical approach with outcome are needed to validate such findings.

In our study, females were more commonly affected, having grades IV/V, who later developed CD. Mocanu et al found in their meta-analysis that one-fifth of affected perianal fistula patients were females, and of a younger age group (mean age 30 years), while reviewing six studies comprising 817 patients.<sup>22</sup> A slightly higher female predisposition (1.18) was also observed by Sahnun et al in reviewing data from a larger population of patients who showed progression of perianal abscess to perianal fistula formation. They found female gender to be an independent predictor of fistula formation,<sup>23</sup> possibly due to greater complications associated with the adjacent vagina and the risks associated with child birth.<sup>24</sup> Xu et al observed that perianal fistulizing CD affected males more than females (3.3:1).<sup>5</sup> Chauhan and colleagues observed a male preponderance in a small sample-sized study conducted at a rural tertiary hospital in northern India.<sup>25</sup> They found middle-age patients to be the most commonly involved group and grade IV the commonest grade by St. James University Hospital Classification. Al-Mofarreh observed a young population affected by CD with a peak between 10-30 years, and a slight male preponderance in a study involving a cohort of 693 patients with inflammatory bowel disease in Riyadh.<sup>26</sup> These differences might be related to different study populations and characteristics, possibly due to local epidemiology, environmental, dietary or sociocultural factors.

We found a few pediatric patients (aged 14 years and below) that had subsequent diagnoses of CD in our study. Al-Bawardy also noted a rise in the incidence of inflammatory bowel disease among this age group in Saudi Arabia.<sup>27</sup> We strongly feel that this group of patients need special consideration in regard to imaging and clinical approach. Two positive pediatric patients (both males, aged 14 and 13 years) in our

study that were diagnosed with CD had ileocolonic disease and one of these had a fistulizing CD for which he underwent surgery. Pediatric CD may have more complicated behavior than the adult form.<sup>28</sup> Herman et al evaluated medical records of 296 pediatric CD patients with perianal disease, and found a 13% incidence proportion of fistulizing perianal CD and 24% of patients with non-fistulizing disease at the time of diagnosis.<sup>29</sup> Maccioni et al found a significantly higher prevalence of rectal involvement and perianal disease in the pediatric population.<sup>30</sup> Also, they noted a higher prevalence of perianal disease in children than in adults (34.6% versus 16.1%) on MR images out of 219 cases. Therefore, timing of surgery in pediatric CD patients should be determined with an individualized approach by an experienced and well organized multidisciplinary inflammatory bowel disease team.<sup>31</sup>

Although we did not focus on the reporting aspect of the MR imaging in our study, we strongly feel that a structured and elaborate reporting by the radiologist is key for decision making, guiding clinicians towards a directed management. Ho et al emphasized the need for a structured MR imaging reporting template and diagrammatic worksheet for perianal sepsis through collaboration between radiologists and colorectal surgeons that helped in optimizing communication of key imaging findings having an impact on patient management, reporting time, and comparison between studies.<sup>32</sup> Tuncyurek et al found that structured MR imaging reports in patients with perianal fistulizing disease did not only miss fewer key features than narrative reports, but was also helpful for treatment planning.<sup>33</sup> Wildman-Tobriner et al also highlighted the importance of structured reporting in describing pediatric Crohn's disease, and mentioned a subjective preference for such reports by clinicians.<sup>34</sup> We therefore suggest that radiologists should not only be familiar with 'what to report', but also to 'how to report'.

Limitations in our study were that it involved a single center with a small sample, and was retrospective, not including already diagnosed or managed CD patients. Study results also might not represent true estimates of occurrence of CD, as many patients could not be included for MR imaging (e.g., claustrophobic patients and those with a contraindication to MR imaging). Larger scale randomized studies are needed to compare different imaging options in both pediatric and adult perianal disease patients. Awareness and suspicion of CD in complex fistulas, a low threshold for assessment of CD, and expertise in its management need to be emphasized among both the primary care facilities and concerned departments. Newer imaging

options need to be addressed, and improved reporting needs to be adopted. More recently, the application of diffusion tensor imaging by Wang et al had promising results.<sup>35</sup> Sahnun et al presented the feasibility of 3D reconstructions for complex perianal fistulas and incorporated these in the reports, which has the potential to improve surgical planning, communication with patients, and augment training.<sup>36</sup> Use of these newer methods and techniques will surely be of interest in future studies to highlight the further usefulness of MR imaging.

**Authors' contributions**

*Dr. KBW - Conception and design, actual write-up of manuscript*

*Dr. WSJ - Patient selection, Critical revision*

*Dr. BA - Patient selection, data interpretation*

*Dr. MA - Patient selection, critical appraisal of findings*

*Dr. FH - Patient selection, critical appraisal of findings*

*Dr. SW - Data interpretation, critical review*

*Dr. MZH - Data interpretation, critical review*

*Dr. ZMA - Data collection and drafting of article*

*SNR - Drafting of article*

*ZJA - Data management and statistical analysis*

## REFERENCES

- Jhaveri KS, Thippavong S, Guo L, Harisinghani MG. MR Imaging of Perianal Fistulas. *Radiol Clin North Am*. 2018 Sep;56(5):775–89.
- Al-Mofleh IA, Azzam NA. Crohn's disease. Increasing trend in Saudi Arabia. *Saudi Med J*. 2013 Nov;34(11):1105–13.
- Fadda MA, Peedikayil MC, Kagevi I, Kahtani KA, Ben AA, Al HI, et al. Inflammatory bowel disease in Saudi Arabia: a hospital-based clinical study of 312 patients. *Ann Saudi Med*. 2012 May-Jun;32(3):276–82.
- Sheedy SP, Bruining DH, Dozois EJ, Faubion WA, Fletcher JG. MR Imaging of Perianal Crohn Disease. *Radiology*. 2017 Mar;282(3):628–45.
- Xu MM, Zhu P, Wang H, Yang BL, Chen HJ, Zeng L. Analysis of the clinical characteristics of perianal fistulising crohn's disease in a single center. *Arq Bras Cir Dig*. 2019 Feb;32(1):e1420.
- Schäfer AO. [Perianal inflammatory diseases: classification and imaging]. *Radiologe*. 2018 Apr;58(4):344–54.
- Aguilera-Castro L, Ferre-Aracil C, Garcia-Garcia-de-Paredes A, Rodriguez-de-Santiago E, Lopez-Sanroman A. Management of complex perianal Crohn's disease. *Ann Gastroenterol*. 2017;30(1):33–44.
- Bhatt S, Jain BK, Singh VK. Multi Detector Computed Tomography Fistulography In Patients of Fistula-in-Ano: An Imaging Collage. *Pol J Radiol*. 2017 Sep;82:516–23.
- Roth CG, Marzio DH, Guglielmo FF. Contributions of Magnetic Resonance Imaging to Gastroenterological Practice: MRIs for GIs. *Dig Dis Sci*. 2018 May;63(5):1102–22.
- Samaan MA, Puylaert CA, Levesque BG, Zou GY, Stitt L, Taylor SA, et al. The development of a magnetic resonance imaging index for fistulising Crohn's disease. *Aliment Pharmacol Ther*. 2017 Sep;46(5):516–28.
- Balci S, Onur MR, Karaosmanoğlu AD, Karçaaltıncaba M, Akata D, Konan A, et al. MRI evaluation of anal and perianal diseases. *Diagn Interv Radiol*. 2019 Jan;25(1):21–7.
- Georgiadou E, Fanter L, Brandes A, Ratsch BA, Friedel H, Dignass A. Perianal fistulas in adult patients with Crohn's disease in Germany - a retrospective cross-sectional analysis of claims data from German sickness funds. *Z Gastroenterol*. 2019 Mar 14.
- Konan A, Onur MR, Özmen MN. The contribution of preoperative MRI to the surgical management of anal fistulas. *Diagn Interv Radiol*. 2018 Nov;24(6):321–7.
- Maconi G, Greco MT, Asthana AK. Transperineal Ultrasound for Perianal Fistulas and Abscesses - A Systematic Review and Meta-Analysis. *Ultraschall Med*. 2017 Jun;38(3):265–72.
- Lee EH, Yang HR, Kim JY. Comparison of Transperianal Ultrasound with Colonoscopy and Magnetic Resonance Imaging in Perianal Crohn Disease. *J Pediatr Gastroenterol Nutr*. 2018 Apr;66(4):614–9.
- Molteni RA, Bonin EA, Baldin Júnior A, Barreto RA, Brenner AS, Lopes TL, et al. Usefulness of endoscopic ultrasound for perianal fistula in Crohn's disease. *Rev Col Bras Cir*. 2019 Jan;45(6):e1840.
- AlSabban Z, Carman N, Moineddin R, Lo RT, King SK, Langer JC, et al. Can MR enterography screen for perianal disease in pediatric inflammatory bowel disease? *J Magn Reson Imaging*. 2018 Jun;47(6):1638–45.
- Cattapan K, Chulroek T, Kordbacheh H, Wacharoenrung D, Harisinghani M. Contrast- vs. non-contrast enhanced MR data sets for characterization of perianal fistulas. *Abdom Radiol (NY)*. 2019 Feb;44(2):446–55.
- Wang S, Tang X, Wang Z, Wang H. [Value of magnetic resonance diffusion-weighted imaging for evaluating the inflammatory activity of perianal Crohn's fistula]. *Zhong Nan Da Xue Xue Bao Yi Xue Ban*. 2019 Feb;44(2):173–9.
- Feng ST, Huang M, Dong Z, Xu L, Li Y, Jia Y, et al. MRI T2-Weighted Imaging and Fat-Suppressed T2-Weighted Imaging Image Fusion Technology Improves Image Discriminability for the Evaluation of Anal Fistulas. *Korean J Radiol*. 2019 Mar;20(3):429–37.
- Garg P. Comparing existing classifications of fistula-in-ano in 440 operated patients: is it time for a new classification? A Retrospective Cohort Study. *Int J Surg*. 2017 Jun;42:34–40.
- Mocanu V, Dang JT, Ladak F, Tian C, Wang H, Birch DW, et al. Antibiotic use in prevention of anal fistulas following incision and drainage of anorectal abscesses: A systematic review and meta-analysis. *Am J Surg*. 2019 Jan 31. pii: S0002-9610(18)31292-3.
- Sahnun K, Askari A, Adegbola SO, Tozer PJ, Phillips RK, Hart A, et al. Natural history of anorectal sepsis. *Br J Surg*. 2017 Dec;104(13):1857–65.
- Kelley KA, Kaur T, Tsikitis VL. Perianal Crohn's disease: challenges and solutions. *Clin Exp Gastroenterol*. 2017 Feb;10:39–46.
- Chauhan NS, Sood D, Shukla A. Magnetic Resonance Imaging (MRI) Characterization of Perianal Fistulous Disease in a Rural Based Tertiary Hospital of North India. *Pol J Radiol*. 2016 Dec;81:611–7.
- Al-Mofarreh MA, Al-Mofleh IA. Emerging inflammatory bowel disease in Saudi outpatients: a report of 693 cases. *Saudi J Gastroenterol*. 2013 Jan-Feb;19(1):16–22.
- Al-Bawardy B. Inflammatory bowel disease: clinical screening and transition of care. *Saudi J Gastroenterol*. 2017 Jul-Aug;23(4):213–5.
- Kim S. Surgery in Pediatric Crohn's Disease: Indications, Timing and Post-Operative Management. *Pediatr Gastroenterol Hepatol Nutr*. 2017 Mar;20(1):14–21.
- Herman Y, Rinawi F, Rothschild B, Nir O, Shamir R, Assa A. The Characteristics and Long-term Outcomes of Pediatric Crohn's Disease Patients with Perianal Disease. *Inflamm Bowel Dis*. 2017 Sep;23(9):1659–65.
- Maccioni F, Bencardino D, Buonocore V, Mazzamuro F, Viola F, Oliva S, et al. MRI reveals different Crohn's disease phenotypes in children and adults. *Eur Radiol*. 2019 Feb 7.
- Marzo M, Felice C, Pugliese D, Andrisani G, Mocchi G, Armuzzi A, et al. Management of perianal fistulas in Crohn's disease: an up-to-date review. *World J Gastroenterol*. 2015 Feb;21(5):1394–403.
- Ho E, Rickard MJ, Suen M, Keshava A, Kwik C, Ong YY, et al. Perianal sepsis: surgical perspective and practical MRI reporting for radiologists. *Abdom Radiol (NY)*. 2019 Feb 15.
- Tuncyurek O, Garces-Descovich A, Jaramillo-Cardoso A, Durán EE, Cataldo TE, Poylin VY, et al. Structured versus narrative reporting of pelvic MRI in perianal fistulizing disease: impact on clarity, completeness, and surgical planning. *Abdom Radiol (NY)*. 2019 Mar;44(3):811–20.
- Wildman-Tobriner B, Allen BC, Davis JT, Miller CM, Schooler GR, McGreal NM, et al. Structured Reporting of Magnetic Resonance Enterography for Pediatric Crohn's Disease: Effect on Key Feature Reporting and Subjective Assessment of Disease by Referring Physicians. *Curr Probl Diagn Radiol*. 2017 Mar - Apr;46(2):110–4.
- Wang Y, Gu C, Huo Y, Han W, Yu J, Ding C, et al. Diffusion tensor imaging for evaluating perianal fistula: feasibility study. *Medicine (Baltimore)*. 2018 Jul;97(29):e11570.
- Sahnun K, Adegbola SO, Tozer PJ, Patel U, Ilangovan R, Warusavitarne J, et al. Innovation in the imaging perianal fistula: a step towards personalised medicine. *Therap Adv Gastroenterol*. 2018 May;11:1756284818775060.