

## Original Article



# Prevention of lymphocele by using gelatin-thrombin matrix as a tissue sealant after pelvic lymphadenectomy in patients with gynecologic cancers: a prospective randomized controlled study

## OPEN ACCESS

Received: Nov 12, 2016

Revised: Jan 22, 2017

Accepted: Feb 8, 2017

### Correspondence to

Yun Hwan Kim

Department of Obstetrics and Gynecology,  
Ewha Womans University School of Medicine,  
1071 Anyangcheon-ro, Yangcheon-gu, Seoul  
07985, Korea.  
E-mail: kimyhmd@ewha.ac.kr

Copyright © 2017. Asian Society of  
Gynecologic Oncology, Korean Society of  
Gynecologic Oncology  
This is an Open Access article distributed  
under the terms of the Creative Commons  
Attribution Non-Commercial License (<https://creativecommons.org/licenses/by-nc/4.0/>)  
which permits unrestricted non-commercial  
use, distribution, and reproduction in any  
medium, provided the original work is properly  
cited.

### ORCID

Yun Hwan Kim

<http://orcid.org/0000-0001-9498-2938>

Hyun Joo Shin

<http://orcid.org/0000-0002-5359-9251>

Woong Ju

<http://orcid.org/0000-0002-0013-8304>

Seung-Cheol Kim

<http://orcid.org/0000-0002-5000-9914>

### Funding

This work was supported by the Ewha  
Womans University Research Grant of 2013.  
The FloSeal material and limited funding were  
supplied by manufacturer, Baxter Ltd.

Yun Hwan Kim, Hyun Joo Shin, Woong Ju, Seung-Cheol Kim

Department of Obstetrics and Gynecology, Ewha Womans University School of Medicine, Seoul, Korea

## ABSTRACT

**Objective:** This prospective randomized controlled pilot study aimed to find whether gelatin-thrombin matrix used as a tissue sealant (FloSeal) can prevent the occurrence of pelvic lymphocele in patients with gynecologic cancer who has undergone pelvic lymphadenectomy.

**Methods:** Each patient, who undergo a laparotomic pelvic lymph node dissection on both sides, was randomly assigned for FloSeal application on 1 side of the pelvis. The other side of the pelvis without any product application being the control side. The amount of lymph drainage at each side of the pelvis was measured for 3 days, and computed tomography scans were obtained 7 days and 6 months after surgery for detection of pelvic lymphocele.

**Results:** Among 37 cases, the median amount of lymph drainage was significantly decreased in the hemi-pelvis treated with FloSeal compared to the control hemi-pelvis ( $p=0.025$ ). The occurrence of lymphocele was considerably reduced in treated hemi-pelvis (8/37, 21.6%) compared with control hemi-pelvis (12/37, 32.4%) after 7 post-operative days ( $p=0.219$ ), and more decreased in the treated hemi-pelvis (5/37, 13.5%) compared with control hemi-pelvis (9/37, 24.3%) after postoperative 6 months ( $p=0.344$ ).

**Conclusion:** The application of FloSeal as a tissue sealant in lymph nodes resected tissues can reduce the incidence of pelvic lymphocele in gynecologic cancer patients. A large randomized controlled study could confirm these preliminary results.

**Keywords:** Genital Neoplasms, Female; Lymphocele; Drainage; Secondary Prevention; Lymph Node Excision; Surgical Oncology

## INTRODUCTION

Pelvic lymphadenectomy is an inevitable procedure to define surgical staging as well as to treat nodal metastasis in various pelvic malignancies including gynecologic cancers. Although the tremendous improvements in the area of preoperative imaging and sentinel

**Conflict of Interest**

No potential conflict of interest relevant to this article was reported.

**Author Contributions**

Conceptualization: K.Y.H.; Data curation: K.Y.H., S.E.J., J.W., K.S.C.; Formal analysis: K.Y.H.; Funding acquisition: K.Y.H.; Investigation: K.Y.H., J.W., K.S.C.; Methodology: K.Y.H., J.W.; Project administration: K.Y.H.; Resources: K.Y.H.; Software: K.Y.H.; Supervision: K.Y.H., J.W., K.S.C.; Validation: K.Y.H.; Visualization: K.Y.H.; Writing - original draft: K.Y.H., S.E.J.; Writing - review & editing: K.Y.H., J.W., K.S.C.

lymph node mapping [1,2], pelvic lymph node dissection (PLND) followed by pathologic confirmation is still the most reliable method to determine nodal metastasis.

Lymphocele or lymphocyst is a cyst-like structure made by lymph accumulation at the site of node removal as a consequence of the surgical dissection and the inadequate closure of afferent lymphatic vessels. The incidence of lymphocele after PLND has been reported with wide range from 11% to 63% [3,4], because most lymphoceles are found incidentally in postoperative images and thereby frequently underdiagnosed. Most lymphoceles are asymptomatic, however sometimes enlarged lymphoceles can cause pelvic pain, leg edema, hydronephrosis, deep vein thrombosis, and infection. Symptomatic or complicated lymphoceles can delay adjuvant treatment including chemotherapy and radiation therapy, which potentially compromise the success of cancer treatment.

For these reasons, a number of surgical techniques and materials have been tried to reduce the development of postoperative lymphoceles after PLND. However, they showed unsatisfactory results [4-11]. Recently, a few investigators proposed to use the gelatin-thrombin matrix, FloSeal (Baxter AG, Vienna, Austria), as a tissue sealant and a preventive material against lymphocele after PLND [12,13]. Therefore, we performed a prospective randomized controlled pilot study to find whether FloSeal can prevent pelvic lymphocele in patients with gynecologic cancer who has undergone PLND.

## MATERIALS AND METHODS

This was a prospective, randomized, controlled, pilot study conducted between April 2014 and May 2016 at a single institution (registered at ClinicalTrials.gov: NCT01974193). The protocol was approved by the Institutional Review Board (ECT 13-41A-03), and gynecologic cancer patients were consecutively enrolled after receiving written informed consent. Inclusion criteria were as follows: patients 1) diagnosed with a gynecologic malignancy including cervical, uterine, and ovarian cancer, 2) indicated to perform a primary laparotomic surgery including PLND for diagnostic and therapeutic purpose. Exclusion criteria were as follows: patients 1) anticipated to experience incomplete PLND due to their medical conditions, 2) expected to survive less than 1 year.

FloSeal application was randomized to one side of the pelvis in each patient, to make an identical clinical environment and consequently to minimize the influence of confounding factors between each pelvis. Randomization took place by using a random number table according to the 3 cancer types; cervical, uterine, and ovarian cancer. The application side of the pelvis was informed to the operator after completion of the bilateral PLND with or without para-aortic lymph node dissection (PALND) to avoid surgeon's prejudice during lymph node dissection.

PLND was made by removing all lymph nodes and fatty tissues between the external and internal iliac arteries, from the bifurcation of the common iliac artery up to the circumflex vein and above the obturator nerve. PALND was performed by resection of all lymph nodes and fatty tissue surrounding the aorta, inferior vena cava, and renal vessels from the renal vein cranially to the midpoint of the common iliac vessels caudally, and extending laterally to the edge of the psoas major muscle. Vessel sealing devices using ultrasonic energy was usually applied during lymphadenectomy, however surgical clips were not used to close the lymphatics.

After completion of the lymphadenectomy and after the randomization, an average of 5 mL of FloSeal was applied to the randomized side (right or left) of pelvis followed by gentle compression using wet gauze for at least 2 minutes. Three major risk sites including femoral canal, obturator fossa, and bifurcation of common iliac vessels were carefully coated [9], while the entire area of lymphadenectomy was covered with a thin layer of FloSeal. If PALND was performed simultaneously, another 5 mL of FloSeal material was applied to the same ipsilateral side of the aorta. The peritoneum was left open and a drain was placed through the abdominal wall into each para-vesical space of the pelvis.

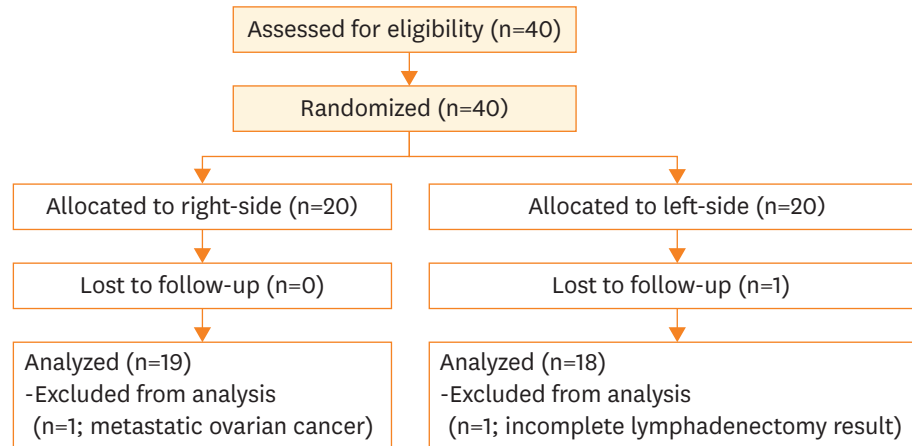
The volume of drainage was measured for 3 days, and the drain was removed if there was no sign of active bleeding. Computed tomography (CT) scans were obtained 7 days and 6 months after the surgery, and evaluated by the radiologists who was unaware of the treated part. CT findings of a smooth and thin-walled cavity filled with a water-equivalent fluid, sharply demarcated from its surroundings and without signs of infiltration, were interpreted as lymphocele [3]. Symptomatic lymphocele was defined when enlarged lymphoceles caused pelvic pain, leg edema, hydronephrosis, deep vein thrombosis, or infection.

The sample size was calculated based on the previous studies by using PASS 2008 software (NCSS Inc., Kaysville, UT, USA) [6,9,14]. Assuming that the overall incidence of lymphocele is about 30% after pelvic lymphadenectomy [6,14], the minimum sample size was 40 hemipelvis for each arm of the study to prove the 30% reduction of the incidence with  $\alpha=0.05$  and  $\beta=0.02$  [9]. Statistical analyses were performed using SPSS 17.0 for Windows (SPSS Inc., Chicago, IL, USA). The median values between the assigned groups were compared using the Mann-Whitney U test, and frequency data using  $\chi^2$  test. To compare the outcome parameters, paired statistics were used between the 2 hemi-pelvis of each patient: Wilcoxon signed-rank test and McNemar test were applied to compare the median amount of lymph drainage and the frequency of lymphocele, respectively.

## RESULTS

A total of 40 patients were screened for eligibility, and were randomly assigned to receive FloSeal application either on the right-side of the pelvis ( $n=20$ ) or on the left-side of the pelvis ( $n=20$ ). The flow of participating patients was presented in the Consolidated Standards of Reporting Trials (CONSORT) diagram (**Fig. 1**). Only 1 participant was lost during the follow-up period. Two patients were excluded during analysis; 1 patient was found to have a metastatic ovarian cancer at the final pathologic report, and the other patient was suspected to receive incomplete lymphadenectomy resulting in unequal surgical quality between the right and the left pelvis. Therefore, in total data from 37 participants were finally analyzed (right-side group,  $n=19$ ; left-side group,  $n=18$ ).

The characteristics of patient population were described and compared between the 2 groups in **Table 1**. The median age of gynecologic cancer patients was 52 (range from 27 to 70) years. Cervical, endometrial, and ovarian cancer were reported for 10/37 (27.0%), 12/37 (32.4%), and 15/37 (40.5%), respectively. The rate of adjuvant pelvic irradiation was 9/37 (24.3%), in only cervical or endometrial cancer patients. Simultaneous PALND was performed in 35/37 (94.6%) patients. Median number of resected lymph nodes was 39 (12–70) in pelvis, and 12 (1–45) in para-aortic area. There was no statistically significant difference between right-side and left-side group in median age, distribution of tumor type,



**Fig. 1.** Flow chart of participating patients presented by the Consolidated Standards of Reporting Trials diagram.

rate of pelvic irradiation, number of resected pelvic and para-aortic lymph node, and median blood loss ( $p > 0.05$ ).

Outcome parameters of the trial were presented in **Table 2**. The median amount of lymph drainage measured at postoperative day 3 was significantly reduced in the treated hemi-pelvis compared with the control hemi-pelvis; 400 (88–1,320) mL vs. 620 (102–1,390) mL, respectively ( $p = 0.025$ ). The frequency of immediate lymphocele observed in postoperative 7-days CT scan was lower in study hemi-pelvis (8/37, 21.6%) compared to control hemi-pelvis (12/37, 32.4%), although it was failed to show statistical significance ( $p = 0.219$ ). The frequency of lymphocele at postoperative 6 months was decreased as much as 30% compared with postoperative 7-days CT scan. There was no new development of lymphocele at the time of postoperative 6 months compared with postoperative 7-days. The frequency was lower in study hemi-pelvis (5/37, 13.5%) than control hemi-pelvis (9/37, 24.3%), however the

**Table 1.** Patients characteristics between the 2 groups according to the site of FloSeal application (n=37)

Characteristics	Right side (n=19)	Left side (n=18)	p-value
Age	52 (34–70)	52 (27–67)	0.915*
Type of tumor			0.980†
Cervical cancer	5 (26.3)	5 (27.8)	
Endometrial cancer	6 (31.6)	6 (33.3)	
Ovarian cancer	8 (42.1)	7 (38.9)	
Adjuvant irradiation	4 (21.1)	5 (27.8)	0.634†
Concurrent PALN dissection	19 (100.0)	16 (88.9)	0.230†
No. of PLN	19 (6–35)	19 (5–42)	0.456*
No. of PALN	6 (1–20)	6 (1–25)	0.336*
Blood loss (mL)	700 (50–4,000)	500 (150–1,600)	0.461*

Values are presented as median (range) or number (%).

PALN, para-aortic lymph node; PLN, pelvic lymph node.

\*Mann-Whitney U test; †Chi-square test.

**Table 2.** Total amount of 3-day pelvic lymph drainage and incidence of lymphocele at each hemi-pelvis at 7 days and 6 months postoperative

Characteristics	Control hemi-pelvis (n=37)	Study hemi-pelvis (n=37)	p-value
Amount of lymph drainage, mL	620 (102–1,390)	400 (88–1,320)	0.025*
Lymphocele at post-operative			
1 wk	12 (32.4)	8 (21.6)	0.219†
6 mo	9 (24.3)	5 (13.5)	0.344†

Values are presented as median (range) or number (%).

\*Wilcoxon signed-rank test; †McNemar test.

**Table 3.** Distribution and size of pelvic lymphocele at 6 months after operation

Location	Control hemi-pelvis (n=37)	Study hemi-pelvis (n=37)
External iliac	9 (2; 1-4)	4 (2; 1.0-2.5)
Internal iliac	0	0
Common iliac	0	1 (4; 4-4)

Values are presented as number (median diameter; range, cm).

difference between groups was not significant ( $p=0.344$ ). Among 14 cases of lymphocele, 13 (92.9%) cases were developed at the area of external iliac artery, and 1 case was at the area of common iliac artery without any complications. The distribution of lymphocele at 6 months after operation was presented with size in **Table 3**.

Among the 37 study participants, only 1 (2.7%) symptomatic lymphocele was developed in control hemi-pelvis of 1 cervical cancer patient after postoperative 1 week. The infected lymphocele was as large as 8 cm in diameter, and caused symptoms such as fever and pelvic pain. This symptomatic lymphocele was successfully treated with percutaneous drainage and intravenous antibiotics. However, the adjuvant chemoradiation was delayed up to 6 weeks after the operation.

Lastly, there was no adverse effect related to FloSeal usage in all participants during the study period.

## DISCUSSION

In our prospective randomized pilot study, we found that the application of FloSeal in the resected area after pelvic node dissection reduced the amount of lymphatic drainage significantly, and thereby decreased the occurrence of pelvic lymphocele in patients with gynecologic cancer who had undergone PLND with or without PALND. However, the lymphocele incidence was not significantly reduced either after 7 days or 6 months follow up.

Up to this moment, numerous surgical techniques and materials have been developed to reduce the occurrence of pelvic lymphoceles after PLND. For example, peritoneum left open, early removal of drain catheter, omentoplasty to facilitate pelvic lymphatic drainage, vaginal stump left open inside the retroperitoneal space, clipping of lymphatic end, ligation of lymphatics by using ultrasonic devices, applying fibrin glue, and attaching collagen-fibrin patch on lymphadenectomy site, and so forth. However, there has been no remarkable method to prevent pelvic lymphocele (summarized in **Table 4**).

The possibility of FloSeal as a preventive agent against pelvic lymphocele was firstly proposed in urologic surgery [12]. In matched-comparison analysis of total 142 patients who underwent laparoscopic or robot-assisted extraperitoneal radical prostatectomy, the incidence of symptomatic pelvic lymphocele was only 3.1% in the FloSeal group compared with 14.5% in the control group. However, the median number of resected pelvic lymph node was small (median 7 to 8) in both groups, and the surveillance of pelvic lymphocele was limited at the time of drain removal and post-operative 4 weeks by ultrasonography until the development of symptomatic lymphocyst. Another study also reported the potential of FloSeal to decrease the rate of symptomatic lymphoceles in patients with gynecologic malignancies [13]. They applied FloSeal and CoSeal (Baxter AG) after laparoscopic transperitoneal PLND with or without PALND. In a matched case-control analysis with 50

## Prevention of lymphocele after pelvic lymphadenectomy

**Table 4.** Preventive methods against lymphocele after pelvic lymphadenectomy in gynecologic malignancies

Preventive methods	Study design	No. of patients	Lymphocele	Symptomatic lymphocele
Peritoneum no-closure [5]	RCT	31 closure vs. 30 no-closure	16/31 (51.6) vs. 7/30 (23.3); p<0.050	11/31 (35.5) vs. 4/30 (13.3); p<0.100
No drain [6]	RCT	68 drain vs. 69 no-drain	NA	16/68 (23.5) vs. 9/69 (13.0); p=0.007
Omentoplasty [4]	Pilot study	10 none vs. 12 omentoplasty	0/10 (0.0) vs. 0/12 (0.0)	0/10 (0.0) vs. 0/12 (0.0)
Vaginal stump open [7]	Retrospective	79 closure vs. 101 stump open	12/79 (15.2) vs. 6/101 (5.9); p<0.050	NA
Ultrasonic shear [8]	Prospective	100 cases	0/100 (0.0)	NA
Surgical clip [9]	RCT	30 bipolar energy vs. 30 clipping	9/30 (30.0) vs. 1/30 (3.3); p=0.006	2/30 (6.6) vs. 0/30 (0.0); p=0.240
Fibrin glue [10]	RCT	46 none vs. 47 fibrin glue	21/46 (46.0) vs. 20/47 (43.0); p=0.763	4/46 (8.7) vs. 3/47 (6.4); p=0.901
Collagen-fibrin patch [11]	RCT (pilot)	28 none vs. 30 collagen-fibrin patch	16/28 (57.1) vs. 7/30 (23.3); p=0.015	9/28 (32.1) vs. 3/30 (10.0); p=0.053

Values are presented as number (%).

NA, not available; RCT, randomized controlled trial.

gynecologic cancer patients, the incidence of symptomatic lymphocele was as low as 11% in the FloSeal and CoSeal group compared with 18% in the control group. It had the advantage to follow the development of lymphocele closely (1 and 4 weeks after surgery and then every 3 months during the first year), however it was limited to discriminate the effect of FloSeal for the prevention of lymphocele because of its use in combination with CoSeal.

The present study is the first prospective randomized study that evaluate the efficacy of FloSeal for the prevention of lymphocyst after PLND, and the findings of the present study agreed with those of the previous retrospective investigations. That is, the incidence of lymphocele after 6 months postoperative was substantially reduced from 24.3% in the control side to 13.5% in the FloSeal treated side, although it was statistically not significant.

The advantage of the present study was that a number of risk factors for the occurrence of lymphocele such as disease entities, the number of resected lymph nodes, postoperative radiotherapy, and the presence of drainage [6,10], were successfully controlled by using the contralateral pelvis of the same patient as a control site. Another advantage of the present study was that it included only laparotomic cases which strictly complied with the protocol. To confirm the efficacy of FloSeal for the prevention of lymphocyst, it was highly stressed to coat and compress FloSeal materials properly to the convex and concave surface of the pelvic wall based on the hypothesized mechanisms. The mechanism of gelatin-thrombin matrix, FloSeal, with fibrin clot formation with fibrin present from dissected tissues is not clear. However, it could be hypothesized that the cross-linked gelatin granules allow conformation to irregular wound geometries, thereby maintaining contiguous contact with the active site of lymphorrhoea in the pelvis. In addition, swelling of the gelatin granules could offer a local tamponade effect [12].

Limitations of this study include the small number of cases, a low occurrence of symptomatic lymphocele, and relatively short follow-up time. The preventive efficacy of FloSeal against the symptomatic lymphocele could not be calculated in our series, because the occurrence of symptomatic lymphocyst was very low that only 1 case occurred among 37 patients. However, it could be translated that the reduced occurrence of total lymphocele can result in the low occurrence of symptomatic lymphocysts. Another limitation is the relatively short follow up. However, 6-months follow-up could be sufficient and reasonable, because most of lymphoceles develop within the first post-operative year [15].

In conclusion, the present prospective randomized pilot study observed a significant reduction of lymphatic drainage and considerable decrease of lymphocyst formation after the application of FloSeal. FloSeal gelatin-matrix can be considered as a potential preventive

material for pelvic lymphocele formation, and a larger controlled randomized trials using FloSeal should be performed in the future.

## REFERENCES

1. Selman TJ, Mann C, Zamora J, Appleyard TL, Khan K. Diagnostic accuracy of tests for lymph node status in primary cervical cancer: a systematic review and meta-analysis. *CMAJ* 2008;178:855-62.  
[PUBMED](#) | [CROSSREF](#)
2. Selman TJ, Mann CH, Zamora J, Khan KS. A systematic review of tests for lymph node status in primary endometrial cancer. *BMC Womens Health* 2008;8:8.  
[PUBMED](#) | [CROSSREF](#)
3. Petru E, Tamussino K, Lahousen M, Winter R, Pickel H, Haas J. Pelvic and paraaortic lymphocysts after radical surgery because of cervical and ovarian cancer. *Am J Obstet Gynecol* 1989;161:937-41.  
[PUBMED](#) | [CROSSREF](#)
4. Logmans A, Kruyt RH, de Bruin HG, Cox PH, Pillay M, Trimbos JB. Lymphedema and lymphocysts following lymphadenectomy may be prevented by omentoplasty: a pilot study. *Gynecol Oncol* 1999;75:323-7.  
[PUBMED](#) | [CROSSREF](#)
5. Suzuki M, Ohwada M, Sato I. Pelvic lymphocysts following retroperitoneal lymphadenectomy: retroperitoneal partial "no-closure" for ovarian and endometrial cancers. *J Surg Oncol* 1998;68:149-52.  
[PUBMED](#) | [CROSSREF](#)
6. Benedetti-Panici P, Maneschi F, Cutillo G, D'Andrea G, di Palumbo VS, Conte M, et al. A randomized study comparing retroperitoneal drainage with no drainage after lymphadenectomy in gynecologic malignancies. *Gynecol Oncol* 1997;65:478-82.  
[PUBMED](#) | [CROSSREF](#)
7. Yamamoto R, Saitoh T, Kusaka T, Todo Y, Takeda M, Okamoto K, et al. Prevention of lymphocyst formation following systematic lymphadenectomy. *Jpn J Clin Oncol* 2000;30:397-400.  
[PUBMED](#) | [CROSSREF](#)
8. Nezhat F, Yadav J, Rahaman J, Gretz H 3rd, Gardner GJ, Cohen CJ. Laparoscopic lymphadenectomy for gynecologic malignancies using ultrasonically activated shears: analysis of first 100 cases. *Gynecol Oncol* 2005;97:813-9.  
[PUBMED](#) | [CROSSREF](#)
9. Gallotta V, Fanfani F, Rossitto C, Vizzielli G, Testa A, Scambia G, et al. A randomized study comparing the use of the Ligaclip with bipolar energy to prevent lymphocele during laparoscopic pelvic lymphadenectomy for gynecologic cancer. *Am J Obstet Gynecol* 2010;203:483.e1-6.  
[PUBMED](#) | [CROSSREF](#)
10. Scholz HS, Petru E, Benedicic C, Haas J, Tamussino K, Winter R. Fibrin application for preventing lymphocysts after retroperitoneal lymphadenectomy in patients with gynecologic malignancies. *Gynecol Oncol* 2002;84:43-6.  
[PUBMED](#) | [CROSSREF](#)
11. Tinelli A, Giorda G, Manca C, Pellegrino M, Prudenzano R, Guido M, et al. Prevention of lymphocele in female pelvic lymphadenectomy by a collagen patch coated with the human coagulation factors: a pilot study. *J Surg Oncol* 2012;105:835-40.  
[PUBMED](#) | [CROSSREF](#)
12. Waldert M, Remzi M, Klatte T, Klingler HC. FloSeal reduces the incidence of lymphoceles after lymphadenectomies in laparoscopic and robot-assisted extraperitoneal radical prostatectomy. *J Endourol* 2011;25:969-73.  
[PUBMED](#) | [CROSSREF](#)
13. Köhler C, Kyeyanwa S, Marnitz S, Tsunoda A, Vercelino F, Schneider A, et al. Prevention of lymphoceles using FloSeal and CoSeal after laparoscopic lymphadenectomy in patients with gynecologic malignancies. *J Minim Invasive Gynecol* 2015;22:451-5.  
[PUBMED](#) | [CROSSREF](#)
14. Achouri A, Huchon C, Bats AS, Bensaïd C, Nos C, Lécuru F. Postoperative lymphocysts after lymphadenectomy for gynaecological malignancies: preventive techniques and prospects. *Eur J Obstet Gynecol Reprod Biol* 2012;161:125-9.  
[PUBMED](#) | [CROSSREF](#)
15. Tam KF, Lam KW, Chan KK, Ngan HY. Natural history of pelvic lymphocysts as observed by ultrasonography after bilateral pelvic lymphadenectomy. *Ultrasound Obstet Gynecol* 2008;32:87-90.  
[PUBMED](#) | [CROSSREF](#)