

Contents lists available at [ScienceDirect](http://www.sciencedirect.com)

## International Journal of Surgery Case Reports

journal homepage: [www.casereports.com](http://www.casereports.com)

## A rare combination between familial multiple lipomatosis and extragastrointestinal stromal tumor

Elena Arabadzhieva<sup>a,\*</sup>, Atanas Yonkov<sup>a</sup>, Sasho Bonev<sup>a</sup>, Dimitar Bulanov<sup>a</sup>, Ivanka Taneva<sup>a</sup>, Vesela Ivanova<sup>b</sup>, Violeta Dimitrova<sup>a</sup><sup>a</sup> Department of General and Hepato-Pancreatic Surgery, University Hospital "Alexandrovska"—Sofia, Medical University—Sofia, 1 G.Sofiiski Str., 1431 Sofia, Bulgaria<sup>b</sup> Department of General and Clinical Pathology, Medical University—Sofia, 2 Zdrave Str., 1431 Sofia, Bulgaria

## ARTICLE INFO

## Article history:

Received 24 June 2015

Received in revised form 20 July 2015

Accepted 25 July 2015

Available online 31 July 2015

## Keywords:

Extragastrointestinal stromal tumor

Familial multiple lipomatosis

Radical resection

CD117

CD34

## ABSTRACT

**INTRODUCTION:** Gastrointestinal stromal tumors (GISTs) are the most common mesenchymal tumors of the gastrointestinal tract. Rarely, GISTs can be located in mesentery, retroperitoneal space, omentum or pancreas. In these cases, the neoplasm is defined as "extra-gastrointestinal stromal tumors" (EGISTs).

**PRESENTATION OF CASE:** We reported a case of a 63-year-old male patient diagnosed by computer tomography with large intraabdominal tumor with vague origin, postoperatively determined as an EGIST. The diagnosis was confirmed by immunohistochemical study. The patient had multiple, subcutaneous, painless lipomas localized in the arms, forearms, thighs, abdomen and thorax. Because of the family history and the clinical presentation the disease was determined as familial multiple lipomatosis (FML). We performed radical tumor resection with distal pancreatectomy and splenectomy, and abdominoplasty, removing redundant skin and underlying subcutaneous fat tissue with multiple lipomas.

**DISCUSSION:** FML is a rare hereditary benign disease. On the other hand, only few cases with familial GIST have been reported. In cases with extensive abdominal involvement, the primary origin of EGIST may be impossible to determine so the differential diagnosis is very difficult.

**CONCLUSION:** Although we could not prove correlation between the observed diseases, they are extremely rare and their combination is unusual which makes the presented case valuable and interesting.

© 2015 The Authors. Published by Elsevier Ltd. on behalf of Surgical Associates Ltd. This is an open access article under the CC BY-NC-ND license (<http://creativecommons.org/licenses/by-nc-nd/4.0/>).

## 1. Introduction

Although gastrointestinal stromal tumors (GISTs) are the most common mesenchymal tumors of the gastrointestinal tract, they comprise less than 1% of all gastrointestinal tumors [1]. GISTs are neoplasms arising from, or differentiating along, a line similar to the cells of Cajal [2]. GISTs most commonly occur in the stomach (60–70%), followed by the small intestine (20–30%), duodenum (4–5%), rectum (4–5%), colon (<2%) and esophagus (<1%) [1,3]. Rarely, GISTs can be located in mesentery, retroperitoneal space, omentum or pancreas [1,3,4]. These "extra-gastrointestinal stromal tumors" (EGISTs) do not display connection to the wall or the serosal surface of the stomach and the intestine [1–3].

Familial multiple lipomatosis (FML) is an extremely rare hereditary benign disease (0002%) [5]. In FML, lipomas are usually painless

[5]. Sometimes these fatty tumors are numerous and large and they have to be excised because patients cannot wear appropriate clothing or interfere with joint movement [5,6].

We present a case of a FML-affected patient diagnosed with large intraabdominal tumor with vague origin, postoperatively determined as an EGIST.

## 2. Presentation of case

A 63-year-old male was admitted with symptoms of intense fatigue, abdominal discomfort and nausea without vomiting, constipation, and fever up to 37.5 °C. Despite his long-term obesity (body weight about 160 kg), in recent months the patient had lost about 20 kg, but the circumference of the abdomen had been increasing. The patient reported that he had multiple widespread palpable nodules in his body but they were long standing and some of them appeared during his childhood. His mother, some of his cousins and his nephew had the same subcutaneous nodules.

The physical examination revealed a patient with obesity and presence of multiple, subcutaneous, mobile and painless lipomas varied in size and localized in the arms, forearms, thighs, abdomen and thorax. The abdomen was without palpable pain, but with

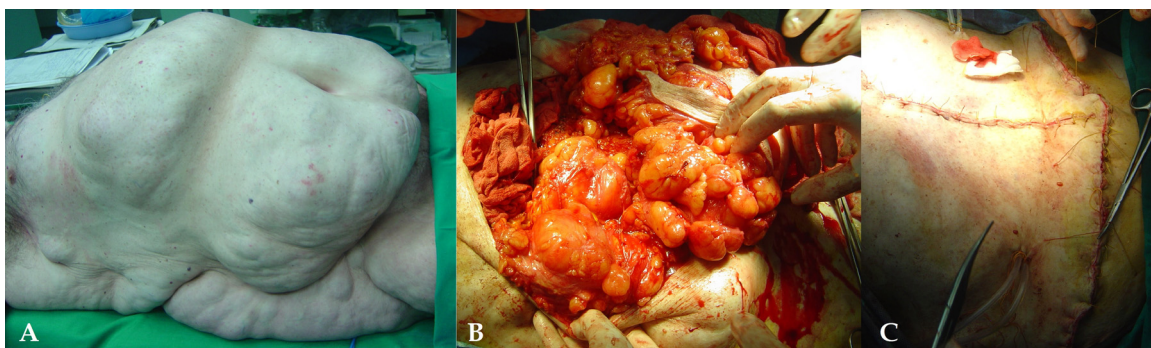
*Abbreviations:* GISTs, gastrointestinal stromal tumors; EGIST, extragastrointestinal stromal tumor; FML, familial multiple lipomatosis; CT, computer tomography; H&E, hematoxylin and eosin; NCCN, National Comprehensive Cancer Network.

\* Corresponding author. Fax: +359 29230307.

E-mail address: [elena.arabadjieva@abv.bg](mailto:elena.arabadjieva@abv.bg) (E. Arabadzhieva).

<http://dx.doi.org/10.1016/j.ijscr.2015.07.027>

2210-2612/© 2015 The Authors. Published by Elsevier Ltd. on behalf of Surgical Associates Ltd. This is an open access article under the CC BY-NC-ND license (<http://creativecommons.org/licenses/by-nc-nd/4.0/>).



**Fig. 1.** (A) Multiple subcutaneous lesions in the thorax, abdomen; (B) intraoperative view of the subcutaneous lipomas; (C) the patient after removal of the lipomas and abdominoplasty.

visible and palpable lobular formations with soft consistence and areas with dense texture (Fig. 1A).

Abdominal computed tomography (CT) demonstrated a soft tissue heterogeneous formation, located under the diaphragm, between the stomach and spleen, leading to compression of these organs. Pancreas was with a normal visible head, but the rest was not visualized. Routine laboratory tests revealed hemoglobin 119 g/l and leukocytes  $17 \times 10^9$  cells/l. Tumor markers (CEA and CA 19–9) were within normal values.

The surgical procedure started with excision of the redundant skin and underlying subcutaneous tissue with multiple lipomas (Fig. 1B). After the laparotomy a rounded formation, attached to the diaphragm was found. The tumor mass was localized behind the stomach and under the transverse colon, involving the lesser sac and lying on the mesentery of the small intestine, reaching the entrance to the pelvic floor. There was no communication with the guts. The total diameter of the tumor was about 40 cm. The tumor was heterogeneous, composed of solid area with diameter up to 15 cm and cystic zones. Multiple whitish round formations with diameter up to 20 mm were isolated in addition to the main tumor. The pancreatic body was milled by the tumor. So the presumable clinical diagnosis was a pancreatic cystadenocarcinoma (Fig. 2). The tumor was carefully extirpated. Splenectomy and distal pancreatic resection were performed. The whole tumor weight was 10–12 kg. The specimen was transected *ex vivo*—cystic parts of the tumor were filled with liquid and necrotic tissues. Abdominoplasty was performed (Fig. 1C).

Microscopically, the tumors were characterized by interlacing bundles of elongated cells with spindle-shaped nuclei with fibrillary collagenous background (Fig. 3). The nuclei of the tumor cells in some areas showed a definite tendency to palisade and form anuclear zones. Mitotic rate varied from 2 to 50 mitotic figures per 50 high power fields in slides from different tumor formations. Foci of hemorrhages and necrosis were presented. Tumor cells reached the peripancreatic fat tissue but did not infiltrate the pancreatic parenchyma. Immunohistochemically the tumor cells were CD117 and CD34 strongly positive, Cytokeratin AE1/3, Smooth Muscle Actin, Desmin, and S-100 negative.

The surgical procedure lasted 4 h and 15 min. The postoperative period was uneventful. The patient was discharged on the 9th postoperative day. An adjuvant therapy with Imatinib was initiated. The patient was in good condition one year later.

### 3. Discussion

In 1846 Brodie reported multiple lipomatosis for the first time, but the hereditary aspect of FML was shown in 1891 by Blashko [5]. Inheritance of the disease is frequently by autosomal dominant transmission, although cases with recessive inheritance have

also been reported [7]. Multiple lipomas, found on the trunk and extremities with a relative sparing of the head and shoulders, appearing mostly in the third decade of life and affecting several members of a family, may be highly suggestive of FML [5,8], as in our case. Typically for FML, our patient's lipomas were painless and they did not limit his daily activity [5–7]. The main treatment of FML is surgical excision [5]. The purpose usually is cosmetic but sometimes there are functional disorders of the joints, extremities, etc. due to the nearby lipomas so their removal is required. Other treatment options are liposuction and injection lipolysis [5,9]. Because of the extreme obesity of our patient, we decided to perform abdominoplasty in order to reduce the subcutaneous fatty tissues simultaneously with the removal of the lipomas.

In the presented case, we observed another rare disease—EGIST. As we mentioned above, EGISTs occur outside the gastrointestinal tract and in cases with extensive involvement of the abdominal cavity the primary site of origin may be impossible to determine [10]. Only few cases with familial GIST have been reported and the inheritance is autosomal dominant [10].

At present the origin of EGISTs remains controversial. EGISTs and the cells of Cajal have some similar features like the expression of CD117 and CD34 [2,3]. Yamamoto et al. reported that EGISTs and GISTs probably have a similar origin because they show comparable KIT mutations [11]. Some authors suggest that GISTs and EGISTs arise from the common precursor cell of cells of Cajal and the smooth muscle cells of the intestine [2]. Other possibility is that EGISTs are mural GISTs with loss of contact with the point of origin due to an extensive extramural growth pattern [2].

Clinical presentation of EGISTs is non specific and variable depending on the tumor size and localization. [1,2,10] The CT and magnetic resonance imaging are the first choice of diagnostic methods [1,4]. The endoscopic studies and endoscopic ultrasound are diagnostic options for gastric and intestinal GISTs or the connection of EGISTs with the guts can be excluded with them [4]. Positron emission tomography is an additional option [1,4].

Unique microscopic features (fusiform, epithelioid or mixed type) and immunohistochemical techniques (CD-117, CD34, actin, desmin, S-100 and ki-67) are very important to confirm the diagnosis. Mitotic index have to be determined in the most active regions and margins status. Different types of mutations can be found in KIT and PDGFRA genes which encode a receptor tyrosine kinases type III [1,2,4,10].

Risk stratification of GISTs according to Miettinen et al., Fletcher's classification and UICC classification is based on mitotic index, tumor size and localization [1–4,10]. But none of these classifications include the EGISTs. Achieved resection margins (R0 or R1) and capsule rupture are other prognostic factors [10]. However, the available data in literature regarding the prognosis of EGISTs are still rather limited [2,10].

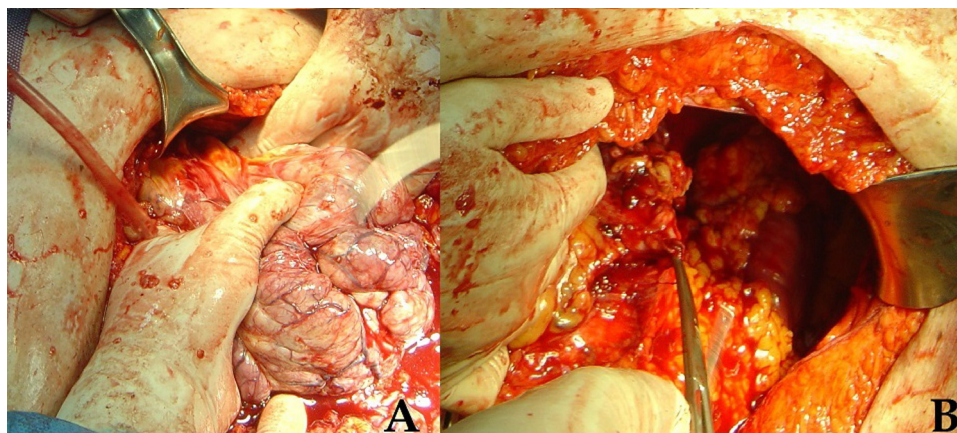


Fig. 2. (A) Intraoperative view of the solid part of the tumor; (B) the patient's abdominal cavity after radical tumor extirpation.

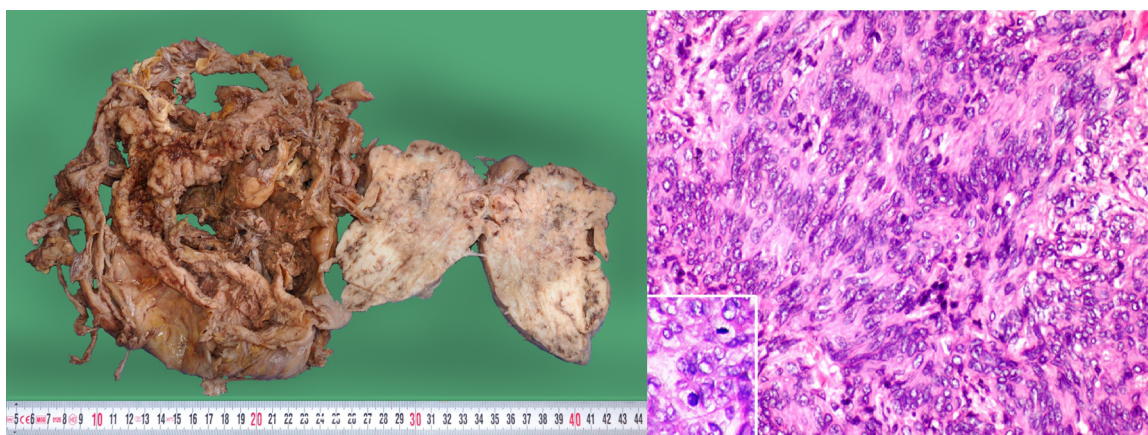


Fig. 3. Macroscopic and microscopic pathological view of the tumor (H&E –hematoxylin and eosin).

Surgical resection is the standard treatment of EGISTs [1,2,4,10]. The aim is to achieve R0 resection related to 48–65% 5-year survival [1]. If adjacent organs are involved, en bloc resections have to be performed [1,4,10]. Intraperitoneal rupture or excessive bleeding is associated with a high risk of postoperative recurrence [10]. Because of the rarity of metastases of GIST in lymph nodes, systematic lymphadenectomy is not a standard procedure [1,4,10].

Despite the fact that complete resection is feasible in most localized GIST cases, there is still a recurrence rate of up to 50% according to some studies [4]. So the opportunity of targeted medical therapy of GISTs by tyrosine kinase inhibitors is very useful [4,10,12,13]. According to the NCCN guidelines, neoadjuvant therapy is recommended for GISTs that are marginally resectable or resectable with risk of significant morbidity [4,13]. Adjuvant treatment for low-risk patients is not indicated [4,12,13]. Cases with capsule rupture are indicated for targeted therapy too [4]. However, data about targeted treatment for EGISTs is still limited [2].

#### 4. Conclusion

We report a case of a patient with two rare diseases—FML and EGIST, misinterpreted macroscopically as a pancreatic cystadenocarcinoma. The radical resection of EGIST is the treatment of choice and therapy with Imatinib was performed because of the revealed high-risk tumor variant. Abdominoplasty was the option to improve the patient's quality of life, removing redundant skin and underlying subcutaneous fat tissue with multiple lipomas. Although we could not prove correlation between the observed

diseases, they are extremely rare and their combination is unusual which makes the presented case valuable and interesting.

#### Conflict of interest

None.

#### Funding

None.

#### Ethical approval

The patient's approval has been given for this case report.

#### Consent

An informed consent was obtained from the patient for publication of this case report and accompanying images. A copy of the written consent is available for review by the Editor-in-Chief of this Journal on request.

#### Author contributions

Elena Arabadzhieva wrote the paper. Sasho Bonev collected the literature for the review in the report. Atanas Yonkov analysed the review. Violeta Dimitrova, Dimitar Bulanov and Ivanka Taneva performed the operation of the patient described in this report.

Vesela Ivanova performed the histological examination and the immunohistochemical study and confirmed the diagnosis. Violeta Dimitrova revised the manuscript for important intellectual content and technical details. All authors have read and approved the final manuscript.

#### Guarantor

Violeta Dimitrova, MD, PhD, DMSc would be the guarantor.

#### References

- [1] E. Lai, S. Lau, W.Y. Lau, Current management of gastrointestinal stromal tumors, *Compr. Rev. Int. J. Surg.* 10 (2012) 334–340.
- [2] V. Beltrame, M. Gruppo, D. Pastorelli, S. Pizzi, S. Merigliano, C. Sperti, Extra-gastrointestinal stromal tumor of the pancreas: case report and review of the literature, *World J. Surg. Oncol.* 12 (2014) 105.
- [3] M. Miettinen, J. Lasota, Gastrointestinal stromal tumors: pathology and prognosis at different sites, *Semin. Diagn. Pathol.* 23 (2006) 70–83.
- [4] A. Poveda, et al., GEIS 2013 guidelines for gastrointestinal sarcomas (GIST), *Cancer Chemother. Pharmacol.* 74 (2014) 883–898.
- [5] D. Chirilă, D. Gligor, Familial multiple lipomatosis, *HVM Bioflux* 6 (2) (2014) 66–69.
- [6] D. Keskin, N. Ezirmik, H. Celik, Familial multiple lipomatosis, *IMAJ* 4 (2002) 1121–1123.
- [7] Y. Gologorsky, D. Gologorsky, A.S. Yarygina, U. Surti, M.J. Zirwas, Familial multiple lipomatosis: report of a new family, *Cutis* 79 (3) (2007) 227–232.
- [8] A. Rubinstein, Y. Goor, E. Gazit, S. Gabili, Non-symmetric subcutaneous lipomatosis associated with familial combined hyperlipidaemia, *Br. J. Dermatol.* 120 (1989) 689.
- [9] F.G. Bechara, M. Sand, D. Sand, S. Rotterdam, M. Stücker, P. Altmeyer, K. Hoffmann, Lipolysis of lipomas in patients with familial multiple lipomatosis: an ultrasonography-controlled trial, *J. Cutan. Med. Surg.* 10 (4) (2006) 155–159.
- [10] A.W. Beham, I.-M. Schaefer, Ph. Schüler, S. Cameron, B.M. Ghadimi, Gastrointestinal stromal tumors, *Int. J. Colorectal. Dis.* 27 (2012) 689–700.
- [11] H. Yamamoto, Y. Oda, K. Kawaguchi, N. Nakamura, T. Takahira, S. Tamiya, T. Saito, Y. Oshiro, M. Ohta, T. Yao, M. Tsuneyoshi, C-kit and PDGFRA mutations in extragastrointestinal stromal tumor (gastrointestinal stromal tumor of the soft tissue), *Am. J. Surg. Pathol.* 28 (2004) 479–488.
- [12] P.G. Casali, J.Y. Blay, E.C.E.C.Po. Experts, Gastrointestinal stromal tumours: ESMO clinical practice guidelines for diagnosis, treatment and follow-up, *Ann. Oncol.* 21 (Suppl. (5)) (2010) 98–102.
- [13] M. Von Mehren, R.S. Benjamin, M.M. Bui, E.S. Casper, E.U. Conrad, T.F. DeLaney 3rd, et al., Soft tissue sarcoma, version 2.2012: featured updates to the NCCN guidelines, *J. Natl. Comp. Cancer* 10 (8) (2012) 951–960.

#### Open Access

This article is published Open Access at [sciedirect.com](http://sciedirect.com). It is distributed under the [IJSCR Supplemental terms and conditions](#), which permits unrestricted non commercial use, distribution, and reproduction in any medium, provided the original authors and source are credited.