

Received: 2012.10.28
Accepted: 2013.02.08
Published: 2013.03.12

***Clostridium perfringens* meningitis, *Plesiomonas shigelloides* sepsis: A lethal combination**

Authors' Contribution:

- A** Study Design
- B** Data Collection
- C** Statistical Analysis
- D** Data Interpretation
- E** Manuscript Preparation
- F** Literature Search
- G** Funds Collection

Emmanuel Okon^{1BDEF}, Eliahu Bishburg^{1BDEF}, Sandra Ugras^{2E}, Trini Chan^{3E}, He Wang^{4E}

¹ Division of Infectious Diseases, Beth Israel Medical Center, Newark, NJ, U.S.A.

² Emergency Room Department, Beth Israel Medical Center, Newark, NJ, U.S.A.

³ Microbiology Laboratory Department, Beth Israel Medical Center, Newark, NJ, U.S.A.

⁴ Pathology Department, Beth Israel Medical Center, Newark, NJ, U.S.A.

Summary

Background:

Anaerobic bacterial meningitis is rare. It is extremely unusual without a portal of entry as most cases reported have been associated with trauma or neurosurgery.

Case Report:

We describe this rare case of clostridium meningitis and plesiomonas sepsis in an immunocompetent adult. A 71 year old man with diabetes presented with acute onset severe headaches, obtundation and signs of severe hemolysis following a 2 week game hunting trip in the Swiss Alps. His clinical status progressed rapidly; he died 3 hours after initial presentation. Post mortem lumbar puncture was performed with CSF analysis suggestive of bacterial meningitis. *Clostridium perfringens* was eventually recovered from the CSF as well as in the blood. *Plesiomonas shigelloides* was recovered from the blood as well.

Conclusions:

This is the first case of blood stream infection with these two organisms in a single patient without an obvious portal of entry.

key words:

meningitis • sepsis • clostridium perfringens • plesiomonas • hemolysis

Full-text PDF:

<http://www.amjcaserep.com/fulltxt.php?ICID=883830>

Word count:

733

Tables:

–

Figures:

1

References:

6

Author's address:

Emmanuel Okon, 201 Lyons Avenue at Osborne Terrace, Newark, NJ 07112, U.S.A., e-mail: ufan96@yahoo.com

BACKGROUND

Meningitis due to *Clostridium perfringens* is rare. When it occurs, there is usually a preceding history of trauma or surgery which serves as a portal of entry [1]. We present a case of *Clostridium* meningitis and *pleisiomonas shigelloides* sepsis in an immunocompetent adult.

CASE REPORT

A 71 year old gentleman was brought to the emergency room from the local international airport with complaints of chest pain and shortness of breath while in flight from Switzerland. He developed abdominal discomfort, severe headaches and extreme fatigue a day prior to his flight to the U.S. He had spent the last 2 weeks at the Swiss Alps, 6000 feet above sea level hunting game, some which he consumed.

His past medical history was significant for anemia of unclear etiology for which he received erythropoietin injections. He was diabetic, on pioglitazone and glyburide and also had coronary artery disease for which he had stents placed. Cardiac catheterization done prior to his trip was unremarkable.

Initial assessment in the emergency room revealed tachycardia and elevated blood pressure, 106/min and 201/74 mmHg respectively and with a temperature of 35.5°C. He had a generalized petechial rash, cyanosis of the face and extremities; oxygen saturation was 60% on room air. Chest x-ray showed bilateral infiltrates consistent with pulmonary edema and EKG was unremarkable. Blood samples drawn for laboratory testing were grossly hemolysed. His laboratory data were as follows; hemoglobin 6.6 g/dL, troponin 0.06 ng/mL, potassium 6.4 mmol/L, creatinine 2.8 mg/dL, total bilirubin 7.4 mg/dL, aspartate transaminase 1751 u/L, alanine transaminase 351 u/L, lactate dehydrogenase 13088 u/L and, lactate of 17.58 (0.5–2) mmol/L.

Patient required mechanical ventilation. Bleeding was noted from the endotracheal tube and intravenous sites.

Computerized tomography angiogram obtained was negative for pulmonary embolism. His clinical status deteriorated rapidly as he became hypotensive and bradycardic. He died approximately 3 hours after initial presentation. He did not receive any antibiotics during this time.

A post-mortem lumbar puncture was performed with the following results; red blood cell count of 900/CMM, white blood cell count of 3100/CMM, Polys 82%, lymphocytes 3%, monocytes 10%, glucose 132 mg/dL, protein 462 g/L and, lactate 29.9 mmol/L. Initial gram stain revealed gram positive bacilli. *Clostridium perfringens* (*C. perfringens*) was subsequently recovered after 44 hours of incubation. The same organisms as well as *Plesiomonas shigelloides* (*P. shigelloides*) were recovered from two sets of blood cultures in less than 24 hours. An autopsy report was suggestive of septic complications as cause of death.

DISCUSSION

C. perfringens is an obligate, anaerobic, spore forming, gram-positive bacteria (Figure 1). It occurs naturally in soil, female genital tract, and intestinal tract of both animals and humans. They are known to produce large variety of toxins, many of which have lethal necrotizing and hemolytic properties. Clinically this organism is most commonly isolated from intra-abdominal infections or contaminated soft tissue injuries [2]. *C. perfringens* meningitis is rare especially in the absence of a portal of entry as most cases reported have been associated with trauma or neurosurgery [3]. Consumption of contaminated meat as source of *C. perfringens* infection has been described [4]. Patients usually present with headache, myalgia, abdominal pain and diarrhea. Anemia is proportional to the degree of hemolysis with evidence of disseminated intravascular coagulation, and these cases are invariably fatal with death occurring frequently in <12 hours [2].

P. shigelloides, facultative, anaerobic, gram-negative bacteria, usually reside in fresh water. They are most commonly

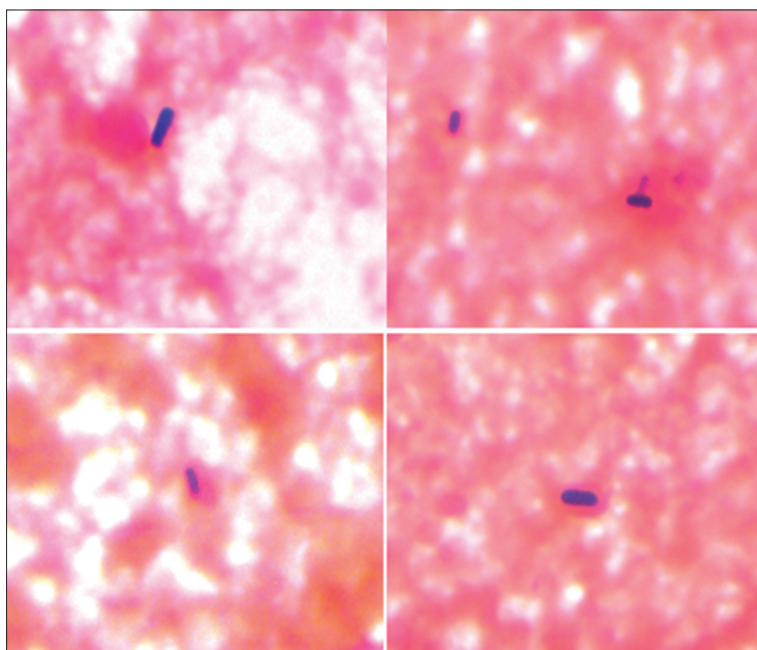


Figure 1. CSF gram stain showing gram positive rods. Magnification $\times 100$.

associated with gastroenteritis and bacteremia. There is some evidence that infection with this organism is associated with hemolysis [5]. *P. shigelloides* sepsis is more common in immunocompromised hosts, at extremes of age and tends to be a mixed infection with other organisms. In these situations, it has been associated with high mortality [6].

CONCLUSIONS

To the best of our knowledge, this report represents the first case of *C. perfringens* meningitis and *P. shigelloides* sepsis in a single patient. Our patient may have been infected by consuming contaminated meat and or water during his hunting trip. The combined effects of these two organisms probably contributed to the fatal outcome of this case. A high index of suspicion is required especially in cases of sepsis with hemolysis for early implementation of effective antibiotics.

Role of funding source

There was no funding associated with writing this paper. As the corresponding author, I had full access to the chart

and the final responsibility for the decision to submit this manuscript.

Conflicts

None.

REFERENCES:

1. Finsterer J, Hess B: Neuromuscular and central nervous system manifestations of *Clostridium perfringens* infections. *Infection*, 2007; 35(6): 396–405
2. Kasper DL, Fauci AS: *Harrison's Infectious Diseases*. McGraw-Hill medical, 2010; 438–43
3. Long JG, Preblud SR, Keyserling HL: *Clostridium perfringens* meningitis in an infant: case report and literature review. *Pediatr Infect Dis J*, 1987; 6: 752–54
4. Centers for Disease Control and Prevention. 2000. Surveillance for food-borne-disease outbreaks – U.S. 1993–1997. Centers for Disease Control and Prevention, Atlanta, GA
5. Janda JM, Abbott SL: Expression of Hemolytic Activity by *Plesiomonas shigelloides*. *J Clin Microbiol*, 1993; 31: 1206–8
6. Lee AC, Yuen KY, Ha SY et al: *Plesiomonas shigelloides* septicemia: case report and literature review. *Pediatr Hematol Oncol*, 1996; 13: 265–69