



## Case report

## Amantadine can induce intra-epithelial deposition in the cornea

Asayo Yoshinaka<sup>a,\*</sup>, Taiichiro Chikama<sup>b</sup>, Yoshiaki Kiuchi<sup>b</sup><sup>a</sup> Hiroshima Red Cross Hospital and Atomic-bomb Survivors Hospital, 1-9-6 Sendamachi, Naka-ku, Hiroshima-shi, Hiroshima, 730-0052, Japan<sup>b</sup> Department of Ophthalmology and Visual Science, Graduate School of Biomedical and Health Sciences, Hiroshima University, 1-2-3 Kasumi, Minami-ku, Hiroshima-shi, Hiroshima, 734-8551, Japan

## ARTICLE INFO

## Keywords:

Amantadine  
 Corneal opacity  
 Confocal microscopy  
 Corneal epithelial cell deposits

## ABSTRACT

**Purpose:** Amantadine has been reported to cause various corneal complications, such as superficial punctate keratitis, corneal endothelial dysfunction, and corneal edema. However, there have been no reports of amantadine-induced deposits in the corneal epithelium. Here, we describe the first case with amantadine-induced deposits in the corneal epithelium proved by confocal biomicroscopy.

**Observations:** An 81-year-old woman presented with impaired vision in both eyes. She had been treated with amantadine for 9 years. Corrected visual acuity was 0.8 in both eyes. Furthermore, both eyes showed opacities in the corneal epithelial layer. On confocal biomicroscopy, there were highly reflective deposits in corneal epithelial cells. There were no pathological findings in the stroma and endothelium. Two months after discontinuation of amantadine, corneal opacities disappeared, and visual acuity was 1.0 in both eyes.

**Conclusions:** Administration of amantadine can cause deposits in corneal epithelial cells.

## 1. Introduction

Amantadine was developed as a treatment for influenza A infection, and later found to exhibit anti-parkinsonian effects.<sup>1</sup> Since that discovery in 1969, it has been widely used in the management of Parkinson's disease.

There have been several reports regarding amantadine-associated ocular complications, such as superficial punctate keratitis, corneal endothelial dysfunction, epithelial edema, and stromal edema.<sup>2-5</sup> However, there have been no reports regarding amantadine-induced deposits in corneal epithelial cells.

Here, we describe a patient who exhibited bilateral corneal epithelial opacities following treatment of Parkinson's disease with amantadine.

## 2. Case report

An 81-year-old woman with bilateral corneal opacities was referred to the Hiroshima University hospital. At the first visit, her corrected visual acuity was 0.8 in both eyes. Intraocular pressures were 15 mmHg in the right eye and 16 mmHg in the left eye. Slit-lamp examination revealed bilateral belt-shaped epithelial opacities in the central part of the cornea (Fig. 1). She had no dry eye findings, such as superficial punctate keratitis or short tear break-up times. There were no signs of

inflammatory findings in the anterior chamber, vitreous or retina. The endothelial cell density at the center cornea was 3017 cells/mm<sup>2</sup> in the right eye and 2297 cells/mm<sup>2</sup> in the left eye. On anterior segment optical coherence tomography examination, there was no opacity and edema in the corneal stroma of either eye (Fig. 2). Confocal biomicroscopy showed high-density plaques in the basal layer of corneal epithelial cells in both eyes (Fig. 3).

The patient's medical history included Parkinson's disease, insomnia, hypertension, hypercholesterolemia, osteoporosis, hypothyroidism, and constipation. She was taking amantadine, clonazepam, milnacipran, carvedilol, lovastatin, levothyroxine, alfacalcidol, alendronate, rabeprazole, and irsogladine. Amantadine had been started 9 years prior for treatment of Parkinson's disease. Her daily dose of amantadine was 300 mg. She had no history of the use of any eye drops. The patient's ocular history was unremarkable, and she had no family history of corneal disease.

We suspected that the corneal opacities might be associated with the use of systemic drugs. Among the drugs that the patient was taking, amantadine has reportedly induced several corneal complications; thus, amantadine was suspected as the probable cause of her corneal opacities. After consultation with her neurologist, amantadine therapy was discontinued. Two months after discontinuation of amantadine, the patient's corneal opacities had disappeared (Fig. 4), and visual acuity

\* Corresponding author. 1-9-6 Sendamachi, Naka-ku, Hiroshima, Hiroshima, 730-0052, Japan.

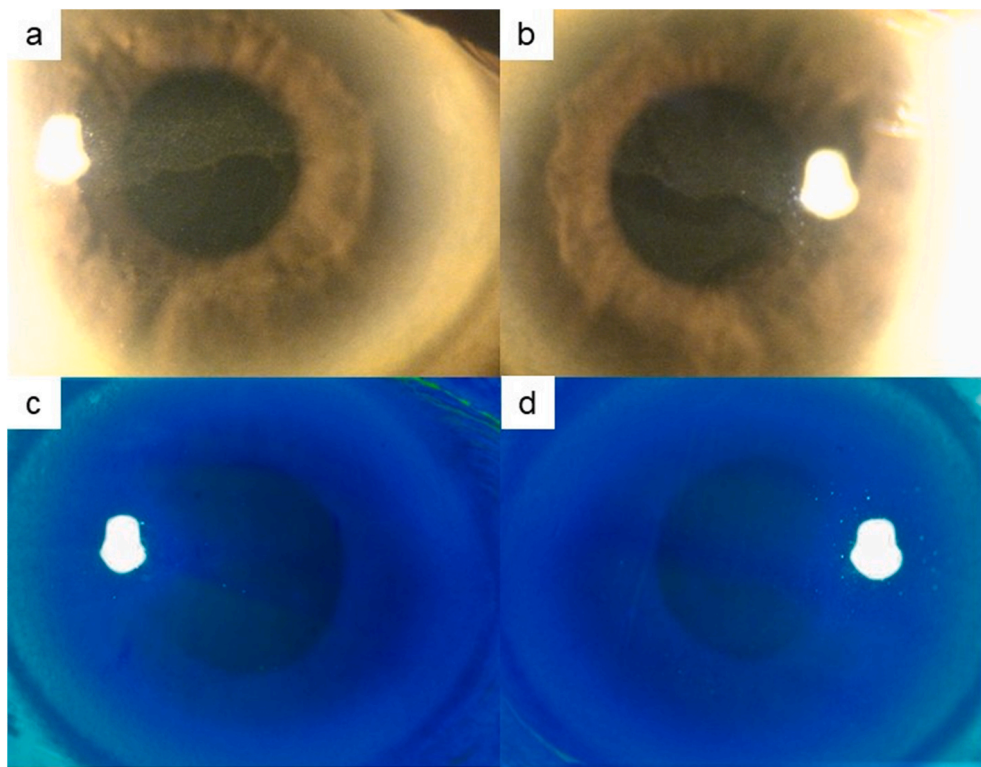
E-mail address: [asayo@hiroshima-u.ac.jp](mailto:asayo@hiroshima-u.ac.jp) (A. Yoshinaka).

<https://doi.org/10.1016/j.ajoc.2020.100852>

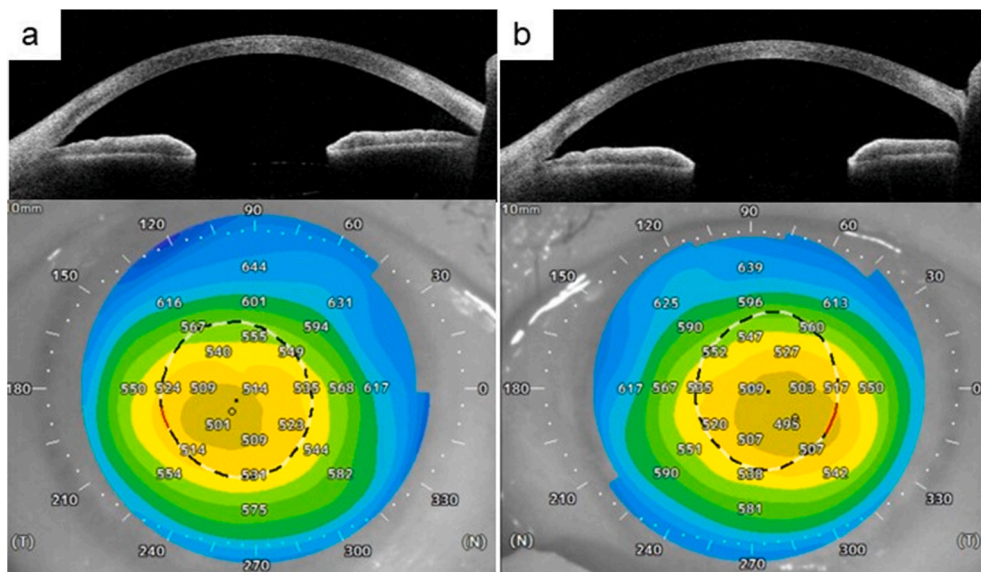
Received 12 February 2020; Received in revised form 5 July 2020; Accepted 26 July 2020

Available online 5 August 2020

2451-9936/© 2020 Published by Elsevier Inc. This is an open access article under the CC BY-NC-ND license (<http://creativecommons.org/licenses/by-nc-nd/4.0/>).



**Fig. 1.** Slit-lamp examination of the anterior segment at the first visit. There were intra-epithelial opacities in the right cornea (a, c) and left cornea (b, d). There was no fluorescein staining in either cornea (c, d).



**Fig. 2.** Anterior segment optical coherence tomography examination of the right cornea (a) and left cornea (b) at the first visit. There was no opacity or edema in either cornea.

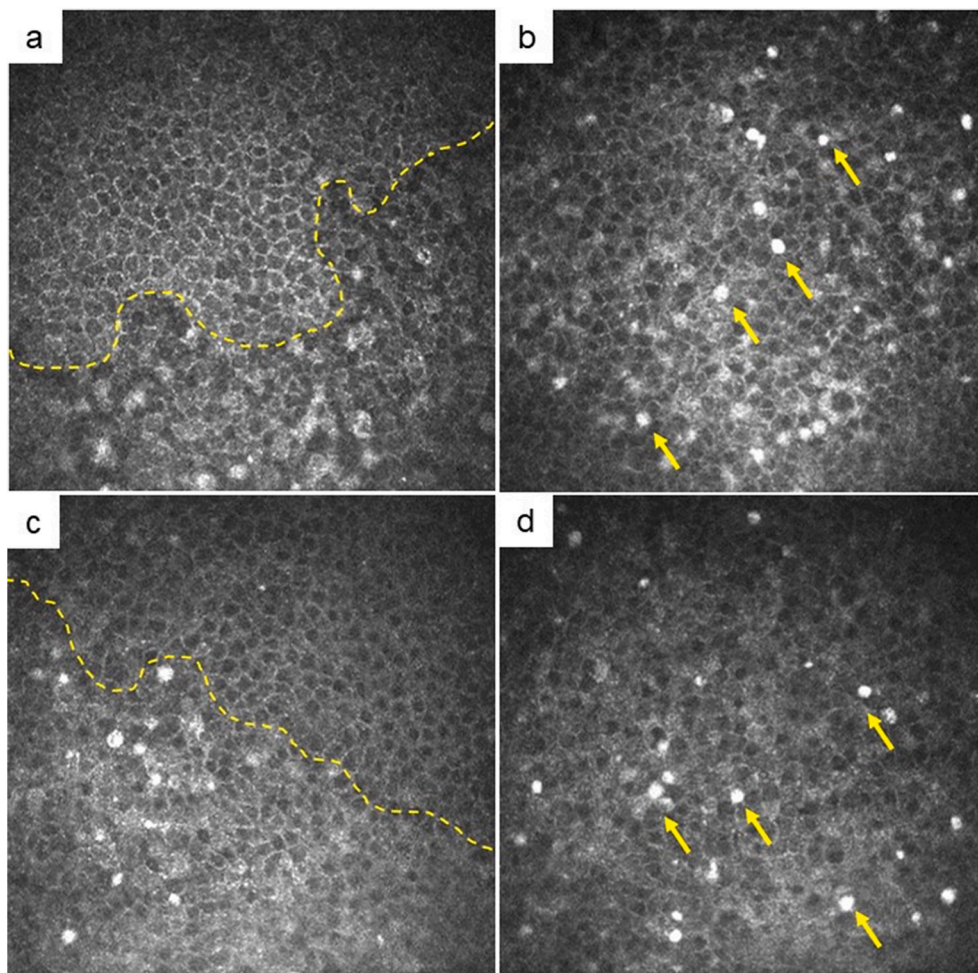
had returned to 1.0 in both eyes. Furthermore, there were no high-density deposits in corneal epithelial cells on confocal biomicroscopy (Fig. 5). The patient was returned to her referring ophthalmologist for continued follow-up care.

**3. Discussion**

Amantadine has been reported to cause various corneal complications, such as superficial punctate keratitis, corneal endothelial

dysfunction, and corneal edema.<sup>2-5</sup> However, these reports did not clearly show that amantadine can induce deposits in corneal epithelial cells. We report here on amantadine-induced deposits in corneal epithelial cells; notably, confocal biomicroscopy was useful for observation of highly reflective deposits in the basal layer of corneal epithelium.

A number of systemic drugs, such as amiodarone, are known to induce deposits in corneal epithelial cells<sup>6</sup>; these drugs tend to induce a vortex pattern of deposits. This vortex pattern of corneal deposits is the



**Fig. 3.** Confocal biomicroscopic findings of the right cornea (a, b) and left cornea (c, d) at the first visit. The basal layers of corneal epithelial cells around the border between the opaque and clear portions of the cornea are shown, and the dotted line represents the border between the normal and abnormal areas. Epithelial cells in the upper area were normal. In the lower area, reflective abnormal epithelial cells were observed (a, c). In the basal layer of the opaque cornea, highly reflective round shaped deposits were observed (b, d) (arrow head).

result of the centripetal migration of cells from the limbal stem cells to the center of the cornea. The epithelial cells in the central area of the cornea are exposed to drugs for a longer period of time, and tend to form opacities due to accumulation of drug inside affected cells. Therefore, in the present case, we speculate that the corneal opacities appeared in the central area of the cornea due to drug exposure.

The patient in the present case, however, did not show a vortex pattern of corneal deposits, but rather a belt-shaped epithelial opacity at the center of each cornea. The mechanism for the formation of amantadine-induced deposits may differ from that in amiodarone-induced keratopathy. The belt-shaped opacities matched with the eyelid apertures, thus the exposure to air may have caused some kind of reaction and induced belt-shaped opacities.

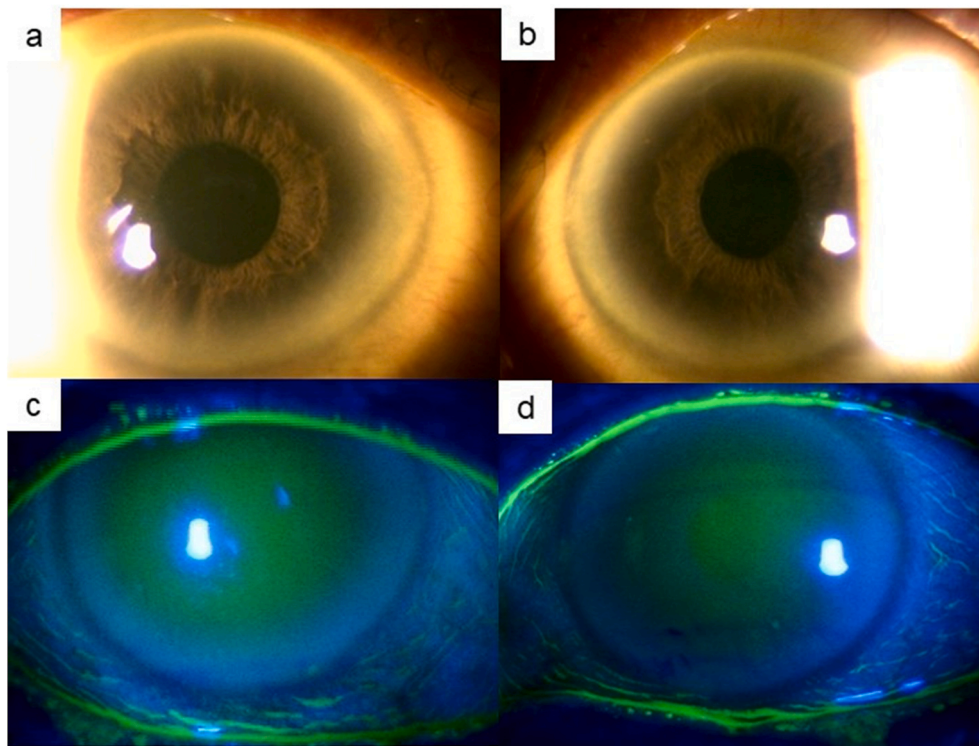
We propose the following two possible mechanisms for the formation of amantadine-induced corneal deposits. First, phospholipidosis (PLD) in the cells of the corneal epithelium may be related to the occurrence of amiodarone-induced keratopathy; notably, amiodarone is the most widely studied systemic drug that causes corneal epithelial changes. Amiodarone belongs to the family of cationic-amphiphilic drugs (CADs), and has been shown to induce PLD in various organs.<sup>8</sup> The cornea is a potential target of PLD. Corneal PLD is termed drug-induced keratopathy and involves formation of corneal deposits. The precise mechanism for CAD-induced corneal toxicity is not well-known, but PLD in the cells of corneal epithelium may be related to amiodarone-induced toxicity. In addition, other CADs (e.g., chloroquine, chlorpromazine and indomethacin) have been reported to cause corneal PLD.<sup>9,10</sup> Amantadine also belongs on the list of CADs,<sup>11</sup> and has been reported to cause phospholipid storage in various organs and tissues in rats, as well as in

cultured cells.<sup>12</sup> It is not yet known whether amantadine causes phospholipid storage in corneal epithelial cells, but amantadine might be associated with drug-induced PLD, similar to the effects of other CADs.

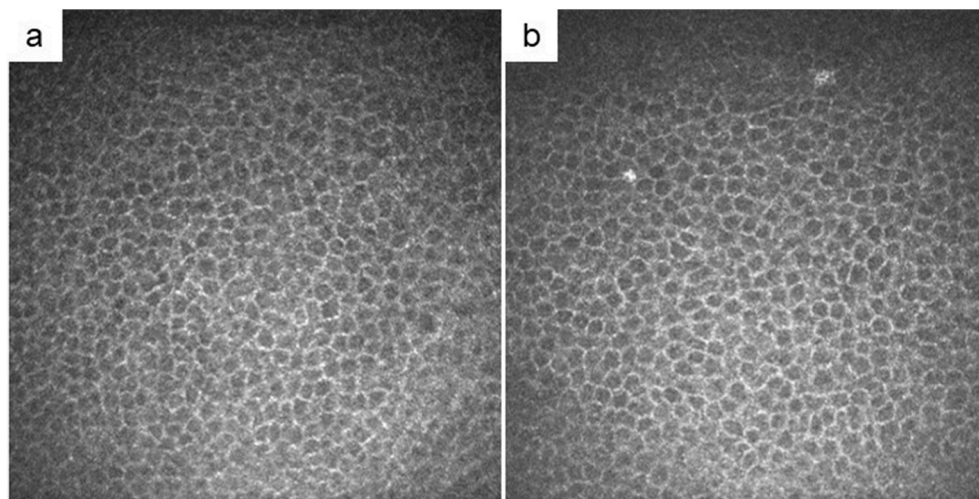
There have also been several reports regarding confocal biomicroscopic observations of amiodarone-induced keratopathy.<sup>13,14</sup> Those studies showed highly reflective epithelial cells, which were morphologically similar to those in the present case. However, some of the highly reflective materials inside the epithelial cells in the present case were hard to explain, because they varied in contrast and shape. A possible reason is that different doses of amantadine or different densities of the cytoplasmic deposits may affect the reflective materials. It is also possible that the highly reflective materials that did not seem to be located inside the epithelial cells may be the result of epithelial cell degeneration after the accumulation of amantadine. However, the resolution of the current confocal biomicroscope limited our ability to obtain a more-detailed image of the morphology of the corneal epithelial cells. Further studies with a larger number of patients are needed to be able to understand the morphological mechanisms.

Second, organic cation transporters (OCTs) may be related to amantadine-induced keratopathy. OCTs constitute broad-specificity transporters for the excretion of endogenous organic cations, as well as the uptake, elimination, and distribution of cationic drugs, toxins, and environmental waste products. OCT1 and OCT2 are members of a solute carrier superfamily of OCTs; notably, OCT1 and OCT2 are primarily expressed in the basolateral membrane of renal tubules, where they aid in renal secretion and reabsorption.<sup>15</sup> Structurally, amantadine is a substrate of both OCT1 and OCT2.<sup>16</sup> Furthermore, several transporters are expressed in various ocular tissues, such as the cornea, iris, ciliary





**Fig. 4.** Slit-lamp examination of the anterior segment at 2 months after discontinuation of amantadine. Corneal intra-epithelial opacities disappeared in the right cornea (a, c) and left cornea (b, d). There was no fluorescein staining in either cornea (c, d).



**Fig. 5.** Confocal biomicroscopy of the right cornea (a) and the left cornea (b) at 2 months after discontinuation of amantadine. These images show almost the same areas as seen in Fig. 3. There were no high-density deposits in the corneal epithelial cells in either cornea.

body, conjunctiva, and retina; in these tissues, facilitate the transport of many drugs, toxins, and endogenous compounds.<sup>17</sup> OCT1 mRNA has been detected in human cornea.<sup>18</sup> These findings suggest that OCTs may contribute to the transport of amantadine into corneal epithelial cells.

Additionally, the patient was using many drugs, and the interactions of these drugs or their metabolites may have contributed to the formation of corneal deposits. Further studies are needed to elucidate the underlying mechanism in amantadine-induced formation of corneal deposits.

#### 4. Conclusions

Amantadine can induce deposits in corneal epithelial cells, and

should be considered in the differential diagnosis of corneal opacity.

#### Patient consent

Consent to publish the case report was not obtained. This report does not contain any personal information that could lead to the identification of the patient.

#### Funding

No funding was received for this work.

## Authorship

All authors attest that they meet the current ICMJE criteria for Authorship.

## Declaration of competing interest

No conflict of interest exists.

## Acknowledgments

We thank Ryan Chastain-Gross, Ph.D., from Edanz Group (<https://en-author-services.edanzgroup.com/>) for editing a draft of this manuscript.

## References

- Schwab RS, England AC, Poskanzer DC, Young RR. Amantadine in the treatment of Parkinson's disease. *J Am Med Assoc.* 1969;208(7):1168–1170. <https://doi.org/10.1001/jama.1969.03160070046011>.
- Nogaki H, Morimatsu M. Superficial punctate keratitis and corneal abrasion due to amantadine hydrochloride. *J Neurol.* 1993;240(6):388–389. <https://doi.org/10.1007/BF00839973>.
- Kubo S, Iwatake A, Ebihara N, Murakami A, Hattori N. Visual impairment in Parkinson's disease treated with amantadine: case report and review of the literature. *Park Relat Disord.* 2008;14(2):166–169. <https://doi.org/10.1016/j.parkreldis.2007.03.003>.
- Jeng BH, Galor A, Lee MS, et al. Amantadine-associated corneal edema. Potentially irreversible even after cessation of the medication. *Ophthalmology.* 2008;115(9):1540–1544. <https://doi.org/10.1016/j.ophtha.2008.03.011>.
- Chang KC, Jeong JH, Kim MK, Wee WR, Lee JH, Jeon BS. The effect of amantadine on corneal endothelium in subjects with Parkinson's disease. *Ophthalmology.* 2010;117(6):1214–1219. <https://doi.org/10.1016/j.ophtha.2009.10.039>.
- Kaplan LJ, William E. Cappaert. Amiodarone keratopathy. *Arch Ophthalmol.* 1982;100(4):601–602. <https://doi.org/10.1001/archophth.1982.01030030603011>.
- D'Amico DJ, Kenyon KR, Ruskin JN. Amiodarone keratopathy: drug-induced lipid storage disease. *Arch Ophthalmol.* 1981;99:257–261, 10001/archophth.1981.03930010259007.
- Halliwell WH. Cationic amphiphilic drug-induced phospholipidosis. *Toxicol Pathol.* 1997;25:53–60. <https://doi.org/10.1177/019262339702500111>.
- Raizman MB, Hamrah P, Holland EJ, et al. Drug-induced corneal epithelial changes. *Surv Ophthalmol.* 2017;62(3):286–301. <https://doi.org/10.1016/j.survophthal.2016.11.008>.
- Lüllmann-Rauch R. Drug-induced lysosomal storage disorders. *Front Biol.* 1979;48:49–130.
- Burmester J, Hanpft R, Kröplin K, Lüllmann-Rauch RPM. Amantadine-induced lipidosis. A cytological and physicochemical study. *Toxicology.* 1987;44:45–59. [https://doi.org/10.1016/0300-483x\(87\)90045-x](https://doi.org/10.1016/0300-483x(87)90045-x).
- Ciancaglini M, Carpineto P, Zuppari E, Nubile M, Doronzo E, Mastropasqua L. In vivo confocal microscopy of patients with amiodarone-induced keratopathy. *Cornea.* 2001;20(4):368–373. <https://doi.org/10.1097/00003226-200105000-00007>.
- Ikegawa Y, Shiraishi A, Hayashi Y, Ogimoto A, Ohashi Y. In vivo confocal microscopic observations of vortex keratopathy in patients with Amiodarone-induced Keratopathy and Fabry disease. *J Ophthalmol.* 2018;2018. <https://doi.org/10.1155/2018/5315137>.
- Karbach U, Kricke J, Meyer-Wentrup F, et al. Localization of organic cation transporters OCT1 and OCT2 in rat kidney. *Am J Physiol Ren Physiol.* 2000;279(4 48-4):679–687. <https://doi.org/10.1152/ajprenal.2000.279.4.F679>.
- Goalski KB, Lou G, Prowse MT, et al. The cation transporters rOCT1 and rOCT2 interact with bicarbonate but play only a minor role for amantadine uptake into rat renal proximal tubules. *J Pharmacol Exp Therapeut.* 2002;303(3):959–968. <https://doi.org/10.1124/jpet.102.038885>.
- Zhang T, Xiang CD, Gale D, Carreiro S, Wu EY, Zhang EY. Drug transporter and cytochrome P450 mRNA expression in human ocular barriers: Implications for ocular drug disposition. *Drug Metab Dispos.* 2008;36(7):1300–1307. <https://doi.org/10.1124/dmd.108.021121>.
- Xiang CD, Batugo M, Gale DC, et al. Characterization of human corneal epithelial cell model as a surrogate for corneal permeability assessment: metabolism and transport. *Drug Metab Dispos.* 2009;37(5). <https://doi.org/10.1124/dmd.108.026286>, 992 LP - 998.