

Contents lists available at [ScienceDirect](http://www.sciencedirect.com)

International Journal of Surgery Case Reports

journal homepage: www.casereports.com

Intraoperative air leak test was useful for the detection of a small biliary fistula: A rare case of non-parasitic hepatic cysts with biliary communication

Atsushi Shimizu*, Shojiro Hata, Kaoru Kobayashi, Masanori Teruya, Michio Kaminishi

Department of Gastrointestinal Surgery, Showa General Hospital, 8-1-1 Hanakoganei, Kodaira, Tokyo 187-8510, Japan

ARTICLE INFO

Article history:

Received 6 August 2015

Accepted 14 September 2015

Available online 16 September 2015

Keywords:

Hepatic cysts

Biliary communication

Surgery

Air leak test

Bile leakage

ABSTRACT

INTRODUCTION: Symptomatic non-parasitic hepatic cysts with biliary communication are rare and no standard treatment has been established yet. Careful attention should be paid to avoidance of postoperative bile leakage during surgical treatment.

PRESENTATION OF CASE: We report the case of a 74-year-old man who visited our department complaining of right upper abdominal pain and elevated serum levels of the liver enzymes. Computed tomography revealed hepatic cysts including a large one measuring 16 cm in diameter in Segments IV and VIII. Percutaneous drainage of the cyst revealed bile-staining of the cyst fluid. Endoscopic retrograde cholangiography demonstrated the presence of a cyst–biliary communication. We performed open deroofing of the cyst. During the operation, the biliary fistula was invisible, however, air injection into the bile duct through the stump of the cystic duct caused release of air bubbles from the cyst cavity, which allowed us to detect the small biliary orifice and repair it successfully by suture.

DISCUSSION: We utilized the intraoperative air leak test, which has previously been reported to be effective for preventing postoperative bile leakage in patients undergoing hepatectomy to detect of a small cyst–biliary communication in a case undergoing non-parasitic hepatic cyst surgery.

CONCLUSION: An intraoperative air leak test may be a useful test during surgical treatment of non-parasitic hepatic cysts with biliary communication.

© 2015 The Authors. Published by Elsevier Ltd. on behalf of Surgical Associates Ltd. This is an open access article under the CC BY-NC-ND license (<http://creativecommons.org/licenses/by-nc-nd/4.0/>).

1. Introduction

Symptomatic non-parasitic hepatic cysts have been treated by various methods, including percutaneous aspiration, sclerotherapy, laparoscopic or open fenestration, deroofing, cystectomy, and hepatectomy [1–4].

Cyst–biliary communication, which is difficult to diagnose by non-interventional radiological studies alone, is a rather uncommon complication that can be incidentally found during the therapeutic procedure [5–10]. Although the optimal treatment strategy for such rare cases is not established, surgical treatment may be the treatment modality of first choice because percutaneous aspiration and sclerotherapy with alcohol or minocycline, as the alternative treatment, ablates the cyst cavity and may lead to irreversible sclerosing cholangitis in cases of cysts with biliary communication [4].

If biliary communication of a hepatic cyst is demonstrated preoperatively or intraoperatively, it is important to repair the biliary fistula meticulously during the operation to avoid the postoperative bile leakage, which may increase the morbidity and postoperative length of hospital stay [11]. However, it is not always easy to identify the site of communication during the operation, especially when the size of the biliary communication is too small to detect, causing stress to the surgeons.

The trans-cystic air leak test, previously described by Zimmitti et al. was reported as a useful technique for intraoperative localization of bile leakage in hepatectomy [12].

We utilized this technique to detect the difficult-to-find intracystic biliary orifice and repaired it successfully while carrying out an open deroofing operation for a non-parasitic cyst with biliary communication.

2. Presentation of case

A 74-year-old man visited our department with the chief complaint of right upper abdominal pain. He had no fever and his blood cell counts were normal, however, the blood chemistry showed elevation of the serum C-reactive protein to 2.41 mg/dL; gamma-

Abbreviations: CT, computed tomography; US, ultrasonography; ERCP, endoscopic retrograde cholangiography.

* Corresponding author.

E-mail address: atsushishimizu1214@hotmail.com (A. Shimizu).

<http://dx.doi.org/10.1016/j.ijscr.2015.09.014>

2210-2612/© 2015 The Authors. Published by Elsevier Ltd. on behalf of Surgical Associates Ltd. This is an open access article under the CC BY-NC-ND license (<http://creativecommons.org/licenses/by-nc-nd/4.0/>).

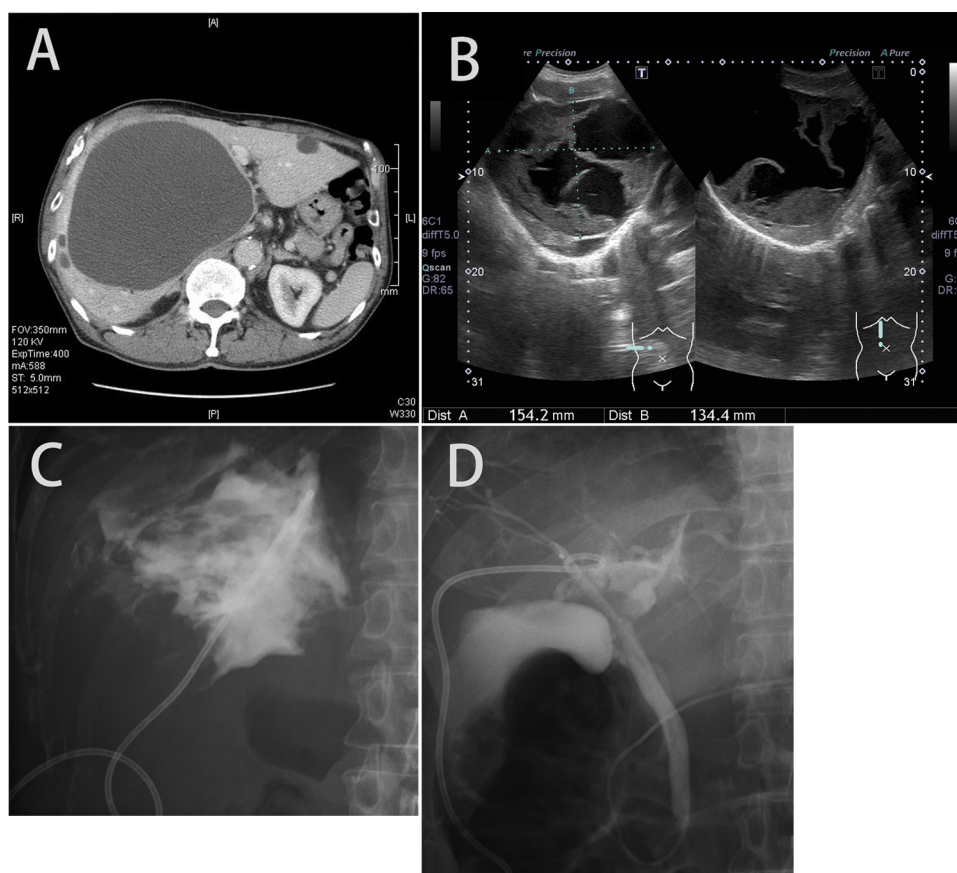


Fig. 1. Preoperative image findings.

(A) Contrast-enhanced CT showing a non-enhancing homogeneous low-density area measuring 16 cm in diameter, occupying the right paramedian sector of the liver. (B) US showing hyperechoic irregular-shaped structures in the cystic mass, suggestive of intracystic hemorrhage. (C) Cystography 5 days after percutaneous transhepatic drainage. The cyst cavity is filled with contrast material, which did not flow into the biliary tree. (D) ERCP showed the communication between the cyst and the biliary tree, but the site of communication was not clear.

glutamic transpeptidase to 510 IU/L, and alkaline phosphatase to 903 IU/L. Contrast-enhanced computed tomography (CT) of the abdomen revealed large cysts in the liver (Fig. 1A). The presence of the hepatic cysts had been pointed out during a routine CT checkup carried out at the time of endoscopic treatment of early gastric cancer 5 years earlier, however, they were left untreated because there were no symptoms. The largest cyst, located in right paramedian sector of the liver was 9 cm in diameter at the initial detection 5 years earlier, but had increased markedly in maximum diameter to 16 cm during the intervening 5-year period; it exhibited homogeneous density with no mural nodules or irregular enhancement. There were no luminal septations, however, the intrahepatic biliary tree was compressed. Ultrasonography (US) revealed the large cystic mass in the right liver containing hyperechoic structures in the cyst cavity which were not visualized in enhanced CT (Fig. 1B).

We performed radiology-guided percutaneous transhepatic drainage of the cyst both for differential diagnosis from a neoplasm and for the relief of the abdominal symptoms. The discharge from the pigtail drainage catheter was initially dark-brownish colored, then changing gradually to pure bile with a total bilirubin concentration of 74.2 mg/dL. Cytological examination showed no malignant cells. Bacterial culture of the discharge fluid showed no growth. The bilious discharge from the external drainage catheter persisted at 400 mL/day for a prolonged period. While cystography conducted 5 days after the tube placement failed to reveal any evidence of biliary communication (Fig. 1C), endoscopic retrograde cholangiography (ERCP) revealed the cyst–biliary communication (Fig. 1D).

Based on the diagnosis of a non-parasitic hepatic cyst with biliary communication associated with intracystic hemorrhage, we performed a radical operation 22 days after the percutaneous drain insertion into the cyst.

At laparotomy, the large drained cyst mainly located in the right paramedian sector was found to be deep-seated beneath the thick liver parenchyma of Segments IV and VIII. The other cysts were exposed and found to be covered by a transparent capsule and to contain serous fluid. After wide resection of the dome of the cyst with covering hepatic parenchyma using a Vessel sealing system (LigaSure®, Covidien, Japan), the necrotic tissues were found in the cyst cavity and were removed as much as possible.

The inner surface of the cyst wall was examined meticulously to identify the biliary communication, but there was no visible biliary fistula. Then we performed cholecystectomy and inserted a 5 Fr silicon catheter through the stump of cystic duct, fixing it by ligation. At first, we injected radiological contrast material into the tube and performed intraoperative cholangiography. Images of the biliary tree showed the contrast material flowing into the cyst cavity from the intrahepatic bile duct, however, but the site of biliary communication could still not be clearly identified.

Then, the cyst cavity was moistened with normal saline, and air was injected into the bile duct with manual occlusion of the distal common duct; this resulted in the appearance of air bubbles inside the cyst cavity (Fig. 2), and gradual suctioning of the pooled saline and meticulous removal of the covering necrotic tissues guided by the bubbles led us to identify the hidden small biliary fistula orifice.

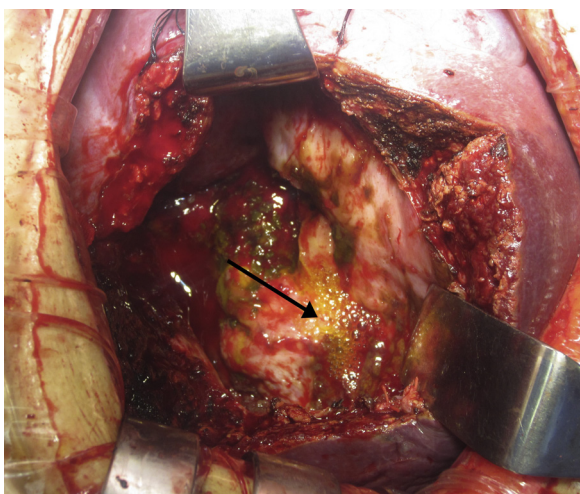


Fig. 2. The air leak test. The opening of the biliary fistula inside the hepatic cyst was invisible due to the presence of necrotic components inside the cyst clinging closely to the cavity of the cyst. Transcystic air injection resulted in the appearance of air bubbles in the cyst, indicating the presence of a cyst–biliary communication in the cavity (arrow). The distal common bile duct was occluded by finger compression during the injection.

We repaired the orifice directly with interrupted sutures using 5–0 monofilament absorbable suture (Biosyn®, Covidien, Japan). Air and indigocarmine were subsequently injected to confirm effective closure of the orifice and to ascertain the absence of any other

residual communication. Then completion intraoperative cholangiography confirmed the absence of any bile leakage or bile duct stricture. An omental patch was placed and fixed so as to cover the deroofed cavity of the cyst to prevent recurrence. The histopathological findings of the resected cyst wall were consistent with the features of a simple cyst, with no findings suggestive of a parasitic or neoplastic origin (Fig. 3A–C).

The postoperative course was uneventful and the patient was discharged from the hospital 13 days after the operation without any biliary complication. Until now, one year since the operation, neither CT nor US has revealed any evidence of recurrence of the cysts.

3. Discussion

Treatment of non-parasitic hepatic cysts with symptoms, including those arising from intracystic bleeding, infection, rupture, or compression of the adjacent organs is rarely associated with incidental detection of a biliary communication during the therapeutic procedures.

Table 1 reviews previously published reports of cases of non-parasitic hepatic cysts with biliary communication that were treated surgically. The median diameter of the treated hepatic cysts was 16 (range: 10–27.9) cm. Three of the 4 cases that were treated by percutaneous drainage showed bile staining of the drainage fluid, which led to a preoperative diagnosis of cyst–biliary communication. Four of the 7 cases were treated by surgical deroofing of the cyst; by an open procedure in 2 cases and by a laparoscopic procedure in 2 cases. Two cases were treated by additional Roux-en

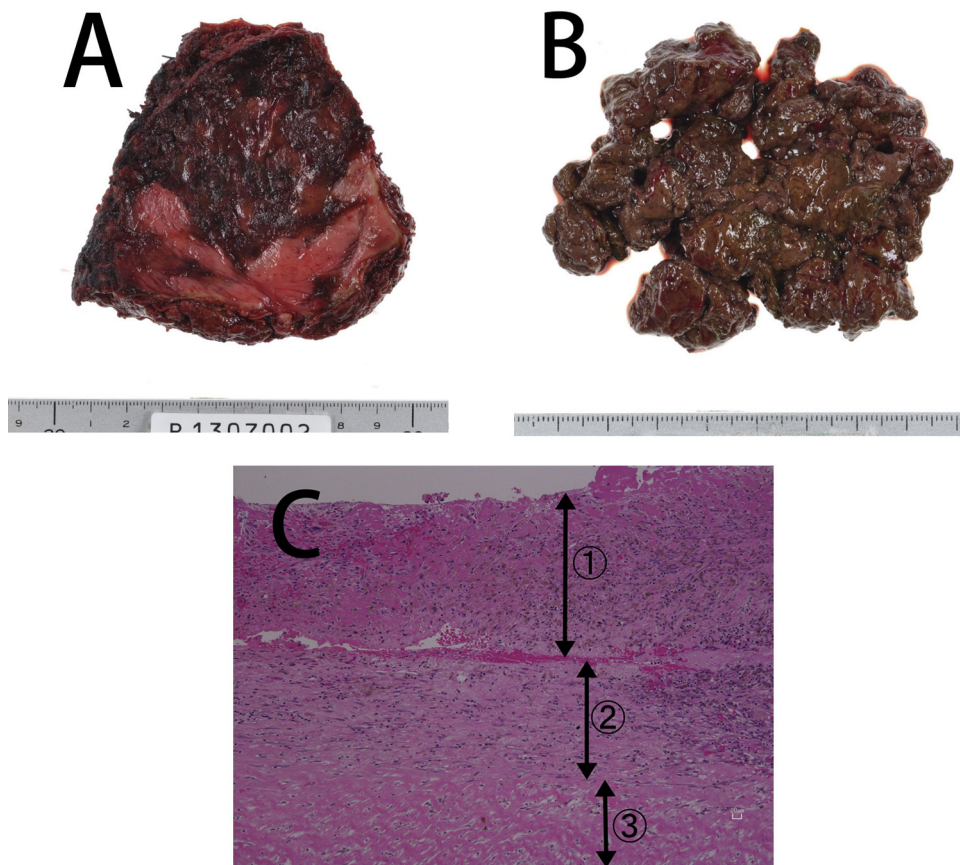


Fig. 3. Findings of the resected specimen. (A) Resected wall of the cyst with the surrounding hepatic parenchyma. (B) The intracystic components consisted of necrotic material and bile. (C) Pathological examination of the inner aspect of the resected cyst. 1. The cavity of the cyst was filled with necrotic tissue containing hemosiderin. 2. The wall of the cyst was composed of a thickened fibrous capsule without any evidence of tumor. 3. Excised normal parenchyma of the liver together with the cyst.

Table 1

Previous reports of non-parasitic hepatic cysts with biliary communication that were treated surgically.

Case	Age	Sex	Abdominal symptom	Maximum diameter (cm)	Location	Timing of diagnosis	Initial treatment	Lap or open	Procedure	Identification of the communication site	Authors	Year
1	38	F	Right upper quadrant pain	11	Segment IV	Postoperative (percutaneous aspiration)	Fenestration	Open	Sclerotherapy	No	Ravindra et al. [9]	1999
2	60	M	Distention, pain and dyspepsia	ND	ND	Intraoperative	No	Open	Deroofing/ cystojejunostomy	No	Ibrarullah et al. [6]	1999
3	71	F	Fullness and pain	16	Right lobe	Intraoperative	Aspiration	Lap	Deroofing/ closure of the orifice	Macroscopic inspection (confirmation by cholangiography and injection of ICG from the orifice)	Masatsugu et al. [8]	2003
4	52	F	Fever and pain	10	Segment IV	Preoperative	Aspiration/drainage	Lap	Deroofing	No (in spite of intravenous ICG injection systematically)	Yamada et al. [10]	2009
5	17	F	Pain	16.5	Segments VII and VIII	Preoperative	Aspiration/drainage	Open	Deroofing/ cystojejunostomy	No	Jain et al. [7]	2010
6	70	F	Fullness and pain	27.9	Entire liver	Intraoperative	No	Open	Deroofing/ closure of the orifice	Macroscopic findings supported by cholangiography	Cui et al. [5]	2013
7	74		Pain	16	Segments IV and VIII	Preoperative	Aspiration/drainage	Open	Deroofing/closure of the orifice	Transcystic air injection (confirmation by cholangiography and injection of indigocarmine)	The present case	

ND: not described, ICG: indocyanine green.

Y cystojejunostomy. Preoperative diagnosis of a cyst–biliary communication is not easy because of the lack of suitable non-invasive methods for the diagnosis. In the previously reported cases in the literature, drainage of bilious fluid from the cyst [10], ERCP [7], cholangiography [5,8] and cystography [10] led to the detection of biliary communication before or during the operation. In the present case, we initially undertook percutaneous drainage of the cyst, not only to relieve the abdominal symptoms, but also to rule out neoplasm because of the increase in cyst size and presence of intracystic components which were atypical for a simple cyst; this unexpectedly led to the diagnoses of a cyst–biliary communication based on the characteristics of the drainage fluid. ERCP, which is also a good preoperative assessment method for biliary communication [13], could not clarify the accurate site of the communication. The etiology of a cyst–biliary communication is not entirely clear. Some authors have suggested that intracystic pressure increase with damage of the lining epithelium of the cyst cavity may result in the penetration to the biliary tree [9]. In our present case, the cyst remained asymptomatic for 5 years, and the timing of appearance of the abdominal symptoms, changes in the US features of the cyst and elevation of the serum levels of the liver enzymes were thought to coincide with the occurrence of intracystic hemorrhage, which could have led to the development of the biliary communication.

In the era of laparoscopic surgery, some authors suggest that the standard treatment for non-parasitic hepatic cysts should be laparoscopic surgery [14], which has been shown to be associated with a lower recurrence rate than sclerotherapy and is less invasive than open surgery. Even though there are two case reports of hepatic cysts with biliary communication that have been treated successfully by a laparoscopic approach [8,10], the indication of laparoscopic surgery in cases preoperatively suspected as having a cyst–biliary communication is still controversial. Some authors recommend open surgery rather than laparoscopic surgery for secure repair of the biliary communication [3]. In fact, in one of the two aforementioned cases reported to be treated by laparoscopy, the site of the communication could not be detected [10].

Even during open operations, the site of communication is sometimes difficult to detect despite preoperative diagnosis of a biliary communication. In such situations, it is controversial as to whether cystenterostomy should be performed, which is associated with the potential risk of ascending cholangitis [4] or complete the operation by only deroofing, without repair of the biliary fistula. However, most authors emphasize the importance of repair of the biliary communication to avoid postoperative bile leakage [5].

Exploration to identify the site of biliary communication during the operation for a hepatic cyst is akin to exploration for a biliary fistula induced by iatrogenic intrahepatic bile duct injury during parenchymal dissection of the liver in hepatectomy. Various agents have been applied for the intraoperative bile leak test performed during hepatectomy such as saline solution [15], methylene blue, indocyanine green [16], fat emulsion [17] and air [18]. There is still no consensus as to the best used agent for the bile leak test to identify a biliary fistula. Among the reported methods, the air leak test is reported to be easily reproducible and useful for repair of an open bile duct, with reduced risk of postoperative bile leakage [12]. In contrast to injection of colored fluid, which often has to be limited to a single injection because of its drawbacks and surface runoff making the precise localization difficult because of staining of the surrounding tissues, air injection can be applied repeatedly; it does not require any special apparatus, or any radiologic apparatus or infrared camera, and involves no costs.

Even in surgery for hepatic hydatid cysts, in which postoperative biliary fistula is reported to be more common (8.2–26%) [19], air injection technique had never been proposed although some authors have mentioned the technical usefulness of injection of a

colored agent into biliary system [20]. To the best of our knowledge, this is the first report of application of the intraoperative transcystic air injection method in non-parasitic hepatic cyst surgery, which we considered to be rational and useful to detect the site of cyst–biliary communication.

4. Conclusion

The technique of transcystic air injection into the bile duct during the deroofing operation for hepatic cysts with a small cyst–biliary communication was useful for detection of the biliary orifice inside the cyst cavity. Surgeons should be aware of this technique as a useful option to obtain favorable outcomes, with reduced postoperative bile-related morbidity when confronting such rare cases of non-parasitic cysts with biliary communication.

Conflict of interest

None.

Funding

None.

Ethical approval

This case report is not a research study.

Consent

Written informed consent was obtained from the patient for publication of this case report and any accompanying images. A copy of the written consent is available for review by Editor-in-Chief of this journal on request.

Author contributions

Atsushi Shimizu is first and corresponding author of this paper. He and Shojiro Hata performed the operations, conceived and designed the study and drafted the manuscript. Kaoru Kobayashi, Masanori Teruya are members of medical team of gastrointestinal surgery in Showa General Hospital and had taken charge of management of the patients. Michio Kaminishi is a hospital director of Showa General Hospital, and he had supervised other authors. All the authors read and approved the final manuscript.

Guarantor

None.

Acknowledgements

We thank Dr. Nobuhisa Akamatsu of the University of Tokyo Hospital who kindly gave us comments that greatly improved the manuscripts. We thank all staffs, who belong to Showa General Hospital for treating and caring for this patient, in particular Dr. Seiichiro Shimizu of the Department of Pathology who contributed significantly to the histopathologic assessment.

References

- [1] M.F. Hansman, J.A. Ryan Jr., J. Ht. Holmes, S. Hogan, F.T. Lee, D. Kramer, et al., Management and long-term follow-up of hepatic cysts, *Am. J. Surg.* 181 (2001) 404–410.
- [2] F. Loehe, B. Globke, R. Marnoto, C.J. Bruns, C. Graeb, H. Winter, et al., Long-term results after surgical treatment of nonparasitic hepatic cysts, *Am. J. Surg.* 200 (2010) 23–31.

- [3] K. Moorthy, N. Mihssin, P.W. Houghton, The management of simple hepatic cysts: sclerotherapy or laparoscopic fenestration, *Ann. R. Coll. Surg. Engl.* 83 (2001) 409–414.
- [4] A. Tocchi, G. Mazzoni, G. Costa, D. Cassini, E. Bettelli, N. Agostini, et al., Symptomatic nonparasitic hepatic cysts: options for and results of surgical management, *Arch. Surg.* 137 (2002) 154–158.
- [5] W. Cui, H.Y. Zhou, Y.H. Zhang, T. Zhang, Q. Li, Surgical management of non-parasitic hepatic cyst with biliary communication: a case report, *Cancer Biol. Med.* 10 (2013) 110–113.
- [6] M.D. Ibrarullah, D. Sreenivasa, P. Sriram, B.P. Padhy, Giant non-parasitic hepatic cyst with biliary communication, *Trop. Gastroenterol.* 20 (1999) 142–143.
- [7] S.K. Jain, A. Vindal, B.K. Basra, R.C. Kaza, Cystojejunostomy for non-parasitic hepatic cyst with biliary communication, *Singapore Med. J.* 51 (2010) e27–29.
- [8] T. Masatsugu, S. Shimizu, H. Noshiro, K. Mizumoto, K. Yamaguchi, K. Chijiwa, et al., Liver cyst with biliary communication successfully treated with laparoscopic deroofing: a case report, *JLS* 7 (2003) 249–252.
- [9] K.V. Ravindra, B.V. Rao, A.P. Rozario, A.V. Pais, P.G. Thomas, I.V. Segment, Liver cyst with biliary communication following laparoscopic deroofing, *Indian J. Gastroenterol.* 18 (1999) 39–40.
- [10] T. Yamada, K. Furukawa, K. Yokoi, Y. Mamada, Y. Kanazawa, T. Tajiri, Liver cyst with biliary communication successfully treated with laparoscopic deroofing: a case report, *J. Nippon Med. Sch.* 76 (2009) 103–108.
- [11] P.J. Klingler, M. Gadenstatter, T. Schmid, E. Bodner, H.G. Schwelberger, Treatment of hepatic cysts in the era of laparoscopic surgery, *Br. J. Surg.* 84 (1997) 438–444.
- [12] G. Zimmitti, J.N. Vauthey, J. Shindoh, C.W. Tzeng, R.E. Roses, D. Ribero, et al., Systematic use of an intraoperative air leak test at the time of major liver resection reduces the rate of postoperative biliary complications, *J. Am. Coll. Surg.* 217 (2013) 1028–1037.
- [13] E.C. Lai, J. Wong, Symptomatic nonparasitic cysts of the liver, *World J. Surg.* 14 (1990) 452–456.
- [14] J.W. Treckmann, A. Paul, G. Sgourakis, M. Heuer, M. Wandelt, G.C. Sotiropoulos, Surgical treatment of nonparasitic cysts of the liver: open versus laparoscopic treatment, *Am. J. Surg.* 199 (2010) 776–781.
- [15] M. Ijichi, T. Takayama, H. Toyoda, K. Sano, K. Kubota, M. Makuuchi, Randomized trial of the usefulness of a bile leakage test during hepatic resection, *Arch. Surg.* 135 (2000) 1395–1400.
- [16] M. Kaibori, M. Ishizaki, K. Matsui, A.H. Kwon, Intraoperative indocyanine green fluorescent imaging for prevention of bile leakage after hepatic resection, *Surgery* 150 (2011) 91–98.
- [17] S. Nadalin, J. Li, H. Lang, G.C. Sotiropoulos, R. Schaffer, A. Radtke, et al., The white test: a new dye test for intraoperative detection of bile leakage during major liver resection, *Arch. Surg.* 143 (2008) 402–404, discussion 404.
- [18] H.Q. Wang, J. Yang, J.Y. Yang, L.N. Yan, Bile leakage test in liver resection: a systematic review and meta-analysis, *World J. Gastroenterol.* 19 (2013) 8420–8426.
- [19] C. Kayaalp, C. Aydin, A. Olmez, S. Isik, S. Yilmaz, Leakage tests reduce the frequency of biliary fistulas following hydatid liver cyst surgery, *Clinics (Sao Paulo)* 66 (2011) 421–424.
- [20] O. Irkorucu, E. Reyhan, H. Erdem, The detection of cysto-biliary communications during surgery for liver hydatid cysts: let's speak the unspoken, *Clinics (Sao Paulo)* 67 (2012) 179.

Open Access

This article is published Open Access at sciedirect.com. It is distributed under the [IJSCR Supplemental terms and conditions](#), which permits unrestricted non commercial use, distribution, and reproduction in any medium, provided the original authors and source are credited.