



The Effect of Ponte Osteotomies on the Sagittal Shape of Rods and Spine Derotation in Adolescent Idiopathic Scoliosis: A Single-Center, Retrospective Cohort Study

Elamir Bachar Harfouch¹, Reem Fahd Bunyan², Mona Al Faraidy³, Nayef Bin Dajim¹, Fahad A. Al Mulhim⁴, Haitham H. Alnemari^{5,6}, Shahid Bashir⁷

■ **BACKGROUND:** Adding a Ponte osteotomy (PO) to other surgical techniques for correcting adolescent idiopathic scoliosis (AIS) profoundly affects the entire sagittal shape of the rod. POs are an effective procedure for correcting thoracic hypokyphosis in patients with AIS.

■ **METHODS:** A retrospective review of 40 patients with AIS was conducted. The sample was divided into 2 groups: PO and non-PO. On a lateral radiograph, the rod end angle (A) was calculated using the intersections of the tangents with the rod end points. The maximal deflection (D) was obtained for each rod. In addition, the rod apex angle (B) was calculated using the intersection of the tangents at 2 points, each 1 cm to 1 side of the rod apex; the distance between the rods at the apex was then measured.

■ **RESULTS:** Concave rods tended to be straight or even lordotic at the apex in the non-PO group (-0.9° vs. $+5.9^\circ$ in the PO group; $P = 0.000$). The rod end angle and deflection were significantly lower in the non-PO group (15.2° and 7.1 mm vs. 26.3° and 17.8 mm in the PO group; $P = 0.000$ and $P = 0.000$). The convex rods were less kyphotic in the non-PO group; for the non-PO group, the end angle and deflection were 27.6° and 16 mm versus 33.4° and 23.8 mm in the PO group ($P = 0.03$ and $P = 0.000$). No significant difference between the groups was observed for the convex rod apex angle ($P = 0.8$). The

rod apices were more superimposed in the PO group (2.9 mm vs. 9.3 mm in the non-PO group; $P = 0.000$).

■ **CONCLUSIONS:** POs increase the overall sagittal kyphosis and improve the three-dimensional derotation of the apex in patients with AIS.

INTRODUCTION

The most common symptom of adolescent idiopathic scoliosis (AIS) is a scoliotic deformity of the spine, which can be corrected through spinal surgery. Ponte osteotomy (PO) is a procedure used to fix the sagittal and coronal balance of the spine. There is some controversy regarding the clinical effectiveness of PO as a treatment for AIS. In 1 study, 191 patients with AIS were evaluated after surgical correction of Lenke type 1A and 1B curvatures using pedicle screws, done with or without PO.¹ The study found that PO improved structural correction on all 3 anatomical planes.¹ Two other studies had contradictory findings; one found that PO significantly improved coronal and sagittal balance in patients with AIS, and the other found no improvement.^{2,3} The second of these, which had a small sample size, also found that PO increased complications, prolonging operative time and increasing the volume of bleeding.³ To address the controversy surrounding the role of PO in correcting AIS, we performed a retrospective analysis of long radiographs to compare the sagittal shape of the concave and convex rods

Key words

- Adolescent thoracic idiopathic scoliosis
- Ponte osteotomy
- Selective segmental pedicle screw

Abbreviations and Acronyms

AIS: Adolescent idiopathic scoliosis

PO: Ponte osteotomy

From the Departments of ¹Spine, ²Neurology and ³Anesthesia, King Fahad Specialist Hospital, Dammam, Saudi Arabia; ⁴Department of Spine, King Faisal University, Al Hasa, Saudi Arabia; ⁵Department of Spine, King Faisal Medical City, Abha, Saudi Arabia;

⁶Department of Spine, McMaster University, Hamilton, Ontario, Canada; and ⁷Neuroscience Center, King Fahad Specialist Hospital, Dammam, Saudi Arabia

To whom correspondence should be addressed: Elamir Bachar Harfouch, M.D.
[E-mail: bacharharfouche@hotmail.com]

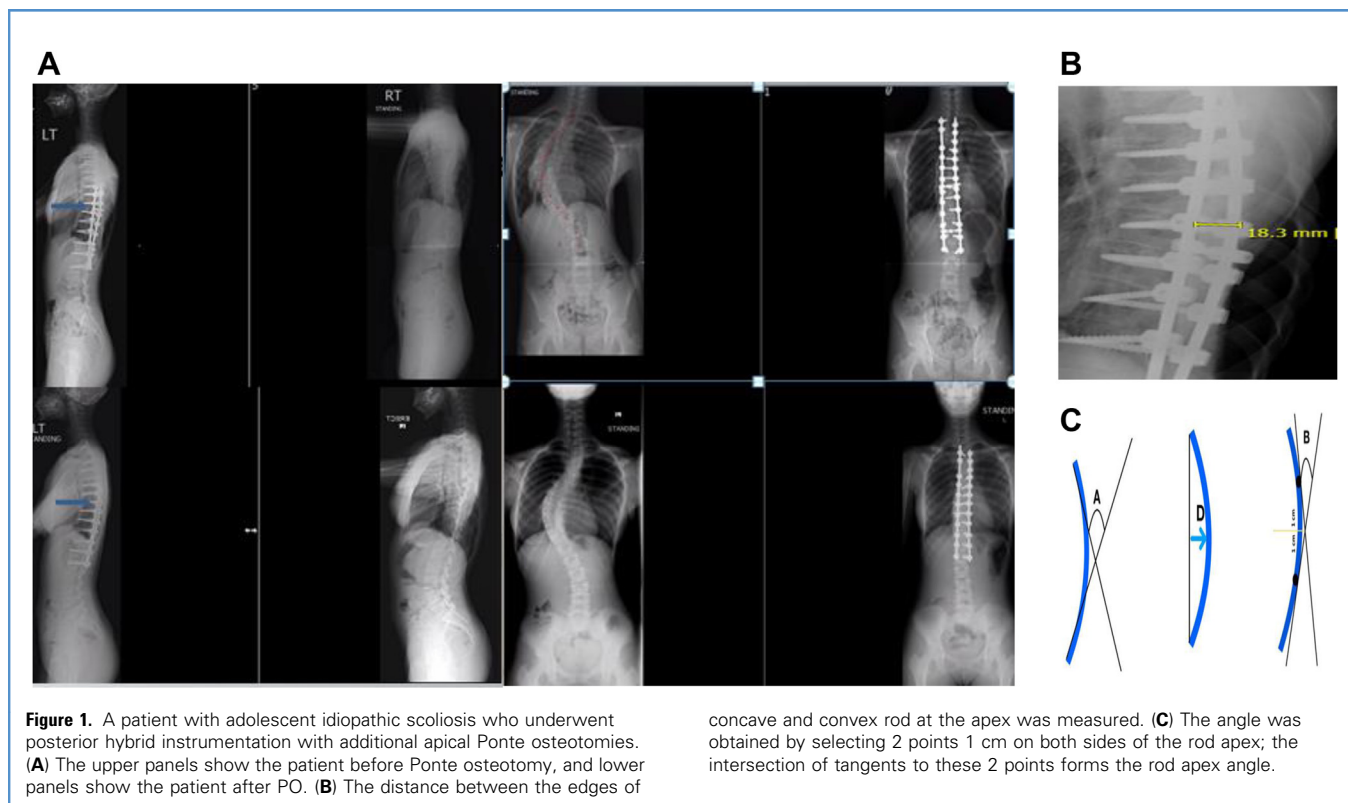
Citation: *World Neurosurg.* X (2022) 15:100125.

<https://doi.org/10.1016/j.wnsx.2022.100125>

Journal homepage: www.journals.elsevier.com/world-neurosurgery-x

Available online: www.sciencedirect.com

2590-1397/© 2022 The Author(s). Published by Elsevier Inc. This is an open access article under the CC BY-NC-ND license (<http://creativecommons.org/licenses/by-nc-nd/4.0/>).



and to study the distance between the 2 rods, which reflects the axial vertebral rotation in segmental pedicle screw constructs.

MATERIALS AND METHODS

Between 2015 and 2017, a single spinal surgeon (EBH) operated on all cases of AIS at our institution. Our protocol is to use freehand screw insertion on all levels as described by Kim et al.⁴ PO was performed using a bone rongeur to remove the distal part of the spinous process and ligamentum flavum. Then, a No. 2 Kerrison rongeur was used to cut the superior articular facet bilaterally. Usually 4–6 POs are required depending on the spine rotation. Deformity correction was performed using a 5.5 cobalt-chromium rod derotation from the concave side while holding the chest wall from the convex side. This was followed by convex rod insertion using the cantilever technique.

A retrospective review of 40 consecutive patients with primary AIS was conducted (Lenke 5C cases were not included because thoracic spinal fusion is not usually required, only for the lower thoracic spine); half of these had POs (Schwab type 2 osteotomy). Ethical clearance was obtained from the local institutional ethical committee for retrospective review of our cases. Data collected included the patients' ages, main thoracic Cobb angle before and after the operation, and flexibility angle of the main thoracic curve in the coronal plane (Figure 1A). Preoperative kyphosis (T5-T12) was also measured. The sagittal shape of the rod was evaluated using radiographic parameters on a lateral radiograph on long 36-inch film. The distance between the edges of the concave and

convex rod at the apex was measured (Figure 1B). These parameters included the rod end angle (A), which was calculated based on the intersection of the tangents to the rod proximal end point and the distal inflection points between the kyphotic and lordotic contours of the rod. The rod maximal deflection (B) was also obtained. The rod apex angle (C) was obtained by selecting 2 points 1 cm to each side of the rod apex; the intersection of the tangents to these 2 points forms the rod apex angle (D) (Figure 1C). The patients were divided into 2 groups: PO and non-PO. Statistical analyses were performed using IBM SPSS for Windows Version 22.0 (IBM Corporation, Armonk, New York, USA). Two-tailed *P* values <0.05 were considered significant.

RESULTS

There were 20 patients in the PO group and 20 patients in the non-PO group. The 2 groups did not differ significantly in patient age or preoperative kyphosis (Table 1). The preoperative coronal deformity of the main thoracic curve was higher in the non-PO group (72° vs. 62° in the PO group; *P* = 0.019). The postoperative coronal angle was higher in the non-PO group (25° vs. 16° in the PO group; *P* = 0.01). Table 1 shows that the concave rods tended to be straight or even lordotic at the apex in the non-PO group (−0.9° vs. 5.9° in the PO group; *P* = 0.000). The concave rod end angle and concave rod deflection were significantly lower in the non-PO group (15.2° and 7.1 mm vs. 26.3° and 17.8 mm in the PO group; *P* = 0.000 and *P* = 0.000, respectively).

Table 1. Age and Kyphosis of Ponte Osteotomy and Non-PO Groups

	Non-PO Group	PO Group	F Statistic	P Value
Age, years	16 ± 2.3	17.5 ± 3.7	2.3	0.134
Main thoracic curve, °	72.3 ± 14.2	61.9 ± 12.3	6.01	0.019
Bending angle, °	48 ± 15.4	42.2 ± 12.9	1.66	0.205
Postoperative angle, °	25.2 ± 9.4	16.3 ± 6.7	11.77	0.001
Concave rod ends angle, °	15.2 ± 8.1	26.3 ± 6.4	22.36	0.000
Deflection concave rod, °	7.1 ± 5.2	17.8 ± 4.0	51.88	0.000
Convex rod ends angle, °	27.6 ± 9.7	33.4 ± 7.3	4.63	0.038
Deflection convex rod, °	16 ± 6.2	23.8 ± 4.6	19.84	0.000
Distance between rods at apex, °	9.3 ± 4.5	2.9 ± 4.1	21.45	0.000
Concave rod apex angle, °	-0.9 ± 2.7	5.9 ± 2.0	80.05	0.000
Convex rod apex angle, °	7.4 ± 2.8	7.2 ± 2.8	0.049	0.826
Types, number of subjects (%)			7.410*	0.686*
1A	7 (35.0)	6 (30.0)		
1B	1 (5.0)	3 (15.0)		
1C	1 (5.0)	2 (10.0)		
2A	5 (25.0)	5 (25.0)		
2B	1 (5.0)	0 (0.0)		
2C	1 (5.0)	1 (5.0)		
3B	1 (5.0)	0 (0.0)		
3C	0 (0.0)	2 (10.0)		
4B	1 (5.0)	0 (0.0)		
4C	1 (5.0)	0 (0.0)		
6C	1 (5.0)	1 (5.0)		
Total number of subjects (%)	20 (100.0)	20 (100.0)		

Age and all kyphosis values are reported as mean ± SD.
* χ^2 test.

The convex rods were less kyphotic in the non-PO group, with an end angle and deflection of 27.6° and 16 mm (vs. 33.4° and 23.8 mm in the PO group; $P = 0.03$ and $P = 0.000$, respectively). The convex rod apex angle did not differ significantly between the groups ($P = 0.8$). The rod apices were more superimposed in the PO group (2.9 mm vs. 9.3 mm in the non-PO group; $P = 0.000$). There was no difference between the Lenke curve subtypes of the 2 groups ($P = 0.6$) (Table 1), and 95% of the cases had major thoracic curves. Also, there was no statistically significant difference in T5-T12 preoperative kyphosis between the 2 groups ($P = 0.4$).

DISCUSSION

AIS is typically associated with hypokyphosis or even lordosis of the thoracic spine. This is caused by a growth discrepancy between the anterior and posterior columns of the thoracic spine.^{5,6}

AIS correction with modern instrumentation using segmental pedicle screws results in a straight spine in the coronal plane but a lordotic thoracic spine.^{7,8} Anterior release of the intervertebral disc or posterior release using PO can overcome this problem.⁹⁻¹¹ Postoperative rod shape changes in the sagittal plane have previously been studied to assess rod deformation.¹² The concave rod kyphosis correlates well with the thoracic kyphosis, and the rod overlap corrects the rotational component of the deformity.^{13,14}

Our findings correlate well with previously published literature.⁸⁻¹⁴ However, we are the first to our knowledge to quantify the differences in rod shape between PO and non-PO groups. In addition, we describe the rod apex angle parameter (Figure 1), which has not been mentioned to our knowledge in previous literature. In fact, we found that this parameter was more important than the other rod parameters because the thoracic hypokyphosis in AIS is characterized by a lordotic apex.

Correction of this apex lordosis affects the general shape of the back and decreases the rib hump caused by the axial vertebral rotation, as demonstrated by Samdani et al.¹³

If the spine is fixed posteriorly using posterior elements and the anterior column is longer than the posterior one, a 5.5-mm cobalt-chromium rod cannot correct the deformity; the rod will be flattened against the fixed spine, and the rod may create a lordosis deformity of up to -8° . In fact, without osteotomy, the sagittal deformity will not be corrected even if segmental fixation is used on all levels. This problem is completely resolved by opening the spine posteriorly to allow the spine to hinge over the anterior part of the intervertebral discs. A PO eliminates the need for anterior release, so the patient does not have to undergo 2 procedures.

Our correction of kyphosis is based primarily on the concave rod; the convex rod does not correct kyphosis when the concave rod is in place. In fact, the convex rod only maintains the correction effected by the concave rod. Therefore, as expected, in the PO group, the convex rod was more kyphotic as the overall kyphosis was corrected by the concave rod. However, the changes to the convex rod apex angle differed owing to vertebral rotation and a lack of true kyphosis. We did observe a mean of 9° of improvement of the coronal correction in the PO group over the non-PO group. However, in the non-PO group, coronal deformity was about 10° higher than in the PO group. There was a significant difference in the axial vertebral rotation between the groups, reflecting the superposition of the rod apex. The rods tend to overlap at the apex in the PO group, which affects the correction of the rib hump deformity.

This study has several limitations. First, the retrospective design makes it vulnerable to the various biases inherent in such studies.

Second, the sample size is limited. Therefore, these findings need to be rigorously evaluated in a larger patient population with prospectively controlled comparison groups. Third, because the patients are members of a consecutive series operated on by a single surgeon, the surgeon's increase in experience could be a confounding factor that might affect the results.

CONCLUSIONS

POs could improve rod kyphosis in spine derotation in patients with AIS. In cases where the rod apex angle parameter seems to be more important than other rod parameters given the lordotic apex, focusing on correcting it yields significant results. Future studies should aim to explore our findings and the clinical correlations further to improve the procedure.

CRedit AUTHORSHIP CONTRIBUTION STATEMENT

Elamir Bachar Harfouch: Methodology, Investigation, Formal analysis, Writing – original draft, Writing – review & editing. **Reem Fahd Bunyan:** Methodology, Investigation, Writing – original draft, Writing – review & editing. **Mona Al Faraidy:** Investigation, Writing – original draft, Writing – review & editing. **Nayef Bin Dajim:** Investigation, Formal analysis, Writing – original draft, Writing – review & editing. **Fahad A. Al Mulhim:** Investigation, Formal analysis, Writing – original draft, Writing – review & editing. **Haitham H. Alnemari:** Investigation, Writing – original draft, Writing – review & editing. **Shahid Bashir:** Methodology, Formal analysis, Writing – original draft, Writing – review & editing.

REFERENCES

- Roaf R. The basic anatomy of scoliosis. *J Bone Joint Surg Br.* 1966;48:786-792.
- Dickson RA, Lawton JO, Archer IA, Butt WP. The pathogenesis of idiopathic scoliosis: biplanar spinal asymmetry. *J Bone Joint Surg Br.* 1984;66:8-15.
- de Jonge T, Dubouset JF, Illés T. Sagittal plane correction in idiopathic scoliosis. *Spine (Phila Pa 1976).* 2002;27:754-760.
- Kim YJ, Lenke LG, Bridwell KH, Cho YS, Riew KD. Free hand pedicle screw placement in the thoracic spine: is it safe? *Spine (Phila Pa 1976).* 2004;29:333-342.
- Imrie M, Yaszay B, Bastrom TP, Wenger DR, Newton PO. Adolescent idiopathic scoliosis: should 100% correction be the goal? *J Pediatr Orthop.* 2011;31(1 Suppl):S9-S13.
- Sucato DJ, Agrawal S, O'Brien MF, Lowe TG, Richards SB, Lenke L. Restoration of thoracic kyphosis after operative treatment of adolescent idiopathic scoliosis: a multicenter comparison of three surgical approaches. *Spine (Phila Pa 1976).* 2008;33:2630-2636.
- Shah SA, Dhaeale AA, Oda JE, et al. Ponte osteotomies with pedicle screw instrumentation in the treatment of adolescent idiopathic scoliosis. *Spine Deform.* 2013;1:196-204.
- Feng J, Zhou J, Huang M, Xia P, Liu W. Clinical and radiological outcomes of the multilevel Ponte osteotomy with posterior selective segmental pedicle screw constructs to treat adolescent thoracic idiopathic scoliosis. *J Orthop Surg Res.* 2018;13:305.
- Vora V, Crawford A, Babekhir N, et al. A pedicle screw construct gives an enhanced posterior correction of adolescent idiopathic scoliosis when compared with other constructs: myth or reality. *Spine (Phila Pa 1976).* 2007;32:1869-1874.
- Cidambi KR, Glaser DA, Bastrom TP, Nunn TN, Ono T, Newton PO. Postoperative changes in spinal rod contour in adolescent idiopathic scoliosis: an in vivo deformation study. *Spine (Phila Pa 1976).* 2012;37:1566-1572.
- Liu RW, Yaszay B, Glaser D, et al. A method for assessing axial vertebral rotation based on differential rod curvature on the lateral radiograph. *Spine (Phila Pa 1976).* 2012;37:E1120-E1125.
- Le Navéaux F, Aubin CE, Parent S, Newton PO, Labelle H. 3D rod shape changes in adolescent idiopathic scoliosis instrumentation: how much does it impact correction? *Eur Spine J.* 2017;26:1676-1683.
- Samdani AF, Bennett JT, Singla AR, et al. Do Ponte osteotomies enhance correction in adolescent idiopathic scoliosis? An analysis of 191 Lenke 1A and 1B curves. *Spine Deform.* 2015;3:483-488.
- Hyun SJ, Kim YJ, Cheh G, Yoon SH, Rhim SC. Free hand pedicle screw placement in the thoracic spine without any radiographic guidance: technical note, a cadaveric study. *J Korean Neurosurg Soc.* 2012;51:66-70.

Conflict of interest statement: The authors declare that the article content was composed in the absence of any commercial or financial relationships that could be construed as a potential conflict of interest.

Received 18 January 2022; accepted 19 April 2022

Citation: *World Neurosurg.* X (2022) 15:100125.
<https://doi.org/10.1016/j.wnsx.2022.100125>

Journal homepage: www.journals.elsevier.com/world-neurosurgery-x

Available online: www.sciencedirect.com

2590-1397/© 2022 The Author(s). Published by Elsevier Inc. This is an open access article under the CC BY-NC-ND license (<http://creativecommons.org/licenses/by-nc-nd/4.0/>).