



Case Report

Cutaneous myiasis in an elderly woman in Somaliland☆☆☆

Mukhtar A. Yusuf, MD^a, Bobbi S. Pritt, MD^b, Josette R. McMichael, MD^{c,*}^a Amoud University College of Health Sciences, Borama, Somaliland^b Department of Laboratory Medicine and Pathology, Mayo Clinic, Rochester, Minnesota^c Department of Dermatology, Emory University, Atlanta, Georgia

ARTICLE INFO

Article history:

Received 20 December 2018

Received in revised form 3 April 2019

Accepted 4 April 2019

Keywords:

myiasis

cutaneous myiasis

furuncular myiasis

tumbu fly

fly larvae

Somaliland

ABSTRACT

Background: Cutaneous myiasis is a self-limited skin infestation by developing fly larvae, with three clinical subtypes: furuncular, migratory, and wound myiasis. Furuncular myiasis is endemic throughout much of Africa; however, few reports are from the Horn of Africa.

Clinical presentation: An 85-year-old woman in Somaliland presented with a 12-day history of multiple painful and pruritic nodules on the temple, arm, chest, breast, flank, and legs. The posterior of a larva was visible within several lesions. One larva was extracted from an arm nodule and identified as *Cordylobia anthropophaga* (tumbu fly) by morphologic examination. The patient was instructed to occlude the other nodules with petroleum jelly and return in 3 days. Instead, she visited a traditional healer who extracted the remaining larvae.

Conclusions: We present a case of furuncular cutaneous myiasis due to *Cordylobia anthropophaga*. Treatment options for this infestation include occlusion with petroleum jelly to cause larvae to exit, surgical extraction, and oral ivermectin. Occlusion may not be acceptable for some patients. Extraction may cause significant inflammatory response if the larva is damaged during the process. To our knowledge, this is the first published report of myiasis in Somaliland, although it is probably underreported. Myiasis is a common dermatosis associated with travel to endemic areas. Furuncular myiasis can easily be misdiagnosed as furunculosis or cellulitis. Dermatologists must be familiar with the clinical features and management of this dermatosis.

© 2019 Published by Elsevier Inc. on behalf of Women's Dermatologic Society. This is an open access article under the CC BY-NC-ND license (<http://creativecommons.org/licenses/by-nc-nd/4.0/>).

Introduction

Cutaneous myiasis is a self-limited skin infestation by developing fly larvae, with three clinical subtypes: furuncular, migratory, and wound myiasis. Furuncular myiasis is mainly caused by *Dermatobia hominis* (botfly) larva in South and Central America, whereas *Cordylobia anthropophaga* (tumbu fly or mango fly) is the most common cause in Africa (McGraw and Turiansky, 2008). *C. anthropophaga* causes myiasis when eggs laid on wet clothing in the shade or soil contaminated with urine and feces come into contact with host skin. The eggs then hatch to release larvae that penetrate the unbroken skin of the host. The larvae grow and mature within the skin of the host until they are ready to enter the pupa form, at which time they emerge and drop off into the environment. Eventually the adult fly emerges from the pupa, allowing the fly's lifecycle to continue (McGraw and Turiansky, 2008).

Human infestation occurs most commonly during the rainy season. Unlike *D. hominis*, *C. anthropophaga* infestation occurs primarily on covered areas of the body and often has multiple lesions. Furuncular myiasis is endemic throughout much of Africa (Blaizot et al., 2018). However, few reports are from the Horn of Africa (Djibouti, Eritrea, Ethiopia, and Somalia).

Somaliland is a self-governing region of northwest Somalia. To our knowledge, reports of myiasis in Somaliland have not been published. No results of myiasis were found while conducting an advanced PubMed search using the terms “Somaliland,” “myiasis,” “cutaneous myiasis,” and “furuncular myiasis.” For Somalia, one report was published about a returning traveler in the United Kingdom with myiasis of the penis (Pepper et al., 2008). Herein, we report on a case in Somaliland of multiple furuncular myiasis in an elderly woman.

Clinical presentation

An 85-year-old woman presented to the dermatology clinic during the rainy season with a 12-day history of multiple painful and pruritic nodules. She reported movement within the lesions. She denied travel outside of Somaliland.

☆ Sources of support: This research did not receive any specific grant from funding agencies in the public, commercial, or not-for-profit sectors.

☆☆ Conflicts of interest: The authors have no conflicts of interest to report.

* Corresponding Author:

E-mail address: jmcmichael@emory.edu. (J.R. McMichael).

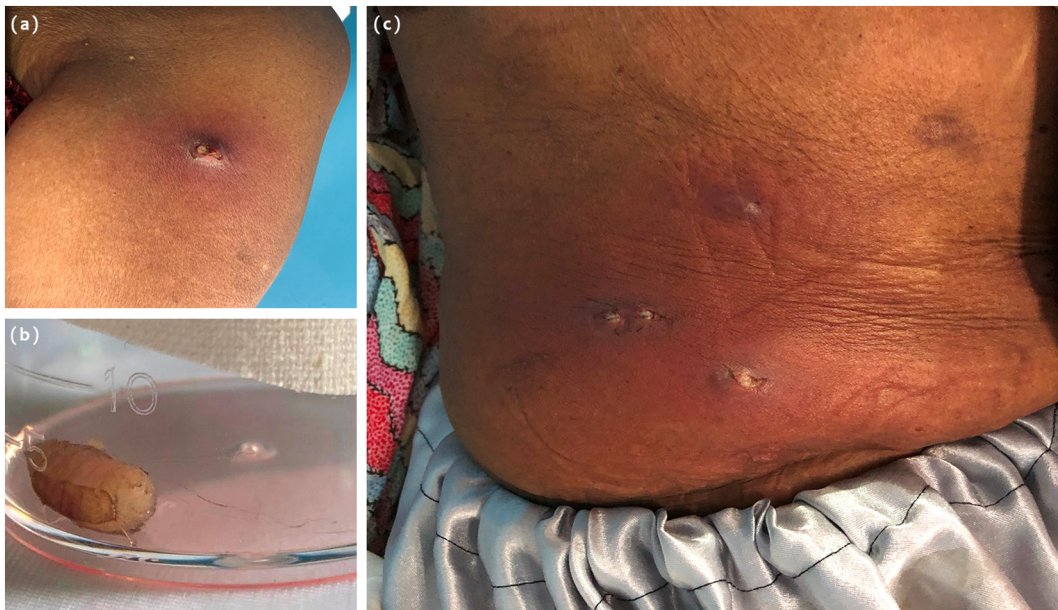


Fig. 1. (A) Tender, pruritic furuncular nodule with surrounding erythema on the left upper anterior arm. The posterior aspect of the larva is seen through an opening in the skin, which allowed for continued contact with air. Larvae mature in the skin for 8 to 12 days before they emerge from the skin. This larva was at a late stage and was easily extracted using a surgical blade and forceps. (B) Live *Cordylobia anthropophaga* larva immediately after extraction. (C) Multiple furuncular nodules with surrounding erythema, induration, and increased warmth on the right flank. The larvae are visible through openings in the skin.

Upon physician examination, 11 erythematous tender nodules, 1 to 2 cm in size and with central puncta, were observed on the patient's temple, arm, chest, breast, flank, and legs. Within several lesions, the posterior of a larva was visible. The right flank was erythematous and indurated (Fig. 1). After local anesthesia with 1% lidocaine, the arm nodule was incised with a surgical blade, and a larva was extracted using forceps. At this time, the patient requested extraction of all larvae. However, extraction may cause tissue trauma,

considerable inflammatory response if the larva is mutilated and not fully removed, and secondary infection. Therefore, for this elderly patient, we advised application of petroleum jelly to the rest of the nodules and a return in 3 days for extraction of any remaining larva. Cephalexin was prescribed due to concern for cellulitis of the right flank.

The extracted larva was placed in a clean container (Fig. 1), to which formalin was added 5 days later. The larva was sent to Mayo

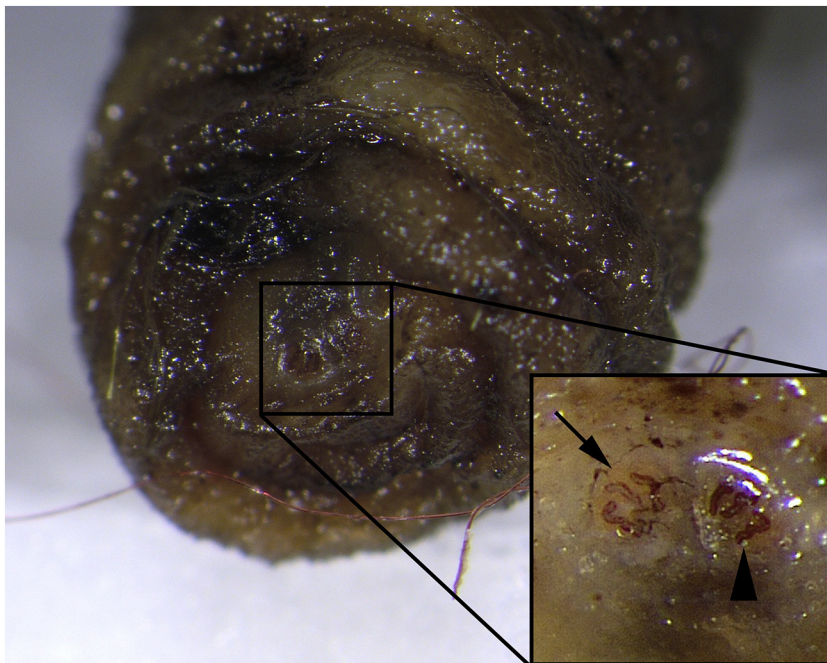


Fig. 2. Posterior aspect of the larva demonstrating the posterior spiracular plates (box and inset) from which a definitive identification can be made. The inset demonstrates the sinuous nature of the three spiracular slits in one of the spiracular plates (arrow head) and lack of a distinct outline (peritreme) of the spiracles (arrow). *C. anthropophaga* can be differentiated from the similar-appearing species, *C. rodhaini*, by its much more sinuous slits. (Photo and identification of larva by Bobbi Pritt, MD, and Heather Arguello, MT (ASCP), at Mayo Clinic Laboratories in Rochester, Minnesota.)

Clinic Laboratories, where it was identified as *C. anthropophaga* based on macroscopic and microscopic features (Fig. 2). The patient did not return for follow up. Later, a family member informed us she had visited a traditional healer who extracted the remaining larvae by an unknown method. The lesions healed well, and no new ones developed.

Conclusions

We present a case of furuncular myiasis in a patient living in Somaliland. If the posterior end of the larvae were not visible, the clinical differential would have included arthropod bites, furunculosis, and causes of cutaneous abscesses, with or without cellulitis. Diagnosis can usually be made with visual inspection, but dermoscopy may facilitate the diagnosis by magnifying the area and possibly by increasing the frequency of larval movements from occlusion of the skin punctum by the lens of a contact dermatoscope (Bakos and Bakos, 2007).

Furuncular myiasis is usually self-limited. Treatment options include 1) occlusion with petroleum jelly to cause larval anoxia and spontaneous exit, 2) surgical extraction, and 3) oral ivermectin. Tetanus vaccination should be considered if not previously administered as recommended. Antibiotics may also be considered when signs of cellulitis are present, such as in this case.

Occlusion is typically required for several hours to 24 hours and may not be acceptable for some patients due to intense anxiety over the movement of the larvae and other bothersome symptoms. Our patient chose not to wait and sought extraction of the larvae from a traditional healer who may or may not have been trained in surgical techniques. Sometimes the larvae die before they emerge, which may create a robust foreign body inflammatory response.

Extraction may cause a significant inflammatory response if the larva is damaged in the process. Extraction is easier if the larva is at a more mature stage. Ivermectin, if not larvicidal, should cause the exit of the larva (McGraw and Turiansky, 2008). It is usually reserved for cases with multiple lesions. Ivermectin was not available at our location.

Preventive measures include keeping clothing off the ground, hanging clothing to dry in sunlight or inside with the windows closed, and ironing clothing prior to wear to kill eggs that may be present (McGraw and Turiansky, 2008).

To our knowledge, this is the first published report of myiasis in Somaliland. Because people commonly seek care from traditional healers or await spontaneous resolution, cutaneous myiasis is probably underreported in Somaliland and perhaps throughout the Horn of Africa. One study reported that myiasis is the fourth most common dermatosis associated with travel (Caumes et al., 1995).

Furuncular myiasis can easily be misdiagnosed as furunculosis or cellulitis. Dermatologists and other health care professionals must be familiar with the clinical features and management. Particularly for the elderly population and those with a significant risk for infection, public education on the importance of seeking care from a trained health care professional may be beneficial to avoid complications.

Acknowledgments

The authors are grateful to Dr. Mona A. Abdillahi for obtaining follow-up information on our patient and Heather Arguello for photography and identification of the *C. anthropophaga* larva.

References

- Bakos R, Bakos L. Dermoscopic diagnosis of furuncular myiasis. *Arch Dermatol* 2007; 143(1):123–4.
- Blaizot R, Vanhecke C, Le Gall P, Duvignaud A, Receveur MC, Malvy D. Furuncular myiasis for the Western dermatologist: Treatment in outpatient consultation. *Int J Dermatol* 2018;57(2):227–30.
- Caumes E, Carrière J, Guernonprez G, Bricaire F, Danis M, Gentilini M. Dermatoses associated with travel to tropical countries: A prospective study of the diagnosis and management of 269 patients presenting to a tropical disease unit. *Clin Infect Dis* 1995;20(3):542–8.
- McGraw TA, Turiansky GW. Cutaneous myiasis. *J Am Acad Dermatol* 2008;58(6): 907–26.
- Pepper WC, Benaragama SK, Kalsi JS, Karim O. Cutaneous myiasis of *Cordylobia anthropophaga*. *Urology* 2008;72(1):65.