

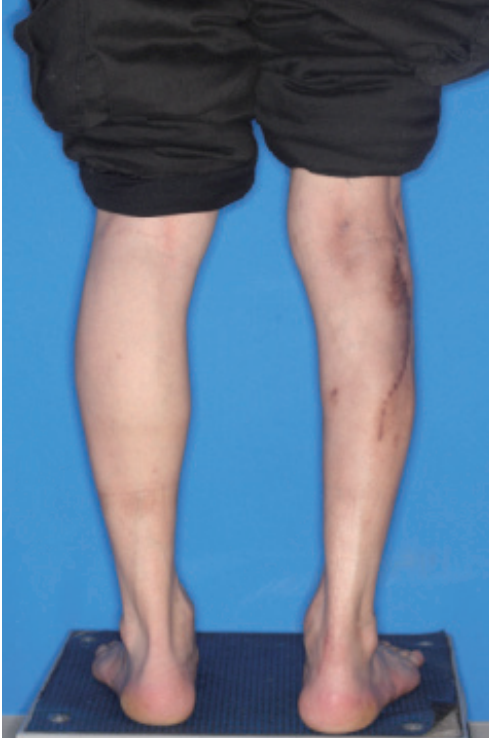

Fig. 5.
Postoperative photograph. Six months after operation.

A search of PubMed articles published from 1970 to 2012 identified 208 cases of ancient hematoma. Of these, 79 cases were in the brain, 59 cases were in the thorax, 36 cases were in the lower extremity, 10 cases were in the abdomen, and 24 cases were in the upper extremity. Only three cases originated from the calf. Of the three cases, one involved a 75-year-old male who received coumadin therapy for deep vein thrombosis. The second case involved a 76-year-old male who had experienced trauma on the soleus muscle 34 years previously. During surgery to remove the hematoma, the soleus muscle was completely resected. The report of the third case did not describe the patient's history. Unlike the other reported cases we reviewed in the literature, the present case had no bleeding risk, including old age. Although we resected the lateral head of the gastrocnemius muscle and calf, healing occurred without motor or sensory dysfunctions.

Hematoma commonly arises right after trauma or operation. The protracted time after trauma or the inability to identify the nature of prior surgery makes it difficult to diagnose an ancient hematoma. A calf is not a common part of the body from which a hematoma originates. The present case had no bleeding risk including old age, which makes the

diagnosis more difficult. As far as we know, this is the first case report of ancient hematoma originating from the calf in a patient, who was not in old age and had no other bleeding risk.

References

1. Mentzel T, Goodlad JR, Smith MA, et al. Ancient hematoma: a unifying concept for a post-traumatic lesion mimicking an aggressive soft tissue neoplasm. *Mod Pathol* 1997;10:334-40.
2. Reid JD, Kommareddi S, Lankerani M, et al. Chronic expanding hematomas. A clinicopathologic entity. *JAMA* 1980;244:2441-2.
3. Labadie EL, Glover D. Physiopathogenesis of subdural hematomas. Part 1: Histological and biochemical comparisons of subcutaneous hematoma in rats with subdural hematoma in man. *J Neurosurg* 1976;45:382-92.
4. Negoro K, Uchida K, Yayama T, et al. Chronic expanding hematoma of the thigh. *Joint Bone Spine* 2012;79:192-4.

Salivary Duct Carcinoma of the Deep Lobe of the Parotid Gland: A Rare Clinical Finding

Hi-Jin You, Tae-Kyoung Yun, Seong-Ho Jeong, Eun-Sang Dhong, Seung-Kyu Han

Department of Plastic Surgery, Korea University College of Medicine, Seoul, Korea

Correspondence: Hi-Jin You
Department of Plastic Surgery, Korea University Ansan Hospital, 123 Jeokgeum-ro, Danwon-gu, Ansan 15355, Korea
Tel: +82-31-412-4288, Fax: +82-31-475-5074, E-mail: hijinyou@gmail.com

This article was presented at the Fourth Research and Reconstructive Forum on April 3-4, 2014, in Busan, Korea.

No potential conflict of interest relevant to this article was reported.

Received: 21 Jan 2015 • Revised: 10 Apr 2015 • Accepted: 7 May 2015
pISSN: 2234-6163 • eISSN: 2234-6171
<http://dx.doi.org/10.5999/aps.2016.43.1.107>
Arch Plast Surg 2016;43:107-110



Copyright © 2016 The Korean Society of Plastic and Reconstructive Surgeons
This is an Open Access article distributed under the terms of the Creative Commons Attribution Non-Commercial License (<http://creativecommons.org/licenses/by-nc/3.0/>) which permits unrestricted non-commercial use, distribution, and reproduction in any medium, provided the original work is properly cited.

Salivary duct carcinoma is a rare malignant tumor that resembles high-grade breast ductal carcinoma. It was first described by Kleinsasser et al. [1] in 1968,

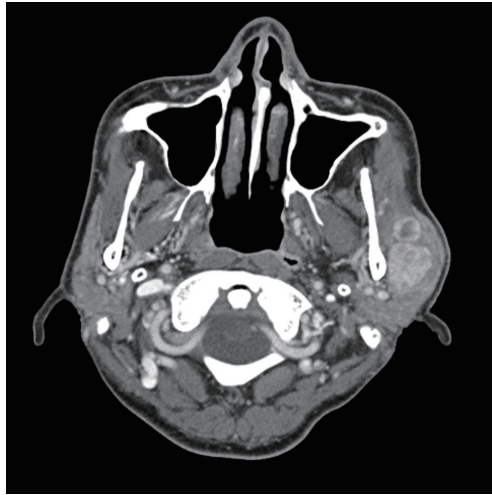


Fig. 1.
Computed tomography scan showing a solid mass in the left parotid gland.

and is characterized by aggressive behavior, early metastasis, local recurrence, and a high mortality rate. It most commonly occurs in the parotid gland. Previously reported cases of salivary duct carcinomas involved only the superficial lobe of the parotid gland or both the superficial and deep lobes [2]. This study reports an unusual case of salivary duct carcinoma confined to the deep lobe of the parotid gland.

A 59-year-old man presented with a long history of a painless lump on the left preauricular area that had gradually enlarged over the previous year. He denied pain, numbness, and facial weakness. Physical examination showed a well-defined 4 × 3-cm mass in the left parotid region. The mass was firm, non-compressible, and non-tender on palpation. His left facial nerve function was intact (House-Brackmann grade 1). Neither cervical lymphadenopathy nor abnormalities within the oral cavity were found. Fine needle aspiration, which is not diagnostic, was not performed. Computed tomography (CT) (Fig. 1) revealed a 2.5 × 3.2 × 4.1-cm, well-enhanced, huge, lobulated, and predominantly solid tumor in the superficial lobe of the left parotid gland. The preoperative laboratory data, including electrocardiography, urinalysis, and a chest radiograph, were unremarkable. A benign tumor, such as pleomorphic adenoma, was strongly suspected, and the patient was therefore taken to the operating room with the intention of performing a left superficial parotidectomy. During the operation, the branches of the facial nerve were preserved via a modified Blair incision. Subsequently, tumor involvement in the deep parotid lobe was identified (Fig. 2). Malignancy was identified in the frozen section of a sample taken from the mass located on

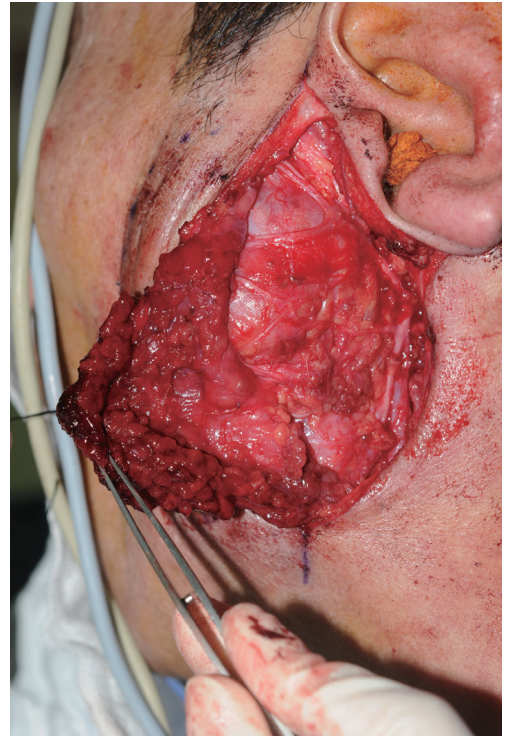

Fig. 2.
Intraoperative photograph showing the mass located on the deep lobe of the parotid gland. The forceps are shown retracting the superficial lobe.

the deep lobe. The excision of the superficial part of the parotid gland was completed, the branches of the facial nerve were subsequently elevated, and the deep lobe of the parotid gland was resected. The lesion was classified as cT2NxM0.

The gross specimen showed a roughly ovoid, nodular, gray-white mass with an irregular border (Fig. 3). The histology report indicated that the tumor was an invasive ductal lesion with cribriform patterns and comedonecrosis (Fig. 4). The resected superficial lobe showed a normal parotid architecture and no tumor. The final diagnosis was salivary duct carcinoma of the deep lobe of the left parotid gland. One of the surgical margins was focally positive for malignancy. No perineural invasion or lymphovascular involvement was found. Control chest CT and positron emission tomography (PET)-CT were negative. Since postoperative CT and magnetic resonance imaging revealed no definitive evidence of perineural spread or metastatic lymphadenopathy, elective neck dissection was not performed. The patient received postoperative chemoradiation therapy with 60 Gy administered in 30 fractions and biweekly cisplatin monotherapy.

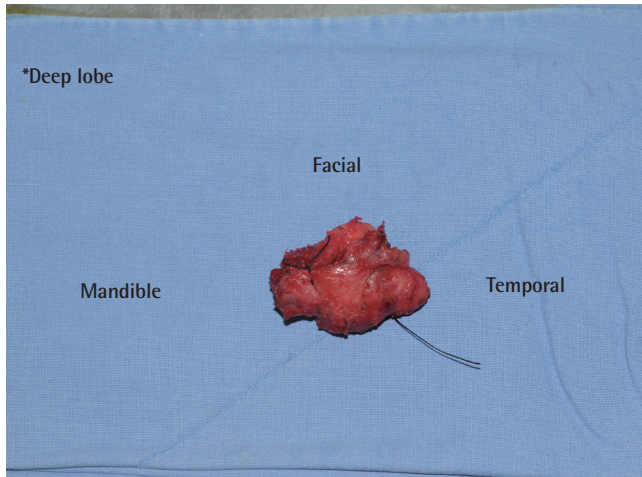


Fig. 3.
Gross specimen of the deep lobe of the parotid gland.

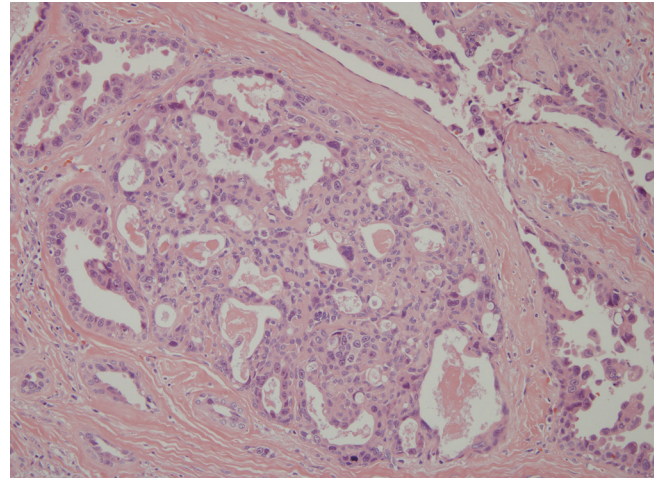


Fig. 4.
Histological features (H&E, $\times 200$) of salivary duct carcinoma, showing a cribriform pattern.

Following temporary facial nerve paralysis (House-Brackmann grade IV), the patient recovered fully functional left facial movement (House-Brackmann grade I) five months after the operation. He has received regular follow-up for one year with no signs of recurrence or metastasis.

Salivary duct carcinoma represents < 1.8% of all major salivary gland tumors. It mainly affects men (73%) in their seventh decade of life. Although it predominantly arises in the parotid gland (72%), the submandibular glands and minor salivary glands may occasionally be involved [2]. It may develop on the basis of pre-existing pleomorphic adenoma in some cases (20%), but generally occurs *de novo* [3]. Clinically, these tumors are typically characterized by a rapidly growing mass with pain, palpable cervical lymphadenopathy, and facial nerve dysfunction. Fine needle aspiration rarely leads to a diagnosis of salivary duct carcinoma. The finding of tumoral calcifications on CT scans may be suggestive in only 33% of cases. Histologically, these tumors appear as high-grade adenocarcinoma, resembling mammary ductal carcinoma with duct formation. They are solid, with a papillary or cribriform growth pattern and intraductal comedonecrosis. Several histological variants have been described, including mucin-rich, sarcomatoid, and micropapillary types. Perineural invasion has been reported in 60% of cases, and around 30% of cases show lymphovascular invasion [3]. Although total parotidectomy with or without neck dissection and postoperative radiation therapy is the standard treatment, the local recurrence rate is high, associated with both cervical nodal involvement and distant

metastasis, and resulting in a poor prognosis.

Chemotherapy is generally reserved for metastatic forms [4]. Some recent studies have shown favorable treatment results using trastuzumab-based therapy.

Deep lobe parotid gland tumors are rare, comprising approximately 5% of parotid gland tumors. Approximately 80%–90% of them are benign mixed tumors, such as pleomorphic adenoma, and the others are adenoid cystic, mucoepidermoid, and acinic cell carcinoma, as well as lipoma [5]. Their outward growth displaces the superficial lobe, and they therefore present as a soft preauricular mass. Deep lobe parotid tumors presenting as preauricular masses are often clinically indistinguishable from lesions of the superficial lobe, making it difficult to establish a definitive preoperative diagnosis of a lesion lying deep to the facial nerve.

Based on a literature review, the salivary duct carcinoma presented in this report is unusual, because it arose in the deep lobe of the parotid gland, did not correlate with CT findings, and presented with no symptoms and an absence of perineural and lymphovascular involvement. Therefore, a better prognosis may be expected than is commonly observed in cases of salivary duct carcinoma. This case was reported because of its rarity, and also to add one more case to the existing literature on these tumors.

References

1. Kleinsasser O, Klein HJ, Hubner G. Salivary duct carcinoma: a group of salivary gland tumors analogous

to mammary duct carcinoma. Arch Klin Exp Ohren Nasen Kehlkopfheilkd 1968;192:100-5.

- Jayaprakash V, Merzianu M, Warren GW, et al. Survival rates and prognostic factors for infiltrating salivary duct carcinoma: Analysis of 228 cases from the Surveillance, Epidemiology, and End Results database. Head Neck 2014;36:694-701.
- Wee DT, Thomas AA, Bradley PJ. Salivary duct carcinoma: what is already known, and can we improve survival? J Laryngol Otol 2012;126 Suppl 2:S2-7.
- Salovaara E, Hakala O, Back L, et al. Management and outcome of salivary duct carcinoma in major salivary glands. Eur Arch Otorhinolaryngol 2013;270:281-5.
- Carr RJ, Bowerman JE. A review of tumours of the deep lobe of the parotid salivary gland. Br J Oral Maxillofac Surg 1986;24:155-68.

Low-Grade Fibromyxoid Sarcoma of the Malar Area

Jun Ho Lee¹, Hwan Jun Choi¹, Hae Yoen Jung²

Departments of ¹Plastic and Reconstructive Surgery and ²Pathology, Soonchunhyang University College of Medicine, Cheonan, Korea

Correspondence: Hwan Jun Choi

Department of Plastic and Reconstructive Surgery, Soonchunhyang University College of Medicine, 31 Soonchunhyang 6gil, Dongnam-gu, Cheonan 31151, Korea

Tel: +82-41-570-2195, Fax: +82-41-574-6133, E-mail: medi619@hanmail.net

This work was supported by the Soonchunhyang University Research Fund.

No potential conflict of interest relevant to this article was reported.

Received: 8 Apr 2015 • Revised: 11 Jun 2015 • Accepted: 19 Jun 2015
pISSN: 2234-6163 • eISSN: 2234-6171
<http://dx.doi.org/10.5999/aps.2016.43.1.110>
Arch Plast Surg 2016;43:110-112



Copyright © 2016 The Korean Society of Plastic and Reconstructive Surgeons
This is an Open Access article distributed under the terms of the Creative Commons Attribution Non-Commercial License (<http://creativecommons.org/licenses/by-nc/3.0/>) which permits unrestricted non-commercial use, distribution, and reproduction in any medium, provided the original work is properly cited.

A 34-year-old female patient presented with a mass on the left malar area that had been palpable for 1 year. The mass had enlarged slowly. The patient complained of discomfort and had aesthetic concerns because of the increased size of the mass. She had no specific medical history. However, the patient had a history of trauma on the ipsilateral oral cavity at puberty. A physical examination revealed that there was a movable soft mass with a diameter of 2 cm and

normal-appearing skin. There was no discoloration, erythema, and inflammation. On computed tomography (CT), a slightly diffuse enhancing low-density mass was seen on the subcutaneous layer adjacent to the zygomaticus muscle (Fig. 1). Removal of the mass was performed under general anesthesia by using an intraoral approach and a pull-through technique with a gingivobuccal incision. The mass was not easily separated from the surrounding tissues and zygomaticus muscles. The margin of the mass was intermingled with the surrounding fibrous tissue (Fig. 2). The lesion was completely excised with no remarkable occurrences (Fig. 3). Grossly, the mass was round, with a diameter of 1.3 cm. The gross findings of the mass included a well-circumscribed, oval-to-round mass with a thin, fibrous pseudo-capsule. The cut surface showed a whorled, white-gray, firm, and fibrous consistency with a homogenous appearance. A histological examination revealed a well-circumscribed mass with no capsulation (Fig. 4). The tumor primarily had a myxoid appearance and was hyper-cellular with bland spindle cells; it had minimal cytologic atypia, generally low mitotic activity and no necrosis, but there were abrupt transitions to collagen rosettes, which was a heavily collagenized area with sparse cellularity. The vasculature in the tumor showed an arcade appearance with hyalinization (Fig. 5). An immunohistochemical study showed that the tumor cells were focally positive for smooth muscle actin but negative for S-100, desmin, and CD34. The

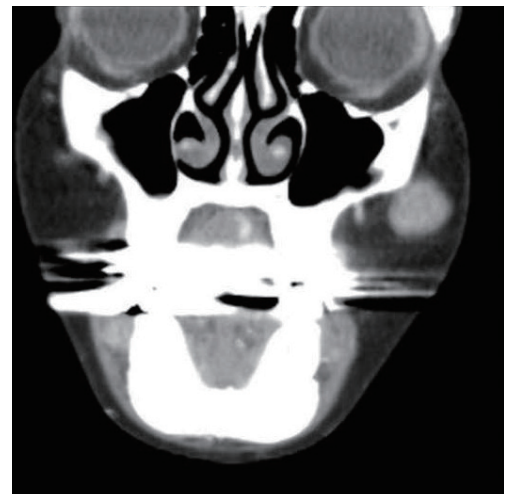

Fig. 1.

A computed tomography image of the mass: a slightly diffuse enhancing low-density mass on the left malar area on the coronal view.