

Case report

# Methotrexate-associated lymphoproliferative disorder demonstrating composite lymphoma of EBV-negative diffuse large B-cell lymphoma and EBV-positive mucocutaneous ulcer

Keiichi Moriya,<sup>1,2)</sup> Yara Yukie Kikuti,<sup>2)</sup> Joaquim Carreras,<sup>2)</sup> Yusuke Kondo,<sup>2)</sup>  
Sawako Shiraiwa,<sup>3)</sup> Naoya Nakamura<sup>2)</sup>

Other iatrogenic immunodeficiency-associated lymphoproliferative disorders induced by immunosuppressive drugs, such as methotrexate (MTX-LPD), exhibit numerous pathological findings. We report the case of an 81-year-old Japanese woman diagnosed with MTX-LPD exhibiting two distinct pathological features from two different sites. Excisional biopsy of the left cervical lymph node revealed EBV-negative diffuse large B-cell lymphoma and biopsy of a pharyngeal ulcer revealed EBV-positive mucocutaneous ulcer. She was treated using an R-CHOP regimen and maintained complete remission for years. This case demonstrates the heterogeneous pathology of MTX-LPD and suggests the necessity of multiple biopsies.

**Keywords:** Other iatrogenic immunodeficiency-associated lymphoproliferative disorders, methotrexate, diffuse large B-cell lymphoma, EBV-positive mucocutaneous ulcer, Epstein-Barr virus

## INTRODUCTION

Other iatrogenic immunodeficiency-associated lymphoproliferative disorders (Oiiia-LPD) has been defined as lymphoproliferative disorders or lymphomas developing in patients receiving immunosuppressive drugs for autoimmune diseases or conditions other than in the post-transplant setting.<sup>1</sup> In particular, many rheumatoid arthritis (RA) patients are treated using methotrexate (MTX). The pathological features of MTX-LPD vary. Histology of diffuse large B-cell lymphoma (DLBCL) is predominant, followed by that of classic Hodgkin lymphoma (CHL).<sup>1,2</sup>

Among the different types of MTX-LPD, composite lymphoma of MTX-LPD has rarely been reported.<sup>3-7</sup> All cases except one were a composite of B-cell lymphoma and T-cell lymphoma.<sup>3-6</sup> The other was a composite of DLBCL and follicular lymphoma (FL).<sup>7</sup> There has been no report of a case with Epstein-Barr virus (EBV)-positive mucocutaneous ulcers (EBVMCU). EBVMCU were recently reported to develop as MTX-LPD. EBVMCU are characterized by the proliferation of EBV-positive B-cells that exhibit almost the

same histology as lymphoma and spontaneously regress.<sup>8</sup>

Although MTX withdrawal is the first choice for patients with MTX-LPD leading to tumor regression, the rate of complete remission (CR) is not high.<sup>1,9</sup> Chemotherapy is required for these patients, but there is no standard regimen.<sup>10</sup> The choice of regimen in each case is usually based on the pathological diagnosis such as DLBCL and CHL.<sup>9</sup> Pathological diagnosis of MTX-LPD is important, but the relationship between pathological findings and clinical courses of MTX-LPD is unclear.

We report a case of composite lymphoma in a patient with MTX-LPD. Two biopsies from different sites demonstrated DLBCL with EBV-negative and EBV-positive MCU. Multiple biopsy may be important for MTX-LPD, and we discuss chemotherapy in regards to coincidental pathological features.

## CASE PRESENTATION

An 81-year-old Japanese woman had a medical history of RA, hypertension, and hyperlipidemia. She had not received

Received: October 13, 2019. Revised: December 30, 2019. Accepted: January 15, 2020. Online Published: March 28, 2020


DOI:10.3960/jslrt.19038

<sup>1)</sup>Department of Hematology, Shinmatsudo Central General Hospital, Matsudo, Japan, <sup>2)</sup>Department of Pathology, Tokai University School of Medicine, Isehara, Japan, <sup>3)</sup>Department of Hematology and Oncology, Tokai University School of Medicine, Isehara, Japan

**Corresponding author:** Naoya Nakamura, Department of Pathology, Tokai University School of Medicine, 143 Shimokasuya Isehara-shi Kanagawa, 259-1193, Japan.

E-mail: naoya@is.icc.u-tokai.ac.jp

Copyright © 2020 The Japanese Society for Lymphoreticular Tissue Research

 This work is licensed under a Creative Commons Attribution-NonCommercial-ShareAlike 4.0 International License.

therapy for rheumatoid arthritis for years, but felt joint pain and swelling from 6 years before the first visit to the hematologist. She was administered oral methotrexate at 4 mg per week and prednisolone at 5 mg per day. These drugs were adjusted for her symptoms, and the final doses were methotrexate at 8 mg per week and prednisolone at 2.5 mg per day.

She came to our hospital for swelling of the left axillary mass. Physical examination revealed painless bilateral axillary lymph node swelling, which her attending physician thought to be OIia-LPD. MTX was withdrawn immediately, and prednisolone was increased to 5 mg per day. She was followed up after 2 weeks for judgment of MTX withdrawal. Progression of axillary lymph node swelling was noted and new cervical lymph node swelling was evident. She was referred to a hematologist immediately. Blood testing and computed tomography were performed to evaluate lymph node localization. Main laboratory findings at that time were as follows: hemoglobin 12.2 g/dL (normal range, 11.5-15.5), serum lactate dehydrogenase 405 U/L (110-219), C-reactive protein 1.52 mg/dL (< 0.30), rheumatoid factor 17 IU/ml (< 20), and soluble interleukin-2 receptor 1830 U/mL (145-519) (Table 1). Computed tomography revealed splenomegaly, and bilateral cervical, axillary, mediastinal, intrapelvic, and inguinal lymph node swelling (Figure 1a, b). She was referred to an otolaryngologist for cervical lymph node biopsy, and laryngoscopy as a routine test before biopsy was carried out. Cryptogenic bilateral pharyngeal ulcers were found, and a biopsy sample from the right ulcer was taken for diagnosis. Then, excisional biopsy of left cervical lymph node was performed 11 days after pharyngeal ulcer biopsy.

After the diagnosis of MTX-LPD, surface lymph nodes slightly decreased in size, but the soluble interleukin-2 receptor level markedly increased from 1,830 to 6,260 U/ml.

Positron emission tomography – computed tomography (PET-CT) revealed FDG uptake in systemic lymph nodes, spleen, tonsils, and upper limbs (Figure 1c). The hematologist decided to administer chemotherapy and she received 6 courses of R-CHOP therapy. She did not wish to consult an otolaryngologist again, but all FDG uptake, including in the pharyngeal area, disappeared after R-CHOP therapy. She is currently in CR.

## PATHOLOGICAL FINDINGS

Right pharyngeal biopsy demonstrated an ulcer with partially missing squamous epithelium. Diffuse infiltration of many small lymphocytes with intermingled large-sized lymphocytes was observed. On immunohistochemistry, there were many CD3(+) small-sized T-cells and scattered CD20(+) large-sized B-cells. The latter were CD3(-), CD5(-), CD10(-), CD20(+), BCL2(+), BCL6(+), and MUM1(+). MIB1 reacted with almost all large lymphocytes (>95%). EBER *in situ* hybridization (ISH) demonstrated positive signals in large-sized B-cells with expression of LMP1 and EBNA2, indicating Latency III. The diagnosis of EBVMCU was made (Figure 2).

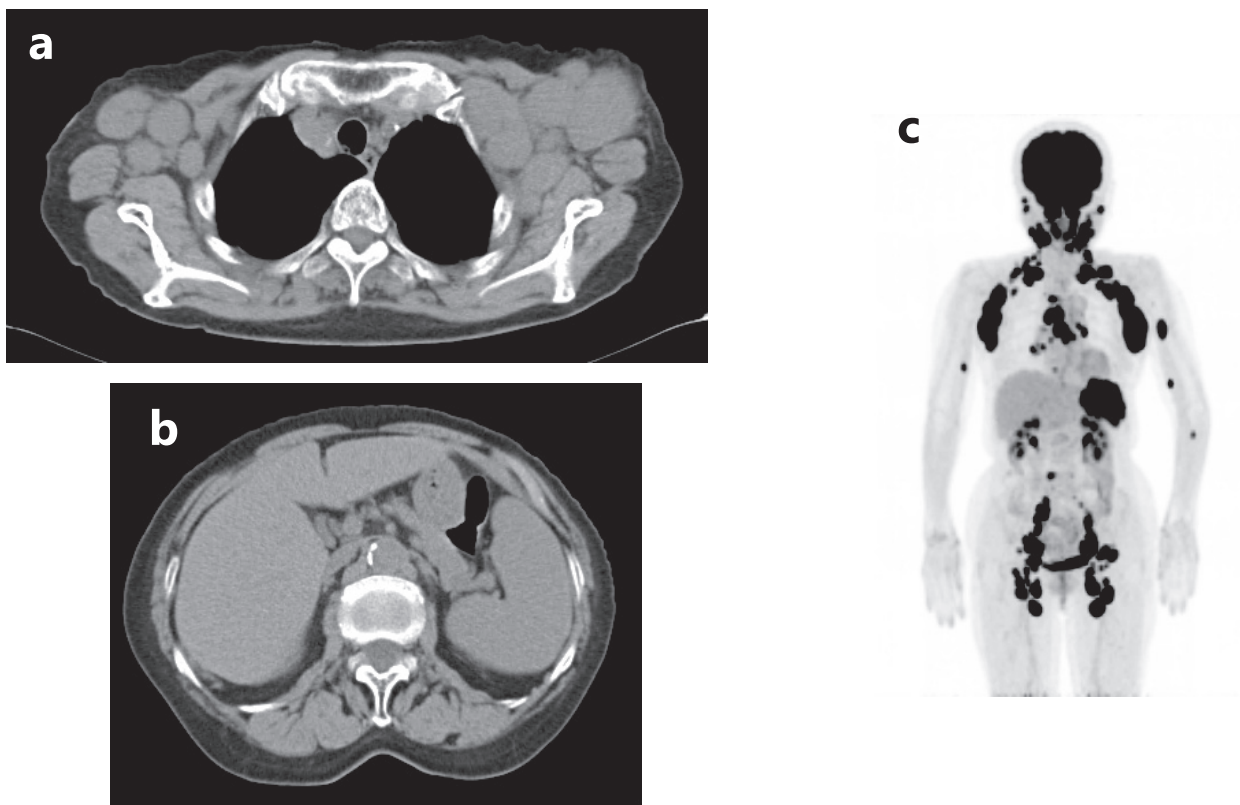
The cervical lymph node was replaced by diffuse infiltration of large-sized immunoblasts with a prominent nucleolus. On immunohistochemistry, they were CD3(-), CD5(-), CD10(+, weak), CD20(+), BCL2(+), BCL6(+), and MUM1(+). The MIB1 index was 90%. EBER ISH was negative. On flow cytometry, large cells were positive for CD10, CD19, CD20, and kappa. The diagnosis of DLBCL was made (Figure 3).

We next performed polymerase chain reaction (PCR) analysis of immunoglobulin heavy chain (IGH) gene rearrangements using extracted DNA from formalin-fixed paraffin-embedded tissue. A genescan of PCR products revealed

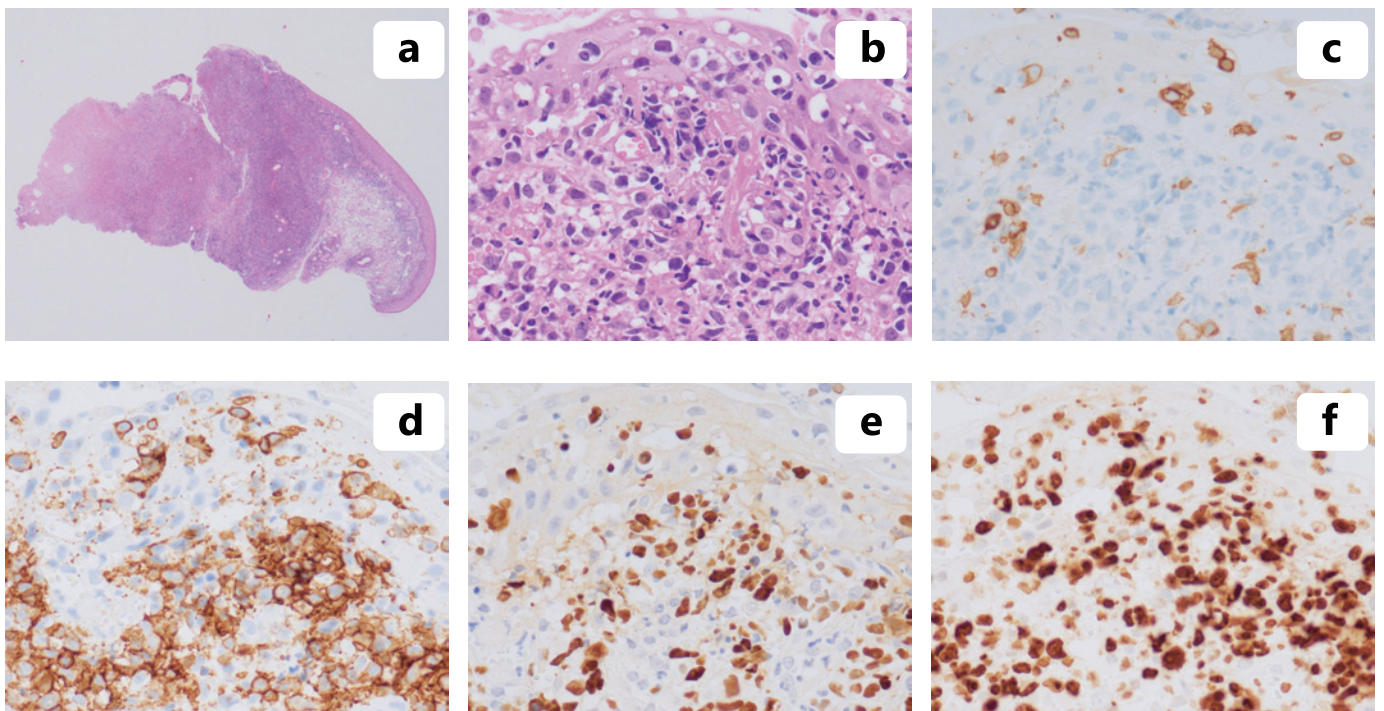
**Table 1.** The laboratory data at observation for left cervical lymph node swelling

			normal range				normal range
WBC	6700	/ $\mu$ L	4000-8000	BUN	18	mg/dL	8
RBC	363	$\times 10^3/\mu$ L	380-480	Cre	0.6	mg/dL	0.5-0.8
Hb	12.2	g/dL	11.5-15.5	Alb	3.6	g/dL	3.9-4.8
Ht	37.5	%	34.0-42.0	CRP	1.52	mg/dL	< 0.3
plt	23.4	$\times 10^3/\mu$ L	14.0-40.0	Glu	95	mg/dL	70-110
AST (GOT)	49	IU/L	< 30	IgG	1069	mg/dL	870-1700
ALT (GPT)	42	IU/L	< 35	IgA	176	mg/dL	110-350
LDH	405	IU/L	110-219	IgM	28	mg/dL	30-180
ALP	205	IU/L	100-310	RF	17	IU/mL	< 20
$\gamma$ GTP	20	IU/L	< 35	sIL-2R	1830	IU/mL	145-519
T-Bil	0.60	mg/dL	0.2-1.1	EBV EADR IgG	< 10		< 10
CK	108	IU/L	30-140	EBV EADR IgM	< 10		< 10
UA	4.7	mg/dL	3.0-6.0	EBNA	20		< 10

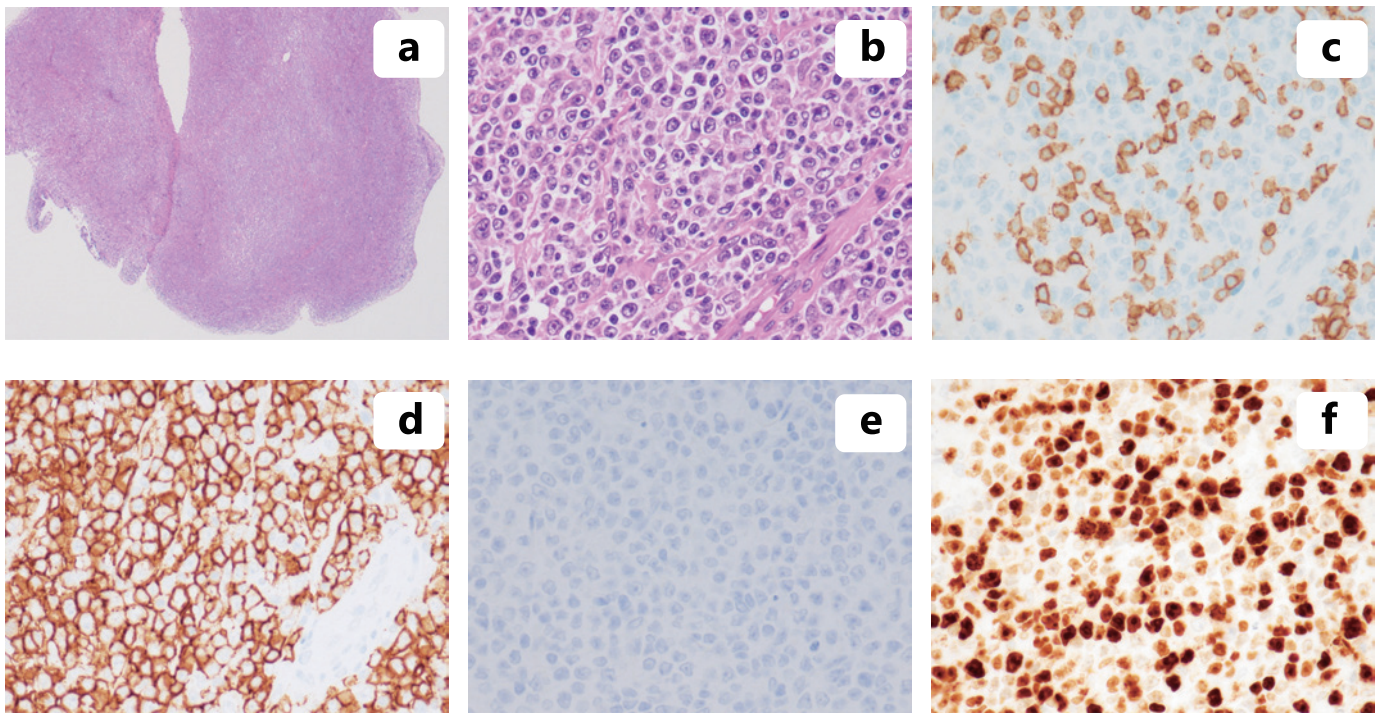
WBC: white blood cell, RBC: red blood cell, Hb: hemoglobin, Ht: hematocrit, plt: platelet, AST: aspartate transaminase, GOT: glutamic oxaloacetic transaminase, ALT: alanine transaminase, GPT: glutamic pyruvic transaminase, LDH: lactate dehydrogenase, ALP: alkaline phosphatase,  $\gamma$ GTP:  $\gamma$  glutamyl transpeptidase, T-Bil: total bilirubin, CK: creatine kinase, UA: uric acid, BUN: blood urea nitrogen, Cre: creatinine, Alb: albumin, CRP: C-reactive protein, Glu: glucose, IgG: immunoglobulin G, IgA: immunoglobulin A, IgM: immunoglobulin M, RF: rheumatoid factor, sIL-2R: soluble interleukin-2 receptor, EADR: early antigen diffuse and restricted, EBNA: EBV nuclear antigen



**Fig. 1.** Radiological images. Computed tomography image shows bilateral axillary lymph node swelling (*a*) and splenomegaly (*b*). PET-CT shows that FDG uptake in systemic lymph nodes, spleen, tonsils, and upper limbs.



**Fig. 2.** EBV-positive mucocutaneous ulcer of the pharynx. Biopsy shows diffuse infiltration under squamous epithelium (*a*, hematoxylin-eosin staining, original magnification x20) and large lymphocytes are interspersed in small lymphocytes (*b*, hematoxylin-eosin staining, original magnification x400). Large lymphocytes are CD3-negative (*c*), CD20-positive (*d*), and EBER-positive (*e*). MIB1 reacted with almost all large lymphocytes (*f*).



**Fig. 3.** Diffuse large B-cell lymphoma of the lymph node. Excisional biopsy of the lymph node shows diffuse infiltration. (*a*, low-power field, x2, hematoxylin-eosin staining) Diffuse proliferation of large lymphocytes is seen (*b*, high-power field, x20, hematoxylin-eosin staining). Large lymphocytes are CD3-negative (*c*), CD20-positive (*d*), and EBER-negative (*e*). The MIB1 index of large lymphocytes is 90% (*f*).

the same peak at 241 base pairs in both specimens (Figure 4).

## DISCUSSION

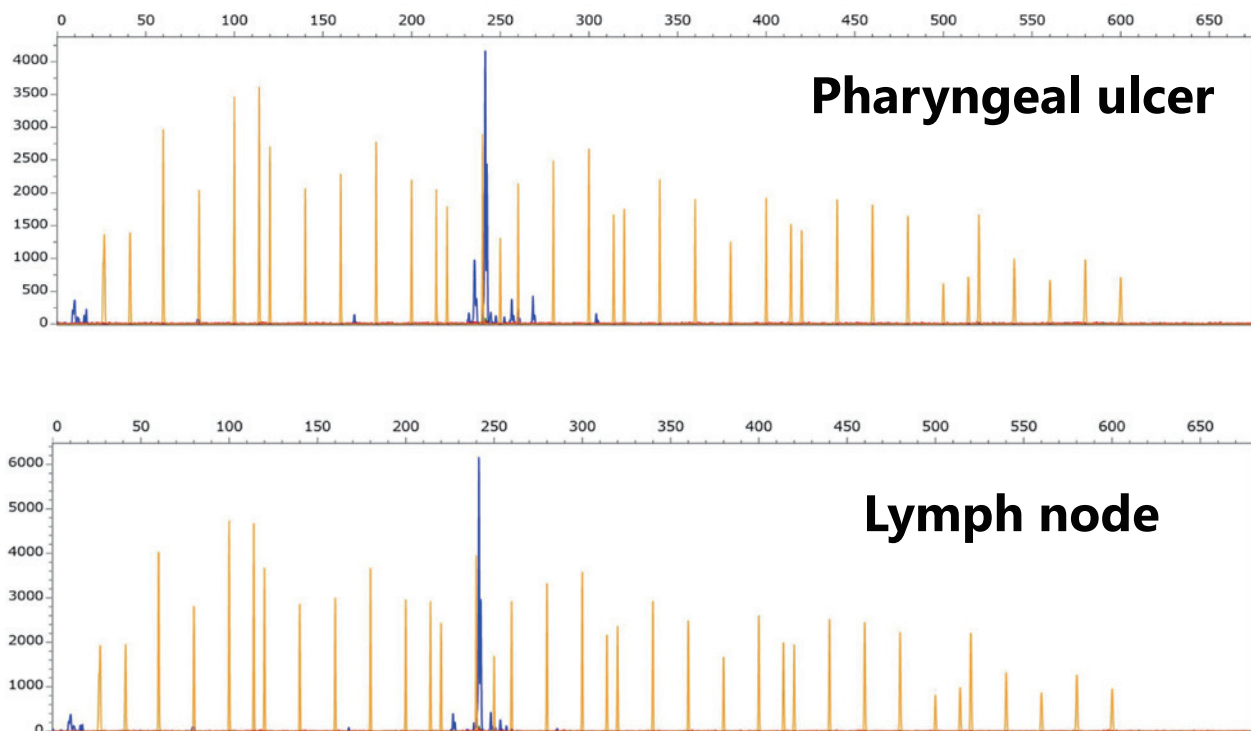
We report a case of MTX-LPD exhibiting composite lymphoma that consisted of EBV-negative DLBCL in the lymph node and EBVMCU in the pharynx. Moreover, PCR of IGH demonstrated the same clonal origin of two different lymphomas. Our case confirmed that MTX-LPD can include multiple clonal expansion.

The first point is the importance of multiple biopsy for MTX-LPD. MTX-LPD are mainly DLBCL and CHL, but rarely FL,<sup>9</sup> peripheral T-cell lymphoma,<sup>8</sup> etc. The pathological features are different, but all cases have the potential for tumor regression by MTX withdrawal. When tumor regression is not observed or tumor regrowth is observed after regression, pathological feature-sensitive chemotherapy is selected. The probability of regression is different among the pathological features. EBVMCU is a new entity from the WHO classification Revised 4th Edition, and almost all cases disappeared after MTX withdrawal.<sup>8</sup> On the other hand, clinical features of DLBCL vary, and EBV-negative cases more often require immunochemotherapy.<sup>9</sup> There are many predictive factors for tumor regression other than pathological features and EBV positivity such as T cell subset in peripheral blood,<sup>11</sup> absolute lymphocyte count after MTX withdrawal,<sup>12</sup> and serum lactate dehydrogenase, C-reactive protein, and soluble interleukin-2 receptor levels.<sup>13</sup> This case followed a different pattern of tumor regression. EBVMCU disappeared only after MTX withdrawal, whereas

DLBCL exhibited negative factors of tumor regression. When an abnormal clinical course of MTX-LPD is noted, biopsy should be performed again, especially if the first pathological feature suggested a good prognosis. Moreover, the chemotherapy regimen is often decided based on pathological findings from one biopsy, but biopsy of a few sites should be considered.

Although no report of composite lymphoma of DLBCL and EBVMCU has been reported because of its relative newness, Goyal *et al.* reported a case of composite lymphoma of DLBCL and CHL with a literature review, and found that in most cases, the two components were clonally related.<sup>14</sup> This is the first case of composite lymphoma demonstrating a clonal relationship with MTX-LPD.

The second point is therapy options. Although chemotherapy is required when regression by MTX withdrawal is not achieved, there is no standard regimen for MTX-LPD.<sup>10</sup> There is no method to develop a regimen, and lymphomagenesis is thought to be caused by the immunosuppressive state under MTX, autoimmune disease, inflammation due to autoimmune disease, and EBV infection. This case had two different pathological features and we thought it was discordant lymphoma at first. IGH-PCR revealed that they had the same clonal origin by different genetic modification. This is reasonable because MTX-LPD patients frequently develop lymphoma via many lymphomagenesis factors. The incidence of coincidental lymphoma is not known. When multiple pathological features are present, the best regimen may be (R-)CHOP. CHL-type MTX-LPD were reported to require chemotherapy more frequently than DLBCL-type MTX-LPD,



**Fig. 4.** PCR analysis of immunoglobulin heavy chain (IGH) gene. The upper panel is gene scan of PCR product from EBVMCU and lower panel is that from DLBCL. Both PCR products have the same peak at 241 base pairs.

and AVBD is an effective therapy.<sup>15</sup> Most CHL-type cases were treated by ABVD, but a few were treated using CHOP-like regimens.<sup>16</sup> There was a limited number of cases, but their treatment outcomes were good. ABVD is used for CHL in general, but (R-)CHOP may be an alternative regimen considering coincidental lymphoma. As MTX-LPD patients often develop infection and have autoimmune disease, chemotherapy may not always be performed because of their frailty. If their general condition does not allow for standard chemotherapy and less-intensive therapy, such as rituximab monotherapy, is needed, low-dose oral etoposide and radiation therapy may be administered.

In summary, we report a rare case of MTX-LPD exhibiting composite lymphoma, suggesting that multiple or repeated biopsies may be useful for MTX-LPD.

#### AUTHOR CONTRIBUTIONS

K.M., collection and assembly of data, data analysis and interpretation, and manuscript writing; Y.Y.K., Y.K., and S.S., collection and assembly of data, data analysis and interpretation; N.N., conception and design, administrative support, data analysis and interpretation, manuscript writing, and final approval of the manuscript. All authors approved the manuscript and agreed to be accountable for all aspects of the work.

#### CONFLICT OF INTEREST

The authors declare that they have no conflicts of interest

regarding the publication of this paper.

#### REFERENCES

- Gaulard P, Swerdlow SH, Harris NL, Sundström C, Jaffe ES. Other iatrogenic immunodeficiency-associated lymphoproliferative disorders. In: Swerdlow SH, Campo E, Harris NL, *et al.* (eds). WHO Classification of Tumours of Haematopoietic and Lymphoid Tissues. Revised 4th ed, Lyon, World Health Organization. 2017; pp. 462-464.
- Sato Y. Highlights: Focus on immunodeficiency-associated lymphoproliferative disorders. *J Clin Exp Hematop.* 2019; 59 : 46-47.
- Huwait H, Wang B, Shustik C, Michel RP. Composite cutaneous lymphoma in a patient with rheumatoid arthritis treated with methotrexate. *Am J Dermatopathol.* 2010; 32 : 65-70.
- Ichikawa A, Arakawa F, Kiyasu J, *et al.* Methotrexate/iatrogenic lymphoproliferative disorders in rheumatoid arthritis: histology, Epstein-Barr virus, and clonality are important predictors of disease progression and regression. *Eur J Haematol.* 2013; 91 : 20-28.
- Makis W, Ciarallo A, Wang B, Gonzalez-Verdecia M, Probst S. Composite cutaneous lymphoma (iatrogenic immunodeficiency-associated lymphoproliferative disorder) in a patient with rheumatoid arthritis treated with methotrexate: Staging and evaluation of response to therapy with <sup>18</sup>F-FDG PET/CT. *Nucl Med Mol Imaging.* 2017; 51 : 261-265.
- Bräuninger A, Spieker T, Willenbrock K, *et al.* Survival and clonal expansion of mutating “forbidden” (immunoglobulin receptor-deficient) Epstein-Barr virus-infected B cells in angioim-

- munoblastic t cell lymphoma. *J Exp Med.* 2001; 194 : 927-940.
- 7 Ikeda J, Morii E, Tomita Y, *et al.* Methotrexate-associated lymphoproliferative disorder mimicking composite lymphoma. *Int J Hematol.* 2006; 83 : 363-365.
  - 8 Ikeda T, Gion Y, Yoshino T, Sato Y. A review of EBV-positive mucocutaneous ulcers focusing on clinical and pathological aspects. *J Clin Exp Hematop.* 2019; 59 : 64-71.
  - 9 Tokuhira M, Tamaru J, Kizaki M. Clinical management for other iatrogenic immunodeficiency-associated lymphoproliferative disorders. *J Clin Exp Hematop.* 2019; 59 : 72-92.
  - 10 Gion Y, Iwaki N, Takata K, *et al.* Clinicopathological analysis of methotrexate-associated lymphoproliferative disorders: Comparison of diffuse large B-cell lymphoma and classical Hodgkin lymphoma types. *Cancer Sci.* 2017; 108 : 1271-1280.
  - 11 Saito S, Suzuki K, Yoshimoto K, *et al.* Restoration of decreased T helper 1 and CD8+ T Cell subsets is associated with regression of lymphoproliferative disorders developed during methotrexate treatment. *Front Immunol.* 2018; 9 : 621.
  - 12 Inui Y, Matsuoka H, Yakushijin K, *et al.* Methotrexate-associated lymphoproliferative disorders: management by watchful waiting and observation of early lymphocyte recovery after methotrexate withdrawal. *Leuk Lymphoma.* 2015; 56 : 3045-3051.
  - 13 Tokuhira M, Saito S, Okuyama A, *et al.* Clinicopathologic investigation of methotrexate-induced lymphoproliferative disorders, with a focus on regression. *Leuk Lymphoma.* 2018; 59 : 1143-1152.
  - 14 Goyal G, Nguyen AH, Kendric K, Caponetti GC. Composite lymphoma with diffuse large B-cell lymphoma and classical Hodgkin lymphoma components: A case report and review of the literature. *Pathol Res Pract.* 2016; 212 : 1179-1190.
  - 15 Berti A, Felicetti M, Peccatori S, *et al.* EBV-induced lymphoproliferative disorders in rheumatic patients: A systematic review of the literature. *Joint Bone Spine.* 2018; 85 : 35-40.
  - 16 Miranda RN, Loo E, Medeiros LJ. Iatrogenic immunodeficiency-associated classical hodgkin lymphoma: clinicopathologic features of 54 cases reported in the literature. *Am J Surg Pathol.* 2013; 37 : 1895-1897.