

# Case Report and Review of Literature

## Severe gynecomastia due to anti androgens intake: A case report and literature review

Chentli Farida, Belhimer Faiza

Department of Endocrine and Metabolic Diseases, Bab El Oued Hospital, 5 Boulevard Said Touati Algiers, Algeria

### ABSTRACT

Gynecomastia is the most bothersome side effect in men taking antiandrogens. It is exceptionally severe and distressing physically and mentally as in the reported case. A man, aged 63, with a history of a well-treated macroprolactinoma, was referred in 2004 for gynecomastia that appeared after treatment by microsurgery, radiotherapy and flutamide for a lesion suspected to be prostate cancer. Clinical examination was normal except for huge enlargement of the breasts. Mammography and breasts MRI did not show any tumor. There was not any metastasis of the supposed prostate cancer and prostatic acid phosphates were within normal ranges. Hormonal exploration showed subclinical hypogonadism [testosterone: 7.4 ng/ml (*n*: 3-9), FSH: 14.9 mu/ml (*n*: 0.7-11) and LH: 9.7 mu/ml (*n*: 0.8-7.6)]. Testes ultrasounds were normal. Radiological and hormonal adrenal explorations were normal [Cortisol: 76 ng/ml (*n*: 50-250), DHEA-S: 59 µg/ml (*n*: 50-560), E2:40.2 pg/ml (*n* < 50)]. Body scan was normal too. The discussed etiologies were post radiation subclinical hypogonadism, and treatment with anti androgens. After flutamide withdraw, there was not any sign of prostate cancer recurrence, and gynecomastia decreased significantly, but did not disappear probably because of fibrosis.

**Key words:** Aging, antiandrogens, gynecomastia, prostate cancer

### INTRODUCTION

Gynecomastia is a common presentation in adolescents and old men. It results from imbalance between estrogens and androgens or from an increased sensibility of breast tissue to estrogens. Since the development of antiandrogens for prostate cancer, antihypertensive drugs, anticortisol, antiviruses, and some other products, iatrogenic gynecomastia is more and more frequent.

The frequency of antiandrogens side effects on the breast varies from a study to another.<sup>[1]</sup> The severity of breast hypertrophy is mild or moderate. But after many years it may become giant, severe, and even huge, painful, difficult to bear physically and psychologically.

### CASE REPORT

A man, aged 63, was referred in 2004 for gynecomastia. His childhood, puberty and sexual life were unremarkable. His medical history began in 2000. He was treated successfully for prolactinoma. At that time his endocrinologist was sure gynecomastia was absent. Bromocriptine normalized prolactin (810 vs. 2 ng/ml) and testosterone (7 ng/ml), and induced an empty sella.

In 2004, he was diagnosed as having a suspect lesion arguing for prostate cancer. Although that one has never been confirmed by histology, he was treated by endoscopic surgery, radiotherapy, and nonsteroid antiandrogen (Flutamide: 750 mg/day) as other products were not available. After that, he had impotency and aching progressive gynecomastia.

Clinical examination showed a stressed man wearing very loose cloths to hide his chest. Physical examination was normal except for bilateral, severe, and asymmetrical giant gynecomastia [Figure 1].

There were no nipple discharge, mass, or axillary

#### Access this article online

##### Quick Response Code:



Website:  
www.ijem.in

DOI:  
10.4103/2230-8210.113770

**Corresponding Author:** Prof. Chentli F, Department of Endocrine and Metabolic diseases, Bab El Oued Hospital, 5boulevard Said Touati, Algiers, Algeria. E-mail: chentli.f@gmail.com

lymphadenopathy. His BMI was equal to 23 kg/m<sup>2</sup>, blood pressure and heart rate were normal. Body hair repartition and testicles were normal.

Mammography, ultrasounds, and breasts MRI showed dense, bilateral glandular aspect without any tumor [Figure 2].

Routine analyses were all in normal ranges, and hormonal exploration showed sub clinical hyper gonadotrophic hypogonadism [Table 1].

Thyroid function, prostatic acid phosphates (PAP) and total HCG were normal [respectively 0.52 μU/ml for TSH (*n*: 0.4-4), 12 pmol/l for free T4 (*n*: 8-24), 0.02 ng/ml for total PAP (*n*: 0-4) and 5 mU/ml for HCG (*n* < 10)]. Liver and kidney functions were normal too.

Radiological exploration of adrenals, kidney, liver, pancreas and chest did not show any abnormalities. Body scan and testes ultrasounds did not show any tumor.

For different etiologies, although the iatrogenic cause was the most evident, we discussed all causes of gynecomastias in elderly. Prolactinoma was the first to be discussed, but it was ruled out as the gynecomastia appeared many years after normalization of prolactin and testosterone. Other hypothalamo-pituitary causes were improbable. Congenital etiologies such true and pseudo hermaphroditism, Klinefelter's syndrome, and other dysgenetic causes were

improbable too. Adrenal feminizing tumors were excluded by adrenal biochemical and radiologic explorations. Tumors secreting HCG were eliminated too as beta HCG and ultrasounds were normal. Bilateral breast metastases of prostate cancer were excluded too.

According to the context, the remaining etiologies are iatrogenic, and paraneoplastic. As metastases were absent, we kept in mind a double iatrogenic cause (radiotherapy and flutamide intake).

## DISCUSSION

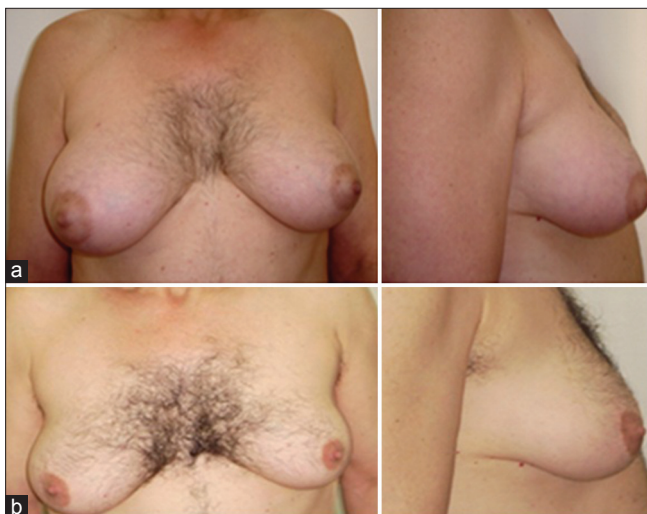Gynecomastia, defined as an abnormal enlargement of one or both breasts in men has numerous causes<sup>[1,2]</sup> depending on the age of the subject.

Broadly, the main etiologies are medications, adrenal tumors, liver and kidney failure.

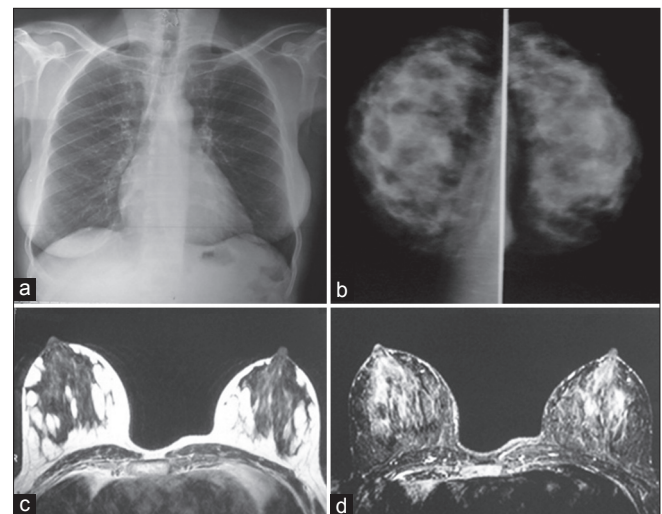
In elderly, unilateral gynecomastia is generally due to a benign or malignant tumor of the breast, but maybe the beginning of bilateral hypertrophy or hyperplasia.

Bilateral gynecomastia is rarely due to primary breast tumors or metastases.

The mechanism of bilateral gynecomastia is generally represented by androgens deprivation, or by a tumor



**Figure 1:** (a) Clinical aspect of gynecomastia under flutamide, (b) After stopping flutamide: Increase in body hair, and decrease in breast size



**Figure 2:** Chest X-ray like a woman's (a), mammography (b), and breasts MRI (c, d) showing dense bilateral glandular aspect

**Table 1: Hormonal assessment**

Hormones	PRL ng/ml	T ng/ml	FSH mu/ml	LH mu/ml	Cortisol ng/ml	DHEA-S μg/ml	E2 pg/ml
	2-5	7.4	14.9	9.7	76	59	40.2
Reference values	5-10	3-9	0.7-11	0.8-7.6	50-200	50-560	<50

PRL: Prolactin, T: Testosterone, FSH: Folliclestimulating hormone, LH: Luteotropon hormone, DHEA-S: Dihydroepiandrosterone sulfate, E2: Estradiol

secreting human chorionic gonadotrophins (HCG) or estrogens.<sup>[1-4]</sup>

In our patient, although iatrogenic causes were evident, endogenous etiologies such as adrenal feminizing tumors,<sup>[4]</sup> testicular tumors secreting estrogens or HCG and paraneoplastic causes were discussed. But, the longstanding, normal rates of estrogens and HCG, and lack of adrenal, testicular, abdomen, chest, and kidney tumors were against.

Hypothalamo pituitary hypogonadism does not seem to be the cause as prolactin was normal and clinical examination did not find any sign of pituitary disorder.

Hyperthyroidism causing an increase in testosterone binding globulin leading to decrease in free androgens and increase of free oestrogens<sup>[1,2]</sup> was excluded as thyroid function was normal. Obesity was not discussed as the BMI was normal.

In our patient severe gynecomastia seems to be secondary to androgens deprivation with at least three causes: Pelvic radiotherapy, anti androgen drugs and aging or andropause as men over 50 tend to produce fewer androgens and gain fat tissue that convert androgens to estrogens. Radiotherapy acts on the testicles causing an overt or subclinical hypogonadism. Chemical products such as anti androgens have many actions: They inhibit the hypothalamo-pituitary-testicular axis, and decrease androgens sensibility of target tissues, leading to low androgens rate and to androgens insensibility.

Among the numerous side effects of androgen deprivation, gynecomastia is probably the most frequent and the most disturbing psychologically.<sup>[5]</sup> But, to our knowledge, apart from true hermaphroditisms and total insensibility to androgens, a severe one like our patient's is exceptional. It causes breast pain, shame,<sup>[5]</sup> and back problems.

Another stressing problem of severe gynecomastia is represented by benign or malignant transformation<sup>[6-8]</sup> especially in obese subjects, and patients who have family history of breast cancer or in those with high sensibility to estrogens/androgens imbalance.<sup>[1,2]</sup> Other products causing gynecomastia are numerous.<sup>[1,2]</sup> The most important are estrogens, cardiovascular products, psychoactive and alkylating agents, anti ulcer medications, anti-cortisol, anti viruses, some antibiotics and substances or extracts from some plants.

The ideal treatment of iatrogenic gynecomastia in prostate cancer should be preventive,<sup>[9]</sup> by avoiding anti androgens when possible or adding breast radiotherapy that reduces the risk of gynecomastia by 50%, and/or anti-oestrogens such as Tamoxifene before the development of gynecomastia or just at the beginning.<sup>[6]</sup>

Withdraw of products causing gynecomastia is not always possible, especially when prostate cancer is sure, or had already spread. In some cases where the products were stopped gynecomastia did not regress substantially probably because of the presence of fibrosis<sup>[1]</sup> as in our case. So, plastic surgery<sup>[10]</sup> seems to be the best solution for experienced surgeons.

## REFERENCES

1. Braunstein GD. Clinical practice Gynecomastia. *N Engl J Med* 2007;357:29-37.
2. Carlson HE. Approach to the patient with gynecomastia. *J Clin Endocrinol Metab* 2011;96:15-21.
3. Bertola G, Giambona S, Balza G, Sironi C, Colombo E, Santangelo M, *et al*. An uncommon cause of gynecomastia: Testicular Leydig cell tumor. Hormonal profile before and after orchiectomy. *Recenti Prog Med* 2006;97:85-8.
4. Melero VM, Centeno RG, Fernández JB, Vigovich C, García-Cervigón PS, Albarrán AJ. Feminizing adrenal tumours in Spain: Report of a case and review of the five previously published patients. *Endocrinol Nutr* 2009;56:470-4.
5. Wassersug RJ, Oliffe JL. The social context for psychological distress from iatrogenic gynecomastia with suggestions for its management. *J Sex Med* 2009;6:989-1000.
6. Chen AC, Petrylak DP. Complications of androgen-deprivation therapy in men with with prostate cancer. *Curr Oncol Rep* 2004;6:209-15.
7. Lee SC, Ellis RJ. Male breast cancer during finasteride therapy. *J Natl Cancer Inst* 2004;96:338-9.
8. Karamanakos P, Mitsiades CS, Lembessis P, Kontos M, Trafalis D, Koutsilieris M. Male breast adenocarcinoma in a prostate cancer patient following prolonged anti-androgen monotherapy. *Anticancer Res* 2004;24:1077-81.
9. Bedognetti D, Rubagotti A, Conti G, Francesca F, De Cobelli O, Canclini L, *et al*. An open, randomised, multicentre, phase 3 trial comparing the efficacy of two tamoxifen schedules in preventing gynecomastia induced by bicalutamide monotherapy in prostate cancer patients. *Eur Urol* 2010;57:238-45.
10. El Noamani S, Thabet AM, Enab AA, Shaeer O, El-Sadat A. High grade gynecomastia: Surgical correction and potential impact on erectile function. *J Sex Med* 2010;7:2273-9.

**Cite this article as:** Farida C, Faiza B. Severe gynecomastia due to anti androgens intake: A case report and literature review. *Indian J Endocr Metab* 2013;17:730-2.

**Source of Support:** Nil, **Conflict of Interest:** None declared.