

# Anesthetic management with a neuromuscular relaxant and sugammadex in a patient with Prader–Willi syndrome: A case report

SAGE Open Medical Case Reports  
Volume 8: 1–3  
© The Author(s) 2020  
Article reuse guidelines:  
sagepub.com/journals-permissions  
DOI: 10.1177/2050313X20927616  
journals.sagepub.com/home/sco



Kyung Woo Kim, Seung Hwan Kim, Eun Jin Ahn, Hyo Jin Kim, Hey Ran Choi and Si Ra Bang 

## Abstract

Prader–Willi syndrome is a genetic disorder that is characterized by obesity, characteristic facial features, hypotonia, and sleep apnea. These abnormalities mean that airway management is difficult in such patients. Several previous reports suggest that neuromuscular blocking agents should not be used to reduce airway and respiratory complications in these patients. However, this is not always possible. Here, we report the case of a patient with Prader–Willi syndrome in whom anesthesia for ophthalmic surgery was managed successfully using sugammadex after administration of rocuronium.

## Keywords

Prader–Willi syndrome, anesthetic management, neuromuscular relaxant, sugammadex

Date received: 17 September 2019; accepted: 27 April 2020

## Introduction

Prader–Willi syndrome (PWS) is a genetic disorder of chromosome 15 that causes hypotonia and developmental delay during infancy. Mental retardation, obesity, short stature, hypogonadism, and behavioral problems become apparent during childhood.<sup>1–3</sup> Obesity, characteristic facial features, hypotonia, and sleep apnea cause difficulties in airway management during anesthesia and increase the risk of respiratory complications.<sup>1,4</sup> Disordered thermoregulation, diabetes, hypertension, and arrhythmia may also be problematic.<sup>5</sup> Therefore, anesthesia management is challenging in patients with PWS. Here, we report the case of a patient with PWS who underwent ophthalmic surgery and recovered uneventfully with administration of sugammadex after rocuronium. The article adheres to the CARE guidelines for clinical case reports. Written informed consent for publication of this case was obtained from the patient.

## Case

The patient was a 21-year-old man (154 cm, 86 kg) with a diagnosis of PWS who was scheduled to undergo pars plana vitrectomy for vitreous hemorrhage. He had a medical history of sleep apnea, scoliosis, mental retardation, attention deficit

hyperactivity disorder, and poorly controlled diabetes mellitus (glycated hemoglobin, 16.3%). Pulmonary function tests confirmed a restrictive pattern. Preoperative arterial blood gas analysis showed a pH of 7.38, a PaCO<sub>2</sub> of 43 mmHg, a PaO<sub>2</sub> of 92 mmHg, and an oxygen saturation of 97%. Preoperative evaluation revealed a small mandible and a Mallampati class IV airway (Figure 1).<sup>6</sup>

The patient was not premedicated before being brought to the operating theater. He was monitored in the operating room by electrocardiography, noninvasive blood pressure assessment, and pulse oximetry. His vital signs before anesthesia included a blood pressure of 120/80 mmHg, a heart rate of 70 beats/minute, a body temperature of 36.5°C, and an oxygen saturation of 97%. After preoxygenation with 100% oxygen via a face mask, remifentanyl 0.2 µg/kg/min was injected and 70 mg of propofol were administered. After train of four (TOF, TOF-Watch<sup>®</sup> SX, Organon Ireland Ltd, Dublin,

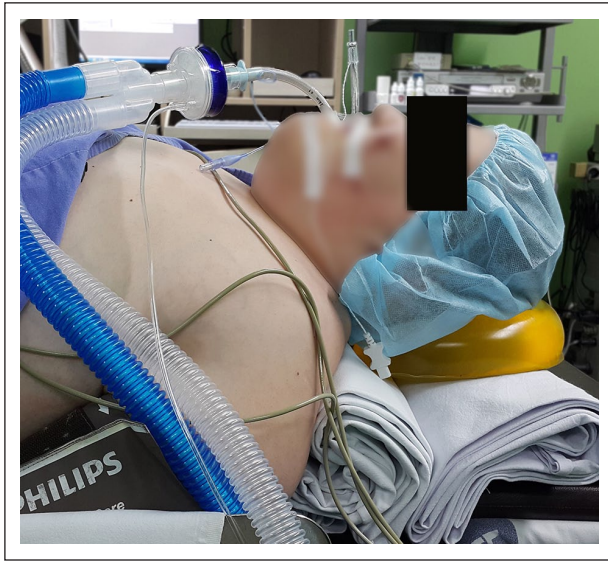
Department of Anesthesiology and Pain Medicine, Inje University Seoul Paik Hospital, Seoul, Korea

### Corresponding Author:

Si Ra Bang, Department of Anesthesiology and Pain Medicine, Inje University Seoul Paik Hospital, 9, Marunnai-ro, Jung-gu, Seoul 04551, Korea.

Email: sira1045@naver.com





**Figure 1.** A morbidly obese patient with Prader-Willi syndrome.

Ireland) was established, 30 mg of rocuronium were injected. After about 2 min, the TOF ratio reached 0 and endotracheal intubation was attempted using a video laryngoscope (UEScope, Zhejiang UE Medical Corp., Zhejiang, China). The anesthesiologist encountered resistance during insertion of a reinforced tube with an internal diameter of 7.0 mm, so switched to a tube size with an internal diameter of 6.5 mm. Anesthesia was maintained with 2 vol% of sevoflurane in a mixture of 2 L/min of air and 2 L/min of oxygen with infusion of remifentanyl at a rate of 0.05 to 0.1  $\mu\text{g}/\text{kg}/\text{min}$ .

An additional dose of muscle relaxant (rocuronium 10 mg) was administered on two occasions when the TOF watch count reached 1. The TOF ratio was 13% at the end of the operation. The anesthesiologist observed the patient for 10 min to confirm spontaneous recovery of muscle relaxation. When the TOF ratio reached 36%, sevoflurane was discontinued and 50 mg of sugammadex were administered. After 2 min, the TOF ratio was 88% and a further 50 mg of sugammadex were injected. Ten minutes later, when the patient was confirmed to be conscious and breathing spontaneously, the anesthesiologist removed the endotracheal tube. The total operating time was 60 min and the anesthesia time was 100 min.

In the post-anesthesia care unit, the patient's oxygen saturation was 97% on 3 L/min of oxygen via a nasal cannula and more than 95% in room air. No opioid was administered postoperatively because the patient had remained pain-free. He was transferred to the intensive care unit for close respiratory monitoring and discharged to the ward the next day with no respiratory complications.

## Discussion

Patients with PWS are at increased risk of developing respiratory complications after anesthesia. The effects of nondepolarizing muscle relaxants are prolonged in these patients if hypotonia is

present, particularly in infants.<sup>2</sup> There have been case reports of delayed recovery in these patients and decreased or no use of neuromuscular blockers because of this problem.<sup>1,5,7</sup>

Patients with PWS develop obesity in childhood because of hyperphagia related to hypothalamic dysfunction and gain weight easily as a result of decreased satiety and limited physical activity.<sup>4,8</sup> This makes airway management difficult and is a major risk factor for postoperative respiratory complications. Obesity has been reported to be an important cause of death in patients with PWS.<sup>9</sup> Furthermore, patients with PWS frequently have sleep apnea and show a restrictive pattern on pulmonary function tests, which leads to difficulty in respiratory management perioperatively.<sup>2</sup>

Vitrectomy surgery can be performed using local or general anesthesia. However, general anesthesia can reduce the risk of accidental movement of the eye during an intraocular procedure.<sup>10</sup> Avoidance of neuromuscular blockade as part of anesthesia management is known to reduce the risk of airway and respiratory problems in patients with PWS<sup>2,5,8</sup> but may not always be possible, as in this case. Our patient did not have hypotonia but was morbidly obese (body mass index, 36.3) and had sleep apnea, a restrictive pattern on pulmonary function tests, and mental retardation, so he was at high risk of respiratory complications perioperatively. Therefore, rocuronium and sugammadex were used with TOF monitoring for safe recovery.

Titration of propofol for induction was guided by the bispectral index value, which was 50. Therefore, we used a lower propofol dose based on actual body weight and used the BIS value for more accurate prediction of loss of consciousness.<sup>11</sup> Intubation is usually performed after administration of rocuronium at 0.6 mg/kg; however, in order to observe the response to a muscle relaxant, we decided to use a lower dose of rocuronium after checking the drug label.<sup>12</sup> Sugammadex selectively encapsulates steroidal neuromuscular blocking agents such as rocuronium and rapidly reverses rocuronium-induced neuromuscular blockade.<sup>13</sup> Although information on use of sugammadex in patients with PWS is limited, our experience is that use of this agent for reversal of muscle relaxation is a safe and reliable option in these patients. In this case, use of sugammadex allowed complete and uneventful recovery from neuromuscular blockade.

Patients with PWS may have disordered thermoregulation because of hypothalamic dysfunction. However, in our patient, body temperature was maintained within a normal range of 36.5°C to 36.8°C without difficulty.<sup>8</sup>

## Conclusion

Perioperative respiratory care in patients with PWS is a challenge. It is particularly important that neuromuscular blockade be managed in a way that allows good recovery. There are presently very few reports on the use of sugammadex in patients with PWS. Our experience indicates that safe recovery from neuromuscular blockade can be ensured by administration of sugammadex and careful neuromuscular monitoring in these patients.

### Data availability

All relevant data concerning this case are contained in this report.

### Declaration of conflicting interests

The author(s) declared no potential conflicts of interest with respect to the research, authorship, and/or publication of this article.

### Ethical approval

Our institution does not require ethical approval for reporting individual cases or case series.

### Funding

The author(s) received no financial support for the research, authorship, and/or publication of this article.

### Informed consent

Written informed consent was obtained from the patient(s) for their anonymized information to be published in this article.

### ORCID iD

Si Ra Bang  <https://orcid.org/0000-0002-3290-0199>

### References

- Meco BC, Alanoglu Z, Cengiz OS, et al. Anesthesia for a 16-month-old patient with Prader-Willi syndrome. *J Anesth* 2010; 24: 949–950.
- Dearlove OR, Dobson A and Super M. Anaesthesia and Prader-Willi syndrome. *Paediatr Anaesth* 1998; 8: 267–271.
- Tseng C-H, Chen C, Wong C-H, et al. Anesthesia for pediatric patients with Prader-Willi syndrome: report of two cases. *Chang Gung Med J* 2003; 26: 453–457.
- Butler MG. Prader-Willi syndrome: current understanding of cause and diagnosis. *Am J Med Genet* 1990; 35: 319–332.
- Kim JY, Lee JH, Kim EJ, et al. Anesthetic management in a pediatric patient with infantile phase Prader-Willi syndrome: a case report. *Korean J Anesthesiol* 2009; 57: 259–263.
- Miller RD. *Miller's anesthesia*. 8th ed. San Diego, CA: Churchill Livingstone, 2015.
- Lee JY, Cho KR, Kim MH, et al. General anesthetic management of Prader-Willi syndrome patient undergoing middle cerebral artery-superficial temporal artery anastomosis. *Korean J Anesthesiol* 2012; 63(1): 85–86.
- Legrand R and Tobias JD. Anesthesia and Prader-Willi syndrome: preliminary experience with regional anesthesia. *Pediatr Anesth* 2006; 16: 712–722.
- Schrander-Stumpel CT, Curfs LM, Sastrowijoto P, et al. Prader-Willi syndrome: causes of death in an international series of 27 cases. *Am J Med Genet A* 2004; 124A: 333–338.
- Licina A, Sidhu S, Xie J, et al. Local versus general anaesthesia for adults undergoing pars plana vitrectomy surgery. *Cochrane Database Syst Rev* 2016; 9: CD009936.
- Subramani Y, Riad W, Chung F, et al. Optimal propofol induction dose in morbidly obese patients: a randomized controlled trial comparing the bispectral index and lean body weight scalar. *Can J Anaesth* 2017; 64(5): 471–479.
- FDA label of rocuronium, [http://www.accessdata.fda.gov/drugsatfda\\_docs/label/2008/078717s000lbl.Pdf](http://www.accessdata.fda.gov/drugsatfda_docs/label/2008/078717s000lbl.Pdf) (accessed 26 February 2020).
- Naguib M. Sugammadex: another milestone in clinical neuromuscular pharmacology. *Anesth Analg* 2007; 104: 575–581.