

Contents lists available at [ScienceDirect](http://www.sciencedirect.com)

## International Journal of Surgery Case Reports

journal homepage: [www.casereports.com](http://www.casereports.com)

## Pedicle screw position changing policy for nerve injury problems during screw insertion on thoracolumbar compression fractures



Ahmad Jabir Rahyussalim<sup>a,\*</sup>, Ifran Saleh<sup>a</sup>, M. Fajrin Armin<sup>a</sup>, Tri Kurniawati<sup>b</sup>,  
Ahmad Yanuar Safri<sup>c</sup>

<sup>a</sup> Department of Orthopaedic and Traumatology, Faculty of Medicine Universitas Indonesia, Dr. Cipto Mangunkusumo General Hospital, Jakarta, 10320, Indonesia

<sup>b</sup> Stem Cell and Tissue Engineering Cluster, MERC Faculty of Medicine Universitas Indonesia, Dr. Cipto Mangunkusumo General Hospital, Jakarta, 10320, Indonesia

<sup>c</sup> Neurophysiology Division of Neurology Departement, Faculty of Medicine Universitas Indonesia, Dr. Cipto Mangunkusumo General Hospital, Jakarta, 10320, Indonesia

## ARTICLE INFO

## Article history:

Received 27 June 2016

Received in revised form

20 September 2016

Accepted 20 September 2016

Available online 23 September 2016

## Keywords:

Pedicle screw placement

Nerve injury

Intra operative monitoring

SSEP

## ABSTRACT

**INTRODUCTION:** Intraoperative neurophysiologic monitoring (IONM) had important role related to the complications in spinal surgery. Somatosensory Evoked Potential (SSEP), Transcranial electric Muscle Evoked Potentials (tceMEPs), and free run EMG are parameters used to assess functional integrity of the nervous system during surgical procedures. Once warning signal was recognized, surgeon have to make a precise decision to overcome that problem.

**PRESENTATION OF CASE:** We present a 47-year old male with back pain due to compression fracture of thoracic vertebra T12 and lumbar vertebrae L1. While stabilizing through the posterior approach on the T11 and 12 as well as L2 and L3, the SSEP monitor showed 50% reduction in the waveform as the pedicle screw was inserted at the left side of T12. The instrumentation was changed into vertebra thoracal T10, T11, and vertebrae lumbar L2, L3. The SSEP normalized and post operatively pain decreased. After surgery there was no neurological deficit.

**DISCUSSION:** Acute trauma as a result of spine instrumentation may provoke significant edema, with mass effect causing neurophysiological dysfunction. Administration of intravenous steroid would do at this stage, followed by constant infusion for following 24–48 h, may help ameliorating the mass effect and improving the neurologic outcome. Alternatively, immediate pedicle screw changing policy showed absolute recovery of nerve injury.

**CONCLUSION:** Insertion of pedicle screw in spinal surgery has a risk of complication that could be treated by pedicle screw changing policy.

© 2016 The Author(s). Published by Elsevier Ltd on behalf of IJS Publishing Group Ltd. This is an open access article under the CC BY-NC-ND license (<http://creativecommons.org/licenses/by-nc-nd/4.0/>).

### 1. Introduction

Pedicle screw placement is a common procedure. It has a great developing technique that is used for fixation and fusion in spine surgery. It was firstly introduced by Harrington and Tullos in 1969 and then in late 1980's developed by Roy Camille et al., Louis, and Steffe. It had already become the leading instrumentation in spinal surgery until nowadays. It could be applied in degenerative, trauma, neoplastic, infectious and malformation cases that had a problem with axial instability [1].

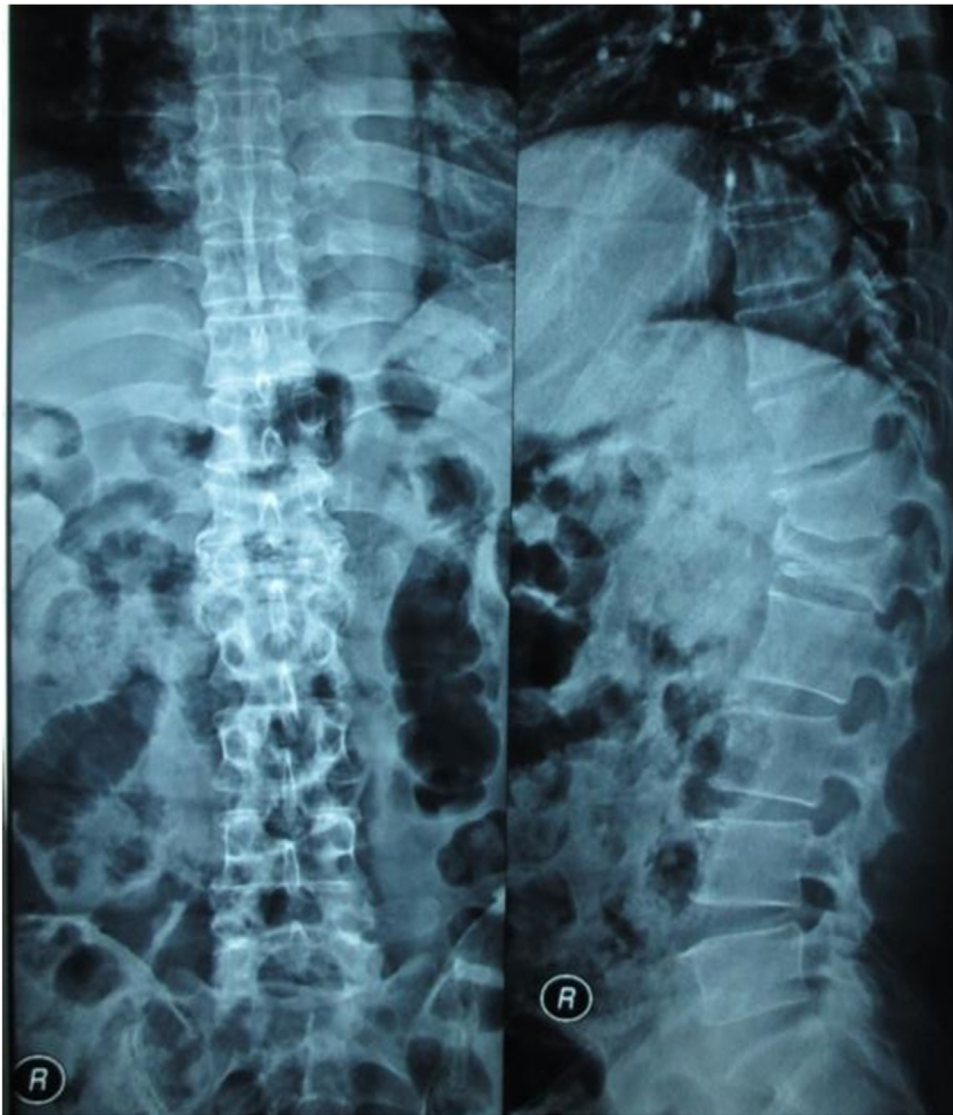
Despite its usefulness, pedicle screw placement maneuvers had some complications. Nerve root, spinal cord injury, vascular injury, cerebrospinal fluid leak, visceral injury, pedicle fracture were some complications that mostly related to pedicle screw malpositioning. Among those complications, the nerve injury due to pedicle screw malpositioning was a common complication that was faced by spine surgeons [2,3].

Intraoperative neurophysiologic monitoring (IONM) has an important role in spinal surgery. There were a various neurophysiologic techniques used to assess functional integrity of the nervous system during surgical procedures. It was useful by providing real time evaluation and immediate feedback to the surgeon at a point where intervention with any doubt taken. This real time feedback would be a guide for surgeon to determine the precise decision in preventing irreversible neural damage [3,4].

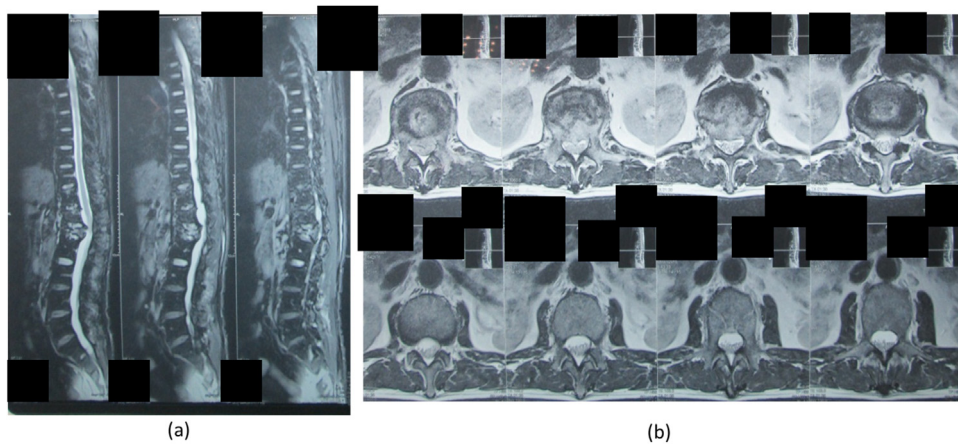
Once warning signal was recognized by IONM, surgeon had to make a precise decision to overcome that problem. Establishing

\* Correspondence to: Dr. Rahyussalim, Faculty of Medicine Universitas Indonesia, Department of Orthopaedic and Traumatology, Jalan Salemba 6, Kelurahan Kenari, Kecamatan Senen, Jakarta Pusat, DKI Jakarta, 10320, Indonesia.

E-mail addresses: [rahyussalim71@ui.ac.id](mailto:rahyussalim71@ui.ac.id), [rahyussalim@gmail.com](mailto:rahyussalim@gmail.com) (A.J. Rahyussalim).

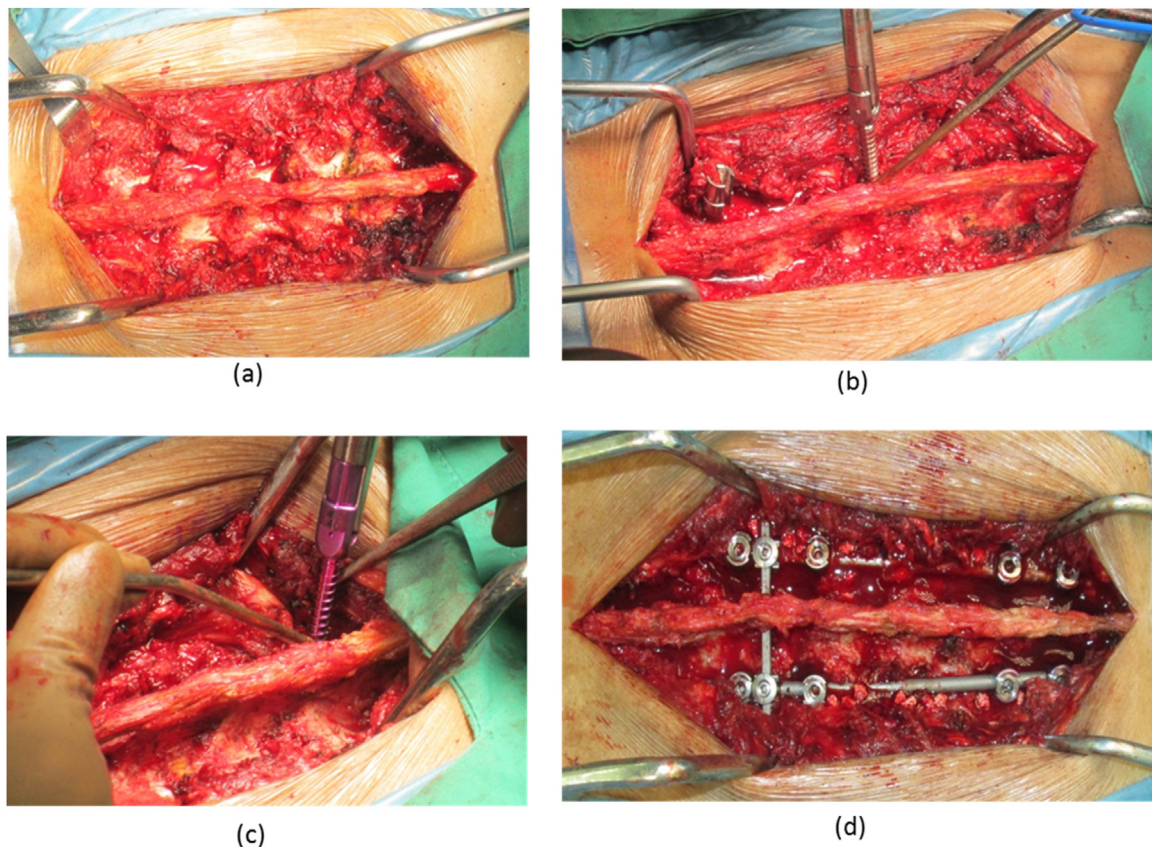


**Fig. 1.** Initial AP and lateral view X ray were showing kypotic deformity due to collapse of vertebrae thoracal T12 and lumbar L1. (The x ray image was taken on 23 June 2015).



**Fig. 2.** Sagittal and axial view of T2 weighted images were showing destruction vertebral body of lumbar L1 and compression fracture on anterior part of vertebral body thoracal T12 (Fig. 2a). It also showed the compression of anterior part of spinal cord by posterior part vertebral body (Fig. 2b). (The MRI image was taken on 1 July 2015).





**Fig. 3.** During surgery: (a) Expose of thoracolumbar vertebrae, (b) Pedicle screw was inserted to vertebrae thoracic T12 and disturb the signal, (c) Screw position changing from T12 to T11 due to signal warning on T12, (d) Final result of operation with screw position with free signal warning.

the cause, mechanism and the pathology of injury associated with nerve injury during spinal surgery were mandatory tools to surgeon as consideration to make an appropriate decision [3]. In this review, a case of nerve entrapment problem after screw insertion on thoracolumbar compression fracture that recognized by intra-operative neurophysiologic monitoring at Ciptomangunkusumo Hospital was presented and correct management was discussed.

### 1.1. Case presentation

A 47 year old male fell from his motorcycle following a traffic accident eleven years ago during which he landed on the asphalt with his buttocks. The motor and sensory functions were normal.

Seven month before hospital admission, patient had the pain worse (VAS 4–5), but he could still move his both leg. Plane x ray confirmation showed that there was vertebral collapse on T12 and L1. It raised kyphotic deformity. It also showed narrowing disc at the level involved (Fig. 1). MRI examination showed a compression fracture at the level vertebrae thoracic T12 and lumbar L1. It showed also there was small fragment of bone come into the canal and compressed the anterior segment of spinal cord (Fig. 2). Laboratory examination showed there is an increase in parameter of Erythrocyte Sedimentation Rate (52 mm/h), C-reactive protein (50 mg/L) and Leucocyte count (12.200/L).

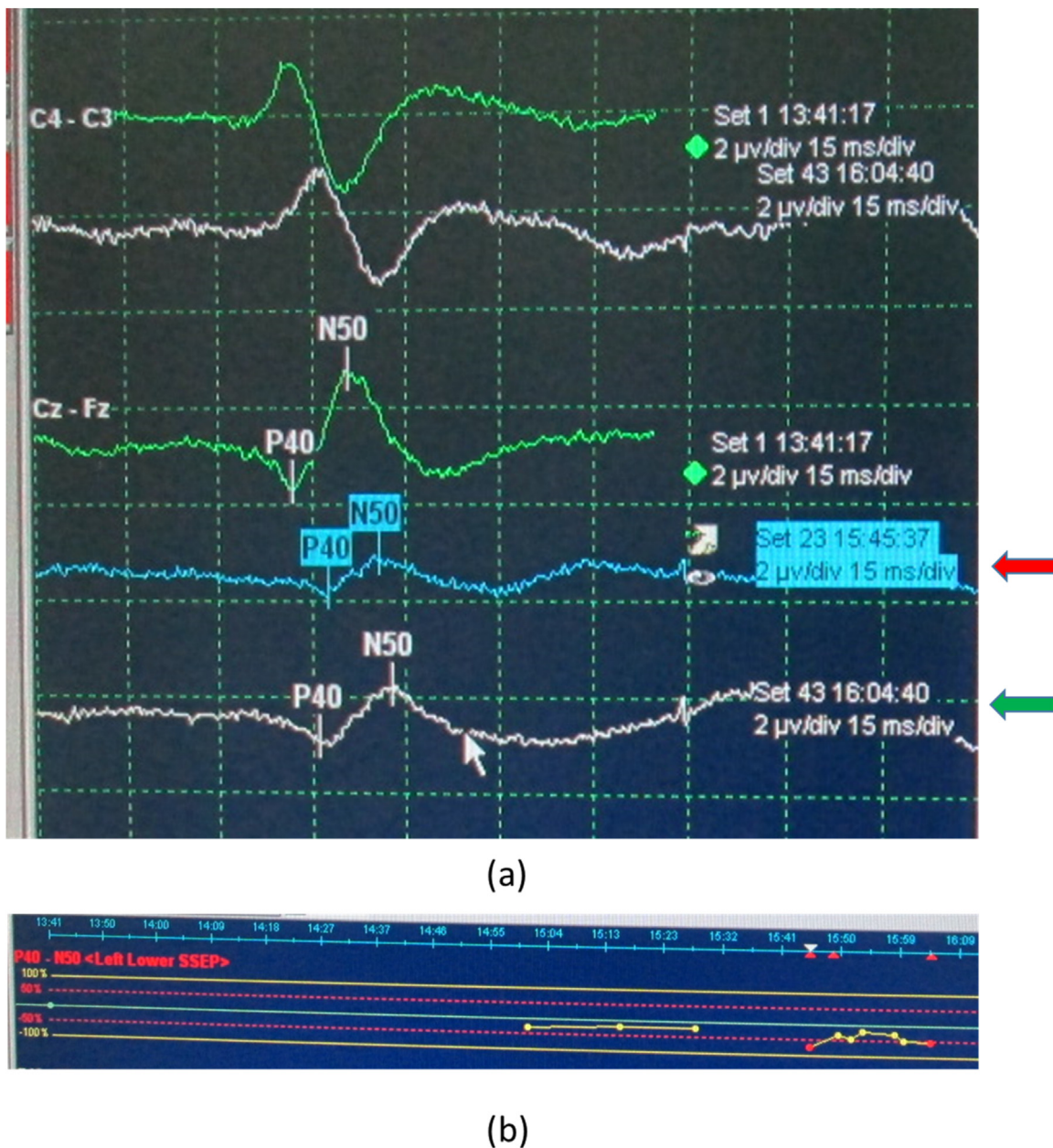
Surgery was performed with general anesthesia and under continuous neurophysiology monitoring of MEP (motor evoked potentials), SSEP (somatosensory evoked potentials) and free-running EMG (electromyography). SSEP of bilateral tibial nerves was performed with the stimulation at the ankle and scalp recording at Cz-Fz and C3'-C4'/C4'-C3'. MEP was performed with stimulation at M3-M4 or M1-M2 (best response) with single

train stimulation of 7 pulses with 200.000Hz frequency, 0.5 ms duration and 0–100 mA intensity and recorded at abductor hallucis brevis muscle and tibialis anterior bilateral muscle. Free run EMG was recorded with the setting of 50 uv/division gain and 100 ms/division sweep at rectus femoris muscle and tibialis anterior muscle bilateral to prevent radix irritation during instrumentation.

Posterior lumbar approach was performed to reach vertebral structure. It was performed the facet joint release and posterior stabilization at the level vertebrae thoracic T11, T12 and lumbar L2, L3. Intra-operative accident was happened when the operator inserted the pedicle screw at level left thoracic T12. SSEP monitor showed left tibial nerve amplitude (P40-N50) decrease more than 50%. The surgeon then decided to pullout the pedicle screw and change the location of pedicle insertion to one level above, vertebrae thoracic T11 (Fig. 3). After changing the screw position, SSEP monitor showed that the nerve amplitude was corrected to the acceptable value (Fig. 4). Final screw insertion was at T10, T11 and L2, L3 on both side. Post-operative evaluation showed that the pain was decreased (VAS 1–2) and there was no deficit in motoric and sensoric function (Fig. 5).

### 2. Discussion

Iatrogenic spinal cord injury was still a feared complication especially in deformity correction surgery such as scoliosis (idiopathic, congenital, neuromuscular, and related syndrome), exaggerated kyphosis, and lordosis. According to the scoliosis research society, the estimated incidence of neurological complications for such surgery was 1%, and it would increase to 1.87% when a combined surgical approach is used [2].



**Fig. 4.** Deterioration of SSEP signal which was monitored at 15.23–15.45p.m. (red arrow). And SSEP signal was improving closed to baseline at 15.50p.m. after screw position change (green arrow).

Mechanisms that could have been responsible for neurologic injury during spine procedure were [5]: (a) direct injury due to surgical trauma, especially during spinal canal decompression or placement of spinal implant; (b) traction and/or compression affecting neural structure, that could be occurred during spinal realignment and deformity correction using spinal instrumentation or as a result of epidural hematoma following corpectomy procedure; (c) ischemia resulting in decreased perfusion of the spinal cord and/or nerve roots, resulting in ischemic injury to neurologic structures (e.g. following ligation of critical segmental vessels supplying the spinal cord or after an episode of sustained hypotension). Ischemia was the most common mechanism that was responsible for neurologic deficit during scoliosis surgery; (d) compressive neuropathy as a result of patient positioning prior to or during surgery (e.g. brachial plexus injury) [5].

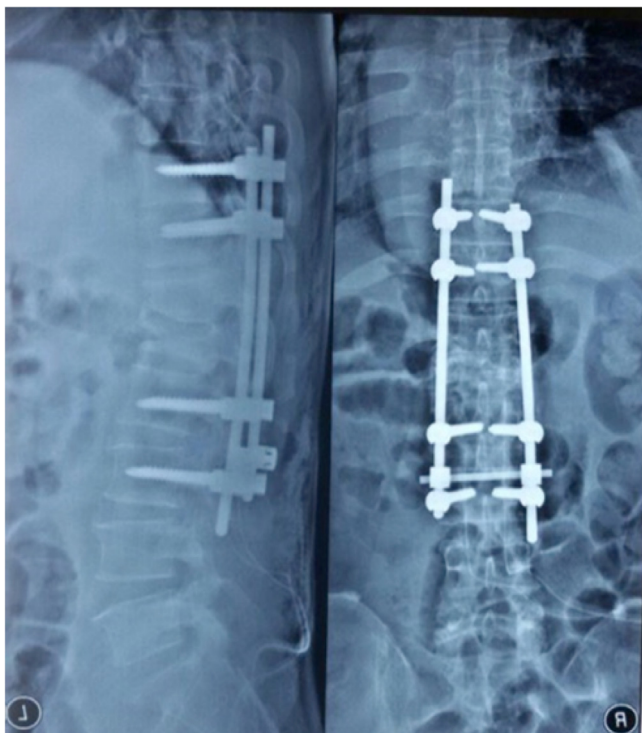
The causes of iatrogenic neurologic sequelae were implant-related damage, such as breach of a pedicle screw into the spinal

canal or foramen, and injury during correction maneuvers, including distraction, compressive force to correct deformity, and the rod rotation technique to realign the vertebra [6]. But among those causes the implant related damage was most common in clinical practice [7].

The ideal pedicle screw should have a maximum diameter and length without breaching the pedicle's cortical layer, the vertebral body. And the direction of insertion should converge on both side of one vertebrae. Lonstein et al., described that the most common type of perforation was anterior cortex (2.8%), and followed by lateral cortex (1.0%), inferior cortex (0.6%), medial cortex of pedicle (0.4%) and superior cortex (0.2%) [2].

Nevertheless, a satisfactory outcome could also be achieved despite sub-optimal screw placement and vice versa. For example, a screw that just barely touches the lower border of the pedicle may cause a clinically apparent radiculopathy and it may require revision. On the other hand, a screw that lies inside the spinal canal





**Fig. 5.** AP and Lateral post-op x-rays of the patient showing posterior stabilization with pedicle screw & rod system (The x ray image was taken on 5 July 2015).

may produce no symptoms at all. Therefore, the evaluation of successful fusion surgery should always include a clinical assessment in addition to an appraisal of screw position [1].

Intraoperative neuromonitoring (IONM) was a technique that now widely accepted to reduce the risk of neurologic complications in spinal surgery. Various IONM modalities allowed continuous functional assessment of the neuromuscular junction, peripheral nerves, spinal cord, brainstem, and cortex during spinal surgery. Among the various IONM techniques available, Somatosensory Evoked Potentials (SSEP), Transcranial electric Muscle Evoked Potentials (tceMEP), and Spontaneous electromyography (free-run EMG) were most frequently used in clinical practice [7].

### 2.1. Somatosensory evoked potential

A previous study reported that false negative SSEP monitoring occurred during surgery in only 0.063% of patients. A large multicenter study had reported that postoperative paraplegia was reduced more than 50%–60% with SSEP monitoring [7]. This was modification of the basic electroencephalography (EEG) in which a cortical or subcortical response to repetitive stimulation of a peripheral mixed nerve was recorded at sites cephalad and caudad to the operative field. Data including signal amplitude (height) and latency (time of occurrence) were recorded continuously during surgery and compared with baseline data. SSEP provided direct information about status of the ascending spinal cord sensory tracts (located in the dorsal medial columns of the spinal cord). There are some limitations such as: (a) SSEP provided only indirect information about the status of the spinal cord motor tracts (located in the anterolateral columns of the spinal cord); (b) SSEP data did not provide real-time data regarding neurologic function because there was a slight delay (usually, 1 min) while the SSEP response was averaged for extraction from background noise; (c) SSEPs could be unrecordable in patients with severe myelopathy, peripheral neuropathy, or obesity. In addition, recording SSEP is not a sen-

sitive technique for monitoring individual nerve root function; (d) SSEPs recording can be disturbed by operating room power equipment (due to electrical interference), halogenated anesthetic agents, nitrous oxide, hypothermia, and hypotension.

Warning signal was very important to be introduced to surgeon during surgery. The surgeon should be notified when SSEP showed a persistent unilateral or bilateral loss of amplitude 50% or greater relative to baseline amplitude. Changes in latency were common and less significant, and spinal cord injury was unlikely if amplitude is unchanged.

### 2.2. Transcranial electric muscle evoked potentials (tceMEP)

Transcranial electric motor-evoked potentials (tceMEP) were neuroelectric impulses elicited by transcranial application of a high-voltage stimulus to electrodes placed over specific scalp regions to excite specific areas of the motor cortex. These descending impulses stimulated corticospinal tract axons and were typically recorded from electrodes placed over key upper and lower extremity peripheral muscles as a compound muscle action potential (CMAP). Motor-evoked potentials could also be recorded directly from the spinal cord (D- and I-waves) via electrodes placed percutaneously or through a laminotomy.

The tceMEP could provide information about the functional integrity of the spinal cord motor tracts that could not be obtained using SSEP. They were extremely sensitive to alterations in spinal cord blood flow resulting from intraoperative hypotension or evolving vascular injury. In addition, alterations in tceMEP presented earlier than changes in SSEP in patients with evolving neurologic injury, which permits earlier initiation of corrective action to prevent permanent neurologic compromise. The tceMEP were not a replacement for SSEP but were used in combination with SSEP to provide a direct measure of both spinal cord sensory and motor tract function, thereby increasing the efficacy of spinal monitoring.

Warning Signal for surgeon was very important. The surgeon should be notified when tceMEP showed a persistent unilateral or bilateral loss of amplitude 65% or greater relative to baseline amplitude [2].

### 2.3. Spontaneous electromyography (free-run EMG)

Spontaneous or free-running electromyography (EMG) was widely applied to monitor selective nerve root function during spinal cord surgery. Unlike SEP and SSEP data, EMG was “real-time” recording from peripheral musculature. Spontaneous EMG could help to prevent postoperative radiculopathy during spinal instrumentation surgery, including pedicle screw placement. This technique did not require stimulation and could be recorded continuously from preselected muscle groups based on the nerve roots at risk. One muscle group per nerve was generally considered appropriate.

At baseline, no muscle activity was recorded from an intact nerve root. Surgical manipulations such as pulling, stretching or compression of nerves provoked spikes or bursts of activity termed neurotonic discharges, resulting in activity in the corresponding innervated muscle(s). Spontaneous EMG was quite sensitive to irritation of the nerve root, such as retraction of spinal cord or nerve root, saline irrigation and manipulation during surgery. However, false spontaneous EMG activation commonly occurred during irrigation with cold water, cauterization and use of a high-speed drill because it was sensitive to temperature change.

#### 2.4. Triggered EMG

Intraoperative triggered EMG detected root irritation or the post injury condition of the root after medial pedicle breach. An irritated or damaged nerve root caused a decrease in electric threshold followed by sudden appearance of CMAP of the specific muscles of the myotome after stimulation via the screw. Each pedicle screw was electrically stimulated with an increasing intensity from 5 to 30 mA (duration, 0.2 ms; frequency, 0.8 Hz). Recordings were made at the level of the lower limb muscles with or without the rectus abdominis muscles (depending on the root levels to test). The recording of muscle activity at an intensity under 10 mA (the classically accepted threshold) argued in favor of a medial breach (close proximity of the screw to the nerve root) [8].

Although IONM generally referred to neurophysiological monitoring, the Stagnara wakeup test, which provided direct evaluation of the patient's motor functions without specialized equipment, was still used when necessary. When neuromonitoring alert (significant decrease or loss of neurophysiologic potentials) occurred during surgery, the surgeon and anesthesiologist should remain calm and communicate with the spinal monitoring personnel as the following steps are taken [2]: (a) check that the electrodes had not become displaced; (b) elevate and maintain the mean arterial blood pressure between 85 and 95 mmHg to prevent spinal cord ischemia; (c) assess if there has been a change in anesthetic technique; (d) reverse any antecedent surgical event (e.g. strut graft/cage placement; surgical maneuvers including distraction, compression, or translation); (e) inspect for an obvious source of neural compression (e.g. bone fragment, hematoma); (f) elevate body temperature and irrigate the wound with warm saline; (g) send an arterial blood gas and laboratory tests to assess for an unrecognized metabolic abnormality or unrecognized low hemoglobin; (h) if the tceMEP/SSEP data failed to recover, a wake-up test and awake clinical examination are considered; (i) depending on the patient's response to the wake-up test and the specific spinal problem undergoing treatment, spinal instrumentation may require removal. The individual clinical scenario and stability of the spine must be considered in decision making; (j) usage of steroids (spinal injury protocol) was an option. Acute trauma as a result of spine instrumentation may result in significant edema, with mass effect causing neurophysiological dysfunction. Immediate administration of an intravenous bolus of methylprednisolone, followed by constant infusion for following 24–48 h, may help ameliorating the mass effect and improving the neurologic outcome.

#### 2.5. Steroid injection

We were still considered for the protocol of steroid injection because the protocol was still implemented and adopted in our hospital. The guideline was a modified guideline of NASCIS 2. But

we were not evaluated the benefit of the steroid injection related to the spinal cord injury.

#### 2.6. Longer segment stabilization

The pedicle screw position changing policy had risk of longer segment stabilization. Thoracic area with the ribs has more rigid structure compare to lumbar. The impact of longer segment stabilization for the thoracic area were less than the lumbar area.

In order to keep away the longer segment stabilization risk, we can strengthen the other side by adding one more rod with rod connector. By this technique we need to prepare the implant system before surgery.

### 3. Conclusion

Insertion of pedicle screw in spinal surgery had a risk of complication that could prevent by usage of intraoperative neurophysiological monitoring. Pedicle screw changing policy is useful for initial treatment of neurophysiologic disturbances. SSEP, tceMEP and free running EMG could detect the neurophysiological reaction of the spinal cord, therefore preventing undesired neurological disturbance post-operatively.

### Disclosure

The authors declare that there is no conflict of interests regarding the publication of this paper

### References

- [1] O.P. Gautschi, B. Schatlo, K. Scachler, E. Tessitore, Clinically relevant complications related to pedicle screw placement in thoracolumbar surgery and their management: a literature review of 35,630 pedicle screws, *Neurosurg. Focus* 31 (2011) E8.
- [2] J. Lonstein, F. Denis, J. Perra, et al., Complication Associated with pedicle screws, *J. Bone Joint Surg.* 81A (1999) 1519–1528.
- [3] M.V. Simon, L. Borges, Intraoperative neurophysiology, *Decompressive Surgery of the Spine* (2010) 219–220.
- [4] T.N. Pajewski, V. Arlet, L.H. Philips, Current approach on spinal cord monitoring: the point of view of the neurologist, the anesthesiologist and spine surgeon, *Eur. Spine J.* 16 (2007) 115–129.
- [5] R.H. Vaughan, V.J. Devlin, Spine secret plus, *Intraoperative Neurophysiologic Monitoring During Spinal Procedures*. 2012 (2016) 220–224.
- [6] A.J. Rahyussalim, I. Saleh, D. Purnaning, T. Kurniawati, Optimization correction strength using contra bending technique without anterior release procedure to achieve maximum correction on severe adult idiopathic scoliosis, *Case Rep. Orthop.* 2016 (2016) 7396853.
- [7] J.H. Park, S.J. Hyun, Intraoperative neurophysiological monitoring in spinal surgery, *World J. Clin. Cases* 3 (9) (2015) 757–860.
- [8] Y. Takata, T. Sakai, K. Higashino, et al., State of the art: intraoperative neuromonitoring in spinal deformity surgery, *J. Med. Invest.* 62 (2015) 103–108.

### Open Access

This article is published Open Access at [sciedirect.com](http://sciedirect.com). It is distributed under the [IJSCR Supplemental terms and conditions](#), which permits unrestricted non commercial use, distribution, and reproduction in any medium, provided the original authors and source are credited.