

Comparative Study of Untethering and Spine-Shortening Surgery for Tethered Cord Syndrome in Adults

Hiroaki Nakashima¹ Shiro Imagama¹ Hiroki Matsui² Yasutsugu Yukawa³ Koji Sato²
Tokumi Kanemura⁴ Mitsuhiro Kamiya⁵ Kenyu Ito¹ Yukihiro Matsuyama⁶ Naoki Ishiguro¹
Fumihiko Kato³

¹ Department of Orthopedic Surgery, Nagoya University Graduate School of Medicine, Nagoya, Japan

² Department of Orthopedic Surgery, Nagoya Daini Red Cross Hospital, Nagoya, Japan

³ Department of Orthopedic Surgery, Chubu Rosai Hospital, Nagoya, Japan

⁴ Department of Orthopedic Surgery, Konan Kosei Hospital, Aichi, Japan

⁵ Department of Orthopedic Surgery, Aichi Medical University, Aichi, Japan

⁶ Department of Orthopedic Surgery, Hamamatsu Medical University, Shizuoka, Japan

Address for correspondence Shiro Imagama, MD, PhD, Department of Orthopedic Surgery, Nagoya University Graduate School of Medicine, 65 Tsurumai, Showa-ku, Nagoya, Aichi 466-8560, Japan (e-mail: imagama@med.nagoya-u.ac.jp).

Global Spine J 2016;6:535–541.

Abstract

Study Design Retrospective multicenter study.

Objective Although untethering surgery has been a standard treatment in patients with adult tethered cord syndrome (TCS), spine-shortening osteotomy (SSO) has recently been performed as an alternative technique. The purpose of this study was to compare the clinical outcomes of the two procedures for TCS in adults.

Methods Fourteen patients (37.7 ± 12.5 years) with TCS were enrolled at 6 hospitals. Their clinical charts, operative records, and follow-up data were reviewed. The categories of tethering lesions were tight terminal filum in 1 patient, lipoma in 5 patients, and lipomyelomeningocele in 8 patients. Eleven patients underwent untethering surgery, and 3 patients underwent SSO surgery.

Results There were no significant differences in age, sex, types of preoperative symptoms, or duration of follow-up between the two groups. The preoperative duration of symptoms was significantly longer (25 ± 12.4 years) and the percentage of those with prior surgery was higher in the SSO group (66.7%). The preoperative pathology was lipomeningocele in all SSO group and lipoma or tight terminal filum in the untethering group. Cerebrospinal fluid leakage and urinary infection occurred in 1 patient each among those with untethering, and massive intraoperative bleeding occurred in 1 patient with SSO. SSO provided better clinical improvement than untethering surgery ($p = 0.003$).

Conclusions Based on this small retrospective case series, SSO appears to provide clinical improvement at least comparable to the untethering procedure, especially in more challenging cases.

Keywords

- ▶ tethered cord syndrome
- ▶ adult
- ▶ untethering
- ▶ spine-shortening osteotomy

received
August 6, 2015
accepted after revision
September 22, 2015
published online
November 26, 2015

DOI <http://dx.doi.org/10.1055/s-0035-1569004>.
ISSN 2192-5682.

© 2016 Georg Thieme Verlag KG
Stuttgart · New York

License terms



Introduction

Tethered cord syndrome (TCS) is a neurologic disorder caused by abnormal traction of the spinal cord resulting from several pathologic conditions: thickened filum terminale, meningocele, lipomyelomeningocele, and split cord malformation.¹⁻¹² Although the majority of affected patients with TCS are children and infants, several studies have shown that TCS also occurs in adults.¹⁻¹² Treatment of TCS in adults is challenging because these malformations are rare, and adults may present with degenerative changes.⁹ Moreover, many adults with TCS have undergone previous surgery for myelomeningocele repair or untethering in childhood, which further complicates treatment.⁷

Untethering surgery has been commonly performed in the management of TCS in adults and children.⁷ However, neurologic recovery with regard to pain and neurologic deficit shows great variation, with improvement rates ranging from 0 to 100%.^{1-9,12} The causes of tethering, preoperative duration of symptoms, and completeness of untethering could cause the outcomes to vary. Moreover, complications, such as cerebrospinal fluid (CSF) leakage and neurologic deterioration, have been frequently reported.^{1,5-9,12,13} Therefore, untethering surgery is not always a promising procedure.¹¹

As an alternative to untethering, Kokubun et al introduced spine-shortening osteotomy (SSO) for patients with TCS caused by a lipomyelomeningocele.¹¹ SSO reduces the tension in the spinal cord and minimizes the perioperative complications.^{10,11} Miyakoshi et al reported that all of the neurologic symptoms in the subjects of one of their studies were relieved without complications after SSO,¹⁰ and it was hoped on the basis of that study that SSO would become a preferable approach for TCS in adults, but the number of patients in their study was small ($n = 3$).

Overall, it remains unclear which procedure is preferable for TCS in adults: untethering surgery or SSO. To the best of our knowledge, there have been no reports on comparisons of the surgical results of the two procedures for TCS in adults. The purpose of this study was thus to fill in this knowledge gap by comparing the surgical results of untethering surgery and SSO for treating TCS in adults.

Materials and Methods

Patient Population

We conducted a retrospective multicenter study. Institutional review board approval was obtained for medical records review. Six hospitals in our spine group were included. To be included, patients (1) had to be > 18 years old at the time of surgery and (2) had to have undergone spinal surgery for TCS. The 14 patients (10 men, 4 women) with a mean age of 37.7 ± 12.5 years (range, 19 to 53 years) had undergone surgery for adult TCS between 1994 and 2010. These patients included those who had either tight terminal filum or secondary lesions that restricted the movement of the caudal spinal cord. The findings in all of the patients satisfied the radiologic criteria for a low-lying

conus medullaris below the level of L2. Patients who underwent surgery for TCS secondary to posttraumatic or postinflammatory conditions were not included in this study. The mean duration of follow-up was 4.7 ± 3.5 years (range, 2.0 to 15.5 years). Surgical treatment was indicated for patients with radiologically proven tethering of the spinal cord who consistently showed progressive neurologic deficits, back/lower limb pain, or sphincter dysfunction.

Surgical Procedures

Untethering Surgery

Lumbosacral laminectomies were performed to obtain adequate exposure of the conus medullaris and cauda equina. Surgeries were performed under continuous electrophysiologic neuro-monitoring with somatosensory-evoked potentials, combined with motor-evoked potentials, and electromyography with direct nerve root stimulation. After identification of the terminal filum, we confirmed electromyography activity on bipolar stimulation before clip ligation and definitive sectioning. Tethering lesions due to lipomas were maximally debulked, and occasionally the Cavitron Ultrasonic Surgical Aspirator was used (Valleylab, Boulder, Colorado, United States). In the patients who had undergone myelomeningocele repair during infancy or previous untethering surgery, meticulous dissection was required to ensure complete release of the spinal cord because of extensive arachnoidal adhesions. Duraplasty using substitute materials was performed at the close of surgery.

Spine-Shortening Osteotomy

SSO was performed at the level of T12 or L1 (**Fig. 1**). The surgical procedure performed at L1 is described below. The laminae and transverse processes of the vertebrae at T12 and L2 were resected, and the pedicle screws were placed bilaterally at these vertebrae. Then, temporary rods were fixed in place for column stability while we performed the osteotomy. The lower half of the T12 lamina, the bilateral lower articular processes at T12, and the bilateral L1 superior articular processes were resected, and the bilateral L1 pedicles and bilateral transverse processes were then removed. A T12 to L1 discectomy and L1 upper one-third vertebral body resection were performed thereafter. Next, the T12 and L2 vertebrae were compressed gradually by using a pedicle screw-rod construct with somatosensory-evoked potentials and motor-evoked potentials monitoring. Bone chips from the excised laminae and spinous processes were also placed over the T12 and L1 laminae for posterior fusion.

Clinical Evaluation

The clinical records were reviewed for preoperative symptoms, duration of symptoms, complications, and neurologic improvements.

Statistical Analysis

Independent sample *t* tests and Fisher exact tests were performed to compare the results between the untethering and SSO groups. Values of $p < 0.05$ were considered to

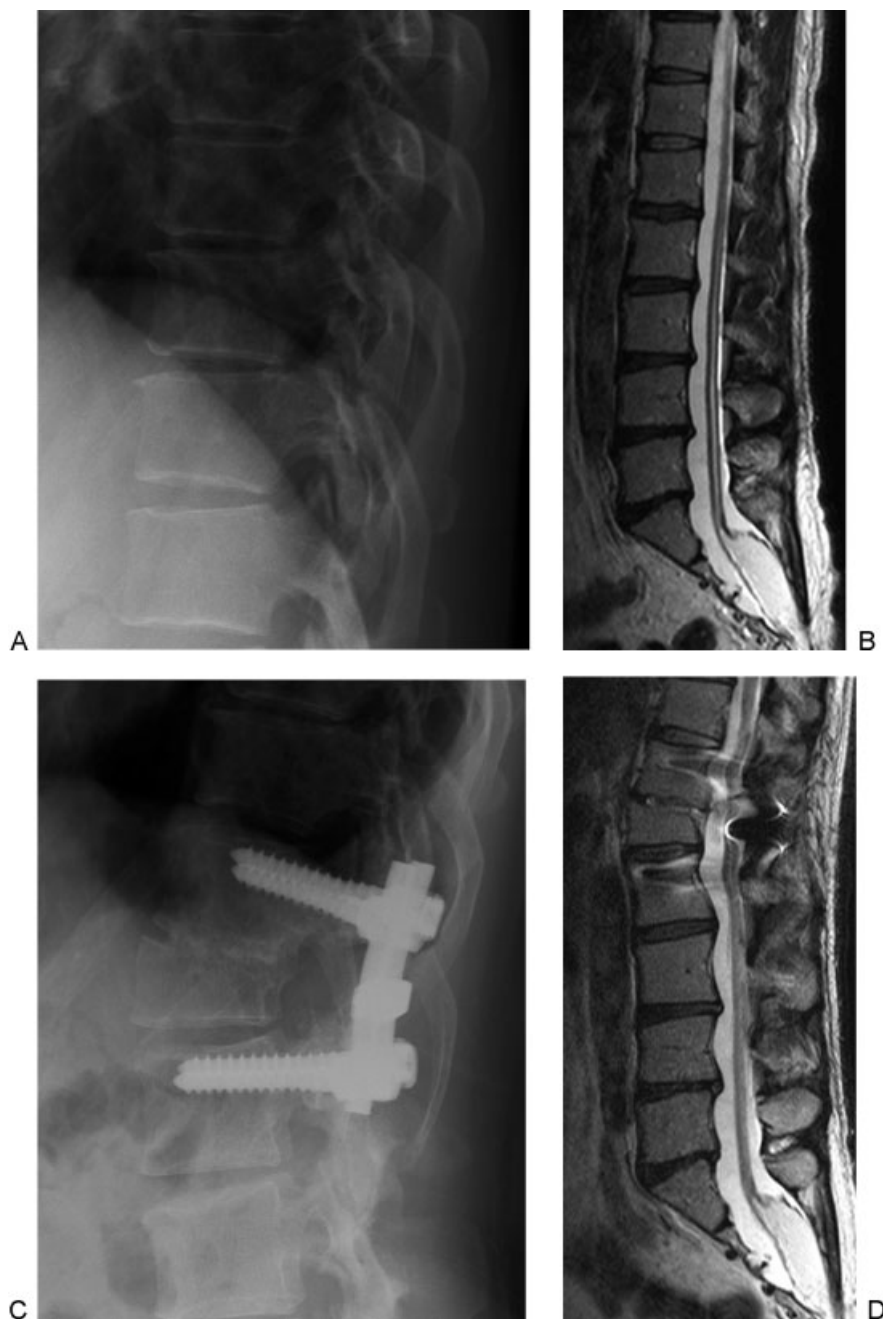


Fig. 1 A representative case of spine-shortening osteotomy. (A) Preoperative lateral radiograph. (B) Preoperative sagittal T2-weighted magnetic resonance imaging (MRI) scan shows a low-placed conus medullaris and terminal filum connected with a subcutaneous lipomyelomeningocele at the S1–S2 level. (C) Postoperative lateral radiograph 3 years after surgery shows complete bone union and significant spine shortening. (D) Postoperative sagittal T2-weighted MRI scan obtained 1 year after surgery. The spinal cord tension was relieved after surgery as shown by preoperative MRI.

indicate statistical significance. Statistical analyses were performed using SPSS version 18 (SPSS Inc., Chicago, Illinois, United States).

Results

Clinical Symptoms

Clinical features at presentation are summarized in ▶ **Table 1**. Cutaneous stigmata (hypertrichosis, dermal

pit, or hairy patch) were the most common features in 12 patients (86%). Other clinical features at presentation included foot deformity in 9 patients (64%) and scoliosis in 4 patients (29%). Altered sensation (numbness or paresthesia) and bladder and/or fecal dysfunction were the most common complaints among 11 patients (79%). Muscle weakness was present in 10 patients (71%), 8 (57%) had leg pain and sciatica, and 6 (43%) had back pain.

Table 1 Summary of clinical features at presentation in 14 patients

Clinical feature	No. of patients (%)
Cutaneous stigma	12 (86)
Bladder and/or fecal dysfunction	11 (79)
Altered sensation	11 (79)
Muscle weakness	10 (71)
Foot deformities	9 (64)
Leg pain and sciatica	8 (57)
Back pain	6 (43)
Spinal deformity	4 (29)

Surgeries

The patients' backgrounds in the two groups are summarized in ▶Table 2. Untethering surgery was performed in 11 patients, and SSO was performed in three patients as initial surgeries for adult TCS in our institutions. The average length of spine shortening was 23.3 mm. There were no significant differences in age, sex, and length of follow-up between the two groups. The duration of symptoms was significantly longer in the SSO group (25 ± 12.4 years) than in the untethering surgery group (8.2 ± 6.3 years; $p = 0.01$). Four patients (29%) underwent prior surgery for myelomeningocele repair during infancy, 2 (18.2%) in the untethering group and 2 (66.7%) in the SSO group; 1 of these 4 patients underwent untethering surgery at 7 years of age. The percentage of patients with prior surgery was higher in the SSO group than in the untethering group, although the difference was insignificant.

Pathologic Findings (▶Table 2)

The variations of tethering lesions were tight terminal filum (present in 1 patient), lipoma (5 patients), and lipomyelomeningocele (8 patients). The patient with tight terminal filum

underwent untethering surgery. The types of lipomyelomeningocele/lipoma (following Chapman classification¹⁴) were dorsal type (present in 5 patients), transitional type (5 patients), and caudal type (3 patients).

Surgeries and Surgical Complications

The mean operation time was 220.2 ± 109.0 minutes for untethering surgery and 399.5 ± 9.6 minutes for SSO; as these numbers clearly indicate, the time was significantly longer for the SSO group ($p = 0.01$). The mean blood loss was 575.5 ± 1316.5 mL in untethering surgery cases, but significantly greater in the SSO group: $1,971.8 \pm 1,739.2$ mL ($p < 0.001$). CSF leakage and urinary infection each occurred in 1 patient in untethering surgery cases, and massive intraoperative bleeding (more than 3,000 mL) was observed in 1 patient in the SSO group. Postoperative bony fusion was confirmed in all patients with SSO by analysis of computed tomography reconstruction images at 1 year after surgery.

Clinical Improvement at Follow-up

Preoperative motor deficits improved in 67% of the patients. In contrast, sensory deficits were less likely to improve; numbness and paresthesias remained unchanged in 55% of the patients. Back and leg pain improved in 50 and 63% of patients, respectively. Urologic dysfunction subjectively improved in 36% of the patients with that complaint. No patients showed worsening of foot deformities and scoliosis.

Improvement in clinical features was compared in the untethering and SSO groups (▶Table 3). The overall clinical improvement was significantly greater in the SSO group (90.0%) than in the untethering group (33.3%; $p = 0.003$).

Reoperation and Recurrent Symptoms

One patient in the untethering surgery group underwent SSO because the symptoms worsened 1 year after untethering. The patient was a 36-year-old man who had undergone myelomeningocele repair during infancy. Untethering surgery was performed as a first procedure at our institution, and a massive arachnoidal scar and adhesion were found intraoperatively. His

Table 2 Patient demographics in the untethering and spine-shortening surgery groups

	Untethering	Spine shortening	<i>p</i> Value
No. of patients	11	3	
Age (y)	39.1 ± 11.6	32.7 ± 14.1	0.47
Sex (M/F)	8/3	2/1	0.84
Duration of symptoms (y)	8.2 ± 6.3	25 ± 12.4	0.01 ^a
No. of patients with previous surgery	2 (18.2%)	2 (66.7%)	0.10
Follow-up (y)	4.7 ± 4.0	4.6 ± 0.4	0.99
Pathologic background			
Lipomeningocele	5	3	0.40
Lipoma	5	0	
Tight terminal filum	1	0	

^a $P < 0.05$.

Table 3 Improvement of clinical features after initial surgery

Clinical feature	Untethering (n = 11)	Spine shortening (n = 3)	p Value
Bladder and/or fecal dysfunction	1/9 (11.1%)	1/2 (50.0%)	0.20
Altered sensation	3/9 (33.3%)	2/2 (100%)	0.57
Muscle weakness	4/7 (57.1%)	3/3 (100%)	0.18
Leg pain and sciatica	3/7 (42.9%)	1/1 (100%)	0.29
Back pain	1/5 (20.0%)	1/1 (100%)	0.12
Gait disturbance	1/2 (50.0%)	1/1 (100%)	0.39
Total	13/39 (33.3%)	9/10 (90.0%)	0.003

Note: Results are the number of patients with improvement/the number of patients with each symptom preoperatively.

preoperative symptoms were muscle weakness, gait disturbance, urinary and fecal dysfunction, and back and leg pain. He experienced improvement in leg pain and motor strength after untethering. However, his condition subsequently deteriorated, and he could not walk by himself 1 year after untethering surgery. He underwent SSO 1.5 years after untethering surgery. His motor weakness marginally improved after SSO; however, he did not improve sufficiently to be able to walk by himself.

During the follow-up period, 2 patients in the untethering surgery group complained of new back pain, and 2 other patients (neither of whom was the previously discussed revision-surgery patient) experienced new leg numbness. One patient showed worsening of sensory function and another patient complained of a new lower back pain in the SSO group. These back pains were treated conservatively with oral analgesic agents.

Table 4 Summary of clinical outcomes in previous studies regarding adult tethered cord syndrome

Authors	Pain	Motor weakness	Altered sensation	Bladder dysfunction
Untethering				
Summary of previous studies	14–100% better; 14% worse	7–87% better; 9% worse	9–45% better; 9% worse	0–50% better; 8% worse
Pang and Wilberger ¹	100% better	87% better		38% better; 8% worse
Iskandar et al ¹³	81% better; 4% worse	48% better; 4% worse		61% better; 6% worse
Hüttmann et al ¹²	91% better; 4% worse	26% better; 6% worse		2% worse
Van Leeuwen et al ⁵	56% better; 6% worse		10% better; 9% worse	14% better
Phi et al ⁶	Back pain: 14% better; 14% worse; leg pain: 11% better; 11% worse		11% better	
Lee et al ⁷	Back pain: 78% better; 3% worse; leg pain: 83% better; 7% worse	64% better; 9% worse	45% better; 5% worse	50% better; 5% worse
Romagna et al ⁸	Back pain: 77% better; leg pain: 47% better	7% better	9% better	0% better
Current study	33% better	57% better	33% better	11% better
Spine shortening				
Summary	38–100% better; 25% worse	13–100% better	25–100% better; 50% worse	0–100% better
Miyakoshi et al ¹⁰	100% better	100% better	100% better	100% better
Kokubun et al ¹¹	38% better; 25% worse	13% better	25% better; 50% worse	0% better
Current study	100%	100%	100%	50%

Table 5 Summary of perioperative complications in previous studies regarding adult tethered cord syndrome

Authors	No. of patients	Follow-up (mean)	Complications		
			CSF leakage	Infection	Others
Untethering surgery					
Pang and Wilberger ¹	23	6 mo–11 y	4%	4% meningitis	0%
Iskandar et al ¹³	34	1 wk–17 y (4 y)	3%	0%	0%
Hüttmann et al ¹²	56	6 mo–12 y (8 y)	19%	4%	2% extradural hematoma/paraparesis; 5% revision CSF; 2% permanent neurologic worsening
Van Leeuwen et al ⁵	57	40 of 57 cases 2 y	12%	0%	2% difficult wound healing
Phi et al ⁶	16	3–123 mo (3.6 y)	6%	0%	19% reoperation
Lee et al ⁷	60	1–125 mo (3.5 y)	15%	5% infection; 2% meningitis	3% neurologic deterioration; 3% reoperation
Klekamp ⁹	85	(5 y)	6%	0%	4% hematoma; 4% urinary tract infection
Romagna et al ⁸	27	(1.3 y)	11%	0%	0%
Current study	11	4.7 y	9%	0%	0%
Spine-shortening surgery					
Miyakoshi et al ¹⁰	3	3–5 y (4 y)	0%	0%	0%
Kokubun et al ¹¹	8	2.5–11.1 y (6.2 y)	0%	0%	25% intraoperative bleeding > 1,000 mL
Current study	3	4.6 y	0%	0%	33% intraoperative bleeding > 3,000 mL

Abbreviation: CSF, cerebrospinal fluid.

Discussion

This study compared clinical outcomes and perioperative complications resulting from untethering and SSO surgery performed on patients with adult TCS. Based on this small retrospective case series, SSO appears to provide clinical improvement at least comparable to that of the untethering procedure, especially in more challenging cases (complex malformations or revision surgery).

TCS in adults is relatively rare and includes a wide spectrum of pathologies.¹ Van Leeuwen et al established four subgroups based on their original tethering pathologies and reported the clinical outcomes after untethering surgery: (1) postrepair myelomeningocele; (2) terminal filum lipoma and tight terminal filum; (3) lipomyelomeningocele and conus lipoma; (4) split cord malformation.⁵ These etiologic backgrounds were found to affect the clinical outcome after untethering. Tight terminal filum is easy to manage and has excellent outcome, but the complexity of the other pathologies makes it difficult to achieve sufficient clinical results in those cases.^{7,9} Patients with such complex pathologies have been found to have a 9 to 50% chance of worsening pain and sensorimotor deficits after untethering.⁷ Unlike pediatric patients, adults experience degenerative changes that further complicate treatment.^{5,9} Moreover, successful untethering correlates with the complexity of the malformation and is extremely difficult to accomplish without causing intraoperative complications.⁹ Consequently, untethering surgery for adult patients with complex tethering pathologies remains challenging.⁹

As an alternative to untethering surgery, Kokubun et al have performed SSO since 1995 in patients with TCS caused by a lipomyelomeningocele because osteotomy is believed to reduce the tension in the spinal cord.^{10,11} Miyakoshi et al reported complete clinical recovery without complications in 2009, which led to the hope that SSO would be the way to reduce perioperative complications and provide better neurologic outcomes.¹⁰ Although Kokubun et al also reported good clinical results after SSO in 2011,¹¹ there have been no reports until now of a comparative study or review of these two procedures.

The summary of outcomes from previous reports (► **Table 4**) shows that the improvement of symptoms after surgery was more frequently observed with SSO. In general, although pain is an initial symptom, it improves significantly after surgery.^{1,5–7,10,11,13} On the other hand, even when the neurologic deficits are not severe at the time of presentation,⁹ sensory deficits and urologic dysfunction are more likely to remain static.^{1,5–7,10,11,13} Preoperative shorter duration of symptoms is associated with favorable clinical outcome because the pathophysiology of TCS is associated with impaired oxidative metabolism in the affected spinal cord.^{7,8,11,15} Meanwhile, a history of prior surgery and complex preoperative categories of tethering lesions are also risk factors for worse clinical outcomes.^{7,9} In the current study, despite longer duration of symptoms, higher rate of prior surgery, and complex preoperative categories of tethering lesions with SSO, the clinical outcome was better with SSO. Although it was difficult to compare clinical outcomes due to the small numbers of patients and

heterogeneity, SSO might be preferable for improving the symptoms in adult TCS after considering these baseline differences.

Perioperative complications are another concern in adult TCS. After untethering surgery, CSF leakage, neurologic deterioration, hematoma, difficult wound healing, and meningitis have been reported (►Table 5).^{1,5-9,13} On the other hand, although massive intraoperative bleeding is a problem, the percentage of cases in which complications have developed has been low with SSO (►Table 5). SSO is a highly invasive type of surgery, but as the average age of adults with TCS ranges from 35 to 46 years,^{1,5-9,13} general health condition is usually good, so SSO could be an appropriate procedure for adults with TCS. In contrast, fusion surgery in SSO might lead to adjacent segment disease that may require subsequent surgery in the long term after SSO. Patients needing surgery for adult TCS are relatively young, so this postoperative complication would be a serious disadvantage of SSO for them. In addition, in terms of cost-effectiveness, SSO is substantially more costly than untethering, which means that SSO can be a financially viable option mainly just in very challenging cases of adult TCS.

This study has two limitations in particular. First, it was a retrospective review of a small number of patients, due to the fact that the number of adult patients with TCS is relatively low, so securing a large number of patients for the study (especially patients with SSO) was difficult even though the study was a multicenter one. Second, a standardized surgical protocol was not used, and the surgical approach was left to the discretion of the attending surgeon. Thus, additional prospective randomized large-scale studies are needed to confirm our results.

In conclusion, SSO appears to provide clinical improvement at least comparable to that achievable with the untethering procedure, especially in more challenging cases where successful untethering is quite difficult to achieve, such as cases of patients with complex malformations, arachnoid adhesions, and revision surgery. Generally, although surgical invasiveness is greater with SSO, this procedure could be considered as a viable alternative to untethering surgery in complicated adult TCS cases.

Disclosures

Hiroaki Nakashima, none

Shiro Imagama, none

Hiroki Matsui, none

Yasutsugu Yukawa, none

Koji Sato, none

Tokumi Kanemura, none

Mitsuhiro Kamiya, none

Kenyu Ito, none

Yukihiro Matsuyama, none

Naoki Ishiguro, none

Fumihiko Kato, none

References

- Pang D, Wilberger JE Jr. Tethered cord syndrome in adults. *J Neurosurg* 1982;57(1):32-47
- Gupta SK, Khosla VK, Sharma BS, Mathuriya SN, Pathak A, Tewari MK. Tethered cord syndrome in adults. *Surg Neurol* 1999;52(4):362-369, discussion 370
- Akay KM, Erşahin Y, Cakır Y. Tethered cord syndrome in adults. *Acta Neurochir (Wien)* 2000;142(10):1111-1115
- Yamada S, Lonser RR. Adult tethered cord syndrome. *J Spinal Disord* 2000;13(4):319-323
- van Leeuwen R, Notermans NC, Vandertop WP. Surgery in adults with tethered cord syndrome: outcome study with independent clinical review. *J Neurosurg* 2001;94(2, Suppl):205-209
- Phi JH, Lee DY, Jahng TA, Chung CK, Kim HJ. Tethered cord syndrome in adulthood: reconsidering the prognosis. *J Korean Neurosurg Soc* 2004;36:114-119
- Lee GY, Paradiso G, Tator CH, Gentili F, Massicotte EM, Fehlings MG. Surgical management of tethered cord syndrome in adults: indications, techniques, and long-term outcomes in 60 patients. *J Neurosurg Spine* 2006;4(2):123-131
- Romagna A, Suchorska B, Schwartz C, Tonn JC, Zausinger S. Detethering of a congenital tethered cord in adult patients: an outcome analysis. *Acta Neurochir (Wien)* 2013;155(5):793-800
- Klekamp J. Tethered cord syndrome in adults. *J Neurosurg Spine* 2011;15(3):258-270
- Miyakoshi N, Abe E, Suzuki T, Kido T, Chiba M, Shimada Y. Spine-shortening vertebral osteotomy for tethered cord syndrome: report of three cases. *Spine (Phila Pa 1976)* 2009;34(22):E823-E825
- Kokubun S, Ozawa H, Aizawa T, Ly NM, Tanaka Y. Spine-shortening osteotomy for patients with tethered cord syndrome caused by lipomyelomeningocele. *J Neurosurg Spine* 2011;15(1):21-27
- Hüttmann S, Krauss J, Collmann H, Sörensen N, Roosen K. Surgical management of tethered spinal cord in adults: report of 54 cases. *J Neurosurg* 2001;95(2, Suppl):173-178
- Iskandar BJ, Fulmer BB, Hadley MN, Oakes WJ. Congenital tethered spinal cord syndrome in adults. *J Neurosurg* 1998;88(6):958-961
- Chapman PH. Congenital intraspinal lipomas: anatomic considerations and surgical treatment. *Childs Brain* 1982;9(1):37-47
- Yamada S, Won DJ, Pezeshkpour G, et al. Pathophysiology of tethered cord syndrome and similar complex disorders. *Neurosurg Focus* 2007;23(2):E6