

Use of a locking intramedullary nail for the treatment of initial varus proximal humeral fracture: a prospective pilot study

Xiang-Yi Deng^{1,#}, Zhi-Yuan Fan^{1,#},
Bao-Fu Yu^{2,#}, Bin-Bin Ni¹, Wei Wang¹,
Hua Lu¹ and Hao Shen¹ 

Abstract

Objective: To evaluate the feasibility of locked intramedullary nailing, rather than locking plate fixation combined with fibular allograft augmentation, for initial varus proximal humeral fractures.

Methods: This prospective pilot study enrolled patients with initial varus proximal humeral fractures that were treated with a locking intramedullary nail. Radiography was performed to evaluate fracture healing. Data about the visual analogue scale (VAS) pain score, Constant Shoulder Score (CSS), Disabilities of the Arm, Shoulder and Hand (DASH) score, American Shoulder and Elbow Surgeons (ASES) score and shoulder range of motion (ROM) were recorded.

Results: Twenty patients, including eight with Neer two-part and 12 with three-part fractures, were followed-up, with a mean time of 12.3 months. All patients sustained fractures that healed without re-varus. During the last follow-up, the shoulder function of the patients had recovered well, with a mean VAS pain score of 1.4, a mean CSS of 83.1, a mean DASH score of 80.8, a mean ASES score of 84.0 and a satisfactory ROM. In one patient, the proximal locking screw came out and was removed via a second surgery.

Conclusions: The use of a locking intramedullary nail alone for initial varus proximal humeral two-/three-part fractures was feasible. This treatment has advantages, such as preventing re-varus and causing milder surgical trauma, than that seen with a locking plate.

[#]These authors contributed equally to this work

Corresponding author:

Hao Shen, Department of Orthopaedic Surgery, Xinhua Hospital Affiliated to Shanghai Jiaotong University School of Medicine, 1665 Kongjiang Road, Shanghai 200092, China.

Email: shenhao@xinhumed.com.cn

¹Department of Orthopaedic Surgery, Xinhua Hospital Affiliated to Shanghai Jiaotong University School of Medicine, Shanghai, China

²Department of Hand Surgery, Huashan Hospital, Fudan University, Shanghai, China



Keywords

Locking intramedullary nail, varus proximal humeral fractures, internal fixation, fibular allograft augmentation, re-varus

Date received: 10 March 2020; accepted: 28 May 2020

Introduction

Proximal humeral fractures account for 4–5% of all types of fracture;¹ and their incidence ranks second after hip and distal radius fractures among elderly patients.^{2–4} With the aging population, the incidence of this type of fracture may continue to rise and the risk for surgical treatment may gradually increase. A previous study reported that between 1990 and 2010, the incidence of proximal humeral fractures in patients aged over 65 years increased by 28%, and the rate of surgical treatment increased by more than 40%.⁵

Initial varus proximal humeral fracture refers to proximal humerus fracture with varus displacement of the humeral head and it is characterized by the comminution of the medial cortex. This type of fracture is susceptible to re-varus displacement due to the lack of medial support after reduction. Moreover, individuals with initial varus proximal humeral fractures have a higher risk of re-varus displacement, complications, screw penetration and reoperation than those with valgus fractures.⁶ The locking plate system, including the PHILOS® plate, is still the main internal implant used for the fixation of this fracture. However, complications, including the varus displacement of humerus head, commonly occur after simple lateral locking plate fixation.⁷ The methods used to prevent varus displacement of the humeral head include the use of humeral screw, allogeneic fibula intramedullary implantation, double-plate fixation and shortening of the

humeral shaft with internal displacement.^{8,9} These methods have disadvantages, such as immune reaction, infections and surgical trauma, and they should be used with caution in specific patients.^{8,9}

In recent years, the use of intramedullary nails for the treatment of proximal humeral fractures has gradually increased and the overall clinical outcome has been good.^{10–12} However, whether the use of a locking intramedullary nail alone is suitable for initial varus proximal humeral fractures has not been reported in the literature. Thus, the current prospective pilot study aimed to evaluate the feasibility of using a locking intramedullary nail alone for the treatment of initial varus proximal humeral fractures.

Patients and methods

Patient population

This prospective pilot study enrolled consecutive patients with confirmed initial varus proximal humeral fractures, based on their medical history and preoperative shoulder radiography and computed tomography scan results, from the Department of Orthopaedic Surgery, Xinhua Hospital Affiliated to Shanghai Jiaotong University School of Medicine, Shanghai, China between June 2015 and December 2017. The inclusion criteria were as follows: (i) patients with proximal humeral two-/three-part fractures; (ii) patients with varus displacement of the humeral head (neck-shaft angle < 110°).

The exclusion criteria were as follows: patients with (i) proximal humeral fracture with humeral head splitting; (ii) combined with shoulder dislocation; (iii) open or pathological fractures; (iv) combined with rotator cuff injury; (v) signs of infection at the injured shoulder.

This study was conducted in accordance with the guidelines of the Declaration of Helsinki for Human Research. As the techniques used in this study were routine, the requirement for ethical approval was waived. Written informed consent was obtained from all participants and their rights to privacy were preserved.

Surgical procedures

A senior surgeon (H.S.) performed the procedure within 2 weeks after sustaining the fractures. The patients were placed in a beach chair position. Then, a 5-cm incision was created at the anterior-lateral acromion (Figure 1). In cases of three-part fractures with greater tuberosity displacement, an appropriate extension of the distal incision was made to facilitate intraoperative reduction of greater tuberosity while protecting the axillary nerve. The deltoid was split to expose the proximal humerus and rotator cuff. For the two-part fractures, 2.0-mm Kirschner wires were drilled into the humeral head. Using the Joy-stick technique, the fracture was reduced under traction to correct the humeral head varus deformity. The guide needle of the intramedullary nail was drilled in rotator interval and intraoperative radiography was performed to confirm the correct point of humeral head entry. This point was selected as the intersection of the axis of the humeral shaft with the humeral head, which is equivalent to a medial of 1.0 cm, at the junction of the humeral head and greater tuberosity. A hollow reamer was used to enlarge the hole under the guidance of the guide needle. Then, a TRIGEN[◇] straight

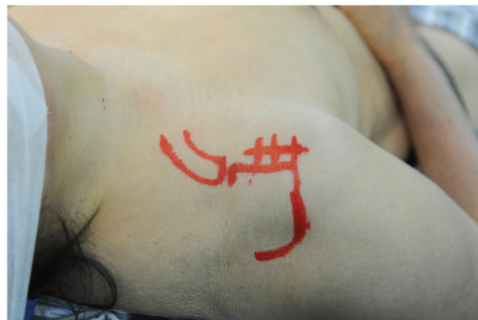

Figure 1. A typical 5-cm incision that was created at the anterior-lateral acromion during surgery in a prospective pilot study that aimed to evaluate the feasibility of using a locking intramedullary nail alone for the treatment of initial varus proximal humeral fractures.

interlocking intramedullary nail with a proximal diameter of 8.0 mm and distal diameter of 7.0 mm (TRIGEN[◇] Humeral Nail; Smith & Nephew, Cordova, TN, USA) was inserted. The position of the intramedullary nail and reduction of fractures were confirmed via intraoperative radiography (Figure 2). Three proximal and two distal locking screws were inserted. For the three-part fractures with greater tuberosity displacement, after inserting the intramedullary nail, the greater tuberosity fragment was reduced and maintained with the reduction forceps; then, the proximal locking screws were inserted (Figure 3).

Postoperative rehabilitation procedures and follow-up

After the surgery, the patients used an abduction pillow sling for 6 weeks and passive motion exercises were performed immediately. Full active and active-assisted motion exercises were initiated 4–6 weeks after surgery. Then, the patients were also encouraged to undergo rehabilitation training with the guidance of rehabilitation physicians. After the surgery, the patients were followed-up at the outpatient

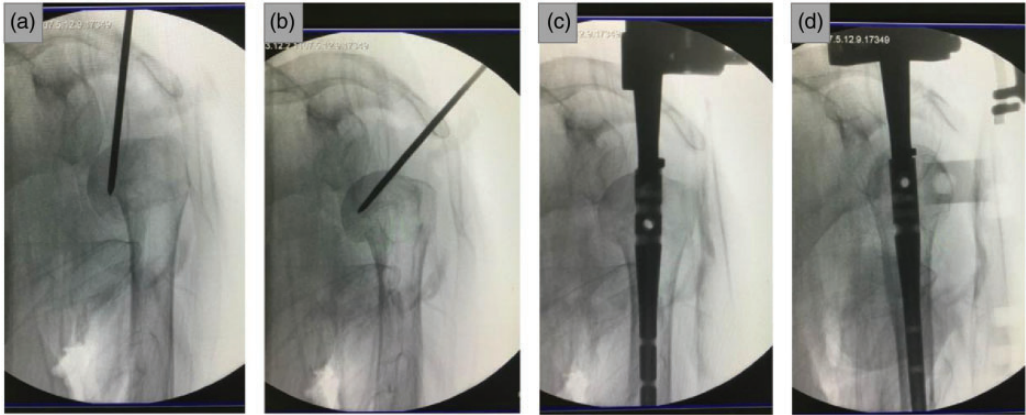


Figure 2. Typical intraoperative radiography showing the reduction during surgery in a prospective pilot study that aimed to evaluate the feasibility of using a locking intramedullary nail alone for the treatment of initial varus proximal humeral fractures. A, B: A 2.0-mm Kirschner wire was drilled into the humeral head. Using the Joy-stick technique, the fracture was reduced. C, D: An intramedullary nail was inserted.

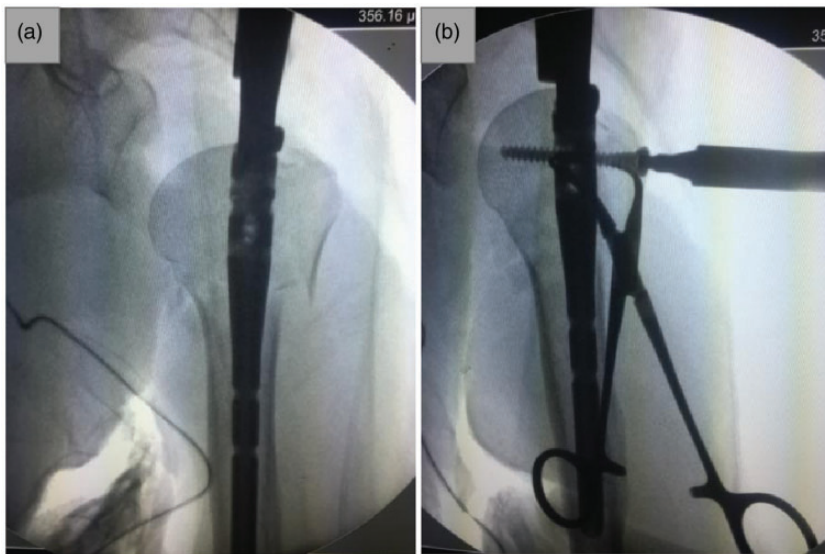


Figure 3. Typical intraoperative radiography showing the reduction and fixation during surgery in a prospective pilot study that aimed to evaluate the feasibility of using a locking intramedullary nail alone for the treatment of initial varus proximal humeral fractures. (a) The greater tuberosity fragment was reduced and maintained with the reduction forceps. (b) The proximal locking screws were inserted.

department at 2, 6 and 12 weeks and every 3 months thereafter. Radiography was performed to evaluate fracture healing and to measure the neck-shaft angle. A visual

analogue scale (VAS) pain score, Constant Shoulder Score (CSS), Disabilities of the Arm, Shoulder and Hand (DASH) score, American Shoulder and Elbow Surgeons

(ASES) score and shoulder range of motion (ROM) were recorded to evaluate postoperative shoulder function.

Complications correlated with fracture healing, such as varus deformity healing (neck-shaft angle $< 110^\circ$), bone nonunion, delayed healing, infection, failure of internal fixation, humeral head ischaemic necrosis, rotator cuff injury and shoulder impact syndrome, were recorded. To measure the neck-shaft angle, a line from superior to the inferior borders of articular surface was created. A second line perpendicular to the first line was created, which went through the centre of the humeral head. The neck-shaft angle was defined as the angle created by this line and the line bisecting the humeral shaft. When the bone fracture line was disappeared on radiography and the clinical physical examinations showed no tenderness, percussion pain, or abnormal movement, the fractured bone was considered to be healing.

Statistical analyses

The SPSS[®] statistical package, version 16.0 (SPSS Inc., Chicago, IL, USA) for Windows[®] was used to calculate the mean \pm SD of continuous data.

Results

This prospective pilot study enrolled 21 patients diagnosed with initial varus proximal humeral fracture. Of the 21 patients, 20, including eight with Neer two-part and 12 with three-part fractures, were followed-up with a mean duration of 12.3 months (range 8–15 months). One patient was lost to follow-up. There were seven men and 13 women. The mean \pm SD age of the participants was 64.2 ± 4.78 years (range 54–75 years).

According to the radiography results obtained during follow-up, all patients presented with anatomical reduction and

fractures that healed with a mean \pm SD time of 2.47 ± 0.41 months. The mean \pm SD postoperative immediate neck-shaft angle was $134.2^\circ \pm 7.4^\circ$ (range 118° – 145°). During the last follow-up, the mean \pm SD neck-shaft angle was $133.7^\circ \pm 7.2^\circ$ (range 118° – 145°). Moreover, the shoulder function of the patients recovered well, with a mean \pm SD VAS pain score of 1.4 ± 0.8 (range 0–3), a mean \pm SD CSS of 83.1 ± 4.8 (range 74–93), a mean \pm SD DASH score of 80.8 ± 4.4 (range 73–88) and a mean \pm SD ASES of 84.0 ± 3.4 (range 78–94).

In terms of the shoulder ROM, the mean angle values of forward flexion, abduction, external rotation and backward extension were 138.7° (range 115° – 175°), 105.7° (range 70° – 135°), 39.3° (range 25° – 47°) and 30.6° (range 20° – 38°), respectively.

In terms of postoperative complications, the proximal locking screw came out and was removed via a second surgery after fracture healing in one patient. None of the patients presented with complications, such as humeral head varus deformity, bone nonunion, delayed healing, infection, failure of internal fixation and ischaemic necrosis of the humeral head. A typical case is shown in Figure 4.

Discussion

A proximal humerus fracture of the varus type is characterized by the comminution of the medial cortex of the proximal humerus after the displacement of the humerus head. The need for surgical treatment may gradually increase due to the aging population. The locking plate system is still the main internal implant used for the fixation of this type of fracture and some researchers reported the utilization of a modified plate for the management of proximal humerus fracture and even proximal humeral aseptic nonunion.^{7,13,14} However, varus displacement of the humerus head occasionally

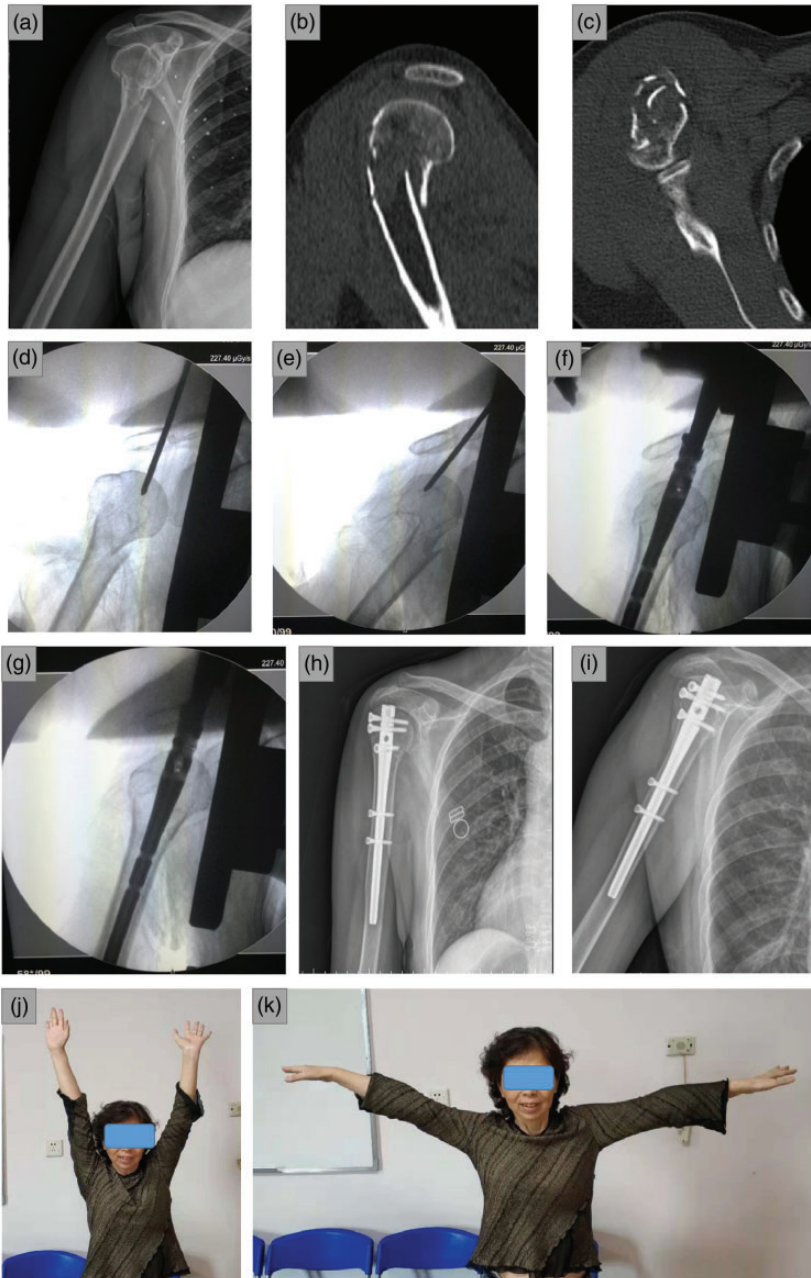


Figure 4. A typical patient diagnosed with initial varus proximal humeral fracture and treated with a locking intramedullary nail alone. (a, b, c) Preoperative radiography and computed tomography scans revealed an initial varus proximal humeral fracture. (d, e, f, g) Intraoperative radiography of the reduction and fixation. (h, i) Radiography conducted 3 months after surgery revealed fracture healing. (j, k) Shoulder range of motion 1 year after surgery.

occurs. Thus, attention must be paid to re-varus displacement after reduction and fixation, and postoperative re-varus displacement is challenging to prevent.

The lack of effective medial support after reduction and the effect of the rotator cuff on the medial side might have caused re-varus after surgery, thereby resulting in a series of complications, including internal fixation failure.^{15,16} In a prognostic analysis of proximal humeral three-/four-part fractures treated with locking plates, the incidence of complications in the varus fracture group was significantly higher than that in the valgus fracture group (79% versus 19%).¹⁷ Regarding this problem, several researchers have proposed different methods for preventing re-varus of the humeral head. For example, a previous study showed the importance of using an oblique locking screw in preventing re-varus of the humeral head and argued that placing an oblique locked screw in the inferomedial region of the proximal fragment could achieve more stable medial column support and could obtain a better reduction maintenance.¹⁸ Some studies have shown that if the medial cortex is effectively supported, anatomical reduction can be achieved and maintained, and the use of an oblique locked screw in the inferomedial region may prevent re-varus.^{19,20} However, this technique is extremely challenging for varus fractures often accompanied by medial comminution. To restore an effective medial support, the use of allogeneic fibula implants to restore medial support was proposed.²¹ Several subsequent studies have shown the efficacy of this technique.^{22–26} However, allogeneic fibula implantation undoubtedly increases the risk of surgical trauma and infection. Moreover, some researchers have proposed the use of double-plate technology to prevent varus of the humeral head and biomechanical experiments have also validated that the double-plate technology can

provide a more stable medial fixation.^{27,28} However, placing a plate on the medial humerus may damage the anterior humeral artery, resulting in necrosis of the humeral head.^{27,28}

In recent years, with the development of proximal humeral intramedullary nails, the use of intramedullary nails for proximal humeral fractures has gradually increased and has achieved good therapeutic outcomes.^{10,28–30} A previous study used straight interlocking intramedullary nails in 26 patients with proximal humeral fractures, all of whom were completely treated, with a mean \pm SD shoulder function Constant score of 83.3 ± 16.7 ; and the patients were satisfied with the treatment outcomes.¹² However, the efficacy of straight interlocking intramedullary nails in treating fractures of the varus type, a special type of proximal humeral fracture, has not been reported.

In this current prospective pilot study, the use of straight interlocking intramedullary nails in the treatment of varus proximal humeral fractures achieved excellent outcomes. In total, 20 patients had fracture healing within 3 months, with a mean \pm SD time of 2.47 ± 0.41 months. Moreover, none of the patients experienced complications such as bone nonunion, delayed healing, infection, failure of internal fixation and ischaemic necrosis of the humeral head after surgery. The patients had a high shoulder function score, with a mean \pm SD ASES of 84.0 ± 3.4 , a mean \pm SD CSS of 83.1 ± 4.8 and a mean \pm SD DASH score of 80.8 ± 3.7 . Although a proximal locking screw came out in one patient, the patient's shoulder motion was restored after screw removal. Moreover, the use of straight interlocking intramedullary nails was effective in preventing re-varus displacement of the humeral head after surgery. In this current study, the mean \pm SD postoperative immediate neck-shaft angle was $134.2^\circ \pm 7.4^\circ$ (range 118° – 145°).

During the last follow-up, the mean \pm SD neck-shaft angle was $133.7^\circ \pm 7.2^\circ$ (range 118° – 145°); and this result indicated that straight cross-locked intramedullary nails had mechanical advantages in controlling the varus head, and they could resist varus stress produced by rotator cuff pulling. The main intramedullary nail holds the humeral head and intramedullary nail implantation improves the medial support. Therefore, the precondition for the treatment of proximal humeral fracture of varus type using the intramedullary nail is that the bone of the humeral head around the point of intramedullary nail insertion is not destroyed; otherwise, the intramedullary nail cannot firmly hold the humeral head. Moreover, the treatment of the proximal humeral fracture with an intramedullary nail has advantages, including less trauma, shorter operative time, lower amount of bleeding during surgery and faster recovery of post-operative function compared with a locking plate. In this current study, the use of straight intramedullary nails with their entry point at the muscle bellied portion rather than at the traditional tendon portion effectively prevented the occurrence of iatrogenic rotator cuff injury and the incidence of postoperative shoulder pain was significantly reduced.

In this current study, 20 patients had a VAS score of 0–3, with an mean of 1.4, which was similar to that in a previous study.¹¹ It was reported that 60% (18/30) of patients experienced some loss of motion after antegrade nailing for humeral shaft fractures.³¹ In this current study, some patients also had some loss of motion. In our opinion, this was associated with the patients' pre-injury condition, since the mean age of patients in this current study was 64.2 years, which was much higher than that of the previous study.³¹ Older patients may have shoulder periarthritis or acromion impact so their postoperative rehabilitation can be more challenging. A

comparison between bilateral shoulder function should also be included in future studies.

The current study had several limitations. First, this was a case series study and the sample size was small. Although this current study showed that the use of upright interlocking intramedullary nails for the treatment of varus proximal humeral fractures had good outcomes, only 20 patients were included. In terms of the fracture types, the patients only presented with two-/three-part fractures. A comparative study using a control group treated with locking plate fixation combined with fibular allograft augmentation was not performed. Thus, further studies should be conducted to validate whether the treatment effect of intramedullary nails on this type of fracture was better than that of locking plates.

In conclusion, locked intramedullary nailing alone, rather than locking plate fixation combined with fibular allograft augmentation, was feasible for the treatment of initial varus proximal humeral two-/three-part fractures with milder surgical trauma.

Acknowledgements

We would like to thank all of the study participants.


Declaration of conflicting interest

The authors declare that there are no conflicts of interest.

Funding

This research received no specific grant from any funding agency in the public, commercial, or not-for-profit sectors.

ORCID iD

Hao Shen  <https://orcid.org/0000-0003-3366-5343>

References

- Bell JE, Leung BC, Spratt KF, et al. Trends and variation in incidence, surgical treatment, and repeat surgery of proximal humeral fractures in the elderly. *J Bone Joint Surg Am* 2011; 93: 121–131.
- D'Elia G, Roselli G, Cavalli L, et al. Severe osteoporosis: diagnosis of non-hip non-vertebral (NHNV) fractures. *Clin Cases Miner Bone Metab* 2010; 7: 85–90.
- Warriner AH, Patkar NM, Curtis JR, et al. Which fractures are most attributable to osteoporosis. *J Clin Epidemiol* 2011; 64: 46–53.
- Nobile F, Carta S, Fortina M, et al. Displaced 3- and 4-part proximal humeral fractures: evaluation and management with an intramedullary nail within 48 h, in the emergency department. *J Acute Dis* 2016; 5: 154–159.
- Khatib O, Onyekwelu I and Zuckerman JD. The incidence of proximal humeral fractures in New York State from 1990 through 2010 with an emphasis on operative management in patients aged 65 years or older. *J Shoulder Elbow Surg* 2014; 23: 1356–1362.
- Chandrappa MH, Hajibandeh S and Hajibandeh S. Postoperative outcomes of initial varus versus initial valgus proximal humerus fracture: a systematic review and meta-analysis. *J Clin Orthop Trauma* 2017; 8: 14–20.
- Owsley KC and Gorczyca JT. Fracture displacement and screw cutout after open reduction and locked plate fixation of proximal humeral fractures [corrected]. *J Bone Joint Surg Am* 2008; 90: 233–240.
- Zhu L, Liu Y, Yang Z, et al. Locking plate fixation combined with iliac crest bone autologous graft for proximal humerus comminuted fracture. *Chin Med J (Engl)* 2014; 127: 1672–1676.
- Berkes MB, Little MT, Lazaro LE, et al. Intramedullary allograft fibula as a reduction and fixation tool for treatment of complex proximal humerus fractures with diaphyseal extension. *J Orthop Trauma* 2014; 28: e56–e64.
- Boileau P, d'Ollonne T, Bessi re C, et al. Displaced humeral surgical neck fractures: classification and results of third-generation percutaneous intramedullary nailing. *J Shoulder Elbow Surg* 2019; 28: 276–287.
- Hao TD and Huat AWT. Surgical technique and early outcomes of intramedullary nailing of displaced proximal humeral fractures in an Asian population using a contemporary straight nail design. *J Orthop Surg (Hong Kong)* 2017; 25: 2309499017713934.
- Lopiz Y, Garcia-Coiradas J, Garcia-Fernandez C, et al. Proximal humerus nailing: a randomized clinical trial between curvilinear and straight nails. *J Shoulder Elbow Surg* 2014; 23: 369–376.
- Egol KA, Ong CC, Walsh M, et al. Early complications in proximal humerus fractures (OTA Types 11) treated with locked plates. *J Orthop Trauma* 2008; 22: 159–164.
- Rollo G, Porcellini G, Rotini R, et al. A new plate design to treat displaced 3–4 parts proximal humeral fractures in comparison to the most tested and used plate: clinical and radiographic study. *Med Glas (Zenica)* 2019; 16. doi:10.17392/1033-19.
- Rollo G, Rotini R, Pichierri P, et al. Grafting and fixation of proximal humeral aseptic nonunion: a prospective case series. *Clin Cases Miner Bone Metab* 2017; 14: 298–304.
- Agudelo J, Sch rmann M, Stahel P, et al. Analysis of efficacy and failure in proximal humerus fractures treated with locking plates. *J Orthop Trauma* 2007; 21: 676–681.
- Solberg BD, Moon CN, Franco DP, et al. Locked plating of 3- and 4-part proximal humerus fractures in older patients: the effect of initial fracture pattern on outcome. *J Orthop Trauma* 2009; 23: 113–119.
- Gardner MJ, Weil Y, Barker JU, et al. The importance of medial support in locked plating of proximal humerus fractures. *J Orthop Trauma* 2007; 21: 185–191.
- Katthagen JC, Schwarze M, Meyer-Kobbe J, et al. Biomechanical effects of calcar screws and bone block augmentation on medial support in locked plating of proximal humeral fractures. *Clin Biomech (Bristol, Avon)* 2014; 29: 735–741.
- Ponce BA, Thompson KJ, Raghava P, et al. The role of medial comminution and calcar restoration in varus collapse of proximal

- humeral fractures treated with locking plates. *J Bone Joint Surg Am* 2013; 95: e113(1-7).
21. Gardner MJ, Boraiah S, Helfet DL, et al. Indirect medial reduction and strut support of proximal humerus fractures using an endosteal implant. *J Orthop Trauma* 2008; 22: 195–200.
 22. Matassi F, Angeloni R, Carulli C, et al. Locking plate and fibular allograft augmentation in unstable fractures of proximal humerus. *Injury* 2012; 43: 1939–1942.
 23. Cha H, Park KB, Oh S, et al. Treatment of comminuted proximal humeral fractures using locking plate with strut allograft. *J Shoulder Elbow Surg* 2017; 26: 781–785.
 24. Kim DS, Lee DH, Chun YM, et al. Which additional augmented fixation procedure decreases surgical failure after proximal humeral fracture with medial comminution: fibular allograft or inferomedial screws. *J Shoulder Elbow Surg* 2018; 27: 1852–1858.
 25. Little MT, Berkes MB, Schottel PC, et al. The impact of preoperative coronal plane deformity on proximal humerus fixation with endosteal augmentation. *J Orthop Trauma* 2014; 28: 338–347.
 26. Chow RM, Begum F, Beaupre LA, et al. Proximal humeral fracture fixation: locking plate construct ± intramedullary fibular allograft. *J Shoulder Elbow Surg* 2012; 21: 894–901.
 27. Choi S, Kang H and Bang H. Technical tips: dualplate fixation technique for comminuted proximal humerus fractures. *Injury* 2014; 45: 1280–1282.
 28. He Y, Zhang Y, Wang Y, et al. Biomechanical evaluation of a novel dualplate fixation method for proximal humeral fractures without medial support. *J Orthop Surg Res* 2017; 12: 72. doi.org/10.1186/s13018-017-0573-4.
 29. Boudard G, Pomares G, Milin L, et al. Locking plate fixation versus antegrade nailing of 3- and 4-part proximal humerus fractures in patients without osteoporosis. Comparative retrospective study of 63 cases. *Orthop Traumatol Surg Res* 2014; 100: 917–924.
 30. Liu QH, Sun W, Zhou JL, et al. A new approach for the treatment of proximal humeral fractures using the TRIGEN proximal humeral nail. *Eur J Orthop Surg Traumatol* 2014; 24: 467–474.
 31. Patino JM. Treatment of humeral shaft fractures using antegrade nailing: functional outcome in the shoulder. *J Shoulder Elbow Surg* 2015; 24: 1302–1306.