

Metronomic palliative chemotherapy in maxillary sinus tumor

Vijay M. Patil, Vanita Noronh, Amit Joshi, Ashay Karpe, Vikas Talreja, Arun Chandrasekharan, Sachin Dhumal, Kumar Prabhash

Abstract

Background: Metronomic chemotherapy consisting of methotrexate and celecoxib recently has shown promising results in multiple studies in head and neck cancers. However, these studies have not included patients with maxillary sinus primaries. Hence, the role of palliative metronomic chemotherapy in patients with maxillary sinus carcinoma that is not amenable to radical therapy is unknown. **Methods:** This was a retrospective analysis of carcinoma maxillary sinus patients who received palliative metronomic chemotherapy between August 2011 and August 2014. The demographic details, symptomatology, previous treatment details, indication for palliative chemotherapy, response to therapy, and overall survival (OS) details were extracted. SPSS version 16 was used for analysis. Descriptive statistics have been performed. Survival analysis was done by Kaplan–Meier method. **Results:** Five patients had received metronomic chemotherapy. The median age was 60 years (range 37–64 years). The proportion of patients surviving at 6 months, 12 months, and 18 months were 40%, 40%, and 20%, respectively. The estimated median OS was 126 days (95% confidence interval 0–299.9 days). The estimated median survival in patients with an event-free period after the last therapy of <6 months was 45 days, whereas it was 409 days in patients with an event-free period postlast therapy above 6 months ($P = 0.063$). **Conclusion:** Metronomic chemotherapy in carcinoma maxillary sinus holds promise. It has activity similar to that seen in head and neck cancers and needs to be evaluated further in a larger cohort of patients.

Key words: Chemotherapy, head and neck cancer, maxilla, metronomic, palliative

Introduction

Carcinoma maxillary sinus is a rare malignancy.^[1-3] The majority of these patients (64.3%) present with locally advanced disease.^[1,2,4] The outcomes of these patients with locally advanced disease even when treated aggressively are dismal.^[1-4] Most patients fail locoregionally.^[5] Salvage surgery or reradiation is rarely feasible due to the location of these tumors.^[6] Palliative chemotherapy remains the only option for these patients.

Palliative chemotherapy in head and neck cancers provides a modest survival benefit.^[7,8] However, the studies which have helped establish the role of palliative chemotherapy as a valid treatment option in head and neck cancer patients excluded patients with maxillary sinus tumors.^[9] Metronomic chemotherapy consisting of methotrexate and celecoxib recently has shown promising results in multiple studies in head and neck cancers.^[10,11] However, even these studies have not included patients with maxillary sinus primaries. Hence, the role of palliative a metronomic chemotherapy in patients with maxillary sinus carcinoma that is not amenable to radical therapy is unknown. We therefore planned this audit to answer this question.

Methods

Selection of cases

This was a retrospective analysis of carcinoma maxillary sinus patients who received palliative metronomic chemotherapy between August 2011 and August 2014. Patients with maxillary sinus carcinoma were selected for this analysis and subjected to following selection criteria.

1. Squamous cell carcinoma maxillary sinus
2. Recipient of metronomic chemotherapy.

All of these patients had received oral methotrexate 15 mg/m² weekly with celecoxib 200 mg twice daily orally. These drugs were discontinued after disease progression or intolerable side effects. All of these patients were evaluated

7 days after start of therapy and then subsequently every month till death. They underwent an axial imaging every 2 months for response assessment.

Data extraction

We maintain a prospective palliative chemotherapy database in the head and neck cancer medical oncology unit. We selected patients from this database, who fulfilled the above selection criteria. The demographic details, symptomatology, previous treatment details, indication for palliative chemotherapy, response to therapy, and overall survival (OS) details were extracted.

Data analysis

The extracted details were entered into an excel sheet and analysis was done in SPSS for Windows, Version 16.0. Chicago, SPSS Inc. Descriptive statistics have been performed. Survival analysis was done by Kaplan–Meier method. OS was calculated from the date of start of metronomic therapy to the date of death. Patients who did not have event (death) were censored during the OS estimation.

Results

Demographic features

There were eight patients of carcinoma maxilla who received palliative chemotherapy. Five (62.5%) of these eight patients had received metronomic chemotherapy. The median age was 60 years (range 37–64 years) and four patients (80%) were males. None of the patients had medical comorbidities. All five patients had a previous history of oral tobacco use (100%). None of these patients had a history of smoking or alcohol use. The baseline median hemoglobin and serum albumin levels were 10.9 g/dl (9.3–12.6 g/dl) and 3.6 (3–4.5 g/L), respectively. All five patients had an Eastern Cooperative Oncology Group performance status of 1.

Tumor details

The baseline T classification (at initial diagnosis and not at recurrence) for these patients was T3 in 1 patient (20%), T4a in

This is an open access article distributed under the terms of the Creative Commons Attribution-NonCommercial-ShareAlike 3.0 License, which allows others to remix, tweak, and build upon the work non-commercially, as long as the author is credited and the new creations are licensed under the identical terms.

For reprints contact: reprints@medknow.com

How to cite this article: Patil VM, Noronh V, Joshi A, Karpe A, Talreja V, Chandrasekharan A, *et al.* Metronomic palliative chemotherapy in maxillary sinus tumor. *South Asian J Cancer* 2016;5:56-8.

Access this article online

Quick Response Code:



Website: www.sajc.org

DOI: 10.4103/2278-330X.181626

Department of Medical Oncology, Tata Memorial Hospital, Mumbai, Maharashtra, India

Correspondence to: Dr. Kumar Prabhash,

E-mail: kumarprabhastmh@gmail.com

2 patients (40%), and T4b in 2 patients (40%). The baseline N classification was N0 in 1 patient (20%), N1 in 1 patient (20%), N2a in 1 patient (20%), and N2b in 2 patients (40%). The group staging was Stage IVa in 3 patients (60%) and Stage IVb in 2 patients (40%).

The indications for palliative chemotherapy were upfront locally advanced disease unsuitable for locoregional treatment in one patients (20%) and recurrent disease not amenable for locoregional treatment in four patients (80%). None of the patients had metastatic disease.

Previous treatment details

Four patients (80%) had received prior therapy. All four patients (80%) had been exposed to platinum therapy previously and three patients (60%) received prior radiation treatment. Three patients (60%) received docetaxel as induction chemotherapy. The details of previous treatment received are shown in Table 1. The best response to last received chemotherapy regimen (as a part of induction chemotherapy) was partial response in one patient and progressive disease in two patients. One patient who had progressive disease came directly for palliative therapy and the other received chemoradiation and then had progression. The median event-free period following the previously received treatment was 3 months (range 0–9 months).

Symptomatology and response

Three patients had swelling over the face, and all five patients had pain at the start of palliative therapy. Symptomatic response within 8 days of start of therapy was noted in three patients (60%). A decline in the analgesic requirement was seen in three patients (60%) and an appreciable decline in facial swelling was seen in one patient (20%).

Radiological response assessment done at 2 months after start of treatment showed partial response in one patient, stable disease in three patients, and progressive disease in 1 patient.

Compliance and toxicity

The median time on metronomic chemotherapy was 89 days (range 7–589 days). There were no Grade 3–4 toxicities observed in the study. The most common toxicity seen was anemia in 3 patients (60%). The grade of anemia was Grade 2 in 1 patient and Grade 1 in 2 patients. Dose modification of methotrexate was required in one patient in view of rise in serum creatinine clearance.

Overall survival

The median follow-up was 589 days. Four out of five patients have progressed, and all four have died. The site of progression was local in all four patients. The proportion of patients surviving at 6 months, 12 months, and 18 months were 40%, 40%, and 20% respectively. The estimated median OS was 126 days (95% confidence interval 0–299.9 days) [Figure 1]. The estimated median survival in patients with an event-free period after the last therapy of <6 months was 45 days, while it was 409 days in patients with an event-free period postlast therapy above 6 months ($P = 0.063$).

Discussion

The cohort of patients in this study had multiple poor prognostic features. The majority of patients (80%; $n = 4$) had previous exposure to chemotherapy and response was progressive disease in 40% of patients. Three patients had

Table 1: Details of previous treatment

Previous treatment	Patients (%)
NACT-CTRT	02 (40)
NACT (then PD on it)	01 (20)
Surgery-CTRT	01 (20)

NACT=Neoadjuvant chemotherapy, CTRT=Chemoradiation, PD=Progressive disease

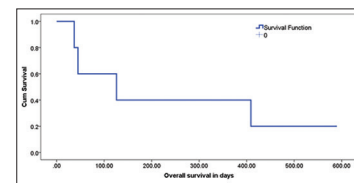


Figure 1: The overall survival graph

received previous radiation. Only one patient had an event-free period from the last therapy of longer than 6 months. The baseline hemoglobin was below the lower level of normal for all patients. All these are poor prognostic features in head and neck cancer patients.^[8] Hence, we need to interpret the results of our present study within the appropriate context.

The median OS was 126 days which is dismal. However, metronomic chemotherapy provided a median OS of 409 days in patients with event-free period postlast therapy longer than 6 months. In head and neck cancer study (not inclusive of maxillary patients), similar findings have been noted. In a study published by us on oral cancers, patients who failed within 3 months of last treatment had median estimated OS of 75 days, whereas it was 132 days ($P = 0.41$) in patients with an event-free period between 3 and 6 months.^[12] We reported similar data in another randomized study in head and neck cancer, where the median estimated OS was 212 days in patients with an event-free period below 6 months, whereas it was 261 days ($P = 0.41$) in patients with event-free period above 6 months.^[10] Thus, it appears that the activity of metronomic chemotherapy in patients with maxillary cancer with an event-free period of >6 months is similar to that seen in general head and neck cancers.

Palliative chemotherapy options in carcinoma maxilla are very limited. A PubMed search was performed by the authors using the search terms “Palliative chemotherapy carcinoma maxilla” and “Palliative chemotherapy maxillary sinus carcinoma.” We identified seven articles in the first search and 13 in the second search. However, none of the articles discussed the use of palliative chemotherapy in maxillary sinus carcinomas. Ours is the first study exclusively reporting on the results of palliative metronomic chemotherapy in maxillary sinus carcinoma. The evidence generated from this study does suggest that metronomic chemotherapy provides symptomatic relief and disease stabilization in maxillary sinus carcinoma patients. In patients with event-free period above 6 months, it also provides meaningful prolongation in OS.

Our study is not without fallacies. It is a retrospective analysis, the cohort of patients is small, there is no comparable cohort of intravenous chemotherapy, and the majority of patients had poor prognostic features. However, carcinoma maxilla is a rare disease and hence performed a study with a large sample size in this tumor will be difficult, especially in a single center. In view of its locally advanced nature of presentation,

most patients would have been exposed to some form of chemotherapy as part of the initial multimodality treatment. In addition, there is a high likelihood the cohort of patients seen in routine clinical practice, would be similar to the patients reported in the present study.

Conclusion

Metronomic chemotherapy in carcinoma maxillary sinus holds promise. It has activity similar to that seen in head and neck cancers and needs to be evaluated further in a larger cohort of patients.

Financial support and sponsorship

Nil.

Conflicts of interest

There are no conflicts of interest.

References

- Dubal PM, Bhojwani A, Patel TD, Zuckerman O, Baredes S, Liu JK, *et al.* Squamous cell carcinoma of the maxillary sinus: A population-based analysis. *Laryngoscope* 2016;126:399-404.
- Kumar V, Sindhu VA, Rathanaswamy S, Jain J, Pogal JR, Akhtar N, *et al.* Cancers of upper gingivobuccal sulcus, hard palate and maxilla: A tertiary care centre study in North India. *Natl J Maxillofac Surg* 2013;4:202-5.
- Noronha V, Patil VM, Joshi A, Krishna MV, Dhupal S, Juvekar S, *et al.* Induction chemotherapy in technically unresectable locally advanced carcinoma of maxillary sinus. *Chemother Res Pract* 2014;2014:487872.
- Qureshi SS, Chaukar DA, Talole SD, D'Cruz AK. Squamous cell carcinoma of the maxillary sinus: A Tata Memorial Hospital experience. *Indian J Cancer* 2006;43:26-9.
- McMahon JD, Wong LS, Crowther J, Taylor WM, McManners J, Devine JC, *et al.* Patterns of local recurrence after primary resection of cancers that arise in the sinonasal region and the maxillary alveolus. *Br J Oral Maxillofac Surg* 2013;51:389-93.
- Zylka S, Zawadzki M, Postula S, Bien S. Recurrence of cancer of the paranasal sinuses after primary treatment – Analysis of conditions and results of salvage treatment. *Otolaryngol Pol* 2010;64:44-9.
- Parikh P, Patil V, Agarwal JP, Chaturvedi P, Vaidya A, Rathod S, *et al.* Guidelines for treatment of recurrent or metastatic head and neck cancer. *Indian J Cancer* 2014;51:89-94.
- Vermorken JB, Specenier P. Optimal treatment for recurrent/metastatic head and neck cancer. *Ann Oncol* 2010;21 Suppl 7:vii252-61.
- Vermorken JB, Mesia R, Rivera F, Remenar E, Kaweckki A, Rottey S, *et al.* Platinum-based chemotherapy plus cetuximab in head and neck cancer. *N Engl J Med* 2008;359:1116-27.
- Patil VM, Noronha V, Joshi A, Muddu VK, Dhupal S, Bhosale B, *et al.* A prospective randomized phase II study comparing metronomic chemotherapy with chemotherapy (single agent cisplatin), in patients with metastatic, relapsed or inoperable squamous cell carcinoma of head and neck. *Oral Oncol* 2015;51:279-86.
- Patil V, Noronha V, Krishna V, Joshi A, Prabhash K. Oral metronomic chemotherapy in recurrent, metastatic and locally advanced head and neck cancers. *Clin Oncol (R Coll Radiol)* 2013;25:388.
- Patil VM, Noronha V, Joshi A, Pinninti R, Dhupal S, Bhattacharjee A, *et al.* Metronomic chemotherapy in platinum-insensitive failures and/or early failures postmultimodality management in oral cancers. *Indian J Med Paediatr Oncol* 2015;36:161-5.



We are pleased to launch the educational activities of the newly formed Immunology Leadership Network. Very soon we will be bringing to you educational modules to simplify this rapidly evolving field. For further details please contact Dr. Anantbhushan A Ranade (draaranade@yahoo.com)

We bring to you the “International Journal of Molecular and ImmunoOncology”. Further details can be obtained from its Editor, Dr. Randeep Singh (drrandeep@yahoo.co.in) or by visiting the website - www.ijmio.com

We bring to you the 67th year of the “Indian Journal of Medical Sciences” in a totally revamped look under a new editorial team. Please visit the websites www.IndianJMedSci.org or www.IndianJMedSci.com. For further details please contact Dr. Shashank Joshi, Editor-in-Chief (shashank.sr@gmail.com) or Dr. Ashish Gulia, Editor (aashishgulia@gmail.com)