

Arthroscopic Treatment of Pigmented Villonodular Synovitis of the Hip Using Puncture Capsulotomy

Mark R. Nazal, M.P.H., Ali Parsa, M.D., and Scott D. Martin, M.D.



Abstract: Pigmented villonodular synovitis (PVNS) is a monoarticular, benign tumor arising from the synovium. Although classically treated with open synovectomy, arthroscopic treatment has demonstrated good clinical outcomes. The arthroscopic management of hip PVNS has been described as technically challenging due to difficulty obtaining the appropriate exposure. The purpose of this technical report is to describe a novel technique that allows for sound excision of PVNS during hip arthroscopy using a puncture capsulotomy. Full visualization throughout the central and peripheral compartments is key to achieving meticulous surgical excision and ablation, with careful attention to the medial and lateral synovial folds and gutters. It is important to avoid chondral injury by using a high outflow rate of irrigation to maintain a constant temperature, to ablate the blood supply of nodular lesions, and to not use a shaver as this may disseminate tumor cells. Multifactorial advancements in hip arthroscopy have permitted adequate visualization and exposure of PVNS lesions, making them amenable to arthroscopic synovectomy. Puncture capsulotomy does not require capsular closure, preserves the iliofemoral ligament, and minimizes exposure of extra-articular structures to the hip joint environment. Recurrence rates are lower in arthroscopic management compared with open management, at 7.7% and 17.8%, respectively.

Pigmented villonodular synovitis (PVNS) is a monoarticular, benign tumor derived from the synovium of a joint. It presents along a spectrum of synovial involvement from localized to diffuse^{1,2} (Table 1). Although it is often slowly progressive, PVNS occurs with various grades of aggression from slowly progressive to invasive with malignant-type characteristics, even invading extra-articular structures^{3,4} (Fig 1). PVNS is typically identified on magnetic resonance imaging (MRI) after patients present with joint pain. The hyperplastic synovium classically shows as a hypointense “blooming” artifact best seen on fast-field

echo sequencing^{5,6} (Fig 2). Historically, the standard of care for the treatment of PVNS, regardless of the affected joint, has been open synovectomy. However, several recent studies have shown that arthroscopic procedures have promising utility in the management of PVNS of various joints with acceptable recurrence rates and favorable outcomes.⁷⁻¹¹

PVNS classically affects young adults, with roughly the same incidence in both genders. It arises most commonly in the knee, followed by the hip, which accounts for up to 15% of all cases.^{1,12,13} Arthroscopic treatment of PVNS in the knee has demonstrated good clinical outcomes, including shorter hospital stay, faster rehabilitation period, and lower morbidity.^{11,14} Despite encouraging initial outcomes of arthroscopic treatment of PVNS in the hip joint, the procedure has been described as technically challenging due to difficulty obtaining appropriate exposure for a complete synovectomy.^{7,9} The purpose of this report is to describe a novel technique that allows for sound excision of PVNS during hip arthroscopy.

Surgical Technique

Patient Positioning

The patient is positioned supine on an advanced traction table (Supine Hip Positioning System, Smith & Nephew, Andover, MA). Gentle traction is applied to

From Sport Medicine, Department of Orthopaedic Surgery, Massachusetts General Hospital, Partners Health System (M.R.N., A.P., S.D.M.), Boston, Massachusetts, U.S.A.; and Orthopedic Research Center, Mashhad University of Medical Sciences (A.P.), Mashhad, Iran.

The authors report the following potential conflicts of interest or sources of funding: The study was supported by the Conine Family Fund for Joint Preservation. Full ICMJE author disclosure forms are available for this article online, as [supplementary material](#).

Received December 10, 2018; accepted February 16, 2019.

Address correspondence to Ali Parsa, M.D., Suite 400, 175 Cambridge St, Boston, MA, 02118, U.S.A. E-mail: aliparsadr@yahoo.com

© 2019 by the Arthroscopy Association of North America. Published by Elsevier. This is an open access article under the CC BY-NC-ND license (<http://creativecommons.org/licenses/by-nc-nd/4.0/>).

2212-6287/181500

<https://doi.org/10.1016/j.eats.2019.02.007>

Table 1. Surgical Pearls and Pitfalls

Pearls	Pitfalls
PVNS can present with various grades of aggression from slowly progressive to invasive with malignant-type characteristics, including invasion into extra-articular structures.	Extended capsulotomy techniques may expose extra-articular structures to the hip joint environment, which may allow for extra-articular spread of PVNS, as opposed to a puncture capsulotomy technique. With aggressive occurrences, failure to treat quickly can result in significant joint destruction.
The gross appearance of PVNS varies from villus, thread-like structures to globous masses with a tan, brown, or red coloration.	Addressing only the typical villous lesions with a stalk and missing other morphologic lesions may lead to failure to eliminate tumor burden, increasing the risk of recurrence.
Full visualization is necessary to achieve meticulous surgical excision and ablation of all PVNS.	Incomplete visualization, due to either inadequate portal placement or incomplete arthroscopic examination, may lead to failure to eliminate tumor burden, increasing the risk of recurrence.
When there is an obvious stalk to the lesion it is critical to ablate the blood supply and surrounding synovium.	If the blood supply is not ablated there may be an increased risk of recurrence; furthermore, bleeding could limit the arthroscopic view intraoperatively.
It is important to keep the irrigation at a constant temperature using a brisk outflow rate.	If the lavage temperature is allowed to rise, it can cause chondral injury, with temperatures above 50°C causing chondrolysis.
PVNS, pigmented villonodular synovitis.	

the contralateral hip while in 40° to 45° of abduction; this provides enough space for C-arm visualization. Intermittent traction is used during the procedure.¹⁵ In conjunction with anatomic landmarks, fluoroscopy is used to verify adequate positioning of the hip. The patient is prepared and draped in standard fashion.

Puncture Capsulotomy

Placement of specific portals will be discussed later in the context of the arthroscopic examination. A puncture capsulotomy technique is used as opposed to an interportal capsulotomy or T-capsulotomy (Video 1). At each of the portals, an obturator is used to create a puncture in the distended hip joint capsule (Stryker, Kalamazoo, MI; Fig 3). A flexible radiofrequency device is then inserted through the puncture, and a limited amount of intermittent ablation is used on the interior surface of the capsule to create a circular entrance.

Visualization, Excision, and Synovectomy

The gross pathology of PVNS occurs along a spectrum, from villus, thread-like structures to globous masses with a tan, brown, or red coloration¹⁶ (Fig 4). Full visualization throughout the central and peripheral compartments, including the gutters, is key as it is critical to achieve meticulous surgical excision and ablation of all the PVNS and surrounding synovium to eliminate tumor burden and reduce recurrences. Therefore, accessory portals are established as needed.

Arthroscopic examination begins with thorough inspection of the entire central compartment, including the acetabular notch, pulvinar, and the superior, inferior, and lateral capsular recesses. The posterolateral portal is used to access any lesions in the acetabular notch and pulvinar. Additionally, the anterior, mid-anterior, and Dienst (placed one-third of the distance

between the anterior superior iliac spine and the anterolateral portal) portals are particularly helpful for accessing lesions found in the anterosuperior capsular recess extending out laterally (Fig 5).¹⁷

Next, the peripheral compartment is entered using the anterolateral and proximal anterolateral portals. Meticulous inspection begins with the medial synovial fold and gutter, in which the distal anterolateral portal is particularly helpful for lesions identified in this area. This portal is established 4 cm distal and 1 cm anterior to the anterolateral portal. Next the capsular reflections off the femoral neck and acetabulum are thoroughly evaluated, followed by the lateral synovial fold and

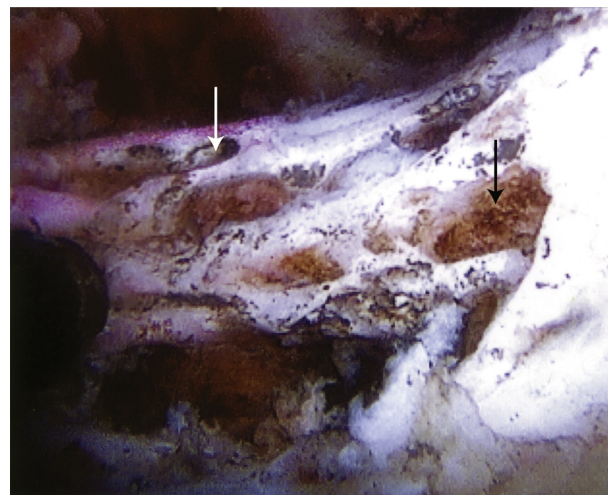


Figure 1. Arthroscopic view from the midanterior portal of aggressive osteolytic pigmented villonodular synovitis (PVNS) lesions (black arrow) eroding into the femur, creating a pathologic finding known as “wormholes” (white arrow). PVNS occurs along a spectrum of aggression from indolent to invasive with malignant-type characteristics. Photo courtesy of the author, Scott D. Martin.

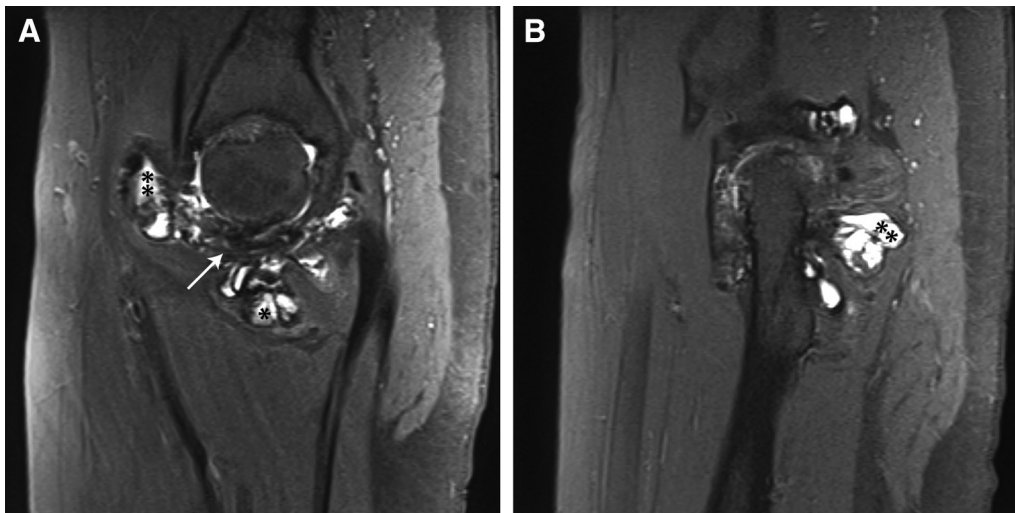


Fig 2. (A) Magnetic resonance imaging (MRI) T1-weighted sagittal image of the right hip, demonstrating hypointense “blooming” (white arrow) artifact caused by the hemosiderin in the hyperplastic synovium. In addition, the diffuse pigmented villonodular synovitis lesions have infiltrated the entire joint space, both the central compartment (asterisk) and peripheral compartment (double asterisk), and penetrated into the joint capsule. (B) MRI T1-weighted sagittal image of the right hip, demonstrating a significant amount of posterior invasion (double asterisk) of the peripheral compartment. Photos courtesy of the author, Scott D. Martin.

gutter, for which the proximal anterolateral portal is particularly helpful. This portal is established 3 cm proximal to the anterolateral portal. It is critical to emphasize that careful attention to the medial and lateral synovial folds and gutters is necessary. In our experience, lesions are frequently found in these locations. Additionally, PVNS might be seen around the ligamentum teres and pulvinar and may extend into the femoral head-neck junction.

Any lesions that are encountered are completely excised and ablated while maintaining meticulous hemostasis. First, a radiofrequency ablator is used to simultaneously cut and ablate the base of the lesion; then the tumor mass is retrieved in toto using a tissue grasper. Afterward a radiofrequency ablator and flexible ultrasonic chisel are used for ablation synovectomy of the tumor bed.

While performing these steps, there are 3 points to keep in mind (Table 1). First, it is important to keep the irrigation at a constant temperature using a high outflow rate. If the lavage temperature is allowed to rise it can cause chondral injury, with temperatures above 50°C causing chondrolysis.¹⁸ Second, when a nodular lesion is identified with an obvious stalk, it is important to ablate the blood supply to that lesion. And third, it is critical to emphasize that a shaver must not be used, as this may disseminate tumor cells.

Any other concomitant pathology of the labrum or bony morphology is addressed after the ablation synovectomy. In this technique, because a puncture capsulotomy was used, the capsular tissue is intact with the exception of the portal entrances; therefore capsular

repair is not necessary. Finally, the arthroscope and instruments are removed, and the portals are closed using 3-0 nylon sutures.

Discussion

Radical synovectomy is the accepted cornerstone of PVNS treatment.¹⁹ This is classically performed using an open technique, but several recent studies have reported positive results with the arthroscopic management of hip PVNS.⁷⁻⁹ Advances in operative technique, arthroscopic equipment, and surgeons’ experience have permitted obtaining adequate visualization and

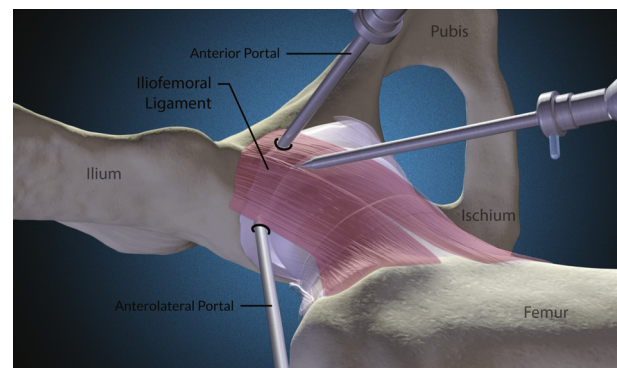


Fig 3. Right hip of a patient in the supine position showing puncture capsulotomy of the anterior and anterolateral portal. This technique preserves the integrity of the capsule and therefore does not require capsular closure. In addition, it preserves the iliofemoral ligament and minimizes exposing the extra-articular structures to the hip joint environment. Illustration by Nicole Wolf, M.S., ©2018. Printed with permission.

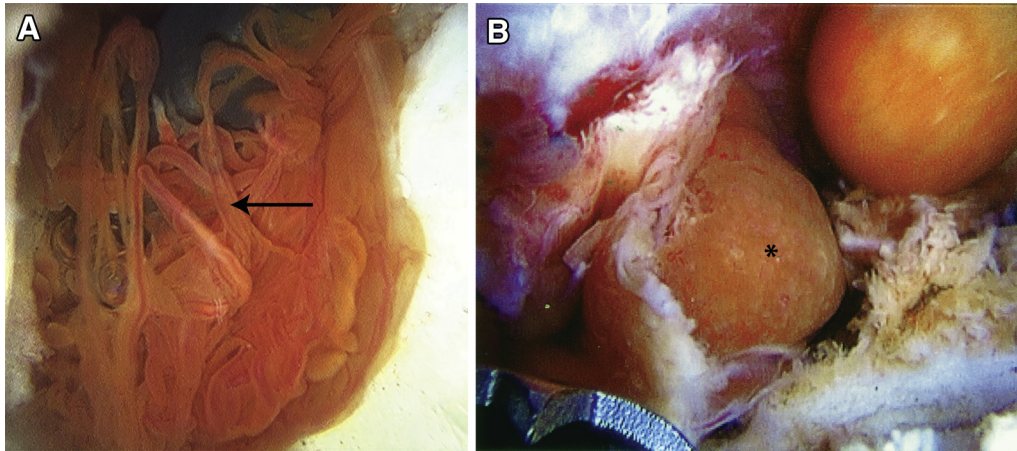


Fig 4. Arthroscopic view of PVNS lesions, which can present along a spectrum of gross pathology from (A) villous, thread-like structures (black arrow) to (B) globous masses (asterisk) with tan, brown, or red coloration. Photos courtesy of the author, Scott D. Martin.

exposure of PVNS lesions, making them amenable to arthroscopic synovectomy. Harris et al.²⁰ reported in a systematic review that with the evolving instrumentation of hip arthroscopy, careful patient selection, and advanced surgeons' learning curve, complication rates have decreased to <1%.

Classically, arthroscopic surgeons did not close the capsulotomy after hip arthroscopy. But with the exponential improvement of these techniques, surgeons have found that capsular closure has a significant role in hip stability.²¹ Philippon et al.²² reported in a case series of revision hip arthroscopy that more than one third had evidence of undiagnosed instability. The most common types of capsulotomy are either interportal or T-capsulotomy. An interportal capsulotomy is performed using a capsular incision made between the anterolateral portal and either the anterior or midanterior portal. It usually enters the joint at 12- to 3-o'clock. Some surgeons prefer to add

a longitudinal component to the incision along with the axis of the femoral neck, producing a T-capsulotomy.²¹

The senior author (S.D.M.) uses a puncture capsulotomy, which is less invasive, maintaining the integrity of the capsule with no need for capsular repair at the conclusion of the procedure, while also preserving the iliofemoral ligament (Table 2). Finally, puncture capsulotomy minimizes exposing the extra-articular structures to the hip joint environment, as aggressive PVNS may invade surrounding structures outside of the joint.³ Complications including persistent hip pain, anterior hip dislocation, microinstability, and heterotopic ossification were found to be decreased with the puncture capsulotomy technique.¹⁷ Although the literature does not clearly report the complication rate with open synovectomy, the Byrd et al.⁹ case series with arthroscopic management did report that there were no complications.

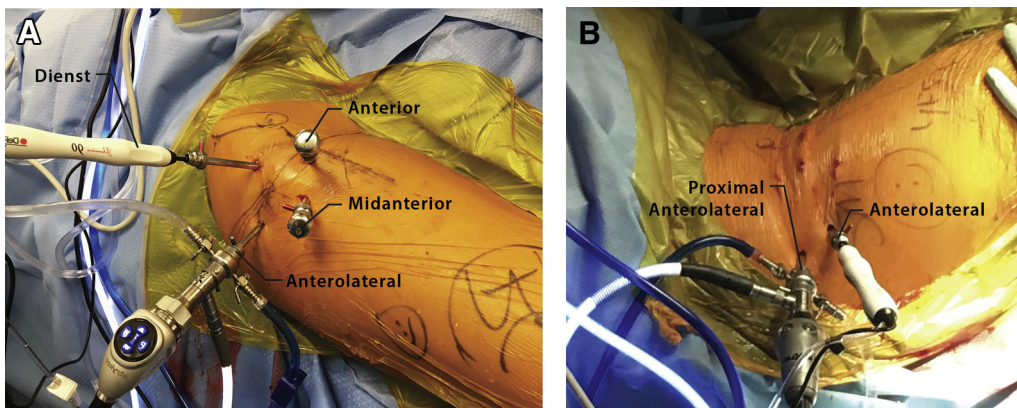


Fig 5. (A) Placement of Dienst, anterior, anterolateral, and midanterior portals and (B) proximal anterolateral and anterolateral portals. Patient placed in the supine position. Full visualization is key to achieving meticulous ablation of all pigmented villonodular synovitis; therefore accessory portals should be established as needed. Photos courtesy of the author, Scott D. Martin.

Table 2. Advantages and Disadvantages

Advantages	Disadvantages
Highest preservation of capsular anatomy and biomechanics.	Difficult and challenging technique.
By addressing concomitant intra-articular pathology, avoid confounding postoperative symptoms with recurring hip pain due to PVNS regrowth.	Increased operative time. Insufficient outflow in conjunction with frequent ablation may increase the lavage temperature, causing chondral thermal injury.
Faster postoperative recovery due to minicapsular approach.	
No risk of overtensioning the capsular repair or of loose capsular repair.	
Lower traction time by decreased operative time not spent on extended capsulotomy and capsular repair.	

PVNS, pigmented villonodular synovitis.

Even open surgical procedures have a high rate of reoccurrence that requires revision surgery or conversion to arthroplasty.^{13,14,23,24} A recent systematic review of hip PVNS managed by open synovectomy found a recurrence rate of 17.8%.²⁵ In comparison, a case series of arthroscopically managed hip PVNS found a lower recurrence rate of 7.7%.⁹ The exact pathophysiology of recurrence is still unknown, but one theory reports that the villus tissue grows into the nutrient foramina of bones in conjunction with microvessels. As the PVNS tissue expands in the foramina, it produces intraosseous cysts with progressive growth leading to further destruction.

Acknowledgment

The authors would like to graciously thank Nicole Wolf, M.S., medical illustrator and animator, for her partnership on this technique manuscript and video.

References

- Upadhyaya S, Alpaugh K, Martin SD. Highly erosive tenosynovial giant cell tumor of the hip treated with arthroscopic synovectomy. *Orthop J Harvard Med Sch* 2015;16:75-81.
- Kokoszka P, Woźniak W, Łapaj Ł, Kruczyński J. Pigmented villonodular synovitis: Various manifestations, inconsistent terminology and treatment. *Cases Study. Ortop Traumatol Rehabil* 2017;19:79-88.
- Chin KR, Barr SJ, Winalski C, Zurakowski D, Brick GW. Treatment of advanced primary and recurrent diffuse pigmented villonodular synovitis of the knee. *J Bone Joint Surg Am* 2002;84:2192-2202.
- Shoji T, Yamasaki T, Nakamae A, et al. Transtrochanteric rotational osteotomy combined with intra-articular procedures for pigmented villonodular synovitis of the hip. *J Orthop Sci* 2015;20:943-950.
- Cheng XG, You YH, Liu W, Zhao T, Qu H. MRI features of pigmented villonodular synovitis (PVNS). *Clin Rheumatol* 2004;23:31-34.
- Lynskey SJ, Pianta MJ. MRI and thallium features of pigmented villonodular synovitis and giant cell tumours of tendon sheaths: A retrospective single centre study of imaging and literature review. *Br J Radiol* 2015;88(1056):20150528.
- Hufeland M, Gesslein M, Perka C, Schröder JH. Long-term outcome of pigmented villonodular synovitis of the hip after joint preserving therapy. *Arch Orthop Trauma Surg* 2018;138:471-477.
- Willimon SC, Schrader T, Perkins CA. Arthroscopic management of pigmented villonodular synovitis of the hip in children and adolescents. *Orthop J Sport Med* 2018;6(3), <https://doi.org/10.1177/2325967118763118>.
- Byrd JWT, Jones KS, Maiers GP. Two to 10 years' follow-up of arthroscopic management of pigmented villonodular synovitis in the hip: A case series. *Arthroscopy* 2013;29:1783-1787.
- Dines JS, DeBerardino TM, Wells JL, et al. Long-term follow-up of surgically treated localized pigmented villonodular synovitis of the knee. *Arthroscopy* 2007;23:930-937.
- Ogilvie-Harris DJ, McLean J, Zarnett ME. Pigmented villonodular synovitis of the knee. The results of total arthroscopic synovectomy, partial, arthroscopic synovectomy, and arthroscopic local excision. *J Bone Joint Surg Am* 1992;74:119-123.
- van der Heijden L, Piner SR, van de Sande MAJ. Pigmented villonodular synovitis: A crowdsourcing study of two hundred and seventy two patients. *Int Orthop* 2016;40:2459-2468.
- Vastel L, Lambert P, De Pinieux G, Charrois O, Kerboull M, Courpied J-P. Surgical treatment of pigmented villonodular synovitis of the hip. *J Bone Joint Surg* 2005;87:1019-1024.
- Startzman A, Collins D, Carreira D. A systematic literature review of synovial chondromatosis and pigmented villonodular synovitis of the hip. *Phys Sportsmed* 2016;44:425-431.
- Skellely NW, Conaway WK, Martin SD. "In-round" labral repair after acetabular recession using intermittent traction. *Arthrosc Tech* 2017;6:e1807-e1813.
- Dorwart R, Genant H, Johnston W, Morris J. Pigmented villonodular synovitis of synovial joints: Clinical, pathologic, and radiologic features. *Am J Roentgenol* 1984;143:877-885.
- Conaway WK, Martin SD. Puncture capsulotomy during hip arthroscopy for femoroacetabular impingement: Preserving anatomy and biomechanics. *Arthrosc Tech* 2017;6:e2265-e2269.
- McCormick F, Alpaugh K, Nwachukwu BU, Xu S, Martin SD. Effect of radiofrequency use on hip arthroscopy irrigation fluid temperature. *Arthroscopy* 2013;29:336-342.
- Xie G, Jiang N, Liang C, et al. Pigmented villonodular synovitis: A retrospective multicenter study of 237 cases. *PLoS One* 2015;10:e0121451.
- Harris JD, McCormick FM, Abrams GD, et al. Complications and reoperations during and after hip arthroscopy: A

- systematic review of 92 studies and more than 6,000 patients. *Arthroscopy* 2013;29:589-595.
21. Domb BG, Stake CE, Finley ZJ, Chen T, Giordano BD. Influence of capsular repair versus unrepaired capsulotomy on 2-year clinical outcomes after arthroscopic hip preservation surgery. *Arthroscopy* 2015;31:643-650.
 22. Philippon MJ, Schenker ML, Briggs KK, Kuppersmith DA, Maxwell RB, Stubbs AJ. Revision hip arthroscopy. *Am J Sports Med* 2007;35:1918-1921.
 23. Verspoor FGM, Zee AAG, Hannink G, van der Geest ICM, Veth RPH, Schreuder HWB. Long-term follow-up results of primary and recurrent pigmented villonodular synovitis. *Rheumatology* 2014;53:2063-2070.
 24. Mankin H, Trahan C, Hornicek F. Pigmented villonodular synovitis of joints. *J Surg Oncol* 2011;103:386-389.
 25. Levy DM, Haughom BD, Nho SJ, Gitelis S. Pigmented villonodular synovitis of the hip: A systematic review. *Am J Orthop (Belle Mead NJ)* 2016;45:23-28.