

[CASE REPORT]

Dystonic Tremor in Adult-onset DYT-KMT2B

Rui Shimazaki¹, Jun Ikezawa¹, Ryoichi Okiyama¹, Kenko Azuma², Hiroyuki Akagawa² and Kazushi Takahashi¹

Abstract:

KMT2B-related dystonia (DYT28, DYT-KMT2B) is an inherited dystonia that generally begins in the lower limbs during childhood and evolves into generalized dystonia. We herein report a case of adult-onset DYT28 with dystonic tremor. A 27-year-old woman initially displayed right upper limb and cervical tremors over the course of 1 year. A neurological examination also revealed cervical and lower limb dystonia. Although the disease generally develops during childhood, we diagnosed the woman with DYT28, as genetic testing revealed a mutation in *KMT2B*. Adult-onset patients with DYT28 might also show uncommon symptoms as well as DYT-TOR1A (DYT1).

Key words: *KMT2B*-related dystonia, DYT28, dystonic tremor, dystonia

(Intern Med 61: 2357-2360, 2022)

(DOI: 10.2169/internalmedicine.8700-21)

Introduction

KMT2B-related dystonia (DYT-KMT2B, DYT28) is an inherited dystonia discovered in 2016 (1) that usually develops during childhood. Typically, dystonia symptoms of DYT28 begin in the lower limbs and subsequently progress to generalized dystonia with the inclusion of the upper limbs, pharynx, and trunk (2). Most cases develop during childhood; therefore, the clinical characteristics of adult-onset DYT28 have remained unidentified.

We herein report a Japanese patient with DYT28 whose disease onset began at 26 years old, with upper limb and neck tremors as the initial symptoms.

Case Report

A 27-year-old Japanese woman presented with a 1-year history of tremors in the right upper limb and cervical regions. She had a medical history of anxiety disorder and a mild intellectual disability; in addition, she had a family history of depression (father and sister) and intellectual disability (brother), but no family history of hyperkinetic movement disorders (Fig. 1).

The patient's height was 140 cm, and she had an elon-

gated face with a bulbous nose. She showed involuntary movement characterized by an irregular tremor in the neck and postural tremor of the right-dominant upper limb and neck. However, resting and task-specific tremors were not observed. The tremor was exacerbated by mental load (e.g., while performing calculations). In addition to tremors, we observed mild generalized dystonia, slight retroflexion, and left rotation in the neck during the appearance of tremors as well as bilateral dorsiflexion of the first toe while walking. Furthermore, although we observed right-dominant hypertrophy of the sternocleidomastoid and paraspinal muscles, she had no subjective symptoms of dystonia, except for neck pain.

Her cranial nerve examination, muscle strength, tendon reflexes, finger-to-nose test, and diadochokinesia tests reported normal findings. Furthermore, her laboratory tests revealed no abnormalities, and brain magnetic resonance imaging also revealed no abnormalities, including the basal ganglia. The accumulation on dopamine transporter single-photon emission computed tomography (DAT SPECT) showed a slightly irregular shape, with the right striatum having a specific binding ratio (SBR) of 3.90 and the left striatum a value of 3.83 (Fig. 2). Surface electromyography showed continuous discharges from the bilateral sternocleidomastoid muscles (SCMs) at rest and alternating discharge

¹Department of Neurology, Tokyo Metropolitan Neurological Hospital, Japan and ²Tokyo Women's Medical University, Institute for Integrated Medical Sciences, Japan

Received: September 20, 2021; Accepted: November 25, 2021; Advance Publication by J-STAGE: January 13, 2022

Correspondence to Dr. Jun Ikezawa, jun_ikezawa@tmhp.jp

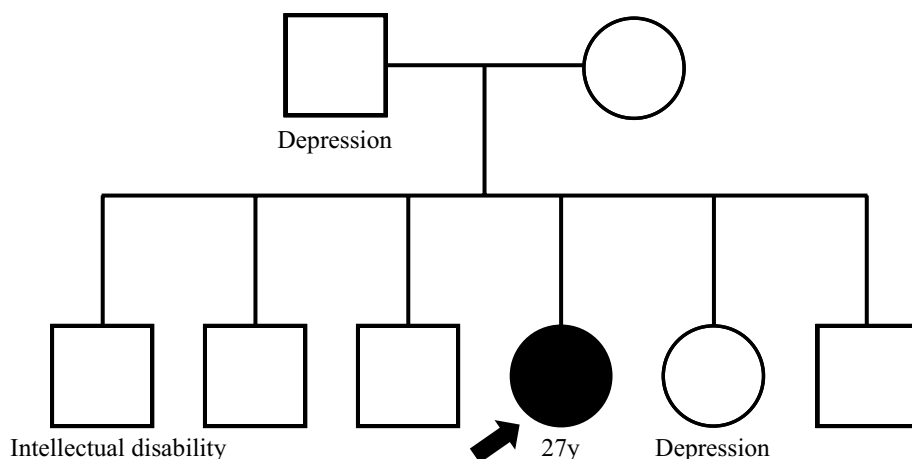


Figure 1. The pedigree.

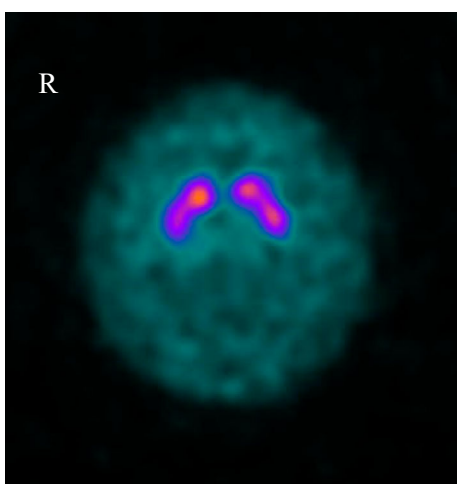


Figure 2. Dopamine transporter single-photo emission computed tomography (DAT SPECT). The striatal accumulation on DAT SPECT is slightly irregular in shape, with specific binding ratio values of 3.90 on the right and 3.87 on the left.

from the right forearm when the patient held her arms in an outstretched posture (Fig. 3). Her intelligence quotient was 70 on the Suzuki-Binet test.

Genetic testing was performed on the patient's blood-derived DNA, and a new heterozygous nonsynonymous substitution was detected in the *KMT2B* gene c. 5285 G>A (p. Arg1762His) (Fig. 4A). This variant is not present in the GenomAD (<https://gnomad.broadinstitute.org/>) or human genetic variation databases (<https://www.hgvd.genome.med.kyoto-u.ac.jp/>) and is not considered to be present in the general population. The affected amino acids are conserved among species (Fig. 4B), and the prediction scores, including Sorting Intolerant From Tolerant, MutationTaster, and Polyphen-2, suggested that this mutation is pathogenic. Based on her characteristics of dystonia, short stature, elongated face with bulbous nose, anxiety, and intellectual impairment, we diagnosed her with DYT28.

She was treated with levodopa/carbidopa (100/10 mg 3 times daily), but her symptoms did not improve. However, on treatment with clonazepam (0.5 mg) and botulinum toxin

injection into the bilateral SCMs and trapezius, her tremors and dystonia improved slightly.

Discussion

In this case, the onset of DYT28 presented as a dystonic tremor in the upper limb and neck at 26 years old. DYT28 generally shows progressive, generalized dystonia starting in the lower limb region and spreading to the upper limb, cervical, pharynx, and trunk during childhood. DYT28 also exhibits other neurological symptoms, including myoclonus, anxiety, intellectual disability, spasticity, and epilepsy. In recent years, there have been a series of reports on DYT28, which may account for 10-22% of cases of child-onset generalized dystonia, suggesting that it is a more common disease than was previously thought (2, 3). The clinical profile of *KMT2B*-related disorders is changing, as a psychiatric variant without dystonia symptoms has been reported (4). However, adult-onset cases are rare; adult-onset dystonia is generally less markedly affected by certain genes than childhood-onset dystonia. (5). Two previous cohort studies of DYT28 identified only 1 case each of adult-onset dystonia among 27 and 53 patients, respectively. However, no cases of dystonic tremor were reported in their cohorts (4, 6).

In Table, we summarize all adult-onset cases reported thus far. Interestingly, the onset site was not the lower limbs in any adult-onset cases; in three cases, the onset began in the upper limbs (4, 7, 8); in one case, in the neck (9); in one case, in the larynx (7); and in two cases, the site was unknown (6, 10). Furthermore, only one case other than the present case showed tremor at an onset age of ≥ 18 years old. These findings suggested that adult-onset DYT28 may present with atypical clinical symptoms. *DYT-TOR1A* (DYT 1) is the most representative inherited dystonia, but there is a difference in symptoms between childhood- and adult-onset cases. Typically, DYT1 has a phenotype that presents in childhood with an onset in the lower limbs and subsequently generalizes. In contrast, patients with adult-onset DYT1 presented with focal dystonia or tremor within the

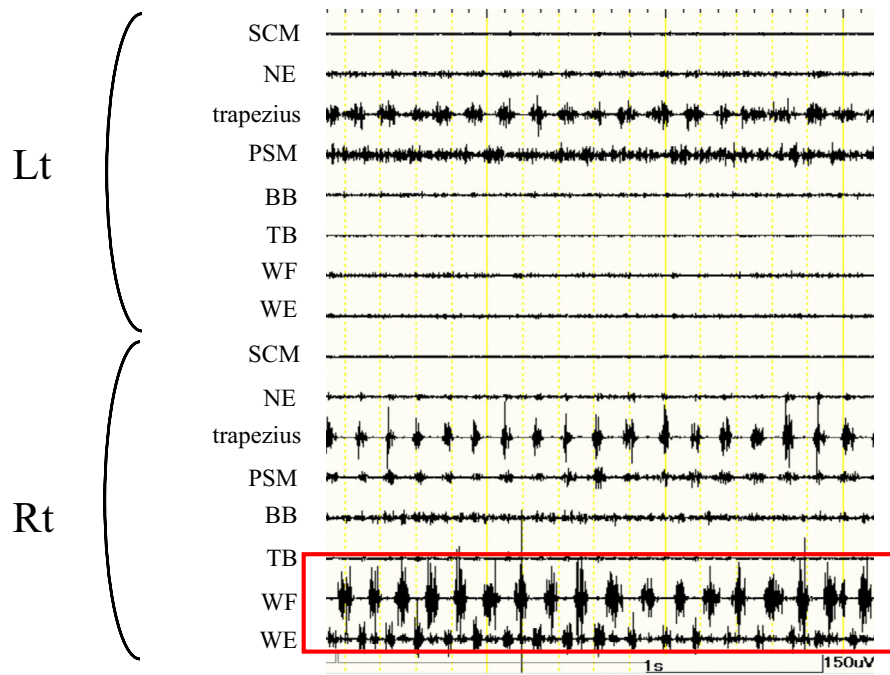


Figure 3. Surface electromyography. Note the alternating discharges from the right forearm. The patient held her arms in an outstretched posture. SCM: sternocleidomastoid, NE: neck extensor, PSM: paraspinal muscle, BB: biceps brachii, TB: triceps brachii, WF: wrist flexor, WE: wrist extensor

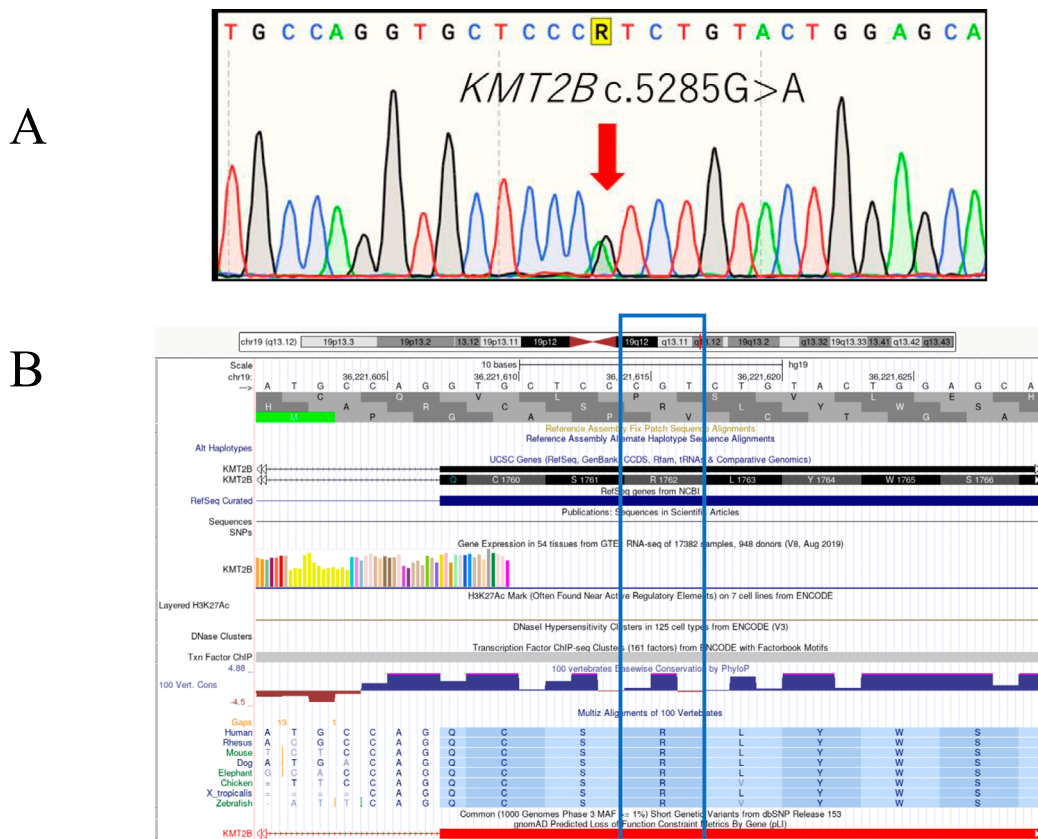

Figure 4. A: Sanger sequencing results for the *KMT2B* gene in the patient. An electropherogram of the Sanger sequencing result. C.5285G>A (p. Arg1762His). B: Levels of conservation of the p. Arg1762 domain in *KMT2B* among different species (references cited in https://genome.ucsc.edu/cgi-bin/hgTracks?db=hg19&lastVirtModeType=default&lastVirtModeExtraState=&virtModeType=default&virtMode=0&nonVirtPosition=&position=chr19%3A36221601%2D36221630&hgid=1183100549_XpNLOGDzktNOcGN0AIV7srA9kOaX).

Table. Summary of Reported Adult-onset DYT28.

Case	Reference	Year of publication	Age/ Sex	Age at dystonia onset	Site of onset	Site of distribution at presentation	Tremor	Other
1	(3)	2017	46/F	23	N/A	Bilateral UL, bilateral LL, cervical, larynx	N/A	N/A
2	(7)	2020	28/F	27	Neck	Neck, trunk, bilateral UL	N/A	Short stature, microcephaly, bulbous nasal tip, cognitive decline
3	(8)	2020	23/M	19	N/A	UL, LL, trunk	Postural tremor	Intellectually normal, long face
4	(5)	2020	35/F	18	Right UL	Right UL, trunk, neck	N/A	N/A
5			33/M	24	Larynx	Larynx, left LL	N/A	Short stature, microcephaly, bulbous nasal tip
6	(4)	2020	34/F	29	UL	Jaw dystonia, UL	N/A	N/A
7	(6)	2020	41/M	20	UL	Trunk, cervical	N/A	N/A
8	Our case		27/F	Unclear	Unclear	Neck, trunk, LL (very mild)	Postural tremor	Short stature, microcephaly, bulbous nasal tip, cognitive decline

UL: upper limbs, LL: lower limbs, N/A: not applicable

family of typical generalized dystonia (11). Similar to DYT 1, adult-onset DYT28 cases may show a clinical course different from that of childhood-onset cases; therefore, further analyses are warranted.

The results of DAT SPECT suggested dopaminergic dysfunction in our case. The striatal accumulation was slightly irregular in shape, and the SBR values were low. The lower limit of the SBR in the Japanese database for patients in their 30s is 6.82 (12), suggesting that the SBR in this case was decreased, although the normal value in the 20s is not established. A recent study revealed that patients with generalized dystonia show a mildly reduced DAT SPECT accumulation (13). The results of DAT SPECT in our case were also considered to reflect a disturbance of the dopaminergic system in dystonia.

We obtained written informed consent from the patient. This study was performed in accordance with the Declaration of Helsinki and was approved by the ethics committee of Tokyo Metropolitan Neurological Hospital and Tokyo Women's Medical University.

The authors state that they have no Conflict of Interest (COI).

References

- Zech M, Boesch S, Esther, et al. Haploinsufficiency of *KMT2B*, encoding the lysine-specific histone methyltransferase 2B, results in early-onset generalized dystonia. *Am J Hum Genet* **99**: 1377-1387, 2016.
- Gorman KM, Meyer E, Kurian MA. Review of the phenotype of early-onset generalised progressive dystonia due to mutations in *KMT2B*. *Eur J Paediatr Neurol* **22**: 245-256, 2018.
- Carecchio M, Invernizzi F, González-Latapi P, et al. Frequency and phenotypic spectrum of *KMT2B* dystonia in childhood: a single-center cohort study. *Mov Disord* **34**: 1516-1527, 2019.
- Cif L, Demailly D, Lin JP, et al. *KMT2B*-related disorders: expansion of the phenotypic spectrum and long-term efficacy of deep brain stimulation. *Brain* **143**: 3242-3261, 2020.
- Zech M, Jech R, Boesch S, et al. Monogenic variants in dystonia: an exome-wide sequencing study. *Lancet Neurol* **19**: 908-918, 2020.
- Meyer E, Carss KJ, Rankin J, et al. Mutations in the histone methyltransferase gene *KMT2B* cause complex early-onset dystonia. *Nat Genet* **49**: 223-237, 2017.
- Li XY, Dai LF, Wan XH, et al. Clinical phenotypes, genotypes and treatment in Chinese dystonia patients with *KMT2B* variants. *Parkinsonism Relat Disord* **77**: 76-82, 2020.
- Winslow N, Maldonado A, Zayas-Rodriguez L, Lamichhane D. Adult-onset *KMT2B*-related dystonia responsive to deep brain stimulation. *Mov Disord Clin Pract* **7**: 992-993, 2020.
- Mun JK, Kim AR, Ahn JH, et al. Successful pallidal stimulation in a patient with *KMT2B*-related dystonia. *J Mov Disord* **13**: 154-158, 2020.
- Pandey S, Bhattad S, Panda AK, Mahadevan L. Late-onset *KMT2B*-related dystonia in an Indian patient with normal cognition, dystonic opisthotonus and lack of oromandibular and laryngeal involvement. *Parkinsonism Relat Disord* **74**: 33-35, 2020.
- Nomura Y, Ikeuchi T, Tsuji S, Segawa M. Two phenotypes and anticipation observed in Japanese cases with early onset torsion dystonia (DYT1) - pathophysiological consideration. *Brain Dev* **22** (Suppl 1): S92-S101, 2000.
- Matsuda H, Murata M, Mukai Y, et al. Japanese multicenter database of healthy controls for [¹²³I]FP-CIT SPECT. *Eur J Nucl Med Mol Imaging* **45**: 1405-1416, 2018.
- Ikezawa J, Yokochi F, Okiyama R, et al. Is generalized and segmental dystonia accompanied by impairments in the dopaminergic system? *Front Neurol* **12**: 751434, 2021.

The Internal Medicine is an Open Access journal distributed under the Creative Commons Attribution-NonCommercial-NoDerivatives 4.0 International License. To view the details of this license, please visit (<https://creativecommons.org/licenses/by-nc-nd/4.0/>).