



Images

The sparkle in her eye: Crystal deposits in cornea, conjunctiva, meibombian glands, and iris in uncontrolled cystinosis

Dara R. Baker^{a,b}, Alisa T. Thavikulwat^a, M. Teresa Magone^{a,*}

^a National Eye Institute, National Institutes of Health, 10 Center Drive, Bethesda, MD, USA

^b George Washington University School of Medicine, 2300, I St. NW, Washington, DC, USA



ARTICLE INFO

Keywords:

Cystinosis
Corneal crystals
Iris crystals
Conjunctival crystals
Meibombian gland crystals
Cysteamine

1. Case report

A 31-year-old woman of Brazilian ancestry with nephropathic cystinosis presented for a follow-up exam at the eye clinic at the National Institutes of Health Clinical Center with photophobia and decreased vision. She was on oral cysteamine bitartrate capsules 675 mg twice daily but reported irregular use of cysteamine 0.44% eye drops between one to five times a day. Additionally, the patient reported the development of diabetes mellitus since her last visit 5 years prior. The patient's blood cystine trough levels were elevated to 3.01 (normal 0.2) nmol half-cystine/mg protein. Best-corrected visual acuities were 20/25 in the right eye and 20/32 in the left eye. Corneal pachymetries were unmeasurable. Examination revealed dense crystal deposition with thickening of the cornea (Fig. 1A) and small crystalline deposits bilaterally on the iris (Fig. 1B). Additionally, she had crystal deposits in the meibombian glands, bulbar and tarsal conjunctivas (Fig. 2), and retinas of both eyes. The patient's oral cysteamine bitartrate was increased gradually by the primary team to achieve normal blood cystine levels and compliance with frequent daily application of cysteamine eye drops was stressed.

2. Discussion

Cystinosis is a genetic disease affecting the proteins responsible for transmembrane export of cystine, resulting in intracellular cystine accumulation and crystallization in delicate tissues. Renal and ocular manifestations appear early in the disease course, offering an

opportunity for rapid initiation of therapy. Other manifestations include hypothyroidism, diabetes mellitus, pulmonary dysfunction, and male hypogonadism. Corneal crystals commonly present in childhood around the first year of life and cause photophobia with secondary blepharospasm.¹ Pigmentary retinopathy has been described in some patients, possibly preceding appearance of corneal crystals and leading to decreased color, peripheral, and night vision.²

Cystinosis is treated with systemic oral cysteamine, which binds to cystine and allows the complex to exit the lysosome via a lysine transport enzyme.³ Oral cysteamine inadequately penetrates the poorly vascularized cornea, so corneal crystals often respond better to cysteamine eye drops.³ In our patient, the presence of crystals in the iris in combination with elevated serum cystine levels indicated the need for improved systemic control. Our patient's oral cysteamine medication was subsequently adjusted to achieve levels of <2 nmol half-cystine/mg protein.

3. Conclusion

While corneal crystals represent an early finding of cystinosis, systemic disease progression may result in cystine deposition in the conjunctiva, iris, ciliary body, choroid, fundus and optic nerve. Patients with cystinosis require lifelong ocular monitoring and ophthalmologists should be aware of ocular manifestations and indications of disease progression, which may reflect a need for better systemic control.

* Corresponding author. Consult Services Section, National Eye Institute, NIH 10 Center Drive Building 10, OP10 Bethesda, MD 20814, USA.

E-mail address: teresa.magonedequadroscosta@nih.gov (M.T. Magone).

<https://doi.org/10.1016/j.ajoc.2021.101169>

Received 13 July 2020; Received in revised form 5 April 2021; Accepted 19 July 2021

Available online 24 July 2021

2451-9936/© 2021 Published by Elsevier Inc. This is an open access article under the CC BY-NC-ND license (<http://creativecommons.org/licenses/by-nc-nd/4.0/>).

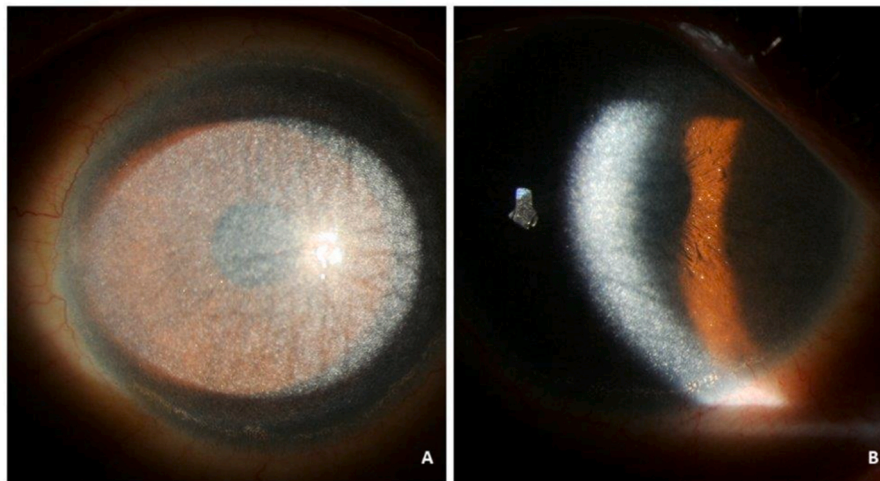


Fig. 1. A. Slit lamp photograph of a 31-year-old woman with cystinosis showing cystine crystal deposition in the cornea. B. Slit lamp photograph of the same patient showing cystine iris crystals.

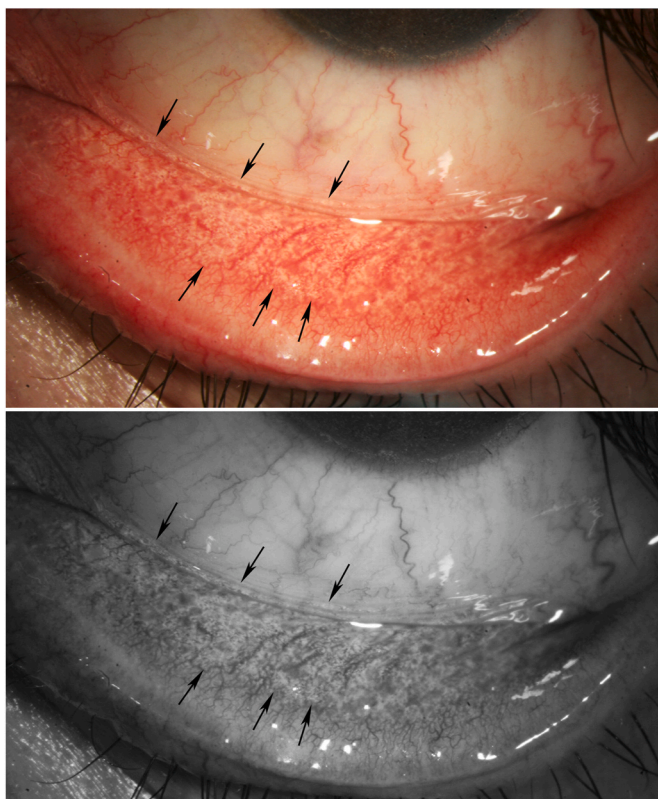


Fig. 2. Top: slit lamp photograph of conjunctival and meibomian gland cystine crystals seen as white deposits (black arrows) in the same patient as Fig. 1. Bottom: black and white photograph of same eye to highlight diffuse cystine deposits in the conjunctival fornix and meibomian glands (black arrows).

Patient consent

The patient provided written informed consent for publication of this

Case.

Funding

National Institutes of Health (NIH) intramural research program. Dara Baker is funded by the Medical Research Scholars Program, a public-private partnership supported jointly by the NIH and generous contributions to the Foundation for the NIH from the Doris Duke Charitable Foundation, the American Association for Dental Research, the Colgate-Palmolive Company, Genentech, alumni of student research programs, and other individual supporters via contributions to the Foundation for the National Institutes of Health.

Authorship

All authors attest that they meet the current ICMJE criteria for Authorship.

Declaration of competing interest

The following authors have no financial disclosures: DRB, AT, TM.

Acknowledgements

None.

References

1. Tsilou E, Zhou M, Gahl W, Sieving PC, Chan CC. Ophthalmic manifestations and histopathology of infantile nephropathic cystinosis: report of a Case and review of the literature. *Surv Ophthalmol.* 2007;52:97–105.
2. Gahl WA, Thoene JG, Schneider JA. *Cystinosis.* *N Engl J Med.* 2002;347:111–121.
3. Tsilou ET, Rubin BI, Reed G, et al. Nephropathic cystinosis: posterior segment manifestations and effects of cysteamine therapy. *Ophthalmology.* 2006;113: 1002–1009.