



Cross-sectional Study

Comparison of efficacy three-site versus single-site steroid injections for the treatment of adhesive capsulitis



Muhammad Sharif^a, Muhammad Sufyan Khan^b, Tayyeba Khursheed Ahmed^c, Wajahat Aziz^d, Uzma Rasheed^d, Shazia Zammurad^d, Arslan Iqbalⁱ, Hassan Mumtaz^{e,*}, Hassan ul Hussain^f, Mohammad Hasan^h, Sheeza Erum^g

^a PGR Rheumatology Dept PIMS, Pakistan

^b Registrar Rheumatology Dept PIMS, Pakistan

^c PGR Rheumatology Dept PIMS, Pakistan

^d Rheumatology Department PIMS, Pakistan

^e Maroof International Hospital, Public Health Scholar, Health Services Academy, Islamabad, Pakistan

^f Dow University of Health Sciences, Karachi, Pakistan

^g Dow University of Health Sciences, Pakistan

^h Jinnah Postgraduate Medical Center, Pakistan

ⁱ Indiana University, Bloomington, USA

ARTICLE INFO

Keywords:

Frozen shoulder
Steroid instillation
Novel three-site technique
CONSTANT Score
Joints

ABSTRACT

Background: Frozen shoulder or adhesion capsulitis is a frequent ailment that causes pain and progressively restricts both active and passive shoulder motions. It is estimated that it affects 2%–5% of the general population and up to 20% of diabetes mellitus patients.

We aimed to compare the effectiveness of three-site steroid injections against one-site injections in the treatment of adhesive capsulitis.

Methodology: The Rheumatology Department of Pakistan Institute of Medical Sciences in Islamabad conducted this cross-sectional study. Between August 2021 to December 2021. The study comprised a total of 98 patients. This study included patients of both genders with shoulder pain between the ages of 40 and 70. Patients were divided into two groups & dosage was given at Sub-coracoid, Subacromial, and Posterior Capsule. The CONSTANT score was used to assess patients three times (Initial, 3months & 6 months later).

Results: The average age, gender distribution, and dominant/non-dominant side ratio of the participants were nearly identical between the two groups. More patients in group B (77.22 8.17) had a higher mean CONSTANT score than those in group A (72.73 7.05). Patients were checked in on again after three and six months.

Conclusion: The three-site injection technique is a safe and effective method for frozen shoulder. It provides an early recovery and improved shoulder function with a reduced frequency of relapse as compared to single-site injection techniques.

1. Introduction

Adhesive capsulitis (AC) or frozen shoulder affects the Glenoid Humeral (GH) joint's passive and active motions, causing excruciating pain when the shoulder is moved [1,2]. The incidence of adhesive capsulitis has increased due to changing lifestyles (adopting a sedentary lifestyle) and co-morbid conditions [3]. The pathogenesis of adhesive capsulitis is

not fully understood. There are three phases, so far, that can be distinguished: freezing (progressive loss of motion with gradual onset of pain), freezing (gradual subsidence of pain and stiffness that eventually plateaus to the same extent as active or passive ROMs), and thawing (gradual improvement in movement) [4]. Nevertheless, there are many other factors, such as emotional stressors.

A painful and self-limiting disease, AC still makes people's daily

* Corresponding author. Maroof International Hospital. Public Health Scholar: Health Services Academy, Islamabad, Pakistan.

E-mail addresses: msharif111@yahoo.com (M. Sharif), Sufyankhan6072@gmail.com (M.S. Khan), Taymohsin@gmail.com (T.K. Ahmed), Wajahataziz@hotmail.com (W. Aziz), Umza_sheikh@gmail.com (U. Rasheed), Shaziazammurad@hotmail.com (S. Zammurad), Drarsalanshah136@gmail.com (A. Iqbal), Hassanmumtaz.dr@gmail.com (H. Mumtaz), hassanulhussain12@gmail.com (H. Hussain), M_hasan_96@yahoo.com (M. Hasan), drsheelzaerum@gmail.com (S. Erum).

<https://doi.org/10.1016/j.amsu.2022.104071>

Received 30 May 2022; Received in revised form 18 June 2022; Accepted 22 June 2022

Available online 28 June 2022

2049-0801/© 2022 The Authors. Published by Elsevier Ltd on behalf of IJS Publishing Group Ltd. This is an open access article under the CC BY-NC-ND license (<http://creativecommons.org/licenses/by-nc-nd/4.0/>).

activities more difficult. AC has traditionally been considered a benign disease with complete recovery of pain and range of motion. Even though this condition can sometimes last for years, it rarely fully resolves [5]. In terms of AC management, there is no consensus, and the treatment options are usually non-operative.

Non-steroidal anti-inflammatory drugs (NSAIDs), oral corticosteroid injections, and other forms of physical therapy have all been proposed as potential treatments for AC [6,7]. Despite this, there is still no cure for AC. Since the majority of therapy is based on non-surgical methods, operational techniques are only used for refractive instances [8]. Surgical options include manipulation under anaesthesia, supra-clavicular blocks, capsular release, hydro-dilation, and open surgery [9].

Different steroids and different techniques produce different results—some are beneficial, while others are detrimental. Injecting into a joint without radiologic guidance, dose, number of curves, and pathological variances across joints are all factors that contribute to low effectiveness [10]. The purpose of this study was to compare the efficacy of a three-site steroid injection technique that used anterior capsule, sub Acromial, and sub-coracoid injection sites to a single-site technique.

2. Materials & methods

This cross-sectional study was conducted in the Rheumatology Department of the Pakistan Institute of Medical Sciences, Islamabad.

from August 2021 to December 2021. A total of 98 patients were included in the study [1]. The sample size was calculated with the WHO sample size calculator using the following parameters: expected prevalence of 50%, precision level 5%, and confidence level 95% [3]. Our study is fully compliant with STROCSS 2021 guideline [11]. A complete STROCSS checklist has been provided as a supplementary file.

2.1. Inclusion and exclusion criteria

Patients from both genders with an age group between 40 and 70 years old with shoulder pain were included in this study. Patients below 40 years of age or above 70 years of age with a history of surgery or who were known to have any other shoulder pathologies were excluded from the study.

2.2. Data collection

The study enrolled 110 patients initially assessed for the study, but later 98 patients were selected after obtaining informed written consent in accordance with the Helsinki Declaration and taking their full medical history. Ethical approval was obtained from the ethical committee of Shaheed Zulfiqar Ali Bhutto Medical University, reference no F.1-1/2015/ERB/SZABMU/767.

All of the patients had imaging diagnostic tests, oral NSAIDs, and

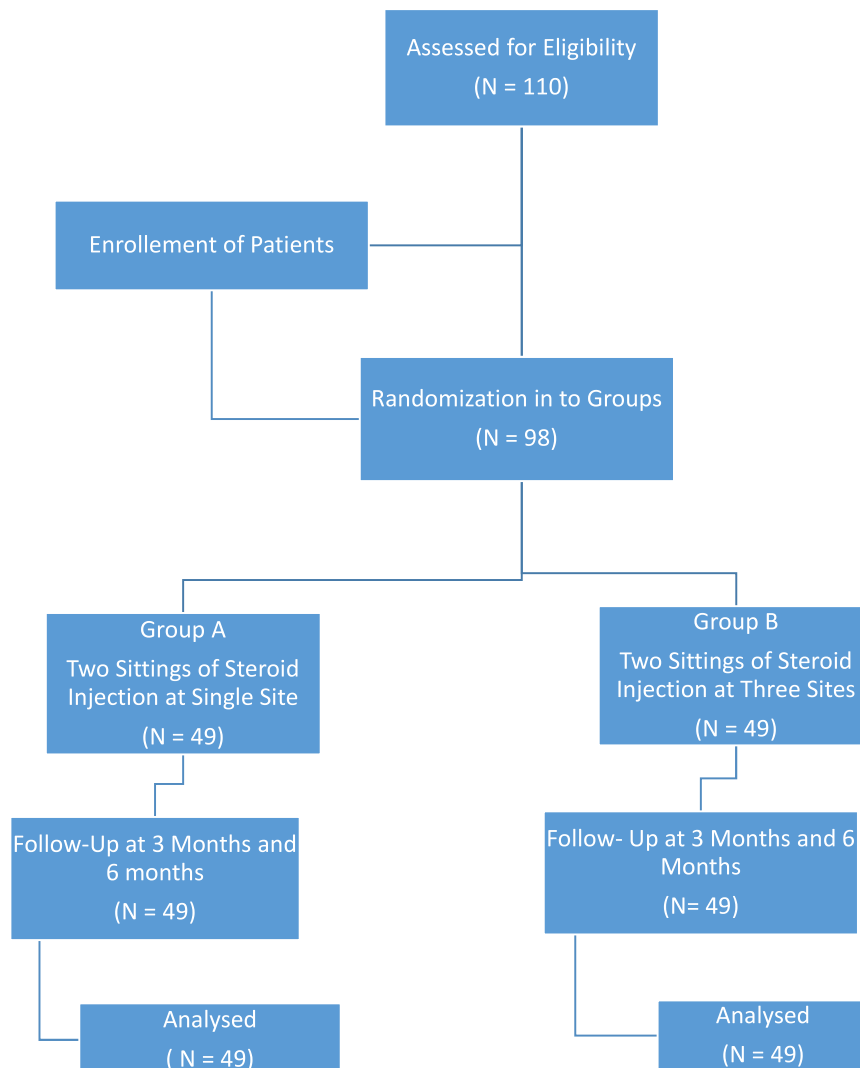


Fig. 1. Flowchart of Patient's selection.

physiotherapy supervised by a physiotherapist before injection. Additionally, ultrasonic therapy was administered, as well as home exercises (wall crawling/cart wheeling) over a period of 4 weeks. This was done to rule out true adhesive capsulitis from the temporary muscle injury.

All the participants were divided into two equal groups. Steroid injections were administered to Group A using the posterior route. A steroid dosage was diluted in Group B and administered in three distinct locations with three different doses of the steroid (sub-coracoid, Sub acromial, and posterior capsule). Both groups received a second dose six weeks later. The CONSTANT score was used to evaluate the patients at 3 stages (i.e, initially, 3 months later and 6 months later), as shown in Fig. 1.

2.3. Data analysis

Data was recorded and analysed through SPSS version 25 (Statistical Package for Social Sciences). For continuous variables mean ± SD was calculated and for categorical data frequency & percentages were calculated. Linear graphical representations were used to illustrate the different treatment intervals. We compared quantitative variables using paired t-tests (for non-parametric data) between follow-ups within groups and independent t-tests (for non-parametric data) between groups. P-values <0.05 were considered statistically significant.

3. Results

The study included 98 participants. The mean age of the patients in Group A was 52.47 9.59 years, and in Group B it was 52.94 9.33. The majority of the patients in both groups were females. Group A had 20 (40.9%) males and 29 (59.1%) females. Group B had 19 (38.8%) males and 30 (61.2%) females.

The majority of patients had adhesive capsulitis of their dominant extremity. In Group A, 29 patients (59.1%) had adhesive capsulitis on the dominant side. In Group B, 32 (65.3%) of 49 patients had adhesive capsulitis on their dominant side.

The mean duration of disease in Group A (14.61 1.92 months) was longer than the mean duration of disease in Group B (13.14 1.44 months). The mean CONSTANT Score was reported to increase more in Group B patients (74.76 7.71) as compared to the Group A patients (81.59 8.13) at 6 months, as shown in Table 1.

The patients were followed up at 3 months and 6 months. range of motion in terms of flexion, extension, internal rotation, and external rotation were assessed and extension was found to be a statistically significant difference in both the groups, having p value of 0.04. At 6 months, it was seen that in comparison to group A having 111.27 11.75, patients in group B showed more improvement in ROM in terms of

Table 1
Baseline characteristics of patients.

Characteristics	Group A Single Site Injection N = 49	Group B Three Site Injection N = 49	P- Value
Age (Years)	52.47 ± 9.59	52.94 ± 9.33	–
Gender			
1. Male	20 (40.9%)	19 (38.8%)	–
2. Female	29 (59.1%)	30 (61.2%)	
Side Of Extremity			
1. Dominant	29 (59.1%)	32 (65.3%)	0.532
2. Non-Dominant	20 (40.9%)	17 (34.6%)	
Mean Duration of Disease (Months)	14.61 ± 1.92	13.14 ± 1.44	0.812
CONSTANT Score			
1. Initial	53.63 ± 7.04	54.56 ± 7.01	0.626
2. At 3 Months	72.73 ± 7.05	77.22 ± 8.17	
3. At 6 Months	74.76 ± 7.71	81.59 ± 8.13	

Flexion (122.63 20.89), Extension (44.9 5.35 in Group A, 50.1 6.95 in Group B), Internal Rotation (112.2 12.4 in Group A, 123.86 20.3 in Group B) and External Rotation (57.92 5.59 in Group A, 79.41 6.48 in Group B). Details of the progress are shown in Table 2.

The flexion movement at three injection sites was initially 55.39, but it improved to 122.63 after six weeks. After six months, internal rotation movement had improved from 55.98 to 123.86. After treatment, the initial extension movement was 26.65, but it increased to 50.1. A 34.88 external rotation score was recorded; however, the score was later improved to an impressive 79.41. There was a significant improvement seen in the Three Site Injections Group in terms of all four movements, as shown in Fig. 2.

Both groups' scores were compared using the Constant Score. The Single Site Injection group started with a score of 53.63, but by the end of the study, it had risen to 74.76. The initial score for the three injection sites was 54.56, but after six months the score rose to 81.59. The comparison of CONSTANT Score in single site and three-site injection groups is shown in Fig. 3.

4. Discussion

There is speculation that adhesive capsulitis is associated with inflammation and fibrosis type III collagen in the shoulder joint and capsule. Lack of Myo Fibroblasts is the pathophysiology of disease [12]. Contracture of the rotator cuff, sub Acromial scarring, reduced Gleno Humeral (GH) joint volume, and fibrosis within the capsule-ligament complex are the four most common reasons for shoulder pain [13]. For the most part, AC is diagnosed clinically. Even so, results from MRI scans, such as thickening of the axilla with decreased capsule volume, loss of sub-coracoid fat, and distension of the superior sub Scapularis bursa, can be useful [14]. In studies, ultrasound has also been found to be a reliable diagnostic tool for the detection of thickening of the Coraco Humeral ligament in AC [1]. On the other hand, MRI findings correlate more strongly with ROM and pain intensity. These two imaging methods supported the diagnosis [15]. Moreover, a specific pattern of Gleno Humeral restriction has been associated with capsular ligament contracture in previous studies to explain adhesive capsulitis [13].

One of our primary findings was an improved CONSTANT score in the patients. The CONSTANT score of patients who had three-site injections was significantly higher at 6 months compared to those who had

Table 2
Improvement in range of motion.

Movement	Group A Single Site Injection N = 49	Group B Three Site Injection N = 49	P- Value
Flexion (Degrees)			
Initially	54.16 ± 8.46	55.39 ± 8.47	0.68
At 3 Months	71.31 ± 9.44	76.63 ± 9.84	
At 6 Months	111.27 ± 11.75	122.63 ± 20.89	
Extension (Degrees)			
Initially	26.59 ± 5.77	26.65 ± 5.84	0.04
At 3 Months	34.47 ± 7.08	40.88 ± 6.45	
At 6 Months	44.9 ± 5.35	50.1 ± 6.95	
Internal Rotation (Degrees)			
Initially	54.96 ± 7.26	55.98 ± 7.03	0.394
At 3 Months	75.41 ± 6.78	79.02 ± 8.32	
At 6 Months	112.2 ± 12.4	123.86 ± 20.3	
External Rotation (Degrees)			
Initially	36.14 ± 5.14	34.88 ± 5.34	0.25
At 3 Months	44.49 ± 4.18	54.59 ± 7.91	
At 6 Months	57.92 ± 5.59	79.41 ± 6.48	

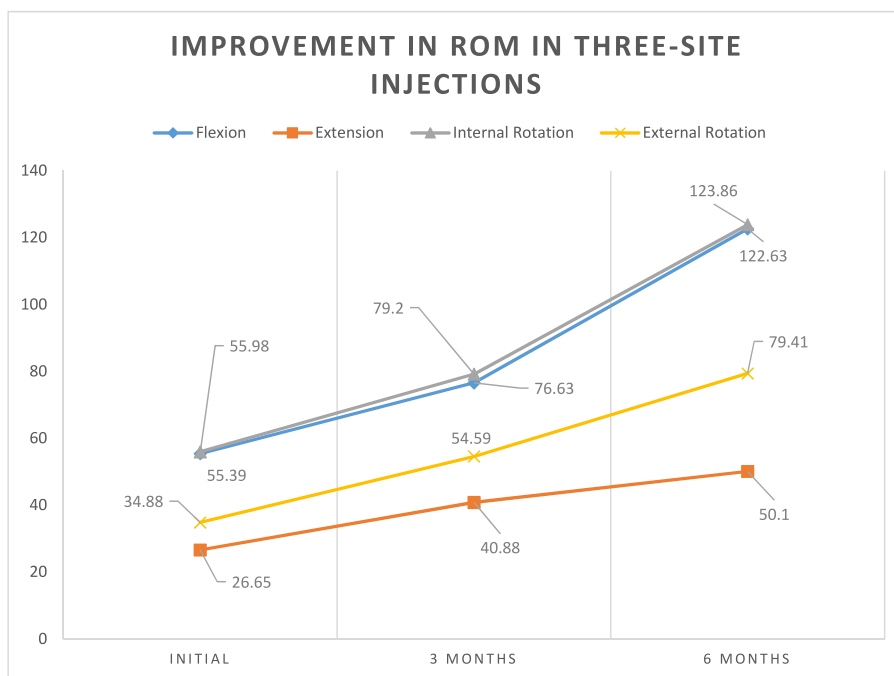


Fig. 2. An illustration showing the significant improvement and near-normal range of motion achieved by the end of 6 months by the patients in the new three-site injection group.

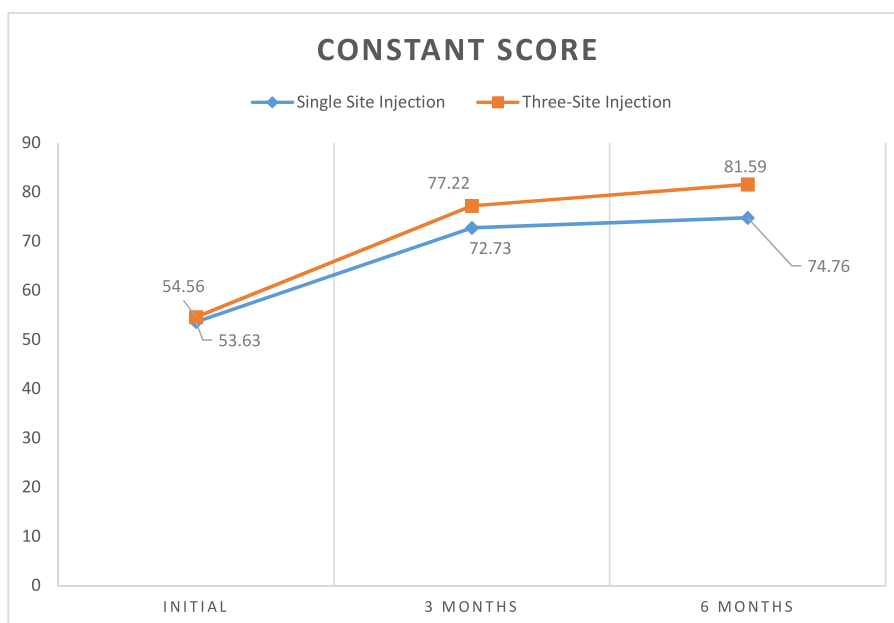


Fig. 3. Comparison of CONSTANT Score in both the groups.

single-site injections. Our results are in accordance with the findings of a comparative study published in 2017, who also compared the CONSTANT scores of patients with three-site injections versus single-site injections [1].

It has been established that dominance and AC recovery are related. Studies have shown that patients with AC often experience pain in the dominant shoulder. Injections of corticosteroids may not be as effective when treating injuries on the patient’s non-dominant side [15]. This is in conformity with our study as the majority of the patients had AC on their dominant side. Patients with AC on the non-dominant side also showed very slow recovery [16].

Patients in the three-site injection group [16] showed improvement in ROM, similar to previous studies. When patients of three-site injections were evaluated after the first sitting, their flexion, extension, and internal and external rotation had improved by 20°, 15°, 23°, and 19.5°, respectively. These values improved further when the patients were reevaluated after the second session, and their ROM was almost normal. A similar result was documented in a comparative study published in 2018 [17]. In addition, approximately 30% of patients in the single-site group had persistent restricted movement, suggesting instilling steroids at specific sites of adhesive capsulitis is effective [18, 19].

4.1. Limitations

Due to the COVID-19 pandemic, we were only able to select a small number of participants for our study. Our study was hampered by its single-centric focus. Many factors increase the study's generalisability by conducting a multi-center trial: a larger sample size, the possibility for inclusion in a wider range of populations, and the ability to compare results across centres.

5. Conclusions

Three-site injections are safer and more effective than single-site injections for treating adhesive capsulitis. Patients who undergo this technique report faster recovery, better shoulder function, and fewer relapses than those treated with single-site injections.

Provenance and peer review

Not commissioned, externally peer-reviewed.

Ethical approval

Ethical approval was obtained from the ethical committee of Shaheed Zulfiqar Ali Bhutto Medical University, reference no F.1-1/2015/ERB/SZABMU/767.

Sources of funding

Nil.

Authors contribution

Contributorship Statement:

The main concept was determined by Muhammad Sharif.

The article is reviewed and approved by Muhammad Sufyan Khan.

Collection of data is done by Tayyeba Khursheed Ahmed, Shazia Zammurad.

Data is interpreted by Wajahat Aziz, Uzma Rasheed.

Writing of the manuscript is done by Hassan Mumtaz, Hassan-ul-Hussnain

Statistical analysis is done by Mohammad Hasan, Sheeza Erum.

Manuscript editing is done by Arslan Iqbal.

Registration of research studies

Name of the registry: Research Registry

Unique Identifying number or registration ID: researchregistry8023

Hyperlink to your specific registration (must be publicly accessible and will be checked): <https://www.researchregistry.com/browse-the-registry/#home/registrationdetails/62ae19071176c8001fb11695/>

Consent

The informed consent from the patients was obtained considering Helsinki's Declaration.

Guarantor

Muhammad Sharif & Hassan Mumtaz.

Declaration of competing interest

Nil.

Acknowledgments

No acknowledgments to be made.

Appendix A. Supplementary data

Supplementary data to this article can be found online at <https://doi.org/10.1016/j.amsu.2022.104071>.

References

- [1] N. Pushpasekaran, N. Kumar, R.K. Chopra, D. Borah, S. Arora, Thawing frozen shoulder by steroid injection: an evaluation and comparative study between a novel three-site injection and single-site injection, *J. Orthop. Surg.* 25 (1) (2017), 2309499016684470.
- [2] C.H. Cho, K.C. Bae, D.H. Kim, Treatment strategy for frozen shoulder, *Clin. Shoulder Elb.* 11 (3) (2019) 249–257.
- [3] D. Challoumas, M. Biddle, M. McLean, N.L. Millar, Comparison of treatments for frozen shoulder: a systematic review and meta-analysis, *JAMA* 3 (12) (2020), e2029581.
- [4] C.H. Cho, K.S. Song, B.S. Kim, D.H. Kim, Y.M. Lho, Biological aspect of pathophysiology for frozen shoulder, *Biomed Res Int.* (2018), 7274517.
- [5] M. Akbar, M. McLean, E. Garcia-Melchor, L.A. Crowe, P. McMillan, U.G. Fazzi, D. Martin, A. Arthur, J.H. Reilly, I.B. McInnes, N.L. Millar, Fibroblast activation and inflammation in frozen shoulder, *PLoS One* 14 (4) (2019), e0215301.
- [6] K. Mezian, R. Coffey, K.V. Chang, Frozen Shoulder, *Internet, InStatPearls*, 2021.
- [7] Y. Sun, S. Liu, S. Chen, J. Chen, The effect of corticosteroid injection into rotator interval for early frozen shoulder: a randomized controlled trial, *J. Am. Coll Sports Med.* 46 (3) (2018) 663–670.
- [8] J.Z. Cher, M. Akbar, S. Kitson, L.A. Crowe, E. Garcia-Melchor, S.C. Hannah, et al., Alarmins in frozen shoulder: a molecular association between inflammation and pain, *J. Am. Coll Sports Med.* 46 (3) (2018) 671–678.
- [9] V. Pandey, S. Madi, Clinical guidelines in the management of frozen shoulder: an update, *Indian J. Orthop.* 55 (2) (2021) 299–309.
- [10] C.H. Cho, B.W. Min, K.C. Bae, K.J. Lee, D.H. Kim, A prospective double-blind randomized trial on ultrasound-guided versus blind intra-articular corticosteroid injections for primary frozen shoulder, *Bone J. Open* 103 (2) (2021) 353–359.
- [11] G. Mathew, R. Agha, for the STROCSS Group, Stross 2021: strengthening the Reporting of cohort, cross-sectional and case-control studies in Surgery, *Int. J. Surg.* 96 (2021), 106165.
- [12] M.I. Butt, T. Iqbal, S. Anjum, Comparison between manipulation under anaesthesia and intra-articular steroid injections for frozen shoulder, *J. Rawalpindi Med. Coll.* (2018) 342–345.
- [13] R. Kumar, N. Bansal, D. Sidhu, D. Kular, D. Sharma, D. Jain, An observational study to compare the outcome of local steroid injections and ultrasonic wave therapy in frozen shoulder patients, *Int. J. Orthop.* 4 (1) (2018) 98–101.
- [14] C. Song, C. Song, C. Li, Outcome of manipulation under anesthesia with or without intra-articular steroid injection for treating frozen shoulder: a retrospective cohort study, *Medicine* 100 (13) (2021).
- [15] B. Mao, R. Peng, Z. Zhang, K. Zhang, J. Li, W. Fu, The effect of intra-articular injection of hyaluronic acid in frozen shoulder: a systematic review and meta-analysis of randomized controlled trials, *J. Orthop. Res.* 17 (1) (2022), 1–0.
- [16] R.D. Khan, K. Shahzad, S. Khan, M. Israr, F.M. Zahid, Comparison of physiotherapy with and without intra-articular corticosteroid injection for treatment of frozen shoulder: a comparative study, *J. Pakistan Med. Assoc.* 71 (8) (2021), S17–21.
- [17] V. Bohra, A.K. Sharma, A. Partani, Frozen shoulder-comparison of physiotherapy alone and along with subacromial or combined subacromial and intraarticular steroid injections, *J. Dent. Med. Sci.* 17 (6) (2018) 67–73.
- [18] R. Chen, C. Jiang, G. Huang, Comparison of intra-articular and Subacromial corticosteroid injection in frozen shoulder: a meta-analysis of randomized controlled trials, *Int. J. Surg.* 68 (2019) 92–103.
- [19] K.L. Gupta, Management of adhesive capsulitis of the shoulder: PRP and steroid injections, *Int. J. Pharmaceut. Chem. Res.* 12 (3) (2020) 32–36.