

# Accuracy of Soft Tissue Prediction of 2 Virtual Planning Systems in Patients Undergoing Intraoral Quadrangular Le Fort II Osteotomy

Katrin Willinger, MSc\*  
 Godoberto Guevara-Rojas, PhD†  
 Julia Cede, MD, DMD\*  
 Kurt Schicho, MD\*  
 Tanja Stamm, PhD, MSc, MBA‡  
 Clemens Klug, MD, DMD\*

**Background:** Virtual surgical planning (VSP) is state of the art in routine clinical work. Visualization of soft tissue changes adds important information for surgical planning. The aim of this study was to evaluate accuracy of soft tissue prediction of 2 VSP systems in patients undergoing an intraoral quadrangular Le Fort II osteotomy. **Methods:** VSP was performed with the software application IPS Case Designer (IPS) and Dolphin Imaging 11.95 (DOL) in bone and soft tissue structure. Distances were measured at the 3 levels of the face at the infraorbital rim, the sinus floor, and the lateral incisor level with 2 VSP systems (DOL and IPS).

**Results:** A convenience sample of 19 patients was included in the study with a mean age of 21.9 years. From cranial to caudal, mean differences between simulation and postintervention data were as follows: infraorbital rim level: DOL and ST0: mean difference: 2.90 mm; IPS and ST0: 1.70 mm; sinus floor level: DOL and ST0: mean difference: 3.57 mm; IPS and ST0: 1.34 mm; and lateral incisor level: DOL and ST0: mean difference: 2.48 mm; IPS and ST0: 2.25 mm.

**Conclusions:** Generally, both VSP systems are suitable for planning an intraoral quadrangular Le Fort II osteotomy. Especially in the infraorbital region, improvement of the algorithm is required for trustworthy prediction of soft tissue changes. (*Plast Reconstr Surg Glob Open* 2021;9:e3326; doi: [10.1097/GOX.0000000000003326](https://doi.org/10.1097/GOX.0000000000003326); Published online 1 February 2021.)

## INTRODUCTION

Today, virtual surgical planning (VSP) is a state-of-the-art procedure in orthognathic surgery. For a successful surgical plan, it is important to visualize the proposed jaw movements and resulting changes of the facial soft tissue. The availability of a realistic expectation of the surgical outcome can enhance patient satisfaction.<sup>1-4</sup> This is especially relevant in the field of corrective surgery in midface deficiency cases.

Among available VSP systems, Dolphin Imaging 11.95 (DOL) and IPS Case Designer (IPS) are widely used.

The intraoral quadrangular Le Fort II osteotomy (IQLFIIO) is an established method for correcting midface deficiency.<sup>5</sup> Developed by Keller and Sather<sup>5</sup> in 1987, the method has been modified several times. The most recent step was described by our group in 2017.<sup>6</sup> The use of the piezotome, the change of the osteosynthesis protocol, and the camouflage of the infraorbital advancement step with milled bone and fibrin glue were introduced with the intention to reduce the technique's morbidity and thus promote the technique for more common use.

For visualization and measurement of soft tissue changes, the Midfacial Advancement Line (MFAL) technique is a suitable tool. The MFAL is a parasagittal curved slice through the face in a 3-dimensional (3D)-rendered image. Thereby surgical changes at the infraorbital rim (IR), at the level of the sinus floor (SF), and of the crown of the lateral incisor (LI) can be viewed at once, giving a good impression of the effect of advancement.<sup>7</sup>

Many studies in the past had their focus on the accuracy and precision of VSP for bone movements and consecutive soft tissue changes, mostly for the chin and lower and upper lip regions.<sup>3,4,8-12</sup> To our knowledge, investigations for the infraorbital region for IQLFIIO cases do not exist yet.

From the \*University Clinic of Cranio- and Maxillofacial Surgery, Medical University of Vienna, Vienna, Austria; †University of Applied Sciences FH Campus Wien, Wien, Austria; and ‡Center for Medical Statistics, Informatics and Intelligent Systems (CeMSIIS), Medical University of Vienna, Vienna, Austria.

This study was funded by the Medical Scientific Fund of the Mayor of the City of Vienna (Project 17097).

Received for publication August 20, 2020; accepted October 28, 2020.

Copyright © 2021 The Authors. Published by Wolters Kluwer Health, Inc. on behalf of The American Society of Plastic Surgeons. This is an open-access article distributed under the terms of the [Creative Commons Attribution-Non Commercial-No Derivatives License 4.0 \(CCBY-NC-ND\)](https://creativecommons.org/licenses/by-nc-nd/4.0/), where it is permissible to download and share the work provided it is properly cited. The work cannot be changed in any way or used commercially without permission from the journal.

DOI: [10.1097/GOX.0000000000003326](https://doi.org/10.1097/GOX.0000000000003326)

**Disclosure:** The authors have no financial interest to declare in relation to the content of this article.

The main objective of this study was to evaluate the infraorbital and midfacial soft tissue prediction of 2 VSP systems by measuring distances between planning and postintervention datasets in IQLFIIO cases.

## MATERIALS AND METHODS

This study was approved by the ethics committee of the Medical University of Vienna (No. EK 1775/2017) and performed according to the Declaration of Helsinki and the Good Clinical Practice guidelines. For publishing identifying images, written informed consent was obtained from all patients in this study.

### Study Sample

The study sample was recruited from a consecutive series treated by modified IQLFIIO at our institution between April 2013 and December 2018. Inclusion criteria were midfacial deficiency and skeletal class III malocclusion as well as the fulfilled protocol with presurgical and postsurgical orthodontic treatment. Eighteen out of 19 patients also received mandibular osteotomy in the same surgical procedure with the midfacial advancement. Exclusion criteria were the absence or poor quality of available presurgical intervention and postsurgical intervention computer tomography (CT) datasets (4 months plus). Six patients of our consecutive case series had to be excluded after having received an augmentation with a bone block at the infraorbital step of IQLFIIO.

### Data Acquisition: VSP

The postintervention data were obtained from CT or cone beam CT (CBCT) examinations at least 4 months after the surgical treatment. VSP was performed by using the software application IPS Case Designer (KLS Martin Group) and Dolphin Imaging 11.95 (Patterson Dental Supply, St. Paul, Minn.). Hard tissue changes between preoperative and postoperative CT scans were measured in a previous step to import these movements into the VSP systems. The soft tissue surface of the CT was set as a reference image soft tissue for each patient. Then a routine workflow for the virtual planning of an IQLFIIO was performed. The position of the maxilla in postintervention status of each patient defined the target position of the maxilla in the VSP system. After the planning process, the VSP data for both bone and soft tissue structures were then exported as STL files.

### Image Fusion and Data Processing

Image fusion was performed with Materialise Mimics Research 21.0 (Materialise NV, Belgium). In a first step, the postsurgical intervention CT or CBCT data were imported into Mimics, and 3D rendering was conducted for hard and soft tissues. Then the data files from the VSP system were also imported into Mimics. In the align module, the postoperative dataset and the virtually planned dataset were stacked using the position of the bony maxilla as a reference point. First, a global registration was performed automatically, while a second step entailed manually conducted fine adjustment. The correct merging was checked

for each patient in 3 different views—axial, sagittal, and coronal.<sup>3</sup> After switching to the 3D-rendered view, the merged models were split along the MFAL orthogonally to the screen. With the exported soft tissue file from the DOL planning system, it was first necessary to calculate polylines from part and cavity fill from polylines to perform the MFAL. For evaluating differences concerning the soft tissue, one part of the postintervention dataset (ST0) and the corresponding second part from the VSP dataset along the MFAL were selected (Fig. 1). In a lateral view, the distances between predicted and real soft tissue were measured by magnifying each landmark point of the MFAL.

### Data Analysis

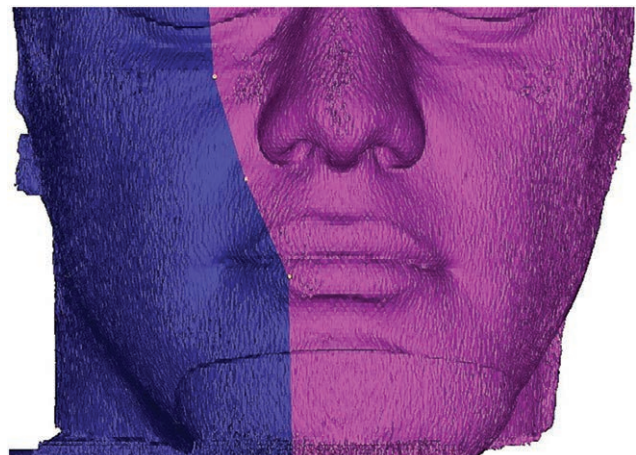
All the measurements have been done by 1 researcher who has been experienced and trained in using these softwares consequently.

The distances between the postsurgical intervention soft tissue surface and the predicted soft tissue surface from the VSP systems DOL and IPS were measured in millimeters at both sides along the MFAL. For characterizing the study cohort, descriptive statistics was used. All data were recorded in Microsoft Excel 2017.

We hypothesized that the mean of the absolute differences between the predicted soft tissue surface from the VSP systems DOL and IPS and the postsurgical intervention soft tissue surface did not differ significantly from 2 mm in soft tissue changes. Therefore, a 1-sample Student *t* test was conducted. Statistical significance was defined as a *P* value smaller than 0.05. We calculated following statistical measures: mean error, SD, median, 95% confidence interval (CI) of the mean error, variants, minimum, maximum, range, interquartile range, skewness, and kurtosis. For the graphical analysis, we created boxplot graphics. Statistical analysis was performed using the open source software R Project R 3.1.1.

## RESULTS

The study sample was composed of 19 skeletally mature patients, all aged between 18 and 37 years (5 women, 14



**Fig. 1.** Three-dimensional-rendered dataset along the MFAL with the postintervention status and VSP.

men, mean age: 22 years). All patients were white and met the inclusion criteria.

Altogether 228 measurements were obtained (2 systems, 19 patients, 2 sides, 3 points).

ST0 images were obtained at a mean of  $9.6 \pm 6.1$  months (range: 4.0–36.0 months) after surgical intervention.

All analyzed IQLFIO cases were planned without vertical, transversal, and rotation changes. The average sagittal forward movement of the maxilla was 4.35 mm (range: 2.3–9.5 mm; SD: 1.90).

Distances were measured at the three levels of the face at the IR, the SF, and the LI level with 2 VSP systems (DOL and IPS).

From cranial to caudal, mean differences between simulation and postintervention data were as follows: IR level: DOL and ST0: mean difference: 2.90 mm (SD: 2.1) and 95% CI (3.6–2.2); IPS and ST0: mean difference: 1.70 mm (SD: 1.3) and 95% CI (1.3–2.1); SF level: DOL and ST0: mean difference: 3.57 mm (SD: 2.0) and 95% CI (2.9–4.2); IPS and ST0: mean difference: 1.34 mm (SD: 0.9) and 5% CI (1.0–1.6); and LI level: DOL and ST0: mean difference: 2.48 mm (SD: 1.9) and 95% CI (1.9–3.1); IPS and ST0: mean difference: 2.25 mm (SD: 1.6) and 95% CI (1.7–2.8).

Figure 2 (DOL) and Figure 3 (IPS) show box plots graphics for each landmark for both VSP systems.

The highest inaccuracy was seen for DOL at the SF level.

Implausible predictions of the soft tissue, like bone perforation, were found at the IR level for both systems in 8 cases each (DOL: case: 2, 4, 5, 7, 8, 9, 17, 18; IPS: case: 5, 7, 10, 14, 15, 16, 17, 18; Figs. 4, 5).

We did not find any correlation between the timing of postsurgical scans and measured differences. Figure 6 shows the distribution of data in a scatter plot for each landmark.

Neither did we find any correlation of the magnitude of bone movement nor the discrepancy between the actual result and prediction. Figure 7 shows the distribution of data in a scatter plot for each landmark.

## DISCUSSION

To our knowledge, this is the first work to evaluate soft tissue changes in patients undergoing an IQLFIO for the treatment of midfacial deficiency and class III malocclusion. While most of the studies in the past concentrated on soft tissue profile changes after a Le Fort I osteotomy and on movement prediction concerning the lips and chin region,<sup>2–4,10,12,13</sup> the focus of this study lay on the prediction and visualization of changes in the region of the IR.

We compared soft tissue prediction of 2 commonly used software applications, IPS and DOL, with the real postoperative outcome. For measuring the distances, we implemented a novel visualization method, the MFAL technique. This method had been validated before in a similar setting with fused pre- and postsurgical datasets but without the VSP simulations. In that work, the authors compared the MFAL technique with a point-to-point measuring method and a 3D surface analysis (with false color display). Two observers had used all 3 techniques twice. Inter- and intraobserver agreement analyses were performed and did not reveal significant differences. MFAL proved to be the most suitable method for visualizing as well as for measuring changes in the midface region.<sup>7</sup>

Consequently, the authors chose MALF for this work, in a single observer design with 1 of the 2 observers of the previous study. The results of this study show that especially in the infraorbital region, both VSP systems significantly differ from the postsurgical datasets. The numerous different variables make the surgical soft tissue prediction

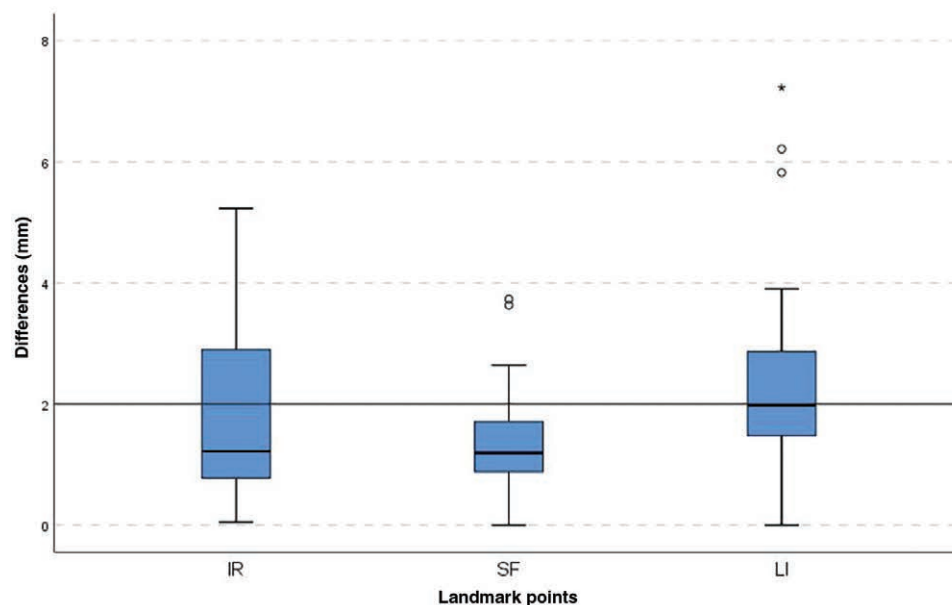
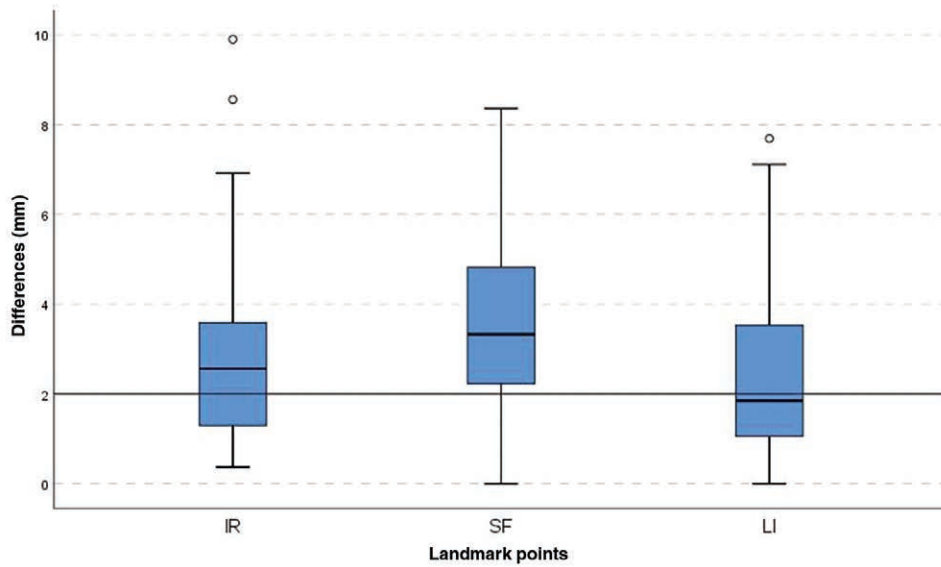


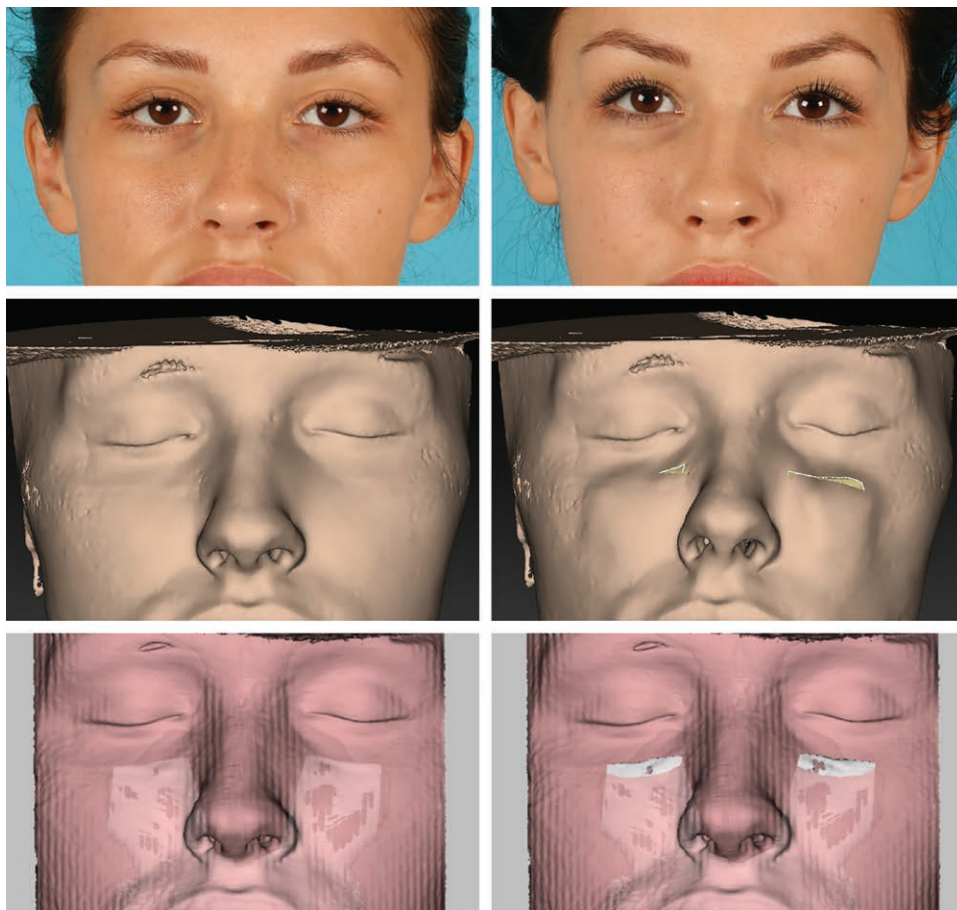
Fig. 2. Boxplot of differences for landmarks IR, SF, and LI for the System Dolphin Imaging.



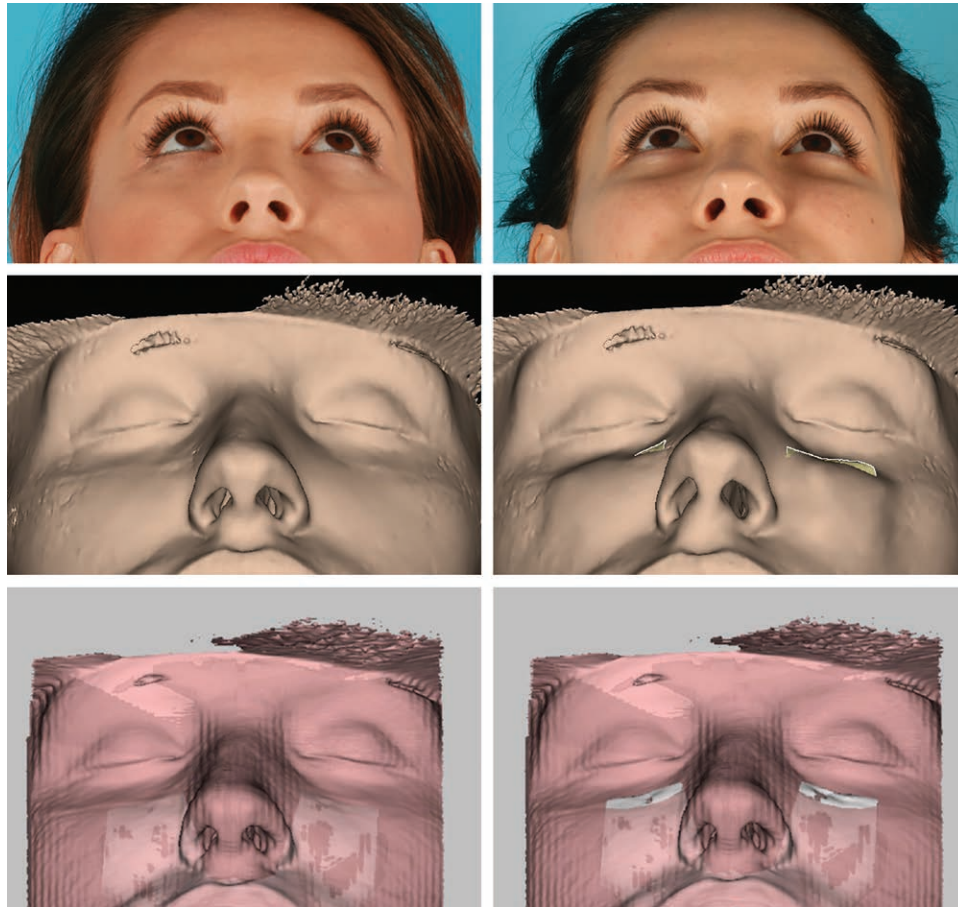
**Fig. 3.** Boxplot of differences for landmarks IR, SF, and LI for the System IPS Case Designer.

very difficult. By adaption of a specific algorithm, VSP systems are able to predict soft tissue profiles after a virtual osteotomy.<sup>3,13</sup> In the present study, the bony structure of

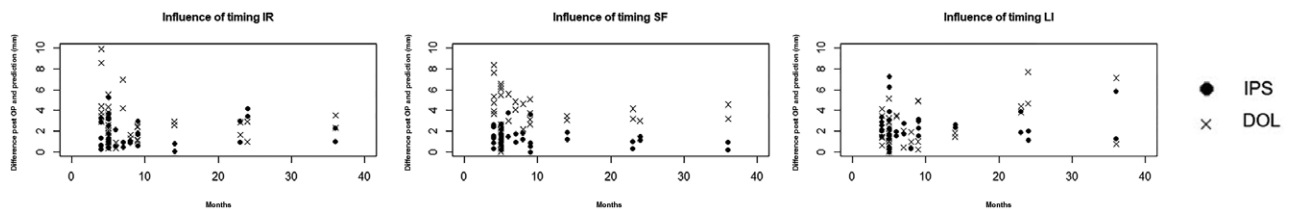
the IR perforated the soft tissue simulation profile in both VSP systems (Figs. 4, 5). This is a major shortcoming of these software applications. The existing algorithms limit



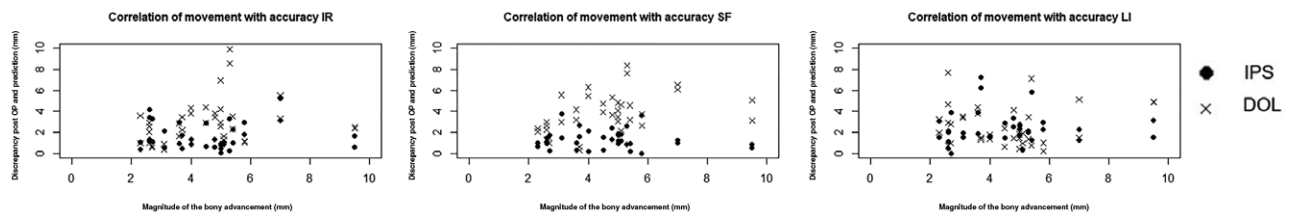
**Fig. 4.** Soft tissue perforation at the level of the IR in the planning software Dolphin Imaging and IPS Case Designer at the IR, SF, and LI en face.



**Fig. 5.** Soft tissue perforation at the level of the IR in the planning software Dolphin Imaging and IPS Case Designer at the IR, SF, and LI from below.



**Fig. 6.** Correlation between the timing of postsurgical scans and measured bony advancement for the landmarks IR, SF, and LI.



**Fig. 7.** Correlation of the magnitude of bone movement and the discrepancy between the actual result and prediction.

the accuracy and quality of soft tissue prediction at the upper level of the face. We suggest that the more data the developers of the algorithm of the VSP systems incorporate, the better the prediction of soft tissue in this region could become. However, there are some variables that are

patient related and cannot be factored easily into algorithms. For example, age might have an impact on soft tissue elasticity. Other influences include fat distribution, body weight, or the tension of the circular mimic muscles.<sup>3,9,14</sup> With this work, we will provide data generation

for the improvement of algorithms to get a reliable prognosis for soft tissue changes after an IQLFIO, especially in the region of the IR. With the help of new technologies like the 3D intraoperative photography, further options for procuring more data to visualize soft tissue profiles are created. The investigators of this study suggest doing some further work for improving soft tissue prediction at the upper level of the face.

Most studies, which had their focus of evaluation of distances between planning data files and postsurgical intervention status of patients after an orthognathic surgery, considered differences of 2 mm as clinically acceptable.<sup>9-11</sup> The authors agree that as mentioned in Kaipatur and Flores-Mir,<sup>2</sup> differences not larger than 2 mm are not noticeable to the naked eye. Additionally, in our opinion, it is also important to consider in which region of the face, differences are measured. Changes at the lower level of the face are different than the ones at the upper level. For instance, in the region of the IR, very small structures have to be taken into consideration. Moreover, there is less adipose tissue and a very fine skin surface in this region.

For this work, differences between soft tissue prediction for patients undergoing mono- or bimaxillary osteotomy are not significant because the authors had their focus on the movements in the midface region. As mentioned in Kaipatur and Flores-Mir,<sup>2</sup> only 2 of 7 studies pointed out that prediction programs for bimaxillary surgery are less reliable in their predictions than the ones for monomaxillary surgery.

For obtaining postsurgical intervention control CT data, as found in literature, the time frame was relatively large.<sup>13</sup> In this work, all postsurgical records used originated from a period at least 4 months after the IQLFIO. This timing was chosen because the authors expected that the soft tissue edema would have minimized and the data could be used for a realistic result. At the same time, the wide time frame of the postsurgical intervention CT examinations could be one limitation of this study, as further movement, for example, as a result of further bony movements, muscle line changes or a different pose of the teeth through orthodontic treatment would not be captured. Nadjmi et al<sup>10,13</sup> recommend that the records of all patients should be at the same time and before orthodontic treatment.

Another restriction of this study is that all results were based on white patients. As different origins of people involve different facial features, this consideration could be a reason for developing new algorithms or adapting existing ones.<sup>3,9</sup> Further studies are deemed necessary by the authors.

An additional limitation is that the authors declined the merging of the soft tissue with a 2D photograph. But we think that this would have had no impact on our results, and possible errors caused by multiple overlays could be excluded this way.

A strength of this study is that the study population was uniform, and possible confounding variables like the ones mentioned above as limitations could eventually be eliminated.

Another advantage is that the IQLFIO was conducted by 1 very experienced surgeon alone for all the cases. All image manipulation and analysis was also performed by 1 radiographer, who is very experienced in working with CT data, 3D rendering, image fusion, and virtual 3D planning for orthognathic surgery.

## CONCLUSIONS

With both VSP systems, planning of an IQLFIO is technically feasible. However, both applications show implausible predictions at the IR level. (The bone perforated through soft tissue.) Prediction of soft tissue changes differs significantly in both systems. Especially in the infraorbital region, improvement of the algorithm is required for trustworthy prediction of soft tissue changes.

*Katrin Willinger, MSc*

Department of Cranio-, Maxillofacial and Oral Surgery  
Medical University of Vienna  
Währinger Gürtel 18-20  
1090 Vienna  
Austria

E-mail: n09501464@students.meduniwien.ac.at

## ACKNOWLEDGMENTS

*The authors would like to thank Mrs. Carina Wiederer, MSc, and Mr. Ing Christoph Trautner, Company Mimics-Materialise, for their valuable support.*

*Statement of Conformity: This study was conducted in accordance with the Declaration of Helsinki.*

## REFERENCES

- Howell LK, Scott MA, Urata MM. Current status of surgical planning for orthognathic surgery: traditional methods versus 3D surgical planning. *Plast Reconstr Surg Glob Open*. 2015;3:1-10.
- Kaipatur NR, Flores-Mir C. Accuracy of computer programs in predicting orthognathic surgery soft. *J Oral Maxillofac Surg*. 2009;67:751-759.
- Liebrechts J, Xi T, Timmermans M, et al. Accuracy of three-dimensional soft tissue simulation in bimaxillary osteotomies. *J Craniomaxillofac Surg*. 2015;43:329-335.
- Resnick CM, Dang RR, Glick SJ, et al. Accuracy of three-dimensional soft tissue prediction for Le Fort I osteotomy using Dolphin 3D software: a pilot study. *Int J Oral Maxillofac Surg*. 2017;49:289-295.
- Keller EE, Sather AH. Intraoral quadrangular Le Fort II osteotomy. *J Oral Maxillofac Surg*. 1987;45:223.
- Klug C, Cede J. Technical modifications for intraoral quadrangular Le Fort II osteotomy. *J Oral Maxillofac Surg*. 2017;75:402.e1-402.e16.
- Willinger K, Cede J, Guevera-Rojas G, et al. The midfacial advancement line - a comparative evaluation of a new measurement method in orthognathic surgery. *J Oral Maxillofac Surg*. 2020;78:286.e1-289.e9.
- Kazandjian S, Sameshima GT, Champlin T, et al. Accuracy of video imaging for predicting the soft tissue profile after mandibular setback surgery. *Am J Orthod Dentofacial Orthop*. 1999;115:382-389.
- Nam K, Hong J. Is three-dimensional soft tissue prediction by software accurate? *J Craniofac Surg*. 2015;26:729-733.
- Nadjmi N, Defrancq E, Mollemans W, et al. Quantitative validation of a computer-aided maxillofacial planning system, focusing on soft tissue deformations. *Ann Maxillofac Surg*. 2018;4:171-175.

11. Peterman RJ, Jiang S, Johe R, et al. Accuracy of Dolphin visual treatment objective (VTO) prediction software on class III patients treated with maxillary advancement and mandibular setback. *Prog Orthod.* 2016;17:19.
12. Magro-Filho O, Magro-Ernica N, Pereira Queiroz T, et al. Comparative study of 2 software programs for predicting profile changes in class III patients having double-jaw orthognathic surgery. *Am J Orthod Dentofac Orthop.* 2010;137:452.e.
13. Nadjmi N, Tehranchi A, Azami N, et al. Comparison of soft-tissue profiles in Le Fort I osteotomy patients with Dolphin and Maxilim softwares. *Am J Orthod Dentofacial Orthop.* 2013;144:654–662.
14. Wagner F, Figl M, Cede J, et al. Soft tissue changes in patients undergoing intraoral quadrangular Le Fort II osteotomy versus conventional Le Fort I osteotomy. *J Oral Maxillofac Surg.* 2018;76:416–425.