

# Preliminary impression techniques for microstomia patients

K. Aswini Kumar, Vinaya Bhat<sup>1</sup>, K. Chandrasekheran Nair<sup>2</sup>, Reshma Suresh<sup>3</sup>

Departments of Prosthodontics and <sup>3</sup>Periodontics, Amrita Vishwa Vidyapeetham, Amrita School of Dentistry, Kochi, Kerala, <sup>1</sup>Department of Prosthodontics and Implantology, AB Shetty Memorial Institute of Dental Sciences, Mangalore, Karnataka, <sup>2</sup>Department of Prosthodontics, Vishnu Dental College, Bhimavaram, Andhra Pradesh, India

## Abstract

The Prosthetic rehabilitation of microstomia patients presents difficulties at all the stages. The difficulty starts with the preliminary impression making. This is due to the tongue rigidity and the decreased oral opening. A maximum oral opening which is smaller than the size of the tray can make prosthetic treatment challenging. Due to the restricted mouth opening, insertion and removal of the impression trays is extremely cumbersome and various modifications of the trays have been used in the past. Among these are the flexible trays and the sectional trays used with different modes of reassembling the segments extra orally after the impression is made. This article reviews the literature published from 1971 to 2015 concerning preliminary impression techniques used in making impressions for patients with microstomia based on various tray designs. An electronic search was performed across three databases (PubMed, Science Direct and Google Scholar) for relevant citations. The keywords/combinations used for the search were microstomia, limited/constricted/restricted mouth opening/oral access, trismus, sectional trays, impressions and prosthetic/prosthodontic rehabilitation. The search was limited to papers written in English which resulted in a total of 45 related articles of which 17 articles were included for discussion of this review.

**Key Words:** Impressions, limited/constricted/restricted mouth opening/oral access, microstomia, prosthetic/prosthodontic rehabilitation, sectional trays, trismus

## Address for correspondence:

Dr. K. Aswini Kumar, Department of Prosthodontics, Amrita Vishwa Vidyapeetham, Amrita School of Dentistry, Cochin, Kerala, India.

E-mail: draswini2000@gmail.com

Received: 22<sup>nd</sup> January, 2016, Accepted: 17<sup>th</sup> March, 2016

## INTRODUCTION

Microstomia is defined as an abnormally small oral orifice.<sup>[1]</sup> It can occur due to electrical, thermal, or chemical burns or due to facial trauma. The condition can also result from genetic disorders such as partial duplication of chromosome 6q, Hallopeau–Siemens-type recessive dystrophic epidermolysis bullosa, Freeman–Sheldon (whistling face) syndrome, Burton skeletal dysplasia, and diseases such as Plummer–Vinson

syndrome or scleroderma.<sup>[2-4]</sup> Other causes include surgical treatment for orofacial cancers and reconstruction of lip defects, surgical treatment of orofacial neoplasms and cleft lips.<sup>[2]</sup> Literature is abundant with various modes of prosthodontic management of microstomia that has been caused by scleroderma.<sup>[2,5-8]</sup>

Generally, to fabricate any prosthesis, impressions are the basic requirement. Prosthetic rehabilitation of microstomia patients

Access this article online	
Quick Response Code:	Website: www.j-ips.org
	DOI: 10.4103/0972-4052.186400

This is an open access article distributed under the terms of the Creative Commons Attribution-NonCommercial-ShareAlike 3.0 License, which allows others to remix, tweak, and build upon the work non-commercially, as long as the author is credited and the new creations are licensed under the identical terms.

For reprints contact: reprints@medknow.com

**How to cite this article:** Kumar KA, Bhat V, Nair KC, Suresh R. Preliminary impression techniques for microstomia patients. J Indian Prosthodont Soc 2016;16:229-33.

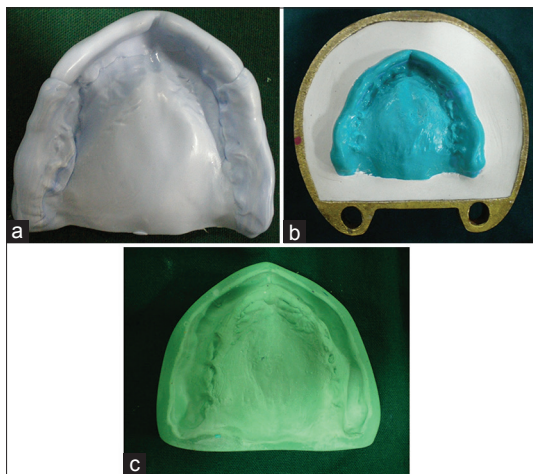
presents difficulties at all the stages, from the preliminary impressions to fabrication of the prosthesis. The difficulty starts with the preliminary impression making.<sup>[3]</sup> This is due to the tongue rigidity and the decreased oral opening.<sup>[2,6]</sup> A maximum oral opening which is smaller than the size of a complete denture can make prosthetic treatment challenging.<sup>[5]</sup> Due to the restricted mouth opening, insertion and removal of the impression trays is extremely cumbersome, and various modifications of the trays have been used in the past. Among these are the flexible trays and the sectional trays used with different modes of reassembling the segments extraorally after the impression is made.

This article intends to review the literature published from 1971 to 2015 concerning preliminary impression techniques used in making impressions for patients with microstomia based on various tray designs. An electronic search was performed across three databases (PubMed, Science Direct, and Google Scholar) for relevant citations. The keywords/combinations used for the search were microstomia, limited/constricted/restricted mouth opening/oral access, trismus, sectional trays, impressions, and prosthetic/prosthetic rehabilitation. The search was limited to papers written in English which resulted in a total of 45 related articles of which 17 articles were included for discussion of this review.

**FLEXIBLE TRAY TECHNIQUES**

**Technique I: Flexible impression trays**

In this technique, a nonrigid tray was used to obtain a diagnostic impression. The material used consists of silicone putty that was inserted and molded in the mouth before it polymerized. Because of its flexible nature, the silicone tray could be easily inserted and removed.



**Figure 1:** (a-c) Flexible impression tray technique

**Methods**

Putty material was mixed in sufficient quantity to cover all the important anatomic regions of the arch. Sufficient quantity of accelerator was added to the mix to reduce the setting time of the material to 1 min. The material was then placed into the patient’s mouth and adapted to hard and soft tissues. It was allowed to polymerize, and the tray was quickly removed from the mouth [Figure 1a]. Then, the tray was filled with injectable silicone material, and the procedure was repeated to obtain a more detailed impression. Impression tray had to be stabilized by placing it into a nondisplacing mix of dental plaster before it was boxed and poured [Figure 1b]. The diagnostic cast was then made [Figure 1c].<sup>[5,9,10]</sup>

**Technique II: Flexible plastic trays**


**Methods**

Here, a horse-shoe-shaped flexible plastic tray (used for fluoride application) was selected. No. 8 round bur was used to make perforations in many places over the surface. A mixture of well-kneaded silicone putty impression material was loaded into the tray and it was molded over the inner surface of the tray. The loaded tray was squeezed enough to insert through the limited oral opening and was seated over the ridge. The material was adapted to the palate with finger pressure, and the tissue was used to mold the material around the periphery. After the material was almost set, it was removed from the mouth and the undercuts and overextended portions of the impression material were trimmed off, thus making an individualized impression tray. Later, a wash impression in this individualized impression tray with light body silicone impression material was made. After the material was set, the impression is examined for details and the cast was prepared.<sup>[2,6]</sup>

**Technique III: Reinforced flexible impression trays**

**Methods**

This was a modified method of Technique I. Here, the



**Figure 2:** Reinforcing wire

flexible impression tray made of putty silicone material was reinforced with an acrylic “U”-shaped device with a cross bar connecting the two arms. A 19-gauge orthodontic wire was formed into a “U”-shape corresponding to the arch form. A cross bar made of the similar dimension wire was soldered to connect the two arms of the horseshoe wire [Figure 2]. This was encapsulated in autopolymerizing resin for additional strength. This was incorporated within the putty impression while it is polymerizing in the mouth [Figure 3]. This helped in preventing the excess flexibility of the impression and prevented it from distortion while removing from the mouth and later while pouring the impression.

### SECTIONAL TRAY TECHNIQUES

Sectional trays are of different types. They can be either segmented anteroposteriorly or mediolaterally. Simple designs to join the impression segments extraorally have been described by various authors.<sup>[2,7,8,11-15]</sup>

#### Technique IV: Anteroposteriorly sectioned stock trays

In this technique, preliminary impressions for both arches were obtained by sectioned stock trays. Using a caliper, the arch width of the mandible and maxilla were measured. Then, two identical stock trays for both jaws corresponding to the measurements were selected.

The first set of trays for each jaw were cut anteroposteriorly in two sections with a disk following a line that bisected the tray into one-third and two-third pieces passing to the right side of the midline. The larger section of the tray included the handle. This tray was made as wide as the mouth opening width of the patient to allow ease of insertion into the oral cavity. At the same time, it was large enough to register as much of the oral structures beyond the midline as possible. The second trays were cut anteroposteriorly to the left side of the midline. The width of these trays was similar to the first trays.

#### Methods

The preliminary impression of the left side of the maxillary arch was made with elastomeric impression material using the first tray. The second tray was used to accomplish the impression of the right side [Figure 4].

First, the right side of the impression was poured with dental plaster. After it was set, the left side of the impression was positioned on the cast and poured, ensuring not to displace the cast seated in the impression and was held with finger pressure until plaster was set [Figures 5 and 6]. The mandibular impression was made and poured in the same manner.<sup>[7,15]</sup>

#### Technique V: Mediolaterally sectioned stock trays

In this technique, the selected stock trays were sectioned

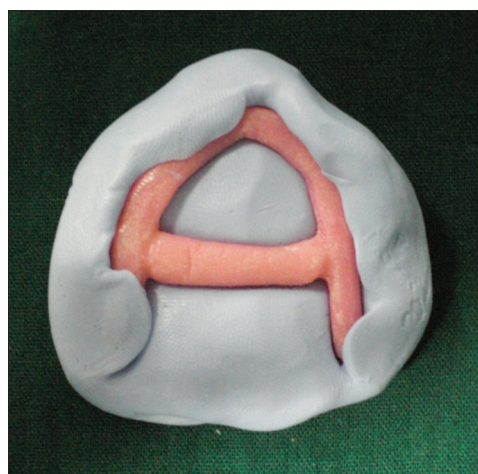


Figure 3: Completed reinforcing device




Figure 4: Anteroposteriorly sectioned tray technique




Figure 5: One-half poured

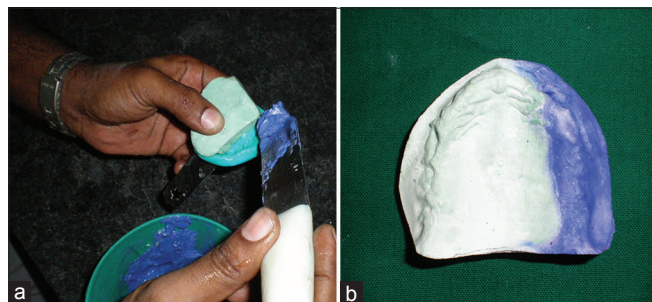mediolaterally instead of sectioning anteroposteriorly as in the previous technique. The impression is made in the posterior segment first, and then the anterior segment was used to make impression with the posterior impression in the mouth. Both the impressions were taken out separately, assembled, and were poured with dental plaster.

**Technique VI: Plastic trays with building blocks**

Here, a suitable plastic impression tray was selected that corresponded to the measurements of the arch width of the patient's ridge measured using a caliper. Plaster or artificial dental stone was poured into the plastic impression tray to form a matrix. To ensure the subsequent fit of the tray on the matrix, the impression tray was removed and reinserted on the matrix. The plastic tray was cut into two sections with a disk, the larger section to include the handle. Three plastic building blocks (toy) were selected to approximate the sectioned tray as a single unit. Two of them were of the similar dimension, i.e., 16 mm × 8 mm × 3 mm and the other one was of double its length, i.e., 32 mm × 8 mm × 3 mm. The two smaller blocks were assembled under the larger block. The entire assembly was positioned on the sectioned tray overlying the sectioned area. The smaller blocks were then joined with the tray using autopolymerizing resin. The larger block was joined with the smaller block that was attached to the smaller segment of the tray (tray segment that was without the handle). In the clinical procedure, impression was first made with irreversible hydrocolloid using the larger sectional tray. Excess impression material was trimmed to flush with tray. With this impression in the mouth, impression on the smaller tray segment was made. When the impressions were in the mouth, pressure was applied on the building blocks till the material was set. Once the material was set, the smaller segment was disassembled and removed before removing the larger segment and was reassembled outside the mouth before pouring the cast.<sup>[14]</sup>

**Technique VII: Technique using impression compound**

- Conroy and Reitzik<sup>[13]</sup> explained a sectional impression technique using impression compound. First, a sectional impression was made and it was trimmed to the midline. Petroleum jelly was applied to the entire impression and was repositioned on the arch. Then, the impression of the other section was made with impression compound. Both the impressions were removed and reassembled outside the mouth and was poured to obtain a preliminary cast
- Al-Hadi and Abbas<sup>[11]</sup> used impression compound to make preliminary impression of the mandibular edentulous



**Figure 6:** (a) Pouring of second half, (b) the completed cast

ridge for a patient with surgically induced microstomia. They divided the ridge into three segments, two posterior and one anterior extending between canines. Impression compound was shaped to correspond to these segments to obtain segmental impressions. They were poured in dental plaster. The special trays were fabricated, tried, and impressions were made individually. The three segments of the impression were stabilized in the mouth with compound before they were withdrawn as one impression. This impression was poured, and a special segmental tray was fabricated on this cast for secondary impression.

**Technique VIII: Technique using cross pins and slots**

Cross-pin placed on one section and slot placed on the other section of the handle of the tray using Pindex<sup>®</sup> machine was proposed by Prasad *et al.*<sup>[16]</sup> Impression compound was used to make preliminary impressions, and excess material crossing midline was trimmed to flush with the margin. The primary cast was poured after tray sections were reassembled extraorally.

**Technique IX: Technique using magnets**

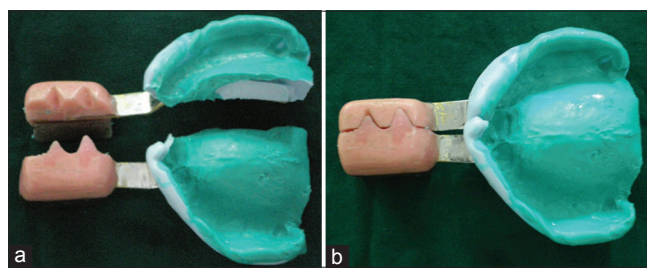
In this technique, a magnet was embedded in acrylic formed around the handle of one-half of the cut stock tray and a metal plate was attached on the other half. After the sectional impressions were made, the two halves of the impression were aligned outside the mouth aided by the magnetic attraction [Figure 7].<sup>[17]</sup>

**Miscellaneous technique**

In cases where a denture was constructed before the patient developed microstomia, McCord *et al.*<sup>[18]</sup> proposed a technique where impression plaster was poured onto the tissue surface of the patient's denture and a cast made on which special tray may be constructed.

**DISCUSSION**

Decreased overall perimeter of the oral cavity poses unique problems during the fabrication of prostheses. Since the impressions are the first step, the operator must have the knowledge of various methods of obtaining impressions for such cases. In the techniques explained above, either a flexible, heavy viscosity material like silicone putty is used



**Figure 7:** (a) Sectioned tray with magnets, (b) assembled tray with impression

as it is or reinforced with a device made of orthodontic wire and autopolymerizing resin. It has also been combined with a flexible plastic tray used for fluoride application. Reinforcement devices provide added support to the impression while they are being poured with dental stone in the laboratory. It takes advantages of the flexibility of the impression material while it is being used and the rigidity of the reinforcing material while the impression is being poured.

The other techniques make use of the modified stock trays. Tray selection is usually done by measuring the circumference of the oral cavity in full opening and later transferring it to the appropriate trays. These trays are then sectioned either anteroposteriorly or mediolaterally. Anteroposterior sectioning usually is done in such a way that the larger segment includes the handle of the tray. The newer technique makes use of the magnetic system. A magnet is embedded in acrylic onto one-half of the sectioned tray, and a metal plate is attached to the other half. This facilitates easy reassembling of the impressions outside the mouth.

Preliminary impressions for patients with microstomia should be followed by technical alterations or modifications of other steps in completing the prosthesis. For edentulous microstomic patients, especially those who have suffered scarring, flexible complete denture materials are an alternative.<sup>[19]</sup> The fabrication of a foldable maxillary removable complete denture with a custom palatal hinge<sup>[20]</sup> and a foldable maxillary and mandibular complete denture with a stainless steel hinge fitted with autopolymerizing acrylic resin<sup>[21]</sup> has also been reported.

## CONCLUSION

For patients with microstomia, all the clinical procedures for fabrication of prostheses are difficult. This article has reviewed and discussed the various techniques available for the first step in the prostheses fabrication, i.e., the preliminary impression. The authors recommend that selection of an appropriate technique should be based on the case requirement and the operator's skills.

## Acknowledgment

Authors would like to thank Dr. Preethy and Dr. Lakshmi Priya of Amrita School of Dentistry for their support.

## Financial support and sponsorship

Nil.

## Conflicts of interest

There are no conflicts of interest.

## REFERENCES

1. The glossary of prosthodontic terms. *J Prosthet Dent* 2005;94:10-92.
2. Benetti R, Zupi A, Toffanin A. Prosthetic rehabilitation for a patient with microstomia: A clinical report. *J Prosthet Dent* 2004;92:322-7.
3. Geckili O, Cilingir A, Bilgin T. Impression procedures and construction of a sectional denture for a patient with microstomia: A clinical report. *J Prosthet Dent* 2006;96:387-90.
4. Wahle JJ, Gardner LK, Fiebiger M. The mandibular swing-lock complete denture for patients with microstomia. *J Prosthet Dent* 1992;68:523-7.
5. Cura C, Cotert HS, User A. Fabrication of a sectional impression tray and sectional complete denture for a patient with microstomia and trismus: A clinical report. *J Prosthet Dent* 2003;89:540-3.
6. Dhanasomboon S, Kiatsiriroj K. Impression procedure for a progressive sclerosis patient: A clinical report. *J Prosthet Dent* 2000;83:279-82.
7. Dikbas I, Koksal T, Kazazoglu E. Fabricating sectional-collapsible complete dentures for an edentulous patient with microstomia induced by scleroderma. *Quintessence Int* 2007;38:15-22.
8. Watanabe I, Tanaka Y, Ohkubo C, Miller AW. Application of cast magnetic attachments to sectional complete dentures for a patient with microstomia: A clinical report. *J Prosthet Dent* 2002;88:573-7.
9. Cheng AC, Kwok-Seng L, Wee AG, Tee-Khin N. Prosthodontic management of edentulous patient with limited oral access using implant-supported prostheses: A clinical report. *J Prosthet Dent* 2006;96:1-6.
10. Whitsitt JA, Battle LW. Technique for making flexible impression trays for the microstomic patient. *J Prosthet Dent* 1984;52:608-9.
11. Al-Hadi LA, Abbas H. Treatment of an edentulous patient with surgically induced microstomia: A clinical report. *J Prosthet Dent* 2002;87:423-6.
12. Baker PS, Brandt RL, Boyajian G. Impression procedure for patients with severely limited mouth opening. *J Prosthet Dent* 2000;84:241-4.
13. Conroy B, Reitzik M. Prosthetic restoration in microstomia. *J Prosthet Dent* 1971;26:324-7.
14. Luebke RJ. Sectional impression tray for patients with constricted oral opening. *J Prosthet Dent* 1984;52:135-7.
15. Suzuki Y, Abe M, Hosoi T, Kurtz KS. Sectional collapsed denture for a partially edentulous patient with microstomia: A clinical report. *J Prosthet Dent* 2000;84:256-9.
16. Prasad R, Bhide S, Gandhi P, Divekar N, Madhav V. Prosthodontic management of a patient with limited mouth opening: A practical approach. *J Indian Prosthodont Soc* 2008;8:83.
17. Kumar KA, Bhat V, Nandini VV, Nair KC. Preliminary impressions in microstomia patients: An innovative technique. *J Indian Prosthodont Soc* 2013;13:52-5.
18. McCord JF, Moody GH, Blinkhorn AS. Overview of dental treatment of patients with microstomia. *Quintessence Int* 1990;21:903-6.
19. Egan JG, Swindells SA. A novel prosthodontic alternative for patients who are edentulous and have microstomia: A case report. *Spec Care Dentist* 2012;32:160-4.
20. Givan DA, Auclair WA, Seidenfaden JC, Paiva J. Sectional impressions and simplified folding complete denture for severe microstomia. *J Prosthodont* 2010;19:299-302.
21. Kumar S, Arora A, Yadav R. Foldable denture: For microstomia patient. *Case Rep Dent* 2012;2012:757025.