

Full-Endoscopic Posterior Lumbar Interbody Fusion with Epidural Anesthesia: Technical Note and Initial Clinical Experience with One-Year Follow-Up

Chao Jiang^{1,2,*}

Si Yin^{1,*}

Jianmin Wei^{3,*}

Weigong Zhao¹

Xiaohui Wang^{1,2}

Yongyuan Zhang^{1,2}

Dingjun Hao²

Heng Du¹

¹Department of Orthopaedics, The First Affiliated Hospital of Xi'an Jiaotong University, Xi'an, Shaanxi, People's Republic of China; ²Department of Spine Surgery, Honghui Hospital, Xi'an Jiaotong University, Xi'an, Shaanxi, People's Republic of China; ³Department of Spine Surgery, Baoji City Hospital of Traditional Chinese Medicine, Baoji, Shaanxi, People's Republic of China

*These authors contributed equally to this work

Objective: The purpose of this study was to introduce and evaluate the early clinical outcomes of the full-endoscopic posterior lumbar interbody fusion (Endo-PLIF) technique with epidural anesthesia (EA) for single-segment lumbar degenerative diseases.

Methods: In this retrospective case series study, we explored the feasibility and effectiveness of the Endo-PLIF with EA for single-segment lumbar degenerative diseases. Between March 2018 and January 2019, a series of 24 patients with single-segment lumbar degenerative diseases underwent Endo-PLIF surgery and were followed up for a minimum of 12 months (15.21±2.27 months). Clinical outcomes including visual analog scale (VAS) scores for back and leg pain, Oswestry Disability Index (ODI) scores, and the Short Form-36 health survey questionnaire (SF-36) were evaluated preoperatively, and postoperatively at 3 days and at 3, 6, and 12-months.

Results: All patients underwent successful single-segment Endo-PLIF surgery. The mean operation time was 209.17±39.49 min, and average amount of bleeding was 43.33±14.87 mL. The VAS for lower extremity pain and back pain significantly improved at 3 days, and at 3, 6, 12 months compared with preoperative, respectively. The ODI scores decreased from 42.04±3.96 to 12.75±2.71 ($P<0.001$) at preoperative and 12 months postoperatively, respectively. The SF-36 Physical Component Scores (PCS) improved from 34.96±4.63 preoperatively to 52.08±6.05 ($P<0.001$) at 12 months postoperatively. Additionally, the SF-36 Mental Component Scores (MCS) improved from 39.38±5.70 at preoperative to 53.13±5.97 ($P<0.001$) at 12 months postoperatively. Two patients experienced dysesthesia, and one patient had a wound infection.

Conclusion: Endo-PLIF with EA is a feasible and valuable technique for the treatment of single-segment lumbar degenerative diseases in selected patients.

Keywords: full-endoscopic posterior lumbar interbody fusion, lumbar degenerative disease, lumbar fusion, clinical outcome

Introduction

Lumbar degenerative diseases (LDD) are common, and the age of onset has been trending downwards over the years. LDD has been considered as the main cause of chronic low back pain (LBP) and sciatica, including lumbar disc herniation, lumbar spinal stenosis, and lumbar spondylolisthesis.^{1,2} Currently, while ladder-like therapy is recommended to treat with LDD, surgery is the most effective

Correspondence: Heng Du
Department of Orthopaedics, The First Affiliated Hospital of Xi'an Jiaotong University, Xi'an, Shaanxi, People's Republic of China
Email drdul8@126.com

treatment in the final step.¹ Open surgical procedures, including anterior lumbar interbody fusion (ALIF), posterior lumbar interbody fusion (PLIF), lateral lumbar interbody fusion (LLIF) and transforaminal lumbar interbody fusion (TLIF), have been regarded as effective interventions that can achieve ideal clinical outcomes by addressing the pathology thoroughly.³ Meanwhile, there are some limitations that should not be ignored, such as extensive soft tissue destruction and long period of recovery. In addition, enhanced recovery after surgery (ERAS) has become of importance to spinal surgeons.^{4,5} Therefore, minimally invasive techniques have been explored to perform lumbar interbody fusion in recent years.

A large body of evidence has demonstrated that minimally invasive techniques can safely and effectively perform LIF.^{6,7} In 2002, Khoo et al⁸ validated minimally invasive PLIF (MIS-PLIF) in three cadaveric torsos and then applied it in three patients. After that, MIS-PLIF was used by more spinal surgeons and obtained excellent clinical outcomes.^{9–11} LIF has shifted from conventionally open to minimally invasive procedures to date. For example, compared with the conventional TLIF, MIS-TLIF can achieve equivalent clinical outcomes with less destruction and a faster postoperative recovery.^{12,13} Furthermore, several studies have reported endoscopic spinal surgery techniques that have proven to be safe and less invasive.^{14–16} Endoscopic transforaminal lumbar interbody fusion (Endo-TLIF), has been employed extensively as a representative procedure.^{17–19} With the updates in surgical technique and minimally invasive concept, endoscopic-assisted spinal surgery will be attractive for surgeons to conduct decompression and LIF for patients with LDD. However, the safety and effectiveness of Endo-PLIF have remained unclear.

In this study, we introduced a minimally invasive technique to perform PLIF using a full endoscopic technique, and collected and analyzed a series of patients' clinical data. The purpose of this study was to evaluate the safety and effectiveness of the Endo-PLIF for the treatment of single-segment LDD.

Materials and Methods

Patients

From March 2018 to January 2019, 24 consecutive patients (14 females and 10 males; mean age: 59.54±7.37 years) suffering from LDD underwent Endo-PLIF.

All operations were performed by the same surgeon (H Du). Surgical indications met the inclusion criteria as the following:¹ patients who complained about low back pain and sciatica;² patients who were diagnosed with lumbar degenerative diseases by combining medical history and imaging data, especially lumbar spinal canal stenosis (the central and lateral recess stenosis) and spondylolisthesis (lower than grade II);³ single-segment that was involved; and⁴ non-surgical treatments that failed or were more than 6 months. Exclusion criteria were as follows:¹ patients who had no symptoms and signs;² patients who suffered from spinal infection or coagulation abnormalities;³ patients who had previously undergone lumbar surgical treatment; and⁴ patients who were unwilling to receive surgery or unable to complete follow-up. Clinical baseline and perioperative characteristics of patients were collected, including age, weight, gender, diagnosis, examination findings, operative details, follow-up time, postoperative complications and functional scores. This study conformed to the Declaration of Helsinki and was approved by the ethics committee of the First Affiliated Hospital of Xi'an Jiaotong University (Number:2020G28). Informed consent was obtained from every patient after explanation of the study.

Outcome Assessment and Follow-Up

Outcome assessment included functional and radiological results. Functional outcomes were determined by comparing preoperative measurements with follow-up data, including visual analog scale (VAS) scores for back and leg pain, Oswestry Disability Index (ODI) scores, and the Short Form-36 health survey questionnaire (SF-36). Follow-up was a minimum of 12 months after surgery. CT scans and X-rays were taken at 3, 6 and 12 months after operation, which were used to evaluate the fusion rate according to Brantigan and Steffee criteria (Table 1).^{20,21} Grade 4 and grade 5 were considered fusion.

Surgical Techniques

The schematic diagram of the procedure is shown in Figure 1. The patient was placed prone on a radiolucent table, which was convenient for surgeons to obtain X-ray images by C-arm during the procedure. Spinous process, bilateral pedicles and intervertebral space horizontal line at vertebral bodies of the adjacent lesion level were confirmed by C-arm fluoroscopic control, and the corresponding positions were marked on the skin (Figure 2A). In order to obtain live feedback from the patients when

Table I The Fusion Grade of Brantigan and Steffee Criteria

Grade	Fusion Result	Radiological Description
1	Obvious radiographic pseudarthrosis	Collapse of vertebral construct, disc height reduction, vertebral slippage, screws break, cage migration, or bone graft resorption.
2	Probable radiographic pseudarthrosis	Significant resorption of bone graft, or visible gap or lucency of the fusion area over 2mm.
3	Radiographic status uncertain	Visible bone graft in the fusion area with approximately the density originally achieved surgically; A small visible lucency or gap in the fusion area with at least half of the graft area showing no lucency between the graft bone and vertebral bone.
4	Probable radiographic fusion	Bone bridges formation in the entire fusion area with at least the density originally achieved surgically. No lucency between the donor bone and vertebral bone.
5	Radiographic fusion	Radiographical evidence showing more dense and mature bone in the fusion area. No interface between the donor bone and vertebral bone. Sclerotic line between the graft and vertebral bone. Mature bony trabeculae bridge in the fusion area, fusion of facet joints.

nerve roots decompressed, the procedure was performed with epidural anesthesia (EA). The anesthetic scheme was the following: 0.1–0.2% ropivacaine + dexmedetomidine (micro-infusion pump–sedation loading dose: 0.5 µg/kg (10–15 min); maintenance doses: 0.2–0.5 µg/kg.h). Further, it was necessary to maintain a catheter for adding anesthetics (ropivacaine 7–10 mL) intraoperatively. After anesthesia, an incision was made at the skin entry point from the outer edge of spinous process (8 mm) to the inner edge of articular process, parallel to midline of the intervertebral space. The needle was inserted into the junction of articular process and lamina, which was kept parallel to the space. The dilating and protective cannula were carried out along the needle, and C-arm was employed to confirm the correct position (Figure 2B). Next, the dilating cannula was removed, and the endoscopic system (SPINEENDOS, Germany) was installed. The parameters of endoscopic system are 7.0 mm (outer diameter), 4.3 mm (inner diameter) and 2.5 mm (endoscopic drill).

Under full endoscopic visualization, the articular processes of surgical level and ligamentum flavum were exposed, and the inferior articular process and partial lamina of upper vertebral body were removed by endoscopic drill (Figure 2C). Additionally, the part superior articular process (SAP) of the lower vertebral body was also removed. We initially removed the inferior articular process and reserved partial SAP. The distance was about 8–10 mm from the nerve root to the remaining SAP, which guaranteed a safe working space for completing surgery. After that, the dural sac and nerve root were exposed by removing ligamentum flavum and hypertrophied tissues (Figure 2D). The ipsilateral nerve root was sufficiently decompressed and released under the endoscopic system. If the patient suffered from bilateral symptoms, the contralateral nerve root decompression was performed by adjusting the cannula direction.

Subsequently, under the C-arm fluoroscopic control and neuromonitoring, the ZELIF[®] system (Sanyou, Inc.,

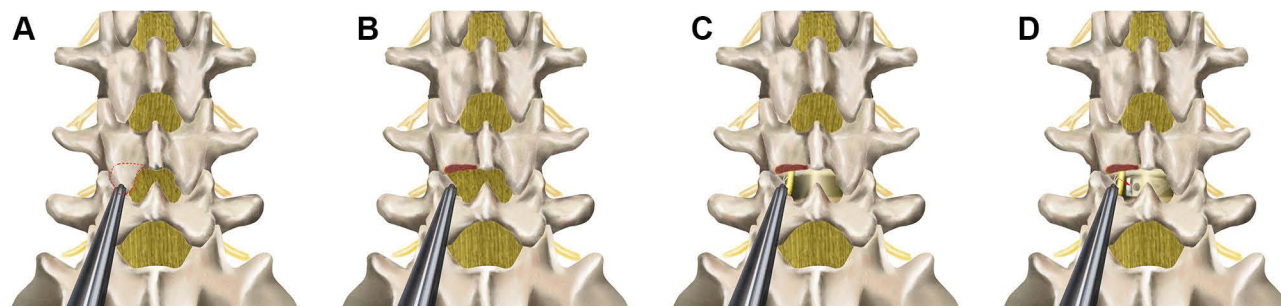


Figure 1 The schematic diagram of the procedure. (A) Placing work cannula targeting to the junction of spinous space and lamina; (B) Removing the inferior articular process; (C) Exposing and decompressing the nerve root; (D) Implanting allograft bone and PEEK cage.

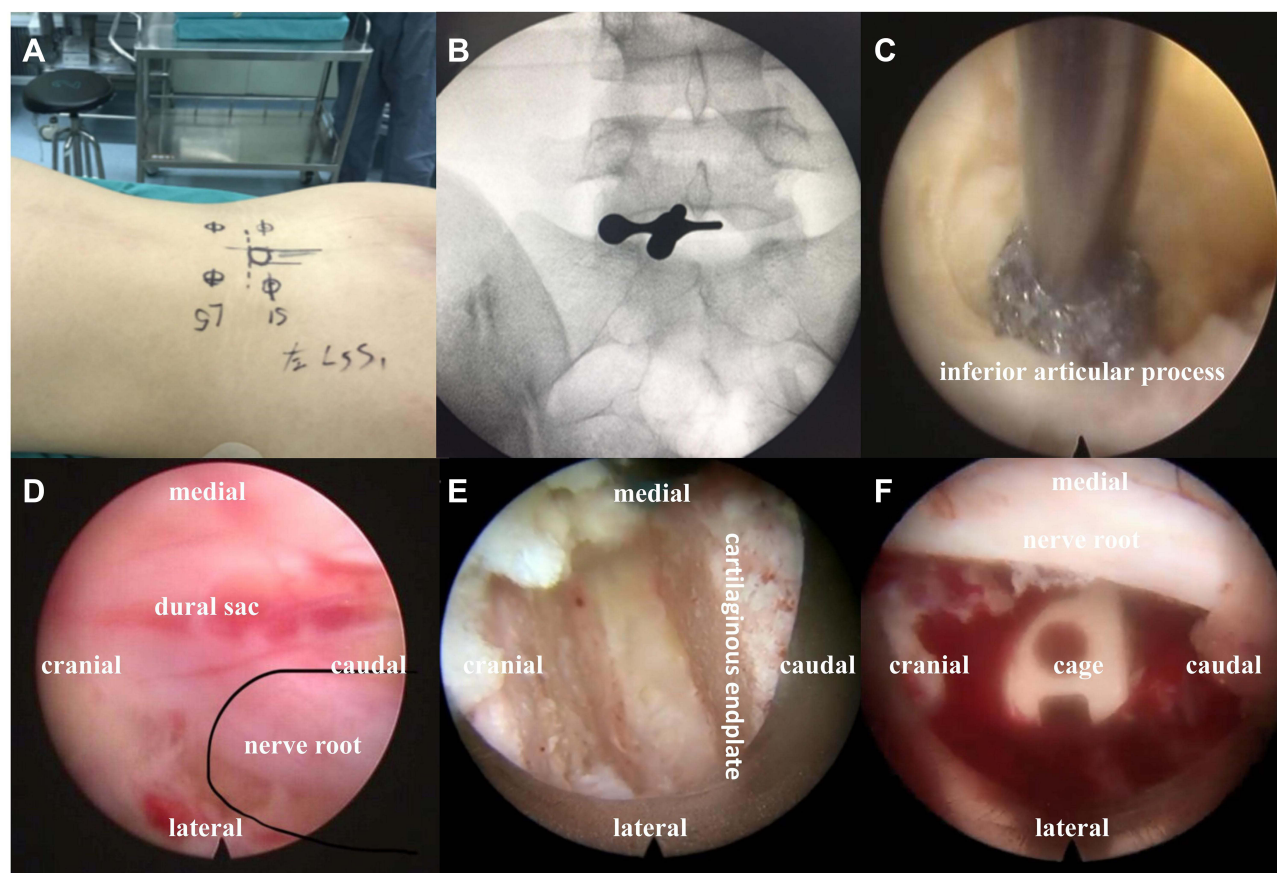


Figure 2 Intraoperative endoscopic images. (A) Confirming and marking skin entry points by C-arm; (B) Placing work cannula targeting to the junction of spinous space and lamina under C- arm fluoroscopic control; (C) Removing the inferior articular process, partial lamina, and the partial superior articular process by endoscopic drill under the full visualization; (D) Exposing nerve root after removing ligamentum flavum and hypertrophied tissues; (E) Scrapping away adequately cartilaginous endplate; (F) Checking cage position by full endoscopic visualization.

Shanghai, China)¹³ was installed via dilating layer by layer and then applied to perform discectomy and endplate preparation, which provided a safe and accessible approach to disc space (Figure 3A and B). The ZELIF[®] system is a caudally expandable rectangular tubular system with the dimensions of 100 mm (length) x 9 mm (width) x 14 mm (height) (Figure 4A and B). The disc tissue was removed through reamers and scrapers of different sizes (Figure 4C). After removal of the disc tissue, the cartilaginous endplate was scrapped away with curettes under endoscopic visualization, which ensured adequate endplate preparation (Figure 2E). The model cages height (8mm/10mm/12mm) and length (23mm/26mm) were implanted through the cannula under the C-arm fluoroscopic control and neuromonitoring. After confirming the optimal size, the model was removed, and the PLIF cage (PEEK material, Sanyou, Inc., Shanghai, China) filled with allograft bone was implanted under the C-arm fluoroscopic control (Figure 3C and D). Full endoscopic view checking found that the dural sac and

nerve root were adequately decompressed without injury (Figure 2F). The endoscopic system and working cannula were withdrawn after meticulous hemostasis.

After local anesthesia, four 15 mm incisions were made in the previously marked skin point entry, and percutaneous pedicle screws were implanted through the incision under the C-arm fluoroscopic control. Bilateral connecting rods were installed percutaneously and tightened screw-rod after confirming the ideal position by C-arm (Figure 3E and F). All instruments were removed, and the skin incisions sutured. There was no drainage after the operation.

Statistical Analysis

Data were analyzed using the statistical software SPSS 23.0 (SPSS, IBM Inc, American). Continuous variables were represented as mean±standard deviation (SD). Categorical variables were shown as number and percent. Differences between preoperative and postoperative variables were analyzed by using the repeated measures

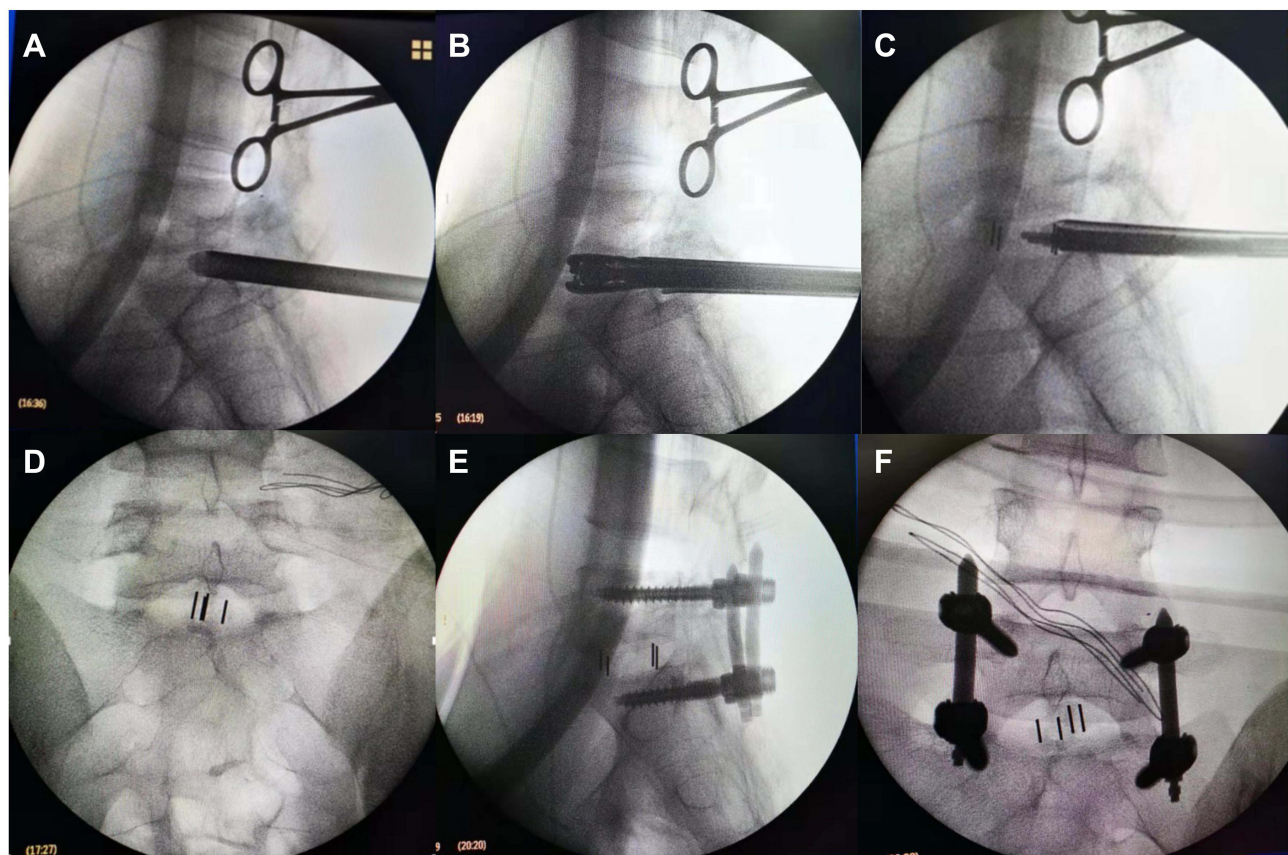


Figure 3 Intraoperative C-arm fluoroscopic control. (A–C) Installing expandable tubular, dilating intervertebral space and implanting allograft bone and PEEK cage under the C-arm fluoroscopic control; (D) Lateral X-rays showing satisfactory cage position; (E and F) Anteroposterior and lateral X-rays showing correct implant position.

analysis of variance. For all tests, the significance was set at a P value of <0.05 (two-tailed).

Results

Baseline Clinical and Intraoperative Detail of Patients

In this study, 24 patients were included with ages ranging from 45 to 75 (59.54 ± 7.37) years. All patients underwent a single-segment Endo-PLIF procedure, with 12 cases at L4/5, 10 cases at L5/S1 and two cases at L3/4. Baseline clinical and perioperative characteristics of patients are shown in Table 2. All patients' diagnosis was confirmed before surgery without contraindications. There were 10 cases with lumbar spinal stenosis, eight cases with lumbar disc herniation accompanying instability, and six cases with lumbar spondylolisthesis. The average operation time was 209.17 ± 39.49 min (range 158–320 min), the mean intraoperative blood loss was 43.33 ± 14.87 mL (range 25–80 mL), and the mean hospitalization duration was 8.67 ± 3.59 days (range 5–22 d).

No patient was lost to follow-up and the average follow-up time was 15.21 ± 2.27 months (range 12–20 m).

Clinical Outcomes

Compared with preoperative clinical assessments, lower back pain VAS dramatically decreased from 5.83 ± 1.09 to 3.54 ± 0.72 , 2.42 ± 0.65 , 1.71 ± 0.75 , 0.96 ± 0.69 at postoperative 3 days and at 3, 6 and 12 months, respectively. Likewise, lower extremity pain VAS dramatically decreased from 6.54 ± 1.22 to 4.33 ± 0.92 , 2.58 ± 0.83 , 1.42 ± 0.78 , 0.71 ± 0.62 at postoperative 3 days and at 3, 6 and 12 months. Further, ODI dramatically improved from 42.04 ± 3.96 to 35.33 ± 5.25 , 25.17 ± 4.26 , 17.67 ± 4.38 , and 12.75 ± 2.71 postoperative 3 days and at 3, 6, and 12 months, respectively. Of note, SF-36 PCS improved from 34.96 ± 4.63 to 39.88 ± 4.92 , 43.79 ± 4.84 , 47.25 ± 4.57 , 52.08 ± 6.05 at postoperative 3 days and at 3, 6, and 12 months, respectively. Similarly, SF-36 MCS improved from 39.38 ± 5.70 to 42.29 ± 5.77 , 45.21 ± 6.21 , 48.92 ± 5.48 , 53.13 ± 5.97 at postoperative 3 days and at 3, 6, and 12 months, respectively (Table 3).

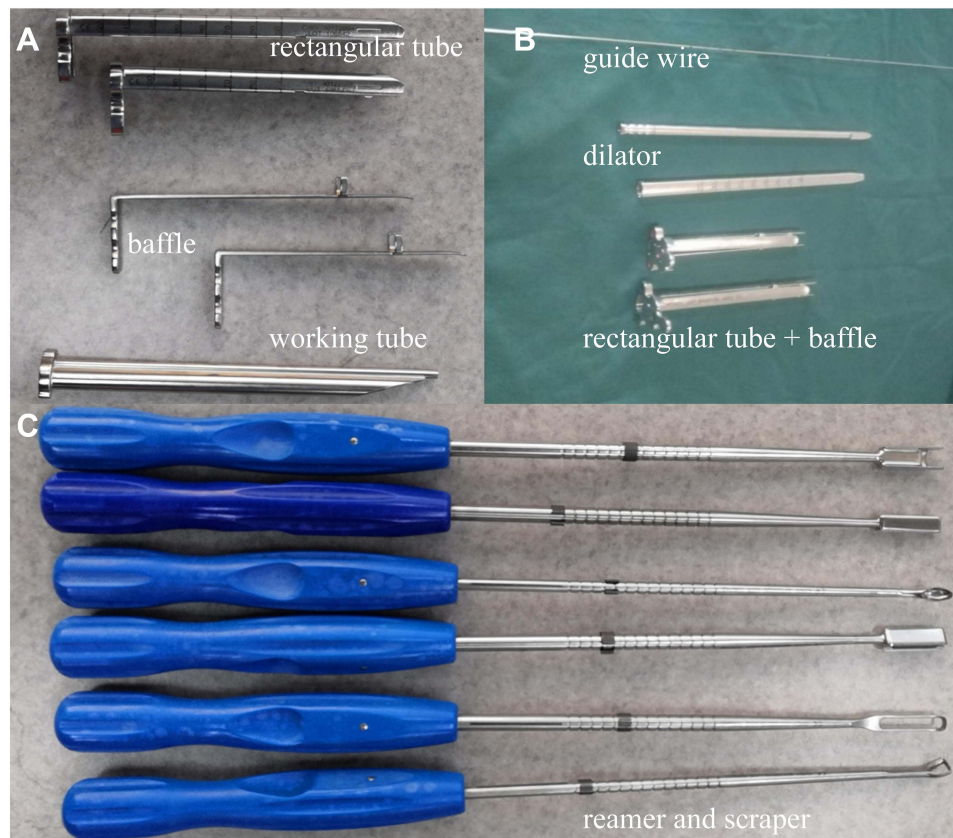


Figure 4 Instruments of ZELIF. (A and B) Guide wire, dilator, working tube and baffle of ZELIF® system; (C) Reamers and scrapers.

Radiological Outcomes

There were no observed cases of nonunion, cage migration and subsidence in our initial 24 patients at 12 months after operation, including 4 cases with fusion grade 4 (16.67%) and 20 cases with fusion grade 5 (83.33%) (Table 3).

Complications

Three patients (12.5%) experienced complications after surgery (Table 2). Two patients suffered from paresthesia without dyskinesia. The distributions of paresthesia corresponded to the surgical site traversing the nerve root, which was caused by a pressed nerve root in the procedure. They were treated with conservative therapy, including physical treatment and medicine. Symptoms were gradually relieved and completely recovered by the last follow-up. There was no severe nerve injury in any patient. Surgical site infection occurred in one patient on the fifth day after surgery, which was superficial in nature with a negative bacterial culture. The surgical wound healed with dressing changes and antibiotics within a month. No patient is required to undergo revision or debridement surgery.

Representative Cases

Two representative cases of patients in this study are shown in Figures 5 and 6.

Discussion

In the present study, we demonstrate that full-endoscopic posterior lumbar interbody fusion (Endo-PLIF) is a feasible and effective technique in initial 24 cases. Previous publications have demonstrated that interbody fusion surgery is an effective treatment for unbearable LBP caused by LDD, especially for patients with nonsurgical therapy failure.^{1,2} In the past decades, conventional open LIF has been regarded as the gold standard for treatment of this patient population due to complete decompression, satisfactory fusion rate, solid internal fixation and excellent clinical outcomes at long-time follow-up.^{3,6} Various procedures for open LIF have been developed to improve the surgical results and minimize morbidity, yet significant surgical destruction still occurs, such as long surgical incision and high intraoperative blood loss.⁶ Additionally, ERAS programs have been paid widespread attention in multiple surgical fields. Wang et al⁵

Table 2 Baseline Clinical and Perioperative Characteristics of Patients

Characteristics		Value	Incidence (%)
N		24	–
Age (years)		59.54±7.37	–
Gender	Males	10	41.67%
	Females	14	58.33%
Weight (kg)		61.5±9.61	–
Operative segment	L3/L4	2	8.33%
	L4/L5	12	50.00%
	L5/S1	10	41.67%
Clinical diagnosis	Lumbar spondylolisthesis	6	25.00%
	Lumbar disc herniation with instability	8	33.33%
	Lumbar spinal stenosis	10	41.67%
Operation time (min)		209.17±39.49	–
Amount of bleeding (mL)		43.33±14.87	–
Hospitalization duration (d)		8.67±3.59	–
Follow-up time (m)		15.21±2.27	–
Fusion		24	100%
Postoperative complications	Wound infection	1(4.17%)	12.5%
	Paresthesia	2(8.33%)	

provided the first ERAS protocol for interbody fusion and conducted a retrospective study, which reduced care cost, recovery time and morbidity after surgery. Regardless of which procedure has been employed to perform LIF, the final aims are similar: achieving optimal outcomes and minimal complications. Endo-PLIF, a newly emerging technique owing to iterative instruments and innovative concepts, takes advantages of less invasive surgery to obtain complete decompression and satisfactory fusion.

In our study, patients who suffered from LDD, including lumbar spinal stenosis, disc herniation with instability and spondylolisthesis, and were immune to nonsurgical treatments underwent single-segment Endo-PLIF. Decompression and fusion play a critical role in addressing LDD for most patients. Of note, endoscopic indications and applications have been evolving in spinal surgery. Foley et al²² first reported and evaluated the feasibility of micro-endoscopy discectomy (MED) in treating lumbar disc herniation. Since then, endoscopic technique has been gaining attraction to address more

spinal diseases. At present, endoscopic techniques have been widely applied in spinal surgery ranging from the cervical to lumbar spine.²³ Meanwhile, initial studies mainly focus on one- or two-segment fusion with endoscopy,²³ but multiple-segments will be explored as instruments improve and experiences accumulate. With this understanding, we performed Endo-PLIF with single-segment.

Regarding operative details, operation time and hospitalization duration were longer in our study compared to similar reports.^{19,24} Preoperative examination may be an important aspect, which usually took two or three days in our hospital. The other reason for this may be that although the surgeon had experience in spinal surgery with endoscopy, it was the first time performing fully endoscopic fusion. Theoretically, the learning curve is essential for spinal surgeons to master a novel technique;³ therefore, those drawbacks will be inevitable for the novice, but will eventually be overcome with skilled technique. We also took more time to evaluate the recovery condition of patient after surgery.

Table 3 Preoperative and Follow-Up Functional Scores

Characteristics		Value	P
Lower back pain VAS	Preoperative	5.83±1.09	–
	Postoperative 3 days	3.54±0.72*	< 0.001
	Postoperative 3 months	2.42±0.65*	< 0.001
	Postoperative 6 months	1.71±0.75*	< 0.001
	Postoperative 12 months	0.96±0.69*	< 0.001
Lower extremity pain VAS	Preoperative	6.54±1.22	–
	Postoperative 3 days	4.33±0.92*	< 0.001
	Postoperative 3 months	2.58±0.83*	< 0.001
	Postoperative 6 months	1.42±0.78*	< 0.001
	Postoperative 12 months	0.71±0.62*	< 0.001
ODI scores%	Preoperative	42.04±3.96	–
	Postoperative 3 days	35.33±5.25*	< 0.001
	Postoperative 3 months	25.17±4.26*	< 0.001
	Postoperative 6 months	17.67±4.38*	< 0.001
	Postoperative 12 months	12.75±2.71*	< 0.001
SF-36 PCS	Preoperative	34.96±4.63	–
	Postoperative 3 days	39.88±4.92*	< 0.001
	Postoperative 3 months	43.79±4.84*	< 0.001
	Postoperative 6 months	47.25±4.57*	< 0.001
	Postoperative 12 months	52.08±6.05*	< 0.001
SF-36 MCS	Preoperative	39.38±5.70	–
	Postoperative 3 days	42.29±5.77*	< 0.001
	Postoperative 3 months	45.21±6.21*	< 0.001
	Postoperative 6 months	48.92±5.48*	< 0.001
	Postoperative 12 months	53.13±5.97*	< 0.001
Fusion grade	Grade 4	4	16.67%
	Grade 5	20	83.33%

Notes: * $P < 0.001$, postoperative 3 days, 3 months, 6 months and 12 months compared with preoperative. Grade 4, probable fusion. Grade 5, fusion.

Abbreviations: VAS, visual analog scale, ODI, Oswestry disability index, PCS, physical component score, MCS, mental component score.

Finally, postoperative complications, especially one case with surgical site infection, increased mean hospitalization duration.

The push to develop minimally invasive techniques has played a vital role in driving spinal surgery technique evolution.²³ However, how to obtain optimal outcomes and minimal complications has been a challenge for

surgeons, especially those with elderly and comorbid patients. On the one hand, surgeon should address patients' complaints as completely as possible. On the other hand, they must consider perioperative risk, complications and costs. Wang MY and colleagues²⁵ reported 10 consecutive patients who underwent endoscopic TLIF without general anesthesia. In the present study, we made

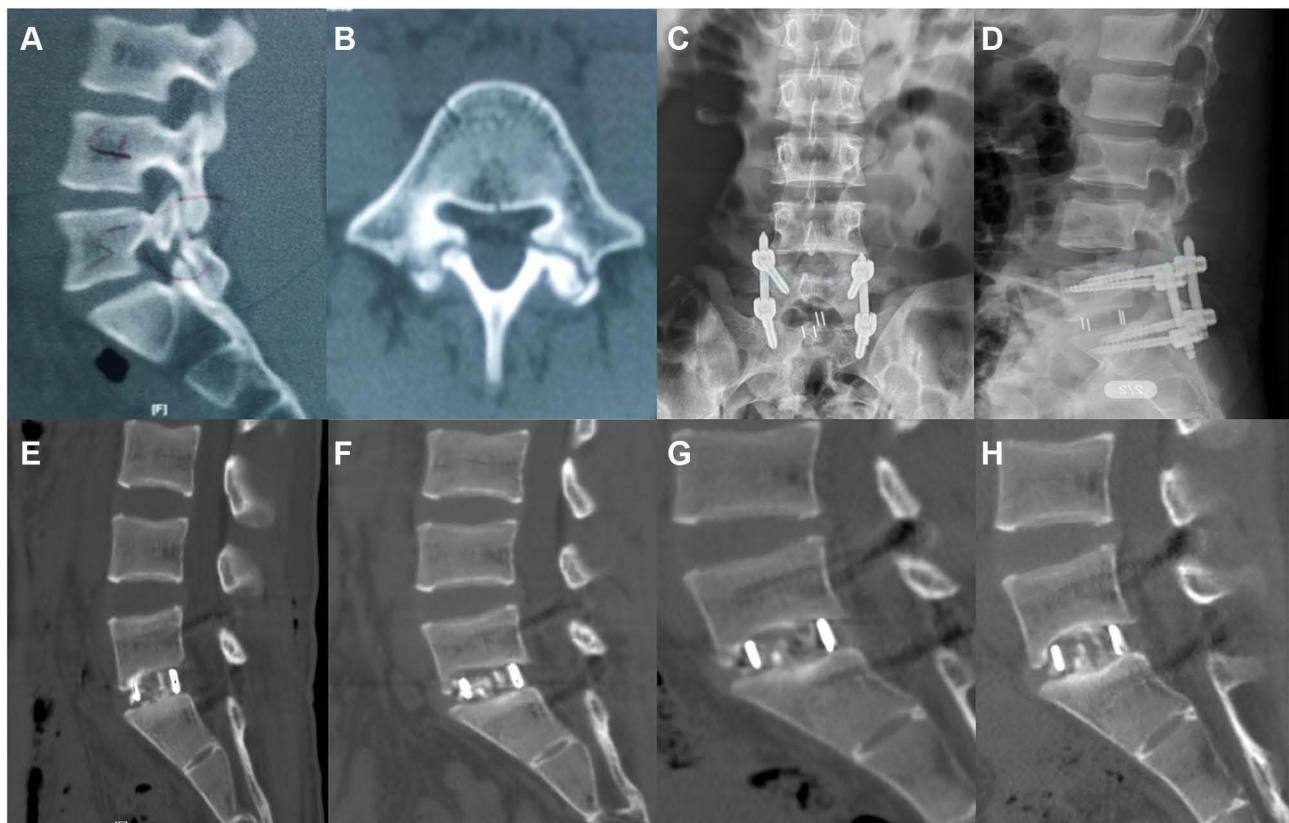


Figure 5 Images were obtained from a 48-year-old male patient with the degenerative spondylolisthesis at L5-S1. (A and B) Sagittal and axial CT images showing degenerative spondylolisthesis at L5-S1; (C and D) Postoperative anteroposterior and lateral X-rays images showing correct cage and pedicle screws after full Endo-PLIF; (E-H) Postoperative sagittal CT images at 3, 6, 9, 12 months showing interbody fusion.

full use of the advantages of EA compared to general anesthesia to reduce risks in higher risk populations. Compared with general anesthesia, EA can provide sufficient pain relief with minimal influences on cardiovascular and respiratory systems. It also keeps patients conscious to cooperate with the surgery, which is helpful to decrease the risk of nerve injury. Moreover, EA not only increases the degree of satisfaction but also improves the effectiveness of the operation. Along with faster recovery and lower cost, EA enhances surgical patients' safety and comfort. Therefore, the aging population, especially those with cardiopulmonary dysfunction, could undergo Endo-PLIF, which may allow for more patients to obtain surgical benefits.

Since the endoscope-assisted TLIF was introduced in 2008,²³ many scholars have attempted and designed special instruments to perform TLIF with the endoscope.^{14,17,19,25,26} Although many spinal procedures share the endoscopic labels, the surgical techniques can mainly be grouped into three categories in terms of the endoscopic system used: percutaneous endoscopic (or

full-endoscopic) TLIF, biportal endoscopic TLIF and micro-endoscopic TLIF.⁷ Compared with the minimally invasive TILF (MIS-TLIF), Endo-TLIF demonstrated better outcomes and faster recovery time after operation, owing to less invasion.^{13,27} In fact, the transforaminal approach must face the following challenges: exiting nerve roots injury and inadequately contralateral decompression, which have been determined by the anatomical structure. In a retrospective research, the TESSYS-ISEE technique was employed to remove the dorsal and ventral structures around the involved nerve root, which achieved 270-degree spinal canal decompression.²⁴ Moreover, the coronal imbalance and lumbar lordosis cannot be completely addressed through Endo-TLIF or MIS-TLIF because of the narrow surgical corridor. Therefore, the expandable cage has been used to overcome this drawback.²⁸ However, there is still controversy surrounding the late outcome of the expandable cage. The expandable cage is superior to the conventional PEEK cage in biomechanical stability but may lead to endplate fracture when bracing in intervertebral space due to excessive extrusion.^{29,30}

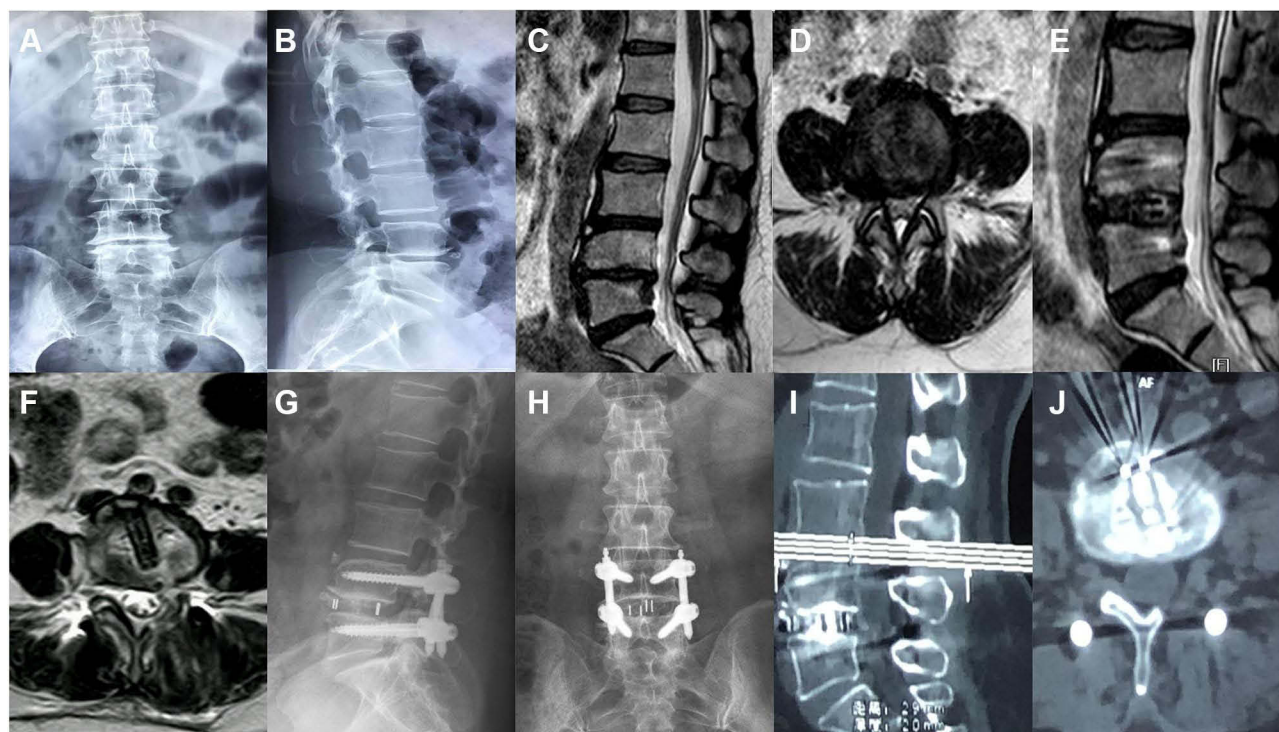


Figure 6 Images were obtained from a 51-year-old female patient with the lumbar spinal stenosis at L4-5. (A–D) Preoperative X-rays and MRI images showing lumbar spinal stenosis at L4-5; (E and F) Postoperative sagittal and axial MRI images showing complete decompression after full Endo-PLIF; (G and H) Postoperative anteroposterior and lateral X-rays at 3 months showing correct position; (I and J) Postoperative sagittal and axial CT images at 6 months showing interbody fusion.

A recent monocentric study reported that the expandable cage did not show better clinical outcome and improved sagittal alignment in the MIS-TLIF, and even increased the risk of late subsidence after operation.³¹ In our patients, we used similar PLIF surgical access to achieve complete decompression and fusion under the endoscope. Only part of the superior articular process was removed, which is less invasive and helps maintain the stability of spine. Meanwhile, this technique is helpful to perform contralateral decompression and conforms to anatomical structure for orthopedic surgeons. Additionally, the whole procedure was performed with full visualization, which reduces tissue injury and performs thorough endplate preparation. For interbody fusion, short-term outcomes are determined by decompression and long-term outcomes are determined by endplate preparation. In order to achieve satisfactory decompression and fusion, we took the advantages of ZELIF[®] in our series. This exquisite design provides enough working room and can reach the intervertebral space, which is helpful to perform adequate decompression and insert the conventional PEEK cage. There were no observed cases of nonunion, cage migration or subsidence in our initial 24 patients at 12 months after operation. Importantly, postoperative follow-up

indicated remarkable improvement in VAS, ODI score, SF-36 PCS and MCS. Compared with previous studies, postoperative outcomes were similar and less invasive to our design.^{11,14}

In summary, we utilized the endoscope and ZELIF[®] to conduct posterior lumbar interbody fusion with epidural anesthesia. First, we achieved sufficient decompression, especially for central canal and contralateral decompression. Second, a conventional PEEK cage could be inserted by ZELIF[®]. Finally, the aging patients, especially those with cardiopulmonary dysfunction, could obtain surgical benefits with EA. Based on the preliminary experience, the major Endo-PLIF indications include single-level lumbar degenerative diseases, such as lumbar spinal canal stenosis (the central and lateral recess stenosis) and spondylolisthesis (lower than grade II).

The complications and limitations of the present study should be brought to attention. Postoperative complications have negative effects, such as prolonging hospitalization and increasing cost. Paresthesia occurred in two patients after surgery, and after analysis, we found that insufficient articular process removal was the main cause; the nerve root was disturbed when cage inserted into disc space through narrow channel. Certainly, the traversing nerve root and epidural

may be injured when the posterior access is taken, which are the disadvantages of this technique. One patient suffered from an incision infection and the resultant increased hospitalization stay. Several limitations were as follows: First, this was a retrospective case series, and the sample size was small. Compared with randomized controlled trials (RCTs), the reliability of the results was limited. Second, only the selected patients underwent this novel procedure; therefore, whether this procedure was suitable for a greater population requires further study. Third, more potential complications were not exposed due to the short follow-up and small sample; multi-center studies consisting of a larger sample size should be performed in the future.

Conclusion

In summary, Endo-PLIF with EA is proven to be a feasible and effective technique for the treatment of single-segment lumbar with degenerative diseases in selected patients. However, Endo-PLIF technique has relatively limited indications, and requires surgeon mastery of the technique. In addition, narrow working channels and large cage insertion remain huge challenges. Future improvement of technique and instrument is needed for application of Endo-PLIF in the treatment of lumbar degenerative diseases.

Abbreviations

EA, epidural anesthesia; Endo-PLIF, Full-endoscopic Posterior Lumbar Interbody Fusion; VAS, visual analog scale; ODI, Oswestry Disability Index; SF-36, Short Form-36 health survey questionnaire; MCS, Mental Component Scores; PCS, Physical Component Scores; LDD, Lumbar degenerative diseases; LBP, low back pain; ALIF, anterior lumbar interbody fusion; PLIF, posterior lumbar interbody fusion; LLIF, lateral lumbar interbody fusion; TLIF, transforaminal lumbar interbody fusion; ERAS, enhanced recovery after surgery; MIS-PLIF, minimally invasive PLIF; Endo-TLIF, Endoscopic transforaminal lumbar interbody fusion; MED, micro-endoscopy discectomy.

Data Sharing Statement

All the data will be available upon motivated request to the corresponding author.

Ethics Approval and Consent to Participate

This study conformed to the Declaration of Helsinki and was approved by the ethics committee of the First

Affiliated Hospital of Xi'an Jiaotong University (Number:2020G28). Informed consent was obtained from every patient after explanation of the study.

Consent for Publication

Informed consent was obtained from every patient before publishing their data.

Acknowledgments

The authors thank AiMi Academic Services (www.aimieditor.com) for the English language editing and review services.

Author Contributions

All authors made substantial contributions to conception and design, acquisition of data, or analysis and interpretation of data; took part in drafting the article or revising it critically for important intellectual content; agreed to submit to the current journal; gave final approval for the version to be published; and agreed to be accountable for all aspects of the work.

Funding

This study was supported by the Natural Science Foundation of Shaanxi Province of China (grant number 2019JM-558 and 2020SF-080) and the Fundamental Research Funds for the Central Universities (grant number xjh012019062).

Disclosure

The authors declare that they have no competing interests.

References

1. Phillips FM, Slosar PJ, Youssef JA, et al. Lumbar spine fusion for chronic low back pain due to degenerative disc disease: a systematic review. *Spine*. 2013;38(7):E409–422. doi:10.1097/BRS.0b013e3182877f11.
2. Xiao L, Zhao Q, Sun X, et al. Relationship between alterations of spinal/pelvic sagittal parameters and clinical outcomes after oblique lumbar interbody fusion. *World Neurosurg*. 2020;133:e156–e164. doi:10.1016/j.wneu.2019.08.158
3. Wu J, Liu H, Ao S, et al. Percutaneous endoscopic lumbar interbody fusion: technical note and preliminary clinical experience with 2-year follow-up. *Biomed Res Int*. 2018;2018:5806037. doi:10.1155/2018/5806037
4. Kehlet H, Wilmore DW. Multimodal strategies to improve surgical outcome. *Am J Surg*. 2002;183(6):630–641. doi:10.1016/S0002-9610(02)00866-8
5. Wang MY, Chang PY, Grossman J. Development of an Enhanced Recovery After Surgery (ERAS) approach for lumbar spinal fusion. *J Neurosurg Spine*. 2017;26(4):411–418. doi:10.3171/2016.9.SPINE16375

6. Xu DS, Walker CT, Godzik J, et al. Minimally invasive anterior, lateral, and oblique lumbar interbody fusion: a literature review. *Ann Trans Med*. 2018;6(6):104. doi:10.21037/atm.2018.03.24.
7. Ahn Y, Youn MS, Heo DH. Endoscopic transforaminal lumbar interbody fusion: a comprehensive review. *Expert Rev Med Devices*. 2019;16(5):373–380. doi:10.1080/17434440.2019.1610388
8. Khoo LT, Palmer S, Laich DT, et al. Minimally invasive percutaneous posterior lumbar interbody fusion. *Neurosurgery*. 2002;51(5 Suppl):S166–181.
9. Park Y, Ha JW. Comparison of one-level posterior lumbar interbody fusion performed with a minimally invasive approach or a traditional open approach. *Spine*. 2007;32(5):537–543. doi:10.1097/01.brs.0000256473.49791.f4
10. Fan S, Hu Z, Zhao F, et al. Multifidus muscle changes and clinical effects of one-level posterior lumbar interbody fusion: minimally invasive procedure versus conventional open approach. *EUR Spine J*. 2010;19(2):316–324. doi:10.1007/s00586-009-1191-6.
11. Sidhu GS, Henkelman E, Vaccaro AR, et al. Minimally invasive versus open posterior lumbar interbody fusion: a systematic review. *Clin Orthop Relat Res*. 2014;472(6):1792–1799. doi:10.1007/s11999-014-3619-5.
12. Lee KH, Yue WM, Yeo W, et al. Clinical and radiological outcomes of open versus minimally invasive transforaminal lumbar interbody fusion. *Eur Spine J*. 2012;21(11):2265–2270. doi:10.1007/s00586-012-2281-4.
13. Ao S, Zheng W, Wu J, et al. Comparison of Preliminary clinical outcomes between percutaneous endoscopic and minimally invasive transforaminal lumbar interbody fusion for lumbar degenerative diseases in a tertiary hospital: is percutaneous endoscopic procedure superior to MIS-TLIF? A prospective cohort study. *Int J Surg*. 2020;136–143. doi:10.1016/j.ijsu.2020.02.043
14. Ruetten S, Komp M, Merk H, et al. Full-endoscopic interlaminar and transforaminal lumbar discectomy versus conventional microsurgical technique: a prospective, randomized, controlled study. *Spine*. 2008;33(9):931–939. doi:10.1097/BRS.0b013e31816c8af7.
15. Cong L, Zhu Y, Tu G, A meta-analysis of endoscopic discectomy versus open discectomy for symptomatic lumbar disk herniation. *Eur Spine J*. 2016;25(1):134–143. doi:10.1007/s00586-015-3776-6
16. Ruan W, Feng F, Liu Z, et al. Comparison of percutaneous endoscopic lumbar discectomy versus open lumbar microdiscectomy for lumbar disc herniation: a meta-analysis. *Int J Surg*. 2016;31:86–92. doi:10.1016/j.ijsu.2016.05.061
17. Jacquot F, Gastambide D. Percutaneous endoscopic transforaminal lumbar interbody fusion: is it worth it? *Int Orthop*. 2013;37(8):1507–1510. doi:10.1007/s00264-013-1905-6
18. Lee S-H, Erken HY, Bae J. Percutaneous transforaminal endoscopic lumbar interbody fusion: clinical and radiological results of mean 46-month follow-up. *Biomed Res Int*. 2017;2017:3731983. doi:10.1155/2017/3731983
19. Kim JE, Choi DJ. Biportal Endoscopic transforaminal lumbar interbody fusion with arthroscopy. *Clin Orthop Surg*. 2018;10(2):248–252. doi:10.4055/cios.2018.10.2.248
20. Brantigan JW, Steffee A. A carbon fiber implant to aid interbody lumbar fusion. two-year clinical results in the first 26 patients. *Spine*. 1993;18(14):2106–2117. doi:10.1097/00007632-199310001-00030
21. Heo DH, Park CK. Clinical results of percutaneous biportal endoscopic lumbar interbody fusion with application of enhanced recovery after surgery. *Neurosurg Focus*. 2019;46(4):E18. doi:10.3171/2019.1.FOCUS18695
22. Foley K, Smith M, Rampersaud Y. Microendoscopic approach to far-lateral lumbar disc herniation. *Neurosurg Focus*. 1999;7(5):e5. doi:10.3171/foc.1999.7.5.8
23. Brusko GD, Wang MY. Endoscopic lumbar interbody fusion. *Neurosurg Clin N Am*. 2020;31(1):17–24. doi:10.1016/j.nec.2019.08.002
24. Xiong C, Li T, Kang H, et al. Early outcomes of 270-degree spinal canal decompression by using TESSYS-ISEE technique in patients with lumbar spinal stenosis combined with disk herniation. *Eur Spine J*. 2019;28(1):78–86. doi:10.1007/s00586-018-5655-4.
25. Wang MY, Grossman J. Endoscopic minimally invasive transforaminal interbody fusion without general anesthesia: initial clinical experience with 1-year follow-up. *Neurosurg Focus*. 2016;40(2):E13. doi:10.3171/2015.11.FOCUS15435
26. Wu P, Kim H, Lee Y, et al. Uniportal full endoscopic posterolateral transforaminal lumbar interbody fusion with endoscopic disc drilling preparation technique for symptomatic foraminal stenosis secondary to severe collapsed disc space: a clinical and Computer tomographic study with technical note. *Brain Sci*. 2020;10(6). doi:10.3390/brainsci10060373.
27. Zhang H, Zhou C, Wang C, et al. Percutaneous endoscopic transforaminal lumbar interbody fusion: technique note and comparison of early outcomes with minimally invasive transforaminal lumbar interbody fusion for lumbar spondylolisthesis. *Int J Gen Med*. 2021;14:549–558. doi:10.2147/IJGM.S298591
28. Kim CW, Doerr TM, Luna IY, et al. Minimally invasive transforaminal lumbar interbody fusion using expandable technology: a clinical and radiographic analysis of 50 patients. *World Neurosurgery*. 2016;90:228–235. doi:10.1016/j.wneu.2016.02.075
29. Gonzalez-Blohm SA, Doulgeris JJ, Aghayev K, et al. Biomechanical analysis of an interspinous fusion device as a stand-alone and as supplemental fixation to posterior expandable interbody cages in the lumbar spine. *J Neurosurg Spine*. 2014;20(2):209–219. doi:10.3171/2013.10.SPINE13612
30. Mantell M, Cyriac M, Haines CM, et al. Biomechanical analysis of an expandable lateral cage and a static transforaminal lumbar interbody fusion cage with posterior instrumentation in an in vitro spondylolisthesis model. *J Neurosurg Spine*. 2016;24(1):32–38. doi:10.3171/2015.4.SPINE14636
31. Armocida D, Pesce A, Proietti L, et al. Minimally invasive transforaminal lumbar interbody fusion (MIS-TLIF) using expandable cages: increased risk of late post-operative subsidence without a real improve of perioperative outcomes. A clinical mono-centric study. *World Neurosurg*. 2021;04:e1–e7.

The Journal of Pain Research is an international, peer reviewed, open access, online journal that welcomes laboratory and clinical findings in the fields of pain research and the prevention and management of pain. Original research, reviews, symposium reports, hypothesis formation and commentaries are all considered for publication. The manuscript

management system is completely online and includes a very quick and fair peer-review system, which is all easy to use. Visit <http://www.dovepress.com/testimonials.php> to read real quotes from published authors.