

## Reviews

# The Neuropsychiatry of Hyperkinetic Movement Disorders: Insights from Neuroimaging into the Neural Circuit Bases of Dysfunction

Bradleigh D. Hayhow<sup>1,2</sup>, Islam Hassan<sup>1</sup>, Jeffrey C. L. Looi<sup>3</sup>, Francesco Gaillard<sup>4</sup>, Dennis Velakoulis<sup>1,2</sup> & Mark Walterfang<sup>1,2\*</sup>

<sup>1</sup> Neuropsychiatry Unit, Royal Melbourne Hospital, Parkville, Australia, <sup>2</sup> Melbourne Neuropsychiatry Centre, University of Melbourne and Melbourne Health, Parkville, Australia, <sup>3</sup> Academic Unit of Psychiatry & Addiction Medicine, Australian National University Medical School, Canberra Hospital, Canberra, Australia, <sup>4</sup> Department of Radiology, Royal Melbourne Hospital, Parkville, Australia

## Abstract

**Background:** Movement disorders, particularly those associated with basal ganglia disease, have a high rate of comorbid neuropsychiatric illness.

**Methods:** We consider the pathophysiological basis of the comorbidity between movement disorders and neuropsychiatric illness by 1) reviewing the epidemiology of neuropsychiatric illness in a range of hyperkinetic movement disorders, and 2) correlating findings to evidence from studies that have utilized modern neuroimaging techniques to investigate these disorders. In addition to diseases classically associated with basal ganglia pathology, such as Huntington disease, Wilson disease, the neuroacanthocytoses, and diseases of brain iron accumulation, we include diseases associated with pathology of subcortical white matter tracts, brain stem nuclei, and the cerebellum, such as metachromatic leukodystrophy, dentatorubropallidolusian atrophy, and the spinocerebellar ataxias.

**Conclusions:** Neuropsychiatric symptoms are integral to a thorough phenomenological account of hyperkinetic movement disorders. Drawing on modern theories of cortico-subcortical circuits, we argue that these disorders can be conceptualized as disorders of complex subcortical networks with distinct functional architectures. Damage to any component of these complex information-processing networks can have variable and often profound consequences for the function of more remote neural structures, creating a diverse but nonetheless rational pattern of clinical symptomatology.

**Keywords:** Movement disorders, neuroimaging, psychopathology, frontostriatal

**Citation:** Hayhow BD, Hassan I, Looi JCL, et al. The neuropsychiatry of hyperkinetic movement disorders: insights from neuroimaging into the neural circuit bases of dysfunction. *Tremor Other Hyperkinet Mov* 2013; 3: <http://tremorjournal.org/article/view/175>

\*To whom correspondence should be addressed. E-mail: [mark.walterfang@mh.org.au](mailto:mark.walterfang@mh.org.au)

**Editor:** Elan D. Louis, Columbia University, United States of America

**Received:** April 17, 2013 **Accepted:** July 8, 2013 **Published:** August 26, 2013

**Copyright:** © 2013 Hayhow et al. This is an open-access article distributed under the terms of the Creative Commons Attribution–Noncommercial–No Derivatives License, which permits the user to copy, distribute, and transmit the work provided that the original author(s) and source are credited; that no commercial use is made of the work; and that the work is not altered or transformed.

**Funding:** None.

**Conflict of interest:** Dr. Gaillard is founder, CEO and Editor of Radiopaedia.org, a collaborative online radiology resource.

**Financial disclosures:** Dr. Velakoulis has received royalties from the publication of Kaplan and Sadock's *Comprehensive Textbook of Psychiatry* (Lippincott Williams & Wilkins, 2009) and receives research support from NHMRC. Dr. Walterfang has served on a scientific advisory board and as a consultant for and received funding for travel from Actelion Pharmaceuticals Ltd; and received royalties from the publication of Kaplan and Sadock's *Comprehensive Textbook of Psychiatry* (Lippincott Williams & Wilkins, 2009).

## Introduction

Movement disorders, particularly those associated with basal ganglia disease, have a high rate of comorbid neuropsychiatric illness.<sup>1</sup> An early recognition of this fact can be found in Huntington's classic description of hereditary chorea, in which he noted "a tendency to insanity and suicide" to be one of the "marked peculiarities" of the disease.<sup>2</sup> Following his lead, McHugh described a triadic syndrome of "dyskinesia, dementia, and depression" in basal ganglia disorders, drawing on examples from Huntington disease (HD) and Parkinson disease in particular.<sup>3</sup> Citing the seminal work of Alexander et al,<sup>4</sup> McHugh went on to propose that damage

to anatomically parallel but functionally distinct neural loops within the basal ganglia was responsible for the diverse manifestations of his syndrome. While aspects of McHugh's remain pertinent today, our understanding of the biology of neuropsychiatric illness in movement disorders has advanced considerably in recent decades.<sup>5–12</sup> This has been facilitated in part by developments in structural and functional neuroimaging techniques, especially in the field of magnetic resonance imaging (MRI) and positron emission tomography (PET).

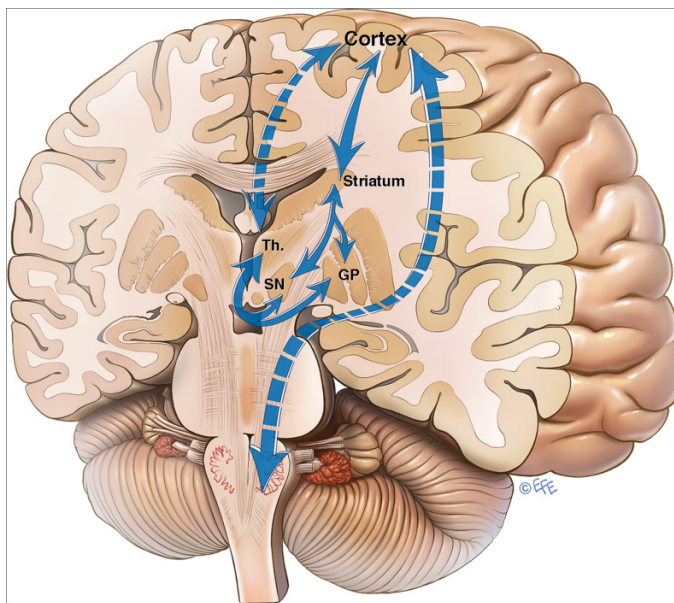
This paper draws on neuroimaging research specifically in relation to hyperkinetic movement disorders, which, in their diversity, offer the

opportunity to refine and extend McHugh’s ideas. We argue that what unifies these disorders in terms of their common relationship to a range of cognitive, emotional, and behavioral symptoms lies in altered structure and function in subcortical loops and circuits with which basal ganglia structures are often, but not always, associated. The core neuropsychiatric syndromes of some of these disorders, such as HD and the neuroacanthocytoses for instance, are very likely to involve dysfunctional cortico-striatal circuits (Figure 1);<sup>11,13</sup> other disorders, such as dentatorubropallidoluysian atrophy (DRPLA) and the spinocerebellar ataxias (SCAs), may involve additional dysfunction within cortico-spinal and cortico-cerebellar circuits (Figure 2).<sup>10,12,14</sup>

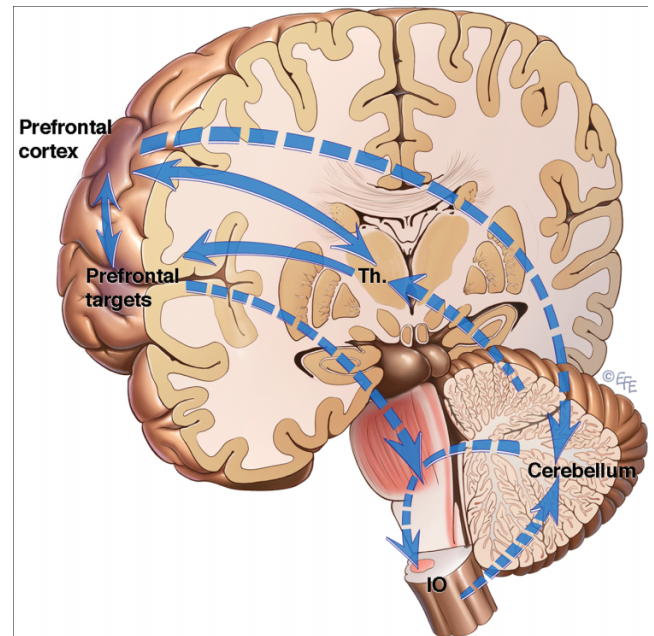
Our revised model synthesizes McHugh’s observations with modern pathophysiologic theories of cortico-subcortical circuits<sup>7-12</sup> and finds support in a number of studies correlating structural and functional neuroimaging with the variable neuropsychiatric comorbidity of the hyperkinetic disorders. We argue that our approach provides novel explanations as to why certain psychiatric syndromes are more common in certain diseases, and may in fact offer a framework within which to hypothesize about the frequent comorbidity of psychiatric symptoms in other neurological disorders.

### Huntington disease

HD (Online Mendelian Inheritance in Man 613004) is an inherited autosomal dominant condition defined by a pathological trinucleotide repeat affecting the huntingtin (*HTT*) gene on the short arm of chromosome 4. Its prevalence is estimated to fall between 4.1 and 7.5 per 100,000.<sup>15</sup> The clinical onset of the disease is generally accepted as the manifestation of motor symptoms. This commonly occurs in the fourth or fifth decade, with an inverse correlation between age of onset



**Figure 1. Prototypical frontal cortico-striatal circuit.** Bidirectional arrows: pathways with both afferent and efferent connections. Dotted lines: notional connections. Solid lines: literal connections. Th: Thalamus. SN: Substantia nigra. GP: Globus pallidus. Striatum: caudate nucleus and putamen.



**Figure 2. Prototypical cortico-cerebellar circuit.** Bidirectional arrows: pathways with both afferent and efferent connections. Dotted lines: notional connections. Solid lines: literal connections. Th: Thalamus. IO: Inferior olive. and number of pathological trinucleotide repeats on the largest expanded allele.<sup>16</sup>

Neuropsychiatric symptoms have long been associated with HD.<sup>2</sup> Depression appears to be the most common psychiatric comorbidity, with estimates of prevalence ranging from 33% to 69% of patients.<sup>17</sup> This stands in contrast to the estimated lifetime prevalence of depression in the general population of about 16.5%.<sup>18</sup> While one study found the rate of suicide to be up to eight times higher than that of the general population in HD patients over the age of 50,<sup>19</sup> a more recent finding is that depressive symptoms decline with illness stage,<sup>20</sup> a discrepancy that may be due to supervening of depressive symptoms by cognitive impairment in the later stages of the illness. Mania and psychosis are less common in HD, with estimates of prevalence ranging from 3–12% and 5–10%, respectively,<sup>21</sup> which still stands in contrast to the estimated lifetime prevalence of up to 1% and 3%, respectively, in the general population.<sup>22,23</sup> Patients with an earlier age of HD onset are at greater risk of psychosis.<sup>24</sup> Formal cases of obsessive compulsive disorder (OCD) have rarely been reported, against a background prevalence of around 1.6% in the general population.<sup>18</sup> Nevertheless, in one large study nearly one-quarter of patients presenting to a specialist clinic for the first time demonstrated obsessive or compulsive symptoms.<sup>25</sup> Obsessive and compulsive symptoms have also been associated with increasing stage of illness<sup>26</sup> and greater executive dysfunction.<sup>27</sup>

The classic neuroimaging finding in HD is atrophy of the caudate and putamen with concomitant alterations in the ratios of frontal horn to intercaudate distance and intercaudate to inner table distance.<sup>28,29</sup> This gives the frontal horns of the lateral ventricles a characteristically rounded or box-like appearance. T2-weighted MRI signal may also be

increased throughout the caudate, putamen, and globus pallidus due to gliosis and iron deposition.<sup>30</sup>

Several studies have used diffusion tensor imaging (DTI) to investigate changes in white matter connectivity in both patients and presymptomatic carriers of HD. Most studies have demonstrated disruption of multiple cortical and subcortical white matter tracts in patients and carriers alike, with robust correlations with stage of illness and selective cognitive and motor impairments.<sup>31–33</sup> The origin of the changes lies in neuronal destruction in specific regions of the caudate and putamen.<sup>34,35</sup>

HD patients with depression have also been shown to exhibit hypometabolism in orbitofrontal and inferior prefrontal cortex on fluorodeoxyglucose (FDG)-PET compared with HD patients without depression.<sup>36</sup> These changes are associated with subcortical but not cortical gray matter volume loss, suggesting that cortical functional changes may arise secondary to subcortical structural changes.

We conclude that disruption to cortico-striatal circuits plays an important role, not just in the motor manifestations of HD but also in the cognitive and behavioral manifestations of the illness.<sup>13,37</sup>

### Neuroacanthocytoses

The neuroacanthocytoses are a group of disorders characterized by neuropsychiatric symptoms associated with spiculated red blood cells in the peripheral circulation. While genetically diverse, the neuroacanthocytoses include such disorders as chorea acanthocytosis (ChAc), McLeod syndrome (MLS), and Huntington disease-like 2 (HDL2), each of which will be considered below.

#### Chorea acanthocytosis

ChAc (OMIM 200150) is a rare autosomal recessive disorder caused by mutations in the *VPS13A* gene on chromosome 9q coding for the membrane protein chorein.<sup>38,39</sup> As in HD, ChAc causes neuronal pathology that is most evident in the caudate and putamen, but can also be seen in the ventrolateral substantia nigra and globus pallidus.<sup>40</sup> The clinical onset of the disease is usually between the ages of 25 and 45 years.

The majority of ChAc patients experience neuropsychiatric symptoms<sup>40,41</sup> and these may precede overt neurological illness by more than a decade.<sup>42,43</sup> The most common psychiatric problem in ChAc is OCD, which affects more than 50% of patients.<sup>43,44</sup> A similar proportion of ChAc patients develop a dysexecutive cognitive syndrome, ultimately leading to a frontal-subcortical dementia with associated impairments in memory and speed of processing.<sup>40,43,45</sup> Schizophrenia-like psychosis is relatively uncommon, but a small number of cases have been reported.<sup>46</sup>

Neuroimaging findings in ChAc typically include progressive and marked atrophy of the caudate and putamen with a predilection for the caudate head.<sup>47</sup> On MRI there may be increased T2-signal in the dorsal striatum<sup>48</sup> and some researchers have observed cerebellar atrophy<sup>49–51</sup> and white matter changes involving the corpus callosum.<sup>50</sup> We note the cerebellar and changes with special interest, given the potential role of cortico-cerebellar dysfunction in executive cognitive impairment,<sup>10</sup> which features prominently in this disease.

In a study of two 33-year-old monozygotic twins, accentuated right hemispheric changes on MRI, FDG-PET and [(123)I]beta-(2beta-carbomethoxy-3beta-(4-iodophenyl)tropane) Single Photon Emission Computed Tomography correlated with more severe hyperkinetic movements on the left.<sup>52</sup> In twin 1, who was initially misdiagnosed with schizophrenia, a significant difference in binding to presynaptic dopamine transporters with marked reduction on the right was also observed. The researchers proposed loss of caudate neurons may thus predispose to psychosis due to the deleterious effect on both up- and downstream information processing within adjacent frontostriatal and striatolimbic pathways previously implicated in schizophrenia.<sup>53</sup> A similar mechanism may account for the prevalence of OCD in ChAc given the established link between obsessive-compulsive and dysexecutive symptoms and impairments in the lateral orbitofrontal loop primarily centered on the caudate.<sup>54</sup>

#### McLeod syndrome

MLS (OMIM 300842) is an X-linked genetic disorder characterized by weakly expressed or absent Kell red blood cell antigens, acanthocytosis, and elevated creatine kinase levels. It is caused by mutations in the *XK* gene and mainly affects males, although female carriers can show mild symptoms.<sup>55</sup> Clinical onset is usually between the ages of 25 and 60 years, and up to 80% of patients demonstrate neuropsychiatric comorbidity at some stage of their illness.<sup>56,57</sup> Like ChAc, the neuronal loss associated with MLS predominantly affects the caudate and putamen,<sup>40,58,59</sup> and neuropsychiatric symptoms not uncommonly predate the neurological manifestations of the illness.<sup>56,60</sup>

Executive dysfunction is common in MLS and has also been described in female carriers.<sup>57</sup> A high prevalence of OCD-like syndromes has been reported by a number of authors.<sup>61–64</sup> Psychotic disorders may be just as frequent, with cases of schizophrenia-like illnesses being reported in which typical psychotic symptoms have preceded the onset of chorea.<sup>56,63,65</sup>

Marked caudate atrophy and increased T2 signal in the lateral putamen are common MRI findings in MLS.<sup>57,61,66,67</sup> Reduced striatal D<sub>2</sub> binding has been reported in PET studies<sup>67,68</sup> along with hypometabolism of the basal ganglia and frontal lobes<sup>66</sup> and altered *N*-acetylaspartate to creatine/choline ratios in the frontal and medial temporal cortex and thalamus.<sup>69</sup> The absence of cortical neuronal loss on limited neuropathological studies<sup>59</sup> is reminiscent of HD, and again suggests that functional cortical abnormalities are secondary to striatal neuron loss, presumably via the loss of mediating cortico-striatal pathways.

#### Huntington disease-like 2

HDL2 (OMIM 606438) is an autosomal dominant disease caused by a CTG expansion in the junctophilin-3 gene (*JPH3*) on chromosome 16q24.3.<sup>70,71</sup> It is only found in patients of black African ancestry.<sup>70</sup>

Only a small number of HDL2 cases with comorbid neuropsychiatric illness have been reported in the literature, but they are notable for



the heterogeneity of associated symptoms, including depression, anxiety, and psychosis, in addition to a frontal-dysexecutive syndrome leading to dementia.<sup>72–75</sup> While neuropsychiatric comorbidity appears to be the rule rather than the exception in HDL2, it may differ from the other neuroacanthocytoses in that neuropsychiatric symptoms seem to be reported only after the onset of neurological illness.

In common with the other neuroacanthocytoses, neuroimaging reveals significant atrophy of both the caudate and the putamen, and to a lesser extent the substantia nigra and pallidum.<sup>71,76</sup> The association of deep structural brain changes with such a broad range psychiatric symptomatology again illustrates the critical role of corticostriatal circuits in the behavioral manifestations of the illness.

### Wilson disease

Wilson disease (WD—OMIM 277900) is an autosomal recessive disorder characterized by a mutation in the *ATP7B* gene coding for a copper transport protein, leading to copper deposition in multiple organ systems. In the central nervous system (CNS), it particularly affects the putamen and pallidum.<sup>77</sup> While the initial presentation of WD may be hepatic, neurological, or psychiatric, about half of all patients have neuropsychiatric symptoms at a given time.<sup>78</sup>

Affective disorders appear to be the most common neuropsychiatric illnesses in WD<sup>79–81</sup> and often meet the criteria for bipolar disorder.<sup>82</sup> Personality changes characterized by irritability and aggression are also very common.<sup>81</sup> While neurologically asymptomatic patients rarely show cognitive deficits,<sup>83</sup> those with neurological disease often display a range of difficulties, including impairments of executive function, memory, and visuospatial processing.<sup>78,84,85</sup> Psychosis is relatively uncommon<sup>81,86</sup> although cases of delusional disorder have been reported.<sup>87,88</sup> OCD has only been reported only once in association with WD,<sup>89</sup> which is surprising given the high rate of OCD in other basal ganglia disorders, but may be hypothesized to reflect some sparing of the caudate relative to illness such as HD and ChAc.

About half of patients with WD demonstrate basal ganglia hypodensity on computed tomography (CT)<sup>90</sup> and virtually all show abnormalities on MRI.<sup>91</sup> Characteristic features may include T2 hyperintensities within the lenticular nuclei, ventrolateral thalamus, and hypothalamus, probably due to the paramagnetic effect of copper and iron deposition within these structures.<sup>92</sup> T2 hyperintensities in the tegmentum often spare the red nuclei and medial margins of the parts reticulata and superior colliculi, giving rise to the so-called “face of the giant panda” sign.<sup>93</sup>

FDG-PET typically shows hypometabolism in the lenticular nuclei,<sup>94</sup> and in one study 19 of 25 patients examined by <sup>99m</sup>Tc-ethyl-cysteinate dimer (ECD) SPECT exhibited diffuse or focal hypoperfusion affecting the superior frontal, prefrontal, parietal, and occipital cortices, the temporal gyri, caudate, and putamen.<sup>95</sup> The fact that the primary pathology associated with this disease is to be found in the basal ganglia once again suggests that proximal damage to components of cortico-subcortical circuits may have profound effects on distal brain function, such as cognition and emotion.

### Neurodegeneration with brain iron accumulation

Neurodegeneration with brain iron accumulation (NBIA) encompasses a group of genetically diverse disorders characterized by neuronal death secondary to brain iron deposition. In the adult population, NBIA includes pantothenate kinase-associated neurodegeneration, aceruloplasminemia, and neuroferritinopathy.

#### Pantothenate kinase-associated neurodegeneration

Pantothenate kinase-associated neurodegeneration (PKAN—OMIM 234200) is a rare autosomal recessive disorder caused by mutations in the *PANK2* gene. There are two main phenotypes. In its classic form, PKAN is characterized by a severe and rapidly progressive hyperkinetic movement disorder with an onset in the first decade leading to complete loss of ambulation. A second, atypical form exists that is characterized by a less severe and less rapidly progressive movement disorder with an onset in the second to third decade.<sup>96</sup> Both phenotypes are associated with additional neurological symptoms including dysarthria, dystonia, and cortico-spinal abnormalities.<sup>96</sup>

Cognitive decline is common in PKAN and tends to affect earlier-onset patients more severely.<sup>97</sup> It is not uncommon for cognitive symptoms to predate motor signs<sup>98</sup> and a pattern of impaired attention and executive function is characteristic.<sup>99</sup> Up to half of all patients experience psychiatric problems, which include behavioral disturbances,<sup>96</sup> OCD,<sup>100,101</sup> tic disorders,<sup>102</sup> psychosis,<sup>103</sup> and depression.<sup>104</sup>

The neuroradiological hallmark of PKAN is the so-called “eye of the tiger sign”, which is characterized by bilateral areas of hyperintensity within a region of hypointensity in the medial globus pallidus on T2-weighted MRI.<sup>105</sup> The low signal intensity is said to result from excessive iron accumulation,<sup>106</sup> with the central high signal being attributed to gliosis and cavitation resulting in increased water content.<sup>107</sup> It is important to note that the sign is not specific to PKAN: it can also be seen in other neurodegenerative disorders such as cortico-basal ganglionic degeneration,<sup>108</sup> progressive supranuclear palsy,<sup>109</sup> and neuroferritinopathy.<sup>107,110</sup>

In terms of functional imaging, a <sup>99m</sup>Tc-ECD SPECT study has described regional hypoperfusion of the bilateral frontoparietal lobes, lenticular nuclei, and ventriculus quartus in two siblings with adult-onset disease and an identical *PANK2* mutation.<sup>111</sup> The cortical metabolic findings are of particular interest given that PKAN is classically defined by its subcortical pathology, which again suggests that diaschisis via cortico-subcortical circuits plays an important role in the genesis of clinical neuropsychiatric symptoms.

#### Aceruloplasminemia

Aceruloplasminemia (AC—OMIM 604290) is a rare autosomal recessive disorder characterized by mutation in the ceruloplasmin (*CP*) gene leading to iron deposition in multiple tissues due to impaired ceruloplasmin ferroxidase activity.<sup>112,113</sup> The major sites of CNS iron deposition include the basal ganglia, cerebellar dentate nuclei, red nucleus, thalamus, and hippocampus.<sup>114</sup> AC occurs in just 1:2 million non-consanguineous births and usually presents in the fifth or sixth decade.<sup>115</sup>

About half of all patients with AC present with cognitive impairment<sup>116</sup> and most progress to develop a subcortical dementia characterized by executive dysfunction and cognitive slowing associated with frontal hypometabolism.<sup>114,117,118</sup> Only one case of major psychiatric illness associated with AC has been reported, in the form of a typical schizophreniform psychosis.<sup>118</sup>

MRI typically demonstrates marked T2 hypointensity corresponding to regions of pathological iron deposition including those noted above<sup>119–121</sup> and can be used to quantify iron accumulation in vivo.<sup>122</sup> Subtle hyperintensities of posterior white matter tracts have also been reported, and subtle superficial cerebral and cerebellar cortical hypointensities may be detectable when sequences sensitive to the magnetic susceptibility effects of iron are used.<sup>121</sup>

Given the characteristic distribution of iron deposition in AC, the primarily dysexecutive cognitive syndrome associated with the illness may be the result of impairment to both cortico-striatal and cortico-cerebellar circuits at the subcortical level.<sup>117</sup>

### Neuroferritinopathy

Neuroferritinopathy (NF—OMIM 606159) is a rare autosomal dominant disorder characterized by mutations in the ferritin light chain (*FTL*) gene. Patients commonly present in the fourth to sixth decade with features of chorea (50%), dystonia (42.5%), or Parkinsonism (7.5%).<sup>123</sup> As with the other NBIA syndromes, the globus pallidus is a common focus of iron deposition.<sup>124</sup>

In the small number of cases described, dementia and psychosis have been the most common neuropsychiatric comorbidities. While patients are generally said to have intact cognition until late in the disorder,<sup>125</sup> disinhibition and emotional lability may be the early symptoms of a dysexecutive cognitive syndrome typically leading to a frontosubcortical dementia.<sup>126,127</sup> In one pedigree, akinetic mutism was an additional late manifestation.<sup>128</sup> Psychosis has also been associated with NF: ataxia, rigidity-bradykinesia and neuroleptic-responsive psychosis was reported in an adolescent patient with a family history of schizophrenia,<sup>129</sup> while another patient who presented with severe generalized dystonia at the age of 22 years later developed delusional jealousy.<sup>130</sup>

MRI typically demonstrates iron deposition and cavitation in the basal ganglia with a characteristic loss of T2 signal. The red nucleus and substantia nigra appear to be the first structures affected, with subsequent involvement of the dentate nucleus, putamen, globus pallidus, thalamus, caudate nucleus, and prefrontal cortex.<sup>126</sup> Increasing R2\* (the inverse of T2\*) signal appears to correlate with increasing severity of dystonia, and may be a clinically useful method of tracking disease progression.<sup>131</sup> Although functional imaging studies are yet to be conducted, the anatomical distribution of injuries on structural MRI would be expected to result in abnormalities in cortico-striatal and cortico-cerebellar circuits, potentially correlating with the predisposition of NF patients to psychosis and dementia.

### Dentatorubropallidolusian atrophy

Dentatorubropallidolusian atrophy (DRPLA—OMIM 125370) is a rare genetic disorder caused by a triplet repeat expansion of the

atrophy gene (*ATN-1*) on chromosome 12p13.31.<sup>132</sup> It is most prevalent in Asian pedigrees, and a review of cases within the Japanese literature found psychosis to be the most common psychiatric comorbidity, affecting about 10% of patients.<sup>133</sup>

Serial neuroimaging findings were reported in a Caucasian man who was first scanned at the age of 38 years with a history of seizures, tremor, ataxia, and dysarthria.<sup>134</sup> Interval imaging showed progressive atrophy of cerebellum and brainstem, with GRE and SWI sequences demonstrating marked susceptibility effect throughout the cerebellar hemispheres, vermis, and dentate nuclei. T2-weighted signal abnormalities have also been documented in both the subcortical white matter and brainstem white matter tracts in DRPLA.<sup>135,136</sup> A neuroradiological–pathological study of a father and son demonstrated signal intensity changes in white matter were due to a marked loss of myelinated fibers, while gray matter changes were largely due to a loss of neuropil.<sup>137</sup> Given the strong evidence that alterations to myelinated fibers underpin psychotic symptoms in schizophrenia,<sup>138–140</sup> it is not surprising that psychosis is a common psychiatric comorbidity in this group. It is difficult to explain why the degenerative changes of the cerebellum and brainstem have not been associated with cognitive symptoms, except to hypothesize that the potential link may not yet have been investigated.

### Spinocerebellar ataxias

The SCAs are a large family of autosomal dominant neurodegenerative disorders associated with subcortical dementia syndromes,<sup>141–144</sup> depression, and personality change.<sup>145</sup>

Neuroimaging studies have mainly focused on SCAs 1 (OMIM 164400), 2 (OMIM 183090), 3 (OMIM 109150), 6 (OMIM 183086), and 17 (OMIM 607136), and typically reveal one of three patterns of atrophy: spinal atrophy (SA), olivopontocerebellar atrophy (OPCA), and cortico-cerebellar atrophy (CCA).<sup>146</sup> OPCA is typical of SCA 1, 2, and 3 and is characterized by diffuse T2 and proton density signal changes in the pons, middle cerebellar peduncle, and cerebellum in association with atrophy of the cerebellum, brainstem, and cervical spinal cord.<sup>147</sup> CCA is associated with SCA 6 and 7, and MRI typically shows atrophy of the cerebellar folia without signal change, while the brainstem and spinal cord volume is preserved.<sup>148</sup> A finding that is believed to be specific to SCA3 is linear T2-hyperintensity along the medial margin of the globus pallidus interna, and may be due to degeneration of the lenticular fasciculus.<sup>149</sup>

In MRI studies using diffusion-weighted and diffusion tensor imaging, both diffusivity and fractional anisotropy (FA) in the brainstem and cerebellum was found to be decreased relative to controls in SCA 1 and 2.<sup>150,151</sup> Decreased FA may be more robustly correlated with clinical severity in SCA 1 than measures of atrophy using conventional MRI.<sup>152</sup>

One voxel-based morphometry study of SCA2 patients correlated patterns of executive dysfunction with atrophy of the posterior cerebellum, and coordinative dysfunction with atrophy of the anterior cerebellum.<sup>153</sup> Another study demonstrated a similar dissociation of cognitive and motor functions in SCA17, as well as an inverse

relationship between CAG repeat length and the rate of disease progression.<sup>154</sup>

Both symptomatic and presymptomatic SCA-17 subjects imaged with MRI and PET demonstrated atrophy of the cerebellum and caudate nucleus and decreased glucose metabolism in the striatum, cuneus, cingulum, and parietal lobes. In addition, PET was closely correlated with both motor and cognitive performance as assessed by the Scale for the Assessment and Rating of Ataxia, Unified Parkinsons Disease Rating Scale, and Mini-Mental State Examination.<sup>11</sup> C-raclopride PET showed postsynaptic dopaminergic dysfunction within the putamen and caudate nucleus that correlated with impairment of motor performance.<sup>155</sup>

Taken together, the neuroimaging findings in a range of SCAs would appear to support the hypothesis that the cortical dysfunction associated with these disorders once again arises from a syndrome of cortico-subcortical and cortico-cerebellar disconnection. That damage to the cerebellum should so robustly translate into impairments of higher cortical functions<sup>14,156</sup> suggests that disrupted cortico-cerebellar circuitry, in addition to the disrupted cortico-striatal and thalamo-cortical circuitry, plays an important role in the genesis of neuropsychiatric symptoms in these conditions.

### Metachromatic leukodystrophy

Metachromatic leukodystrophy (MLD—OMIM 250100) is a severe neurodegenerative metabolic disorder, also classified as a lysosomal storage disorder. It is caused by deficient activity of arylsulfatase A (ARSA) leading to accumulation of glycosphingolipid sulfatide and progressive demyelination in the central and peripheral nervous system.<sup>157</sup> MLD is both genetically and phenotypically heterogeneous, with a variable age of onset.<sup>158</sup>

Some MLD mutations are associated with predominant motor presentations, others with cognitive and psychiatric features. Adult homozygotes for *p.P426L* tended to present with gait disturbances followed by choreoathetotic movements, dysphagia, dysarthria, tremor, and nystagmus, whereas carriers of the less common *p.II79S* mutation present primarily with psychosis.<sup>159</sup> The cognitive changes of MLD may resemble those of a generalized Alzheimer's dementia, with features that include amnesia, visuospatial dysfunction, attentional deficits, and slowed processing speed.<sup>160–162</sup>

MLD is typically associated with the distinctive imaging findings of diffuse periventricular and subcortical white matter hyperintensities sparing subcortical U-fibers on T2-weighted MRI.<sup>163</sup> The pattern of white matter involvement is also characteristic with linear or punctuate high signal radiating in the demyelinated white matter, sparing the perivascular white matter, resembling “tigroid” or “leopard-skin”.<sup>164</sup>

An increase in white matter myo-inositol on magnetic resonance spectroscopy (MRS) supports demyelination in the pathophysiology of MLD.<sup>165</sup> A large case review has previously hypothesized that the heavy burden of white matter disease in MLD, which particularly affects the subfrontal white matter, may account for the unusually high prevalence of psychosis in this disorder via disruptions to both frontotemporal cortico-cortical and cortico-striatal circuitry.<sup>166</sup>

### Niemann–Pick disease type C

Niemann–Pick disease type C (NPC—OMIM C1 257220, C2 607625) is a progressive neurodegenerative disorder caused by disrupted intracellular sterol trafficking. Most cases are associated with disruption of the NPC1 gene on 18q11,<sup>167</sup> but around 5% are associated with disruption of the NPC2 gene on 14q24.2.<sup>168</sup> The clinical manifestations of the disease are highly heterogeneous and may appear any time between birth and late adulthood,<sup>169</sup> although adult patients typically present with ataxia, dystonia, chorea, vertical gaze palsy, impaired cognition, and psychiatric illness.<sup>170</sup>

Psychosis is the most common psychiatric presenting complaint among adult NPC patients.<sup>169,171</sup> Presentations of depression, bipolar affective syndromes and OCD have also been reported.<sup>172,173</sup> While up to 38% of NPC patients will first present with a psychiatric syndrome, psychiatric sequelae—other than those associated with dementia—in patients who first present with neurological symptoms is regarded as rare.<sup>169</sup>

In one study of six adult NPC patients, VBM demonstrated gray matter reductions particularly affecting the hippocampus, thalamus, superior cerebellum, and striatum, regions where ganglioside accumulation is greatest.<sup>170</sup> On DTI, widespread reductions in fractional anisotropy in major white matter tracts were also observed, with subanalyses suggesting pathological contributions from both impaired myelination and altered axonal structure. Other volumetric studies of NPC patients have demonstrated reduced callosal area and thickness<sup>174</sup> and increased pontine-to-midbrain ratio<sup>175</sup> in correlation with duration of illness, symptom score, and aspects of saccadic dysfunction; and reduced left hippocampal volume in correlation with symptom score and cognitive dysfunction.<sup>176</sup> An FDG-PET study of two monozygotic children over a 2-year period demonstrated diffuse cortical hypometabolism initially in the medial frontal cortex that progressed to severe bilateral hypometabolism of frontal, parietal, and temporal cortices.<sup>177</sup>

These structural and functional imaging studies in NPC provide a compelling model of disrupted cortico-cortical connectivity due to diffuse and extensive white matter changes, and cortico-subcortical and cortico-cerebellar disconnectivity secondary to direct gray matter disruption in these key relay zones.

### Discussion

While hyperkinetic movement disorders are heterogeneous in terms of both their neuropathology and neuropsychiatric comorbidity, observations from neuroimaging studies suggest they share some common neural circuit bases in association with complex forms of cognitive, emotional, and behavioral dysfunction. By synthesizing a modern model comprising cortico-striatal-pallido-thalamic and cortico-cerebellar circuits<sup>7–12</sup> with that of McHugh, we argue that damage to certain strategic components of these circuits provides unifying explanation for the apparently disparate functional manifestations of these disorders. The argument proceeds as follows:

Firstly, several neuropsychiatric syndromes are especially prevalent across hyperkinetic movement disorders: executive dysfunction and

subcortical dementia, affective disorders including OCD, and psychotic disorders including schizophrenia-like syndromes. Many of these neuropsychiatric disorders have been independently associated with particular patterns of cortical dysfunction and dysfunction ascribed to particular cortico-subcortical circuits. For instance, it appears that early damage to the striatum strongly predisposes to OCD.<sup>54</sup> The caudate in particular is recognized as a point of origin for the lateral orbitofrontal loop, and OCD may arise as a consequence of alterations to the normal neurodevelopment of this circuit.<sup>43</sup> Cortico-striatal and striato-limbic circuits are similarly implicated in the pathophysiology of psychosis,<sup>178</sup> and cortico-cerebellar circuits in the cognitive abnormalities associated with schizophrenia.<sup>156,179</sup>

Secondly, almost all of the hyperkinetic movement disorders are associated with neuron loss in the basal ganglia, and some are also associated with neuron loss in subthalamic and cerebellar nuclei. These nuclei can be conceptualized as connective hubs or crossroads<sup>4</sup> for both higher and lower brain functions, and within particular cortico-subcortical circuits.

Thirdly, the limited functional imaging studies that exist in this area points towards a dissociation between changes in cortical volume and changes in cortical function,<sup>36</sup> suggesting that the cortical abnormalities associated with these disorders may, in some circumstances, arise secondarily to the loss of populations of subcortical neurons. Alterations to cortico-subcortical (Figure 1) and cortico-cerebellar (Figure 2) circuitry constitute a mechanism for diaschisis that is consistent with the manifestations of neuropsychiatric dysfunction observed.

While certain psychiatric syndromes may be more or less common in the hyperkinetic disorders, their heterogeneity also serves to provide some evidence of the involvement of cortico-subcortical circuitry: although the main circuits may be functionally distinct and subservise different motor, cognitive, and emotional behaviors,<sup>4</sup> they are not anatomically separate; rather, they are parallel loops connected by white matter tracts converging at certain strategic hubs, such as the striatum, pallidum, thalamus, and cerebellum.<sup>7–12</sup> Consequently, these circuits interact in the striatum and other hubs to modulate each other's output,<sup>180</sup> leading to symptoms across a broad range of domains. The strategic vulnerability of cortico-subcortical circuitry at multiple sites in the network may be a key factor in the pathophysiology of these disorders.<sup>181</sup>

In the case of the hyperkinetic disorders with pathology more strongly rooted in the basal ganglia (such as HD and the neuroacanthocytoses), there is persuasive clinical and neuroimaging evidence of remote functional pathology detectable at the level of both white matter tracts and cortex. On the other hand, disorders associated with primary white matter pathology, such as MLD, clearly exert a strong functional influence on their proximal gray matter connections. This paper also extends the model of cortico-subcortical dysfunction to include nuclei in the cerebellum and brainstem, with similar observations to be made for subthalamic diseases such as DRPLA and the SCAs. Finally, those diseases in which cortico-subcortical loops are affected very selectively (such as HD or MLD) appear to

demonstrate more robust associations to severe neuropsychiatric illness than those that are affected more diffusely (such as WD and NBIA).

McHugh proposed a triadic model of basal ganglia disorders characterized by symptoms of dyskinesia, dementia, and depression. His original hypothesis was that these disparate syndromes could be accommodated by virtue of shared anatomical pathology affecting functionally distinct subcortical loops. Our argument is that McHugh's acknowledgement of depression must be extended to include a broader range of psychiatric syndromes associated with the cognitive-emotional domains subserved by such circuits, and that his understanding of dyskinesia must be extended to include a broader range of motoric dysfunction

We would also like to suggest that a neurodevelopmental model may help scaffold an understanding of the relative preponderance of these conditions at different stages of illness. For instance, it is generally the case that disorders known to be associated with departures from a normal neurodevelopmental trajectory tend to present with early neuropsychiatric illness such as OCD and schizophreniform psychosis. The disruption to crucial late neurodevelopmental processes by young-onset neurodegenerative disorders may thus result in neuropsychiatric syndromes that would otherwise tend to present in adolescence or early adulthood.<sup>182</sup> In contrast, disorders that are associated with degeneration of the mature brain, and which result in cognitive decline or frank dementia, tend to be those which present later. One possible exception to this principle is the early appearance of executive dysfunction, which may be detectable in carriers and presymptomatic individuals long before the onset of clinical disease. Executive function may be a particularly cognitive vulnerable faculty given its phylogenetically more recent origin; this may also, however, reflect the rich interconnectedness between frontal cortex and subcortical gray matter, with disorders that either diffusely affect connecting structures or specifically impact basal ganglia structures showing a predilection for impairments in executive function.

In conclusion, we suggest that an expanded version of McHugh's model incorporating modern models of cortico-subcortical circuitry<sup>7–12</sup> can be extended beyond diseases of the basal ganglia to encompass a wide range of neurodegenerative disorders affecting cortico-subcortical loops. Damage to any part of these complex information-processing systems—including cortical grey matter, subcortical white matter, or subcortical gray matter nuclei—can have variable and often profound consequences for the function of more remote neural structures, creating a diverse but nonetheless rational pattern of clinical symptomatology.

### Acknowledgement

The authors wish to acknowledge the assistance of Levent Efe in the preparation of figure illustrations for this article.

### References

1. Lennox BR, Lennox GG. Mind and movement: the neuropsychiatry of movement disorders. *J Neurol Neurosurg, Psychiatry* 2002;72(Suppl 1):i28–i31.



2. Huntington G. On chorea. *Medical and Surgical Reporter (Philadelphia)* 1872; 26:317–321.
3. McHugh PR. The neuropsychiatry of basal ganglia disorders: a triadic syndrome and its explanation. *Neuropsychiatry Neuropsychol Behav Neurol* 1989;2: 239–247.
4. Alexander GE, DeLong MR, Strick PL. Parallel organization of functionally segregated circuits linking basal ganglia and cortex. *Annu Rev Neurosci* 1986;9:357–381, doi: <http://dx.doi.org/10.1146/annurev.ne.09.030186.002041>.
5. Rosenblatt A, Leroi I. Neuropsychiatry of Huntington's disease and other basal ganglia disorders. *Psychosomatics* 2000;41:24–30, doi: [http://dx.doi.org/10.1016/S0033-3182\(00\)71170-4](http://dx.doi.org/10.1016/S0033-3182(00)71170-4).
6. Starkstein SE, Brockman S, Hayhow BD. Psychiatric syndromes in Parkinson's disease. *Curr Opin Psychiatry* 2012;25:468–472, doi: <http://dx.doi.org/10.1097/YCO.0b013e3283577ed1>.
7. Mega MS, Cummings JL. Frontal-subcortical circuits and neuropsychiatric disorders. *J Neuropsychiatry Clin Neurosci* 1994;6:358–370.
8. Cummings JL. Anatomic and behavioral aspects of frontal-subcortical circuits. *Ann NY Acad Sci* 1995;769:1–13, doi: <http://dx.doi.org/10.1111/j.1749-6632.1995.tb38127.x>.
9. Tekin S, Cummings JL. Frontal-subcortical neuronal circuits and clinical neuropsychiatry: an update. *J Psychosom Res* 2002;53:647–654, doi: [http://dx.doi.org/10.1016/S0022-3999\(02\)00428-2](http://dx.doi.org/10.1016/S0022-3999(02)00428-2).
10. Ramnani N. The primate cortico-cerebellar system: anatomy and function. *Nat Rev Neurosci* 2006;7:511–522, doi: <http://dx.doi.org/10.1038/nrn1953>.
11. Walterfang M, Evans A, Looi JC, et al. The neuropsychiatry of neuroacanthocytosis syndromes. *Neurosci Biobehav Rev* 2011;35:1275–1283, doi: <http://dx.doi.org/10.1016/j.neubiorev.2011.01.001>.
12. Stoodley CJ, Valera EM, Schmahmann JD. Functional topography of the cerebellum for motor and cognitive tasks: an fMRI study. *NeuroImage* 2012; 59:1560–1570, doi: <http://dx.doi.org/10.1016/j.neuroimage.2011.08.065>.
13. Looi JC, Walterfang M. Striatal morphology as a biomarker in neurodegenerative disease. *Mol Psychiatry* 2013;18:417–424, doi: <http://dx.doi.org/10.1038/mp.2012.54>.
14. Schmahmann JD. Disorders of the cerebellum: ataxia, dysmetria of thought, and the cerebellar cognitive affective syndrome. *J Neuropsychiatry Clin Neurosci* 2004;16:367–378, doi: <http://dx.doi.org/10.1176/appi.neuropsych.16.3.367>.
15. Folstein SE, Chase GA, Wahl WE, McDonnell AM, Folstein MF. Huntington disease in Maryland: clinical aspects of racial variation. *Am J Hum Genet* 1987;41:168–179.
16. Lee JM, Ramos EM, Lee JH, et al. CAG repeat expansion in Huntington disease determines age at onset in a fully dominant fashion. *Neurology* 2012;78:690–695, doi: <http://dx.doi.org/10.1212/WNL.0b013e318249f683>.
17. van Duijn E, Kingma EM, van der Mast RC. Psychopathology in verified Huntington's disease gene carriers. *J Neuropsychiatry Clin Neurosci* 2007; 19:441–448, doi: <http://dx.doi.org/10.1176/appi.neuropsych.19.4.441>.
18. Kessler RC, Berglund P, Demler O, Jin R, Merikangas KR, Walters EE. Lifetime prevalence and age-of-onset distributions of DSM-IV disorders in the National Comorbidity Survey Replication. *Arch Gen Psychiatry* 2005;62:593–602, doi: <http://dx.doi.org/10.1001/archpsyc.62.6.593>.
19. Schoenfeld M, Myers RH, Cupples LA, Berkman B, Sax DS, Clark E. Increased rate of suicide among patients with Huntington's disease. *J Neurol Neurosurg Psychiatry* 1984;47:1283–1287, doi: <http://dx.doi.org/10.1136/jnnp.47.12.1283>.
20. Paulsen JS, Nehl C, Hoth KF, et al. Depression and stages of Huntington's disease. *J Neuropsychiatry Clin Neurosci* 2005;17:496–502, doi: <http://dx.doi.org/10.1176/appi.neuropsych.17.4.496>.
21. Mendez MF. Huntington's disease: update and review of neuropsychiatric aspects. *Int J Psychiatry Med* 1994;24:189–208, doi: <http://dx.doi.org/10.2190/HU6W-3K7Q-NAEL-XU6K>.
22. Merikangas KR, Akiskal HS, Angst J, et al. Lifetime and 12-month prevalence of bipolar spectrum disorder in the National Comorbidity Survey replication. *Arch Gen Psychiatry* 2007;64:543–552, doi: <http://dx.doi.org/10.1001/archpsyc.64.5.543>.
23. Perala J, Vuvisaari J, Saarni SI, et al. Lifetime prevalence of psychotic and bipolar I disorders in a general population. *Arch Gen Psychiatry* 2007;64:19–28, doi: <http://dx.doi.org/10.1001/archpsyc.64.1.19>.
24. Brooks DS, Murphy D, Janota I, Lishman WA. Early-onset Huntington's chorea. Diagnostic clues. *Br J Psychiatry* 1987;151:850–852, doi: <http://dx.doi.org/10.1192/bjp.151.6.850>.
25. Marder K, Zhao H, Myers RH, et al. Rate of functional decline in Huntington's disease. *Neurology* 2000;54:452–458. Erratum published in *Neurology* 2000;54:1712, doi: <http://dx.doi.org/10.1212/WNL.54.2.452>.
26. Beglinger LJ, Langbehn DR, Duff K, et al. Probability of obsessive and compulsive symptoms in Huntington's disease. *Biol Psychiatry* 2007;61:415–418, doi: <http://dx.doi.org/10.1016/j.biopsych.2006.04.034>.
27. Anderson KE, Louis ED, Stern Y, Marder KS. Cognitive correlates of obsessive and compulsive symptoms in Huntington's disease. *Am J Psychiatry* 2001;158:799–801, doi: <http://dx.doi.org/10.1176/appi.ajp.158.5.799>.
28. Simmons JT, Pastakia B, Chase TN, Shults CW. Magnetic resonance imaging in Huntington disease. *AJNR Am J Neuroradiol* 1986;7:25–28.
29. Aylward EH, Schwartz J, Machlin S, Pearlson G. Bicaudate ratio as a measure of caudate volume on MR images. *AJNR Am J Neuroradiol* 1991;12: 1217–1222.
30. Mirowitz SA, Sartor K, Prenskey AJ, Gado M, Hodges FJ, 3rd. Neurodegenerative diseases of childhood: MR and CT evaluation. *J Comput Assist Tomogr* 1991;15:210–222, doi: <http://dx.doi.org/10.1097/00004728-199103000-00005>.
31. Rosas HD, Tuch DS, Hevelone ND, et al. Diffusion tensor imaging in presymptomatic and early Huntington's disease: Selective white matter pathology and its relationship to clinical measures. *Mov Disord* 2006;21:1317–1325, doi: <http://dx.doi.org/10.1002/mds.20979>.
32. Della Nave R, Ginestroni A, Tessa C, et al. Regional distribution and clinical correlates of white matter structural damage in Huntington disease: a tract-based spatial statistics study. *AJNR Am J Neuroradiol* 2010;31:1675–1681, doi: <http://dx.doi.org/10.3174/ajnr.A2128>.
33. Dumas EM, van den Bogaard SJ, Ruber ME, et al. Early changes in white matter pathways of the sensorimotor cortex in premanifest Huntington's disease. *Hum Brain Mapp* 2012;33:203–212, doi: <http://dx.doi.org/10.1002/hbm.21205>.



34. Bohanna I, Georgiou-Karistianis N, Egan GF. Connectivity-based segmentation of the striatum in Huntington's disease: vulnerability of motor pathways. *Neurobiol Dis* 2011;42:475–481, doi: <http://dx.doi.org/10.1016/j.nbd.2011.02.010>.
35. Douaud G, Behrens TE, Poupon C, et al. In vivo evidence for the selective subcortical degeneration in Huntington's disease. *NeuroImage* 2009;46:958–966, doi: <http://dx.doi.org/10.1016/j.neuroimage.2009.03.044>.
36. Mayberg HS, Starkstein SE, Peyser CE, Brandt J, Dannals RF, Folstein SE. Paralimbic frontal lobe hypometabolism in depression associated with Huntington's disease. *Neurology* 1992;42:1791–1797, doi: <http://dx.doi.org/10.1212/WNL.42.9.1791>.
37. Vonsattel JP, DiFiglia M. Huntington disease. *J Neuropathol Exp Neurol* 1998;57:369–384, doi: <http://dx.doi.org/10.1097/00005072-199805000-00001>.
38. Rampoldi L, Danek A, Monaco AP. Clinical features and molecular bases of neuroacanthocytosis. *Jl Mol Med* 2002;80:475–491, doi: <http://dx.doi.org/10.1007/s00109-002-0349-z>.
39. Ueno S, Maruki Y, Nakamura M, et al. The gene encoding a newly discovered protein, chorein, is mutated in chorea-acanthocytosis. *Nat Genet* 2001;28:121–122, doi: <http://dx.doi.org/10.1038/88825>.
40. Hardie RJ, Pullon HW, Harding AE, et al. Neuroacanthocytosis. A clinical, haematological and pathological study of 19 cases. *Brain* 1991;114 (Pt 1A):13–49.
41. Danek A, Sheesley L, Tierney M, Uttner I, Grafman J. Cognitive and neuropsychiatric findings in McLeod syndrome and in chorea-acanthocytosis. In: Danek A, editor. Neuroacanthocytosis syndromes. 1st Edition. Dordrecht: Springer; 2004. p 95–116.
42. Sorrentino G, De Renzo A, Miniello S, Nori O, Bonavita V. Late appearance of acanthocytes during the course of chorea-acanthocytosis. *J Neurol Sci* 1999;175–178, doi: [http://dx.doi.org/10.1016/S0022-510X\(99\)00005-2](http://dx.doi.org/10.1016/S0022-510X(99)00005-2).
43. Walterfang M, Yucl M, Walker R, et al. Adolescent obsessive compulsive disorder heralding chorea-acanthocytosis. *Mov Disord* 2008;23:422–425, doi: <http://dx.doi.org/10.1002/mds.21725>.
44. Lossos A, Dobson-Stone C, Monaco A, et al. Early clinical heterogeneity in choreoacanthocytosis. *Arch Neurol* 2005;62:611–614, doi: <http://dx.doi.org/10.1001/archneur.62.4.611>.
45. Kartsounis L, Hardie R. The pattern of cognitive impairments in neuroacanthocytosis. *Arch Neurol* 1996;53:77–80, doi: <http://dx.doi.org/10.1001/archneur.1996.00550010095022>.
46. Walterfang M, Evans A, Looi JCL, et al. The neuropsychiatry of neuroacanthocytosis syndromes. *Neurosci Biobehav Rev* 2011;35:1275–1283, doi: <http://dx.doi.org/10.1016/j.neubiorev.2011.01.001>.
47. Walterfang M, Looi JC, Styner M, et al. Shape alterations in the striatum in chorea-acanthocytosis. *Psychiatry Res* 2011;192:29–36, doi: <http://dx.doi.org/10.1016/j.psychres.2010.10.006>.
48. Sokolov E, Schneider SA, Bain PG. Choreoacanthocytosis. *Pract Neurol* 2012;12:40–43, doi: <http://dx.doi.org/10.1136/practneurol-2011-000045>.
49. Tsai CH, Chen RS, Chang HC, Lu CS, Liao KK. Acanthocytosis and spinocerebellar degeneration: a new association? *Mov Disord* 1997;12:456–459, doi: <http://dx.doi.org/10.1002/mds.870120333>.
50. Nicholl DJ, Sutton I, Dotti MT, Supple SG, Danek A, Lawden M. White matter abnormalities on MRI in neuroacanthocytosis. *J Neurol Neurosurg Psychiatry* 2004;75:1200–1201, doi: <http://dx.doi.org/10.1136/jnnp.2003.026781>.
51. Katsube T, Shimono T, Ashikaga R, Hosono M, Kitagaki H, Murakami T. Demonstration of cerebellar atrophy in neuroacanthocytosis of 2 siblings. *AJNR Am J Neuroradiol* 2009;30:386–388, doi: <http://dx.doi.org/10.3174/ajnr.A1282>.
52. Muller-Vahl KR, Berding G, Emrich HM, Peschel T. Chorea-acanthocytosis in monozygotic twins: clinical findings and neuropathological changes as detected by diffusion tensor imaging, FDG-PET and [(123)I]beta-CIT SPECT. *J Neurol* 2007;254:1081–1088, doi: <http://dx.doi.org/10.1007/s00415-006-0492-5>.
53. Pantelis C, Barnes T, Nelson H. Is the concept of frontal-subcortical dementia relevant to schizophrenia? *Br J Psychiatry* 1992;160:442–460, doi: <http://dx.doi.org/10.1192/bjp.160.4.442>.
54. Aouizerate B, Guehl D, Cuny E, et al. Pathophysiology of obsessive-compulsive disorder: a necessary link between phenomenology, neuropsychology, imagery and physiology. *Prog Neurobiol* 2004;72:195–221, doi: <http://dx.doi.org/10.1016/j.pneurobio.2004.02.004>.
55. Jung HH, Hergersberg M, Kneifel S, et al. McLeod syndrome: a novel mutation, predominant psychiatric manifestations, and distinct striatal imaging findings. *Ann Neurol* 2001;49:384–392, doi: <http://dx.doi.org/10.1002/ana.76>.
56. Danek A, Rubio J, Rampoldi L, et al. McLeod neuroacanthocytosis: genotype and phenotype. *Ann Neurol* 2001;50:775–764, doi: <http://dx.doi.org/10.1002/ana.10035>.
57. Jung H, Hergersberg M, Kneifel S, et al. McLeod syndrome: a novel mutation, predominant psychiatric manifestations, and distinct striatal imaging findings. *Ann Neurol* 2001;49:384–392, doi: <http://dx.doi.org/10.1002/ana.76>.
58. Brin M, A H, Symmans W, Marsh W, Rowland L. Neuropathology of McLeod phenotype is like chorea-acanthocytosis. *Can J Neuro Sci* 1993;20:S234, doi: [http://dx.doi.org/10.1016/0022-510X\(93\)90309-M](http://dx.doi.org/10.1016/0022-510X(93)90309-M).
59. Rinne J, Daniel S, Scaravilli F, Pires M, Harding A, Marsden C. The neuropathological features of neuroacanthocytosis. *Mov Disord* 1994;9:297–304, doi: <http://dx.doi.org/10.1002/mds.870090303>.
60. Hewer E, Danek A, Schoser B, et al. McLeod myopathy revisited: more neurogenic and less benign. *Brain* 2007;130:3285–3296, doi: <http://dx.doi.org/10.1093/brain/awm269>.
61. Zeman A, Daniels G, Tilley L, et al. McLeod syndrome: life-long neuropsychiatric disorder due to a novel mutation of the XK gene. *Psychiatr Genet* 2005;15:291–293, doi: <http://dx.doi.org/10.1097/00041444-200512000-00012>.
62. Vazquez M, Martinez M. Electroconvulsive therapy in neuroacanthocytosis or McLeod syndrome. *J ECT* 2009;25:72–73, doi: <http://dx.doi.org/10.1097/YCT.0b013e31817b06e0>.
63. Miranda M, Castiglioni C, Frey B, Hergersberg M, Danek A, Jung H. Phenotypic variability of a distinct deletion in McLeod syndrome. *Mov Disord* 2007;22:1358–1361, doi: <http://dx.doi.org/10.1002/mds.21536>.
64. Oeschner M, Danek A, Winkler G. McLeod-Neuroakanthozytose: ein zu selten diagnostiziertes syndrom? *Akt Neurologie* 1996;23:245–250, doi: <http://dx.doi.org/10.1055/s-2007-1017870>.
65. Jung H, Haker H. Schizophrenia as a manifestation of X-linked McLeod-neuroacanthocytosis syndrome. *J Clin Psychiatry* 2004;65:722–723, doi: <http://dx.doi.org/10.4088/JCP.v65n0520c>.

66. Dotti M, Battisti C, Malandrini A, et al. McLeod syndrome and neuroacanthocytosis with a novel mutation in the XK gene. *Mov Disord* 2000;15: 1282–1284, doi: [http://dx.doi.org/10.1002/1531-8257\(200011\)15:6<1282::AID-MDS1042>3.0.CO;2-2](http://dx.doi.org/10.1002/1531-8257(200011)15:6<1282::AID-MDS1042>3.0.CO;2-2).
67. Danek A, Uttner I, Vogl T, Tatsch K, Witt T. Cerebral involvement in McLeod syndrome. *Neurology* 1994;44:117–120, doi: <http://dx.doi.org/10.1212/WNL.44.1.117>.
68. Oeschner M, Buchert R, Beyer W, Danek A. Reduction of striatal glucose metabolism in McLeod choreoacanthocytosis. *J Neurol Neurosurg Psychiatry* 2001;70:517–520, doi: <http://dx.doi.org/10.1136/jnnp.70.4.517>.
69. Dydak U, Mueller S, Sandor P, Meier D, Boesiger P, Jung H. Cerebral metabolic alterations in McLeod syndrome. *Eur Neurol* 2006;56:17–23, doi: <http://dx.doi.org/10.1159/000095136>.
70. Holmes SE, O'Hearn E, Rosenblatt A, et al. A repeat expansion in the gene encoding junctophilin-3 is associated with Huntington disease-like 2. *Nat Genet* 2001;29:377–378, doi: <http://dx.doi.org/10.1038/ng760>.
71. Margolis R, O'Hearn E, Rosenblatt A, et al. A disorder similar to Huntington's disease is associated with a novel CAG repeat expansion. *Ann Neurol* 2001;50:373–380.
72. Nicholas AP, O'Hearn E, Holmes SE, Chen DT, Margolis RL. Clinical signs and symptoms in a large hereditary spastic paraparesis pedigree with a novel spastin mutation. *Mov Disord* 2004;19:641–648, doi: <http://dx.doi.org/10.1002/mds.20077>.
73. Stevanin G, Fujigasaki H, Lebre A-S, et al. Huntington's disease-like phenotype due to trinucleotide repeat expansions in the TBP and JPH3 genes. *Brain* 2003;126(Pt 7):1599–1603, doi: <http://dx.doi.org/10.1093/brain/awg155>.
74. Bardien S, Abrahams F, Soodyall H, et al. A South African mixed ancestry family with Huntington disease-like 2: clinical and genetic features. *Mov Disord* 2007;22:2083–2089, doi: <http://dx.doi.org/10.1002/mds.21672>.
75. Rodrigues GGR, Walker RH, Brice A, et al. Huntington's disease-like 2 in Brazil—report of 4 patients. *Mov Disord* 2008;23:2244–2247, doi: <http://dx.doi.org/10.1002/mds.22223>.
76. Rudnicki D, Pletnikova O, Vonsattel J, Ross C, Margolis R. A comparison of Huntington disease and Huntington disease-like 2 neuropathology. *J Neuropathol Exp Neurol* 2008;67:366–374, doi: <http://dx.doi.org/10.1097/NEN.0b013e31816b4aee>.
77. de Bie P, Muller P, Wijmenga C, Klomp LW. Molecular pathogenesis of Wilson and Menkes disease: correlation of mutations with molecular defects and disease phenotypes. *J Med Genet* 2007;44:673–688, doi: <http://dx.doi.org/10.1136/jmg.2007.052746>.
78. Rathbun J. Neuropsychological aspects of Wilson's disease. *Int J Neurosci* 1996;85:221–229, doi: <http://dx.doi.org/10.3109/00207459608986684>.
79. Medalia A, Scheinberg I. Psychopathology in patients with Wilson's disease. *Am J Psychiatry* 1989;146:662–64.
80. Srinivas K, Sinha S, Taly A, et al. Dominant psychiatric manifestations in Wilson's disease: A diagnostic and therapeutic challenge! *J Neurol Sci* 2008; 266:104–108.
81. Akil M, Schwartz JA, Dutchak D, Yuzbasiyan-Gurkan V, Brewer GJ. The psychiatric presentations of Wilson's disease. *J Neuropsychiatry Clin Neurosci* 1991;3:377–382.
82. Shanmugiah A, Sinha S, Taly A, et al. Psychiatric manifestations in Wilson's disease: a cross-sectional analysis. *J Neuropsychiatry Clin Neurosci* 2008;20: 81–85, doi: <http://dx.doi.org/10.1176/appi.neuropsych.20.1.81>.
83. Seniow J, Bak T, Gajda J, Poniatowska R, Czlonkowska A. Cognitive functioning in neurologically symptomatic and asymptomatic forms of Wilson's disease. *Mov Disord* 2002;17:1077–1083, doi: <http://dx.doi.org/10.1002/mds.10195>.
84. Medalia A, Isaacs-Glaberman K, Scheinberg I. Neuropsychological impairment in Wilson's disease. *Arch Neurol* 1988;45:502–504, doi: <http://dx.doi.org/10.1001/archneur.1988.00520290030009>.
85. Isaacs-Glaberman K, Medalia A, Scheinberg I. Verbal recall and recognition abilities in patients with Wilson's disease. *Cortex* 1989;25:353–361, doi: [http://dx.doi.org/10.1016/S0010-9452\(89\)80050-4](http://dx.doi.org/10.1016/S0010-9452(89)80050-4).
86. Dening T. The neuropsychiatry of Wilson's disease: a review. *Int J Psychiatry Med* 1991;21:135–148, doi: <http://dx.doi.org/10.2190/BAFK-D0A7-Q1C4-V667>.
87. Wichowicz H, Cubala W, Slawek J. Wilson's disease associated with delusional disorder. *Psychiatry Clin Neurosci* 2006;60:758–760, doi: <http://dx.doi.org/10.1111/j.1440-1819.2006.01592.x>.
88. Stiller P, Kassubek J, Schonfeldt-Leucon C, Connemann B. Wilson's disease in psychiatric patients. *Psychiatry Clin Neurosci* 2008;56:649, doi: <http://dx.doi.org/10.1046/j.1440-1819.2002.01071.x>.
89. Kumawat BL, Sharma CM, Tripathi G, Ralot T, Dixit S. Wilson's disease presenting as isolated obsessive-compulsive disorder. *Indian J Med Sci* 2007;61:607–610, doi: <http://dx.doi.org/10.4103/0019-5359.37047>.
90. Williams J, Walshe J. Wilson's disease: an analysis of the cranial computerized tomographic appearances found in 60 patients and the changes in response to treatment with chelating agents. *Brain* 1981;104:735–752, doi: <http://dx.doi.org/10.1093/brain/104.4.735>.
91. Roh J, Lee T. Initial and follow-up brain MRI findings and correlation with the clinical course in Wilson's disease. *Neurology* 1994;44:1064–1068, doi: <http://dx.doi.org/10.1212/WNL.44.6.1064>.
92. King AD, Walshe JM, Kendall BE, et al. Cranial MR imaging in Wilson's disease. *AJR Am J Roentgenol* 1996;167:1579–1584, doi: <http://dx.doi.org/10.2214/ajr.167.6.8956601>.
93. Hitoshi S, Iwata M, Yoshikawa K. Mid-brain pathology of Wilson's disease: MRI analysis of three cases. *J Neurol Neurosurg Psychiatry* 1991;54:624–626, doi: <http://dx.doi.org/10.1136/jnnp.54.7.624>.
94. Hawkins R, Mazziotta J, Phelps M. Wilson's disease studied with FDG and positron-emission tomography. *Neurology* 1987;37:1707–1711, doi: <http://dx.doi.org/10.1212/WNL.37.11.1707>.
95. Piga M, Murru A, Satta L, et al. Brain MRI and SPECT in the diagnosis of early neurological involvement in Wilson's disease. *Eur J Nucl Med Mol Imaging* 2008;35:716–724, doi: <http://dx.doi.org/10.1007/s00259-007-0681-1>.
96. Hayflick SJ, Westaway SK, Levinson B, et al. Genetic, clinical, and radiographic delineation of Hallervorden-Spatz syndrome. *N Engl J Med* 2003; 348:33–40, doi: <http://dx.doi.org/10.1056/NEJMoa020817>.
97. Freeman K, Gregory A, Turner A, Blasco P, Hogarth P, Hayflick S. Intellectual and adaptive behaviour functioning in pantothenate kinase-associated neurodegeneration. *J Intell Disabil Res* 2007;51:417–426, doi: <http://dx.doi.org/10.1111/j.1365-2788.2006.00889.x>.

98. Cooper G, Rizzo M, Jones R. Adult-onset Hallervorden-Spatz syndrome presenting as cortical dementia. *Alzheimer Dis Assoc Disord* 2000;14:120–126, doi: <http://dx.doi.org/10.1097/00002093-200004000-00010>.
99. Marelli C, Piacentini S, Garavaglia B, Girotti F, Albanese A. Clinical and neuropsychological correlates in two brothers with pantothenate kinase-associated neurodegeneration. *Mov Disord* 2005;20:208–212, doi: <http://dx.doi.org/10.1002/mds.20282>.
100. Nardocci N, Rumi V, Combi M, Angelini L, Mirabile D, Bruzzone M. Complex tics, stereotypies, and compulsive behavior as clinical presentation of a juvenile progressive dystonia suggestive of Hallervorden-Spatz disease. *Mov Disord* 1994;9:369–371, doi: <http://dx.doi.org/10.1002/mds.870090322>.
101. Nicholas A, Earnst K, Marson D. Atypical Hallervorden-Spatz disease with preserved cognition and obtrusive obsessions and compulsions. *Mov Disord* 2005;20:880–886, doi: <http://dx.doi.org/10.1002/mds.20476>.
102. Scarano V, Pellicchia M, Filla A, Barone P. Hallervorden-Spatz syndrome resembling a typical Tourette syndrome. *Mov Disord* 2002;17:618–620, doi: <http://dx.doi.org/10.1002/mds.10105>.
103. Öner Ö, Öner P, Deda G, İçağasıoğlu D. Psychotic disorder in a case with Hallervorden-Spatz disease. *Acta Psychiatr Scand* 2003;108:394–397, doi: <http://dx.doi.org/10.1034/j.1600-0447.2003.00159.x>.
104. Morphy M, Feldman J, Kilburn G. Hallervorden-Spatz disease in a psychiatric setting. *J Clin Psychiatry* 1989;50:66–68.
105. Angelini L, Nardocci N, Rumi V, Zorzi C, Strada L, Savoirdo M. Hallervorden-Spatz disease: clinical and MRI study of 11 cases diagnosed in life. *J Neurol* 1992;239:417–425, doi: <http://dx.doi.org/10.1007/BF00856805>.
106. Savoirdo M, Halliday WC, Nardocci N, et al. Hallervorden-Spatz disease: MR and pathologic findings. *AJNR Am J Neuroradiol* 1993;14:155–162.
107. Guilleman RP. The eye-of-the-tiger sign. *Radiology* 2000;217:895–896.
108. Molinuevo JL, Munoz E, Valldeoriola F, Tolosa E. The eye of the tiger sign in cortical-basal ganglionic degeneration. *Mov Disord* 1999;14:169–171, doi: [http://dx.doi.org/10.1002/1531-8257\(199901\)14:1<169::AID-MDS1033>3.0.CO;2-#](http://dx.doi.org/10.1002/1531-8257(199901)14:1<169::AID-MDS1033>3.0.CO;2-#).
109. Davie CA, Barker GJ, Machado C, Miller DH, Lees AJ. Proton magnetic resonance spectroscopy in Steele-Richardson-Olszewski syndrome. *Mov Disord* 1997;12:767–771, doi: <http://dx.doi.org/10.1002/mds.870120525>.
110. McNeill A, Birchall D, Haylick SJ, et al. T2\* and FSE MRI distinguishes four subtypes of neurodegeneration with brain iron accumulation. *Neurology* 2008;70(16):1614–1619, doi: <http://dx.doi.org/10.1212/01.wnl.0000310985.40011.d6>.
111. Doi H, Koyano S, Miyatake S, et al. Siblings with the adult-onset slowly progressive type of pantothenate kinase-associated neurodegeneration and a novel mutation, Ile346Ser, in PANK2: clinical features and (99m)Tc-ECD brain perfusion SPECT findings. *J Neurol Sci* 2010;290:172–176, doi: <http://dx.doi.org/10.1016/j.jns.2009.11.008>.
112. Yoshida K, Furihata K, Takeda S, et al. A mutation in the ceruloplasmin gene is associated with systemic hemosiderosis in humans. *Nat Genet* 1995;9:267–272, doi: <http://dx.doi.org/10.1038/ng0395-267>.
113. Hellman N, Gitlin J. Ceruloplasmin metabolism and function. *Annu Rev Nutr* 2002;22:439–58, doi: <http://dx.doi.org/10.1146/annurev.nutr.22.012502.114457>.
114. Miyajima H. Aceruloplasminemia, an iron metabolic disorder. *Neuropathology* 2003;23:345–350, doi: <http://dx.doi.org/10.1046/j.1440-1789.2003.00521.x>.
115. Miyajima H, Kohno S, Takahashi Y, Yonekawa O, Kanno T. Estimation of the gene frequency of aceruloplasminemia in Japan. *Neurology* 1999;53:617, doi: <http://dx.doi.org/10.1212/WNL.53.3.617>.
116. McNeill A, Pandolfo M, Kuhn J, Shang H, Miyajima H. The neurological presentation of ceruloplasmin gene mutations. *Eur Neurol* 2008;60:200–205, doi: <http://dx.doi.org/10.1159/000148691>.
117. Miyajima H, Takahashi Y, Kono S, Hishida A, Ishikawa K, Sakamoto M. Frontal lobe dysfunction associated with glucose hypometabolism in aceruloplasminemia. *J Neurol* 2005;252:996–997, doi: <http://dx.doi.org/10.1007/s00415-005-0796-x>.
118. Walterfang M, March E, Varghese D, et al. Schizophrenia-like psychosis and aceruloplasminemia. *Neuropsychiatric Dis Treat* 2006;2:577–581, doi: <http://dx.doi.org/10.2147/ndt.2006.2.4.577>.
119. Daimon M, Moriai S, Susa S, Yamatani K, Hosoya T, Kato T. Hypoacceruloplasminaemia with heteroallelic caeruloplasmin gene mutation: MRI of the brain. *Neuroradiology* 1999;41:185–187, doi: <http://dx.doi.org/10.1007/s002340050730>.
120. Morita H, Ikeda S, Yamamoto K, et al. Hereditary ceruloplasmin deficiency with hemosiderosis: a clinicopathological study of a Japanese family. *Ann Neurol* 1995;37:646–656, doi: <http://dx.doi.org/10.1002/ana.410370515>.
121. Grisoli M, Piperno A, Chiapparini L, Mariani R, Savoirdo M. MR imaging of cerebral cortical involvement in aceruloplasminemia. *Am J Neuroradiol* 2005;26:657–661.
122. Haacke EM, Cheng NY, House MJ, et al. Imaging iron stores in the brain using *Magn Reson Imaging* 2005;23:1–25.
123. McNeill A, Chinnery PF. Neuroferritinopathy: update on clinical features and pathogenesis. *Curr Drug Targets*. 2012;13:1200–1203, doi: <http://dx.doi.org/10.2174/138945012802002375>.
124. Hautot D, Pankhurst Q, Morris C, Curtis A, Burn J, Dobson J. Preliminary observation of elevated levels of nanocrystalline iron oxide in the basal ganglia of neuroferritinopathy patients. *Biochim Biophys Acta* 2007;1772:21–25, doi: <http://dx.doi.org/10.1016/j.bbdis.2006.09.011>.
125. Lehn A, Boyle R, Brown H, Airey C, Mellick G. Neuroferritinopathy. *Parkinsonism Relat Disord* 2012;18:909–915, doi: <http://dx.doi.org/10.1016/j.parkreldis.2012.06.021>.
126. Chinnery P, Crompton D, Birchall D, Jackson M, Coulthard A, Lombes A, et al. Clinical features and natural history of neuroferritinopathy caused by the FTL1 460InsA mutation. *Brain* 2007;130:110–119, doi: <http://dx.doi.org/10.1093/brain/awl319>.
127. Willis A, Sawle G, Guilbert P, Curtis A. Palatal tremor and cognitive decline in neuroferritinopathy. *J Neurol Neurosurg Psychiatry* 2002;73:91–92, doi: <http://dx.doi.org/10.1136/jnmp.73.1.91>.
128. Ohta E, Nagasaka T, Shindo K, et al. Neuroferritinopathy in a Japanese family with a duplication in the ferritin light chain gene. *Neurology* 2007;70:1493–1494, doi: <http://dx.doi.org/10.1212/01.wnl.0000310428.74624.95>.
129. Maciel P, Cruz V, Constante M, et al. Neuroferritinopathy: missense mutation in FTL causing early-onset bilateral pallidal involvement. *Neurology*

- 2005;65:603–605, doi: <http://dx.doi.org/10.1212/01.wnl.0000178224.81169.c2>.
130. Mir P, Edwards M, Curtis A, Bhatia K, Quinn N. Adult-onset generalized dystonia due to a mutation in the neuroferritinopathy gene. *Mov Disord* 2005;20:243–245, doi: <http://dx.doi.org/10.1002/mds.20280>.
131. McNeill A, Gorman G, Khan A, Horvath R, Blamire AM, Chinnery PF. Progressive brain iron accumulation in neuroferritinopathy measured by the thalamic T2\* relaxation rate. *AJNR Am J Neuroradiol* 2012;33:1810–1813, doi: <http://dx.doi.org/10.3174/ajnr.A3036>.
132. Koide R, Ikeuchi T, Onodera O, et al. Unstable expansion of CAG repeat in hereditary dentatorubral-pallidolusian atrophy (DRPLA). *Nat Genet* 1994;6:9–13, doi: <http://dx.doi.org/10.1038/ng0194-9>.
133. Adachi N, Arima K, Asada T, et al. Dentatorubral-pallidolusian atrophy (DRPLA) presenting with psychosis. *J NeuroPsychiatry Clin Neurosci* 2001;13:258–260, doi: <http://dx.doi.org/10.1176/appi.neuropsych.13.2.258>.
134. Simpson M, Smith A, Kent H, Roxburgh R. Neurological picture. Distinctive MRI abnormalities in a man with dentatorubral-pallidolusian atrophy. *J Neurol Neurosurg Psychiatry* 2012;83:529–530, doi: <http://dx.doi.org/10.1136/jnnp-2011-301612>.
135. Yoshii F, Tomiyasu H, Shinohara Y. Fluid attenuation inversion recovery (FLAIR) images of dentatorubral-pallidolusian atrophy: case report. *J Neurol Neurosurg Psychiatry* 1998;65:396–399, doi: <http://dx.doi.org/10.1136/jnnp.65.3.396>.
136. Uyama E, Kondo I, Uchino M, et al. Dentatorubral-pallidolusian atrophy (DRPLA): clinical, genetic, and neuroradiologic studies in a family. *J Neurolog Sci* 1995;130:146–153, doi: [http://dx.doi.org/10.1016/0022-510X\(95\)00019-X](http://dx.doi.org/10.1016/0022-510X(95)00019-X).
137. Sunami Y, Koide R, Arai N, Yamada M, Mizutani T, Oyanagi K. Radiologic and neuropathologic findings in patients in a family with dentatorubral-pallidolusian atrophy. *AJNR Am J Neuroradiol* 2011;32:109–114.
138. Walterfang M, Velakoulis D, Whitford TJ, Pantelis C. Understanding aberrant white matter development in schizophrenia: an avenue for therapy? *Expert Rev Neurother* 2011;11:971–987, doi: <http://dx.doi.org/10.1586/ern.11.76>.
139. Walterfang M, Wood SJ, Velakoulis D, Copolov D, Pantelis C. Diseases of white matter and schizophrenia-like psychosis. *Aust N Z J Psychiatry* 2005;39:746–756, doi: <http://dx.doi.org/10.1080/j.1440-1614.2005.01678.x>.
140. Walterfang M, Wood SJ, Velakoulis D, Pantelis C. Neuropathological, neurogenetic and neuroimaging evidence for white matter pathology in schizophrenia. *Neurosci Biobehav Rev* 2006;30:918–948, doi: <http://dx.doi.org/10.1016/j.neubiorev.2006.02.001>.
141. Bonelli RM, Cummings JL. Frontal-subcortical dementias. *Neurologist* 2008;14:100–107, doi: <http://dx.doi.org/10.1097/NRL.0b013e31815b0de2>.
142. Geschwind DH. Focusing attention on cognitive impairment in spinocerebellar ataxia. *Arch Neurol* 1999;56:20–22, doi: <http://dx.doi.org/10.1001/archneur.56.1.20>.
143. Kish SJ, el-Awar M, Stuss D, et al. Neuropsychological test performance in patients with dominantly inherited spinocerebellar ataxia: relationship to ataxia severity. *Neurology* 1994;44:1738–1746, doi: <http://dx.doi.org/10.1212/WNL.44.9.1738>.
144. Liszewski CM, O’Hearn E, Leroi I, Gourley L, Ross CA, Margolis RL. Cognitive impairment and psychiatric symptoms in 133 patients with diseases associated with cerebellar degeneration. *J Neuropsychiatry Clin Neurosci* 2004;16:109–112, doi: <http://dx.doi.org/10.1176/appi.neuropsych.16.1.109>.
145. Leroi I, O’Hearn E, Marsh L, et al. Psychopathology in patients with degenerative cerebellar diseases: a comparison to Huntington’s disease. *Am J Psychiatry* 2002;159:1306–1314, doi: <http://dx.doi.org/10.1176/appi.ajp.159.8.1306>.
146. Mascalchi M. Spinocerebellar ataxias. *Neurolog Sci* 2008;29(Suppl 3):311–333, doi: <http://dx.doi.org/10.1007/s10072-008-1005-3>.
147. Savoirdo M, Strada L, Girotti F, et al. Olivopontocerebellar atrophy: MR diagnosis and relationship to multisystem atrophy. *Radiology* 1990;174(Pt 1):693–696.
148. Bradac GB, Riva A, Mortara P, Orsi L, Riccio A. Primary progressive cerebellar ataxia. *Neuroradiology* 1989;31:16–18.
149. Yamada S, Nishimiya J, Nakajima T, Taketazu F. Linear high intensity area along the medial margin of the internal segment of the globus pallidus in Machado-Joseph disease patients. *J Neurol Neurosurg Psychiatry* 2005;76:573–575, doi: <http://dx.doi.org/10.1136/jnnp.2004.040279>.
150. Della Nave R, Ginestroni A, Tessa C, et al. Brain white matter damage in SCA1 and SCA2. An in vivo study using voxel-based morphometry, histogram analysis of mean diffusivity and tract-based spatial statistics. *NeuroImage* 2008;43:10–19, doi: <http://dx.doi.org/10.1016/j.neuroimage.2008.06.036>.
151. Mandelli ML, De Simone T, Minati L, et al. Diffusion tensor imaging of spinocerebellar ataxias types 1 and 2. *AJNR Am J Neuroradiol* 2007;28:1996–2000, doi: <http://dx.doi.org/10.3174/ajnr.A0716>.
152. Prakash N, Hageman N, Hua X, Toga AW, Perlman SL, Salamon N. Patterns of fractional anisotropy changes in white matter of cerebellar peduncles distinguish spinocerebellar ataxia-1 from multiple system atrophy and other ataxia syndromes. *NeuroImage* 2009;47(Suppl 2):T72–81, doi: <http://dx.doi.org/10.1016/j.neuroimage.2009.05.013>.
153. D’Agata F, Caroppo P, Boghi A, et al. Linking coordinative and executive dysfunctions to atrophy in spinocerebellar ataxia 2 patients. *Brain Struct Funct* 2011;216:275–288, doi: <http://dx.doi.org/10.1007/s00429-011-0310-4>.
154. Reetz K, Kleiman A, Klein C, et al. CAG repeats determine brain atrophy in spinocerebellar ataxia 17: a VBM study. *PLoS One* 2011;6:e15125, doi: <http://dx.doi.org/10.1371/journal.pone.0015125>.
155. Brockmann K, Reimold M, Globas C, et al. PET and MRI reveal early evidence of neurodegeneration in spinocerebellar ataxia type 17. *J Nucl Med* 2012;53:1074–1080, doi: <http://dx.doi.org/10.2967/jnumed.111.101543>.
156. Andreasen NC, Nopoulos P, O’Leary DS, Miller DD, Wassink T, Flaum M. Defining the phenotype of schizophrenia: cognitive dysmetria and its neural mechanisms. *Biol Psychiatry* 1999;46:908–920, doi: [http://dx.doi.org/10.1016/S0006-3223\(99\)00152-3](http://dx.doi.org/10.1016/S0006-3223(99)00152-3).
157. Blomqvist M, Gieselmann V, Mansson JE. Accumulation of lysosulfatide in the brain of arylsulfatase A-deficient mice. *Lipids Health Dis* 2011;10:28, doi: <http://dx.doi.org/10.1186/1476-511X-10-28>.
158. Hayashi T, Nakamura M, Ichiba M, et al. Adult-type metachromatic leukodystrophy with compound heterozygous ARSA mutations: a case report and phenotypic comparison with a previously reported case. *Psychiatry Clin Neurosci* 2011;65:105–108, doi: <http://dx.doi.org/10.1111/j.1440-1819.2010.02169.x>.



159. Lugowska A, Amaral O, Berger J, et al. Mutations c.459+1G>A and p.P426L in the ARSA gene: prevalence in metachromatic leukodystrophy patients from European countries. *Mol Genet Metab* 2005;86:353–359, doi: <http://dx.doi.org/10.1016/j.yjmgme.2005.07.010>.
160. Amaducci L, Sorbi S, Piacentini S, Bick KL. The first Alzheimer disease case: a metachromatic leukodystrophy? *Dev Neurosci* 1991;13:186–187, doi: <http://dx.doi.org/10.1159/000112158>.
161. Salmon E, Van der Linden M, Maerfens Noordhout A, et al. Early thalamic and cortical hypometabolism in adult-onset dementia due to metachromatic leukodystrophy. *Acta Neurol Belg* 1999;99:185–188.
162. Johannsen P, Ehlers L, Hansen HJ. Dementia with impaired temporal glucose metabolism in late-onset metachromatic leukodystrophy. *Dement Geriatr Cogn Disord* 2001;12:85–88, doi: <http://dx.doi.org/10.1159/000051240>.
163. Barkhof F, Scheltens P. Imaging of white matter lesions. *Cerebrovasc Dis* 2002;13(Suppl 2):21–30, doi: <http://dx.doi.org/10.1159/000049146>.
164. Cheon JE, Kim IO, Hwang YS, et al. Leukodystrophy in children: a pictorial review of MR imaging features. *Radiographics* 2002;22:461–476.
165. Kruse B, Hanefeld F, Christen HJ, et al. Alterations of brain metabolites in metachromatic leukodystrophy as detected by localized proton magnetic resonance spectroscopy in vivo. *J Neurol* 1993;241:68–74, doi: <http://dx.doi.org/10.1007/BF00869766>.
166. Hyde TM, Ziegler JC, Weinberger DR. Psychiatric disturbances in metachromatic leukodystrophy. Insights into the neurobiology of psychosis. *Arch Neurol* 1992;49:401–406, doi: <http://dx.doi.org/10.1001/archneur.1992.00530280095028>.
167. Millat G, Marçais C, Rafi MA, et al. Niemann-Pick C1 disease: the I1061T substitution is a frequent mutant allele in patients of Western European descent and correlates with a classic juvenile phenotype. *Am J Hum Genet* 1999; 65:1321–1329, doi: <http://dx.doi.org/10.1086/302626>.
168. Naureckiene S, Sleat DE, Lackland H, et al. Identification of HE1 as the second gene of Niemann-Pick C disease. *Science* 2000;290:2298–2301, doi: <http://dx.doi.org/10.1126/science.290.5500.2298>.
169. Sevin M, Lesca G, Baumann N, et al. The adult form of Niemann-Pick disease type C. *Brain* 2007;130(Pt 1):120–133.
170. Walterfang M, Fahey M, Desmond P, et al. White and gray matter alterations in adults with Niemann-Pick disease type C: a cross-sectional study. *Neurology* 2010; 75:49–56, doi: <http://dx.doi.org/10.1212/WNL.0b013e3181e6210e>.
171. Walterfang M, Fietz M, Fahey M, et al. The neuropsychiatry of Niemann-Pick type C disease in adulthood. *J Neuropsychiatry Clin Neurosci* 2006; 18:158–170, doi: <http://dx.doi.org/10.1176/appi.neuropsych.18.2.158>.
172. Sullivan D, Walterfang M, Velakoulis D. Bipolar disorder and Niemann-Pick disease type C. *Am J Psychiatry* 2005;162:1021–1022, doi: <http://dx.doi.org/10.1176/appi.ajp.162.5.1021-a>.
173. Imrie J, Vijayaraghaven S, Whitehouse C, et al. Niemann-Pick disease type C in adults. *J Inherit Metab Dis* 2002;25:491–500, doi: <http://dx.doi.org/10.1023/A:1021259403196>.
174. Walterfang M, Fahey M, Abel L, Fietz M, Wood A, Bowman E, et al. Size and shape of the corpus callosum in adult Niemann-Pick type C reflects state and trait illness variables. *AJNR Am J Neuroradiol* 2011;32:1340–1346, doi: <http://dx.doi.org/10.3174/ajnr.A2490>.
175. Walterfang M, Macfarlane MD, Looi JC, et al. Pontine-to-midbrain ratio indexes ocular-motor function and illness stage in adult Niemann-Pick disease type C. *Eur J Neurol* 2012;19:462–467, doi: <http://dx.doi.org/10.1111/j.1468-1331.2011.03545.x>.
176. Walterfang M, Patenaude B, Abel LA, et al. Subcortical volumetric reductions in adult Niemann-Pick disease type C: a cross-sectional study. *AJNR Am J Neuroradiol* 2013;34(7):1334–40, doi: 10.3174/ajnr.A3356.
177. Kumar A, Chugani HT. Niemann-Pick disease type C: unique 2-deoxy-2[(1)(8)F] fluoro-D-glucose PET abnormality. *Pediatric Neurol* 2011;44:57–60, doi: <http://dx.doi.org/10.1016/j.pediatrneurol.2010.08.004>.
178. Pantelis C, Barnes TR, Nelson HE. Is the concept of frontal-subcortical dementia relevant to schizophrenia? *Br J Psychiatry* 1992;160:442–460, doi: <http://dx.doi.org/10.1192/bjp.160.4.442>.
179. Andreasen N, Paradiso S, O’Leary D. “Cognitive dysmetria” as an integrative theory of schizophrenia: a dysfunction in cortical-subcortical-cerebellar circuitry? *Schizophr Bull* 1998;24:203–218, doi: <http://dx.doi.org/10.1093/oxfordjournals.schbul.a033321>.
180. Kimura M, Matsumoto N. Neuronal activity in the basal ganglia. Functional implications. *Adv Neurol* 1997;74:111–118.
181. Walterfang M. Psychiatric aspects of the neurodegenerative choreas. In: Walker RH, editor. *The differential diagnosis of chorea*. Oxford: Oxford University Press; 2011. p 369–406.
182. McGorry PD, Purcell R, Goldstone S, Amminger GP. Age of onset and timing of treatment for mental and substance use disorders: implications for preventive intervention strategies and models of care. *Curr Opin Psychiatry* 2011; 24:301–306, doi: <http://dx.doi.org/10.1097/YCO.0b013e3283477a09>.