

Available online at www.sciencedirect.com

ScienceDirect

journal homepage: www.elsevier.com/locate/radcr

Case Report

Hypoglossal nerve injury with C1 lateral mass screw placement: A case report and review of the literature [☆]

Maria De Abreu Pineda, BS^{a,*}, Elias Atallah, MD^b, John Wainwright, MD^b, Joseph Schaefer, MD^b, Aria Mahtabfar, MD^b, James Harrop, MD^b, Srinivas Prasad, MD^b, Joshua Heller, MD^b, Ashwini Sharan, MD^b, Ahilan Sivaganesan, MD^b, Jack Jallo, MD^b

^a Sidney Kimmel Medical College at Thomas Jefferson University, 1025 Walnut St #100, Philadelphia, PA 19107, USA

^b Thomas Jefferson University Hospital, Department of Neurological Surgery, 111 S 11th St, Philadelphia, PA 19107, USA

ARTICLE INFO

Article history:

Received 22 August 2022

Revised 29 August 2022

Accepted 4 September 2022

Key words:

Hypoglossal nerve injury

C1 lateral mass screw

C1-T2 posterior cervical

decompression and instrumented

fusion (PCDF)

ABSTRACT

We report the case of a 62-year-old man who presented with a progressive myelopathy secondary to spinal cord compression from an odontoid process fracture and subaxial central canal stenosis. The patient underwent a C1-T2 posterior decompression and instrumented fusion (PCDF) and did well immediately postoperatively. However, on POD1, he developed a right hypoglossal nerve (HN) palsy attributed to direct mechanical compression or injury from the C1 lateral mass screw (LMS), which improved following a revision and screw replacement. While HN injury is a known complication of high anterior and anterolateral cervical spine approaches as well as transcondylar screw fixation, this case aims to expand on the limited reports available regarding hypoglossal nerve injury following placement of bicortical C1 LMS. Furthermore, the use of fluoroscopic guidance in addition to anatomic landmarks and triggered electromyography of the tongue are offered as potential solutions to prevent HN injury intraoperatively.

© 2022 Published by Elsevier Inc. on behalf of University of Washington.

This is an open access article under the CC BY-NC-ND license

(<http://creativecommons.org/licenses/by-nc-nd/4.0/>)

Introduction

Hypoglossal nerve (HN) palsy is a rare condition that typically manifests as dysphagia, dysarthria, and ipsilateral tongue deviation. Tumors, predominantly malignant, are the most

common cause of HN palsy, followed by trauma injuries and strokes [1]. The HN arises from the medulla and emerges from the skull through the hypoglossal canal, directed anterolaterally above the occipital condyle [2]. The HN then follows a vertical course inferiorly and crosses the anterior aspect of the lateral mass of C1-C2, specifically lying in front of the lateral

[☆] Competing Interests: The authors declare that they have no known competing financial interests or personal relationships that could have appeared to influence the work reported in this paper.

* Corresponding author.

E-mail address: mvd006@jefferson.edu (M. De Abreu Pineda).

<https://doi.org/10.1016/j.radcr.2022.09.006>

1930-0433/© 2022 Published by Elsevier Inc. on behalf of University of Washington. This is an open access article under the CC BY-NC-ND license (<http://creativecommons.org/licenses/by-nc-nd/4.0/>)

portion of the C1 lateral mass and C1-2 facet joint, and lateral and dorsal to the internal carotid artery (ICA) at the C1 level [3]. Given this anatomical location, complications to neurovascular structures, including persistent HN deficits, following anterior C1-2 transarticular screw fixation have been well documented. However, HN palsy secondary to compression from a bicortical C1 lateral mass screw (LMS) has only rarely been reported [4]. We document a case of a unilateral HN palsy on postoperative day 1 (POD1) secondary to placement of bicortical C1 lateral mass screws after a C1-T2 posterior cervical decompression and instrumented fusion.

Case presentation

History and examination

A 62-year-old male patient presented with a history of frequent falls, several weeks of rapidly progressive gait dysfunction and neck pain radiating into his right tricep, forearm, hand and fingers associated with numbness and paresthesia. Neurologic exam was notable for decreased range of motion of the neck, abnormal tandem gait, bilateral diminished grip strength, and 1+ brachioradialis reflex on the right. The rest of his neurologic exam, including cranial nerve function, was unremarkable. His modified Oswestry Disability Index (ODI) score was 31, consistent with moderate disability level.

Electrodiagnostic and neuroimaging studies

Electromyography (EMG) revealed a right C6 cervical radiculopathy. Magnetic resonance imaging (MRI) of the cervical spine revealed a fracture across the base of the odontoid (Anderson D'Alonzo Type 2) [5], likely representing a non-united chronic fracture. The odontoid process was posteriorly angulated causing a moderate compression of the proximal cervical spinal cord just below the level of the craniocervical junction associated with T2-hyperintense signal in the spinal cord, likely representing myelomalacia. Additionally, the MRI revealed multilevel degenerative disease and central canal stenosis from C3 to C7. Computed tomography imaging and radiographs of cervical spine revealed mild-to-moderate spondylosis at C4-C5, C5-C6 and C5-C7.

Surgical procedure

Given the presentation of progressive myelopathy that was felt to be secondary to spinal cord compression from the odontoid process fracture and subaxial central canal stenosis, the decision was made to proceed with posterior decompression and instrumented fusion. The patient was brought to the operating room electively for a C1-T2 posterior cervical decompression and instrumented fusion with autograft placement (Fig. 1). Patient was intubated under direct visualization with video laryngoscopy). Neurophysiologic monitoring with motor evoked potentials (MEPs), somatosensory evoked potentials (SSEPs), free running electromyography (EMG), and brainstem auditory evoked responses (BAERs), and electroencephalography (EEG) was performed throughout the case, beginning

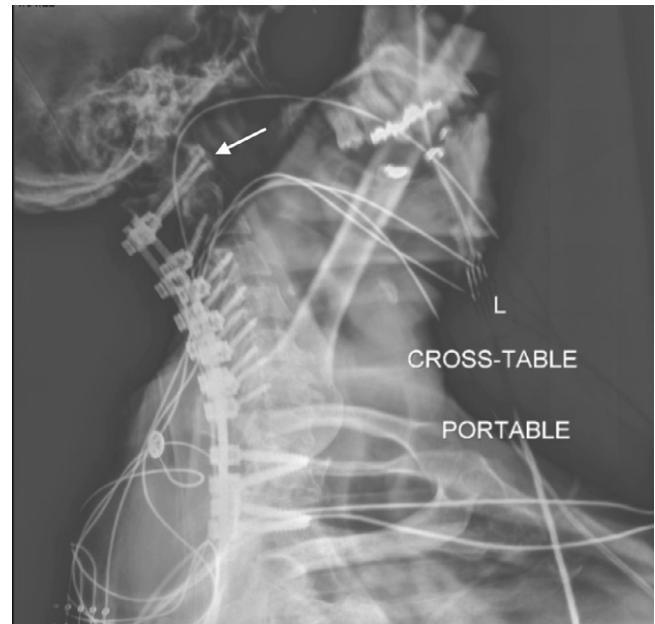

Fig. 1 – Postoperative lateral cervical radiograph, “Swimmer’s view,” depicting placement of the posterior instrumentation from C1-T2. Area of interest at C1 anterior arch (white arrow).

immediately after the intubation. Standard prone positioning with 3-pin head fixation in slight flexion with a mayfield frame was used. Motor and sensory evoked potentials were unchanged after patient positioning. Standard posterior midline cervical spine exposure from C1 to T2 was carried out. Bicortical C1 lateral mass screws and standard C2 pars screws were inserted bilaterally according to Goel [6] and Harms [7] technique. Subaxial C3-C6 lateral mass screws were then placed utilizing the Magerl [8] technique followed by T1 and T2 pedicle screws placement bilaterally. Anatomical landmarks and freehand technique with intermittent spot X-Rays were used during the placement of the instrumentation. Decompression was performed from C2 to C7 using standard technique. Rods were then placed spanning the C1 to T2 instrumentation and a morselized autograft from the laminectomy fragments was laid down after thorough decortication to promote arthrodesis. Closure was performed in standard multilayer fashion over a suction drain. Neurophysiological signals were unchanged throughout the procedure. Patient was extubated and noted to be at his neurologic baseline with no significant motor deficit noticeable prior to leaving the operating room.

Postoperative course

Patient did very well immediately postoperatively. Patient's neurological exam was closely monitored in the recovery room and later in the intermediate care unit. On POD1, while the patient was eating his breakfast, he complained of a sensation of tongue swelling and difficulty moving food around his mouth while eating. Examination revealed significant tongue deviation to the right most concerning for a right hypoglossal nerve palsy (Fig. 2). No other neurological abnormal-

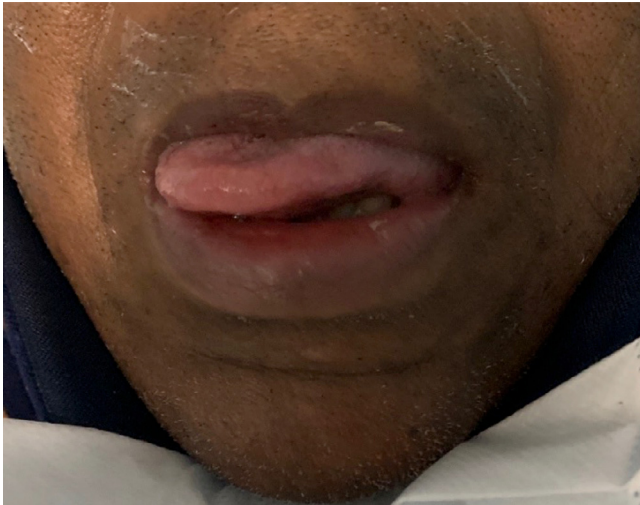

Fig. 2 – Tongue deviation to the right observed on postoperative day 1 (POD1) in a patient with hypoglossal nerve injury.

ities were found. Computer tomography angiography (CTA) of his head and neck did not demonstrate any vascular occlusion. MRI of the brain without contrast revealed no evidence of acute infarct, hemorrhage, or mass effect. On review of the CTA images, the right C1 lateral mass screw was noted to extend 4 mm beyond the anterior cortical margin of the C1 arch (Fig. 3). The hypoglossal palsy was felt to be attributable to direct mechanical compression or injury from the C1 lateral mass screw. Findings were discussed with the patient and a decision was made to proceed with revision of the right C1 screw.

Revision procedure

The patient underwent a revision surgery for right C1 lateral mass screw replacement. The previously placed screw was removed and replaced with a new screw following the same anatomic trajectory that was 4 mm shorter. No electromyographic activity was noticed in the right tongue with the manipulation of the first bicortically inserted C1 screw. Immediate postoperative radiographs (Fig. 4) confirmed appropriate positioning of hardware. Patient did well postoperatively and was recommended to be discharged home. He was assessed by speech therapy and was able to tolerate a regular diet. He was discharged home after appropriate recommendations were made.

Outpatient follow up

At last post-operative follow-up, the patient's hypoglossal palsy was noted to be improved.

Discussion

While hypoglossal nerve injury is a known complication of high anterior and anterolateral cervical spine approaches as

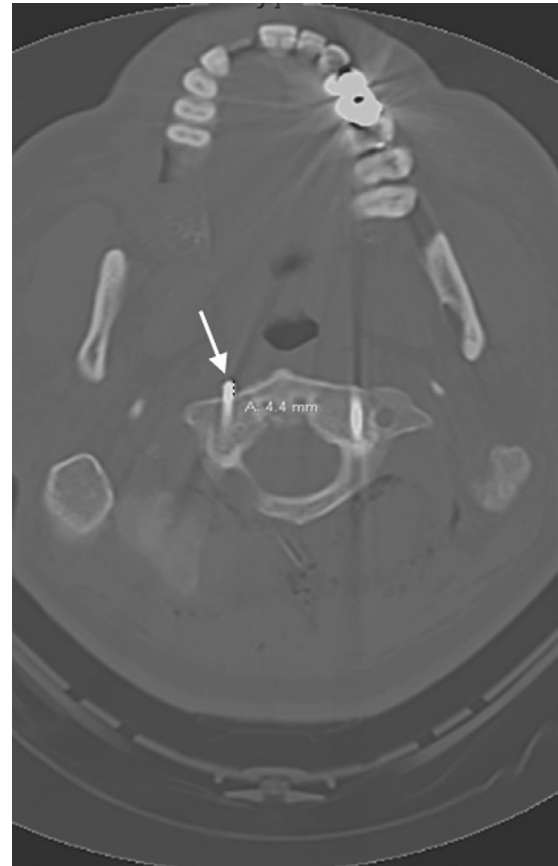


Fig. 3 – Postoperative axial CT image depicting the right C1 screw 4 mm beyond the cortical edge of the C1 arch (white arrow).

well as transcondylar screw fixation, limited cases of hypoglossal nerve injury have been reported with the placement of bicortical C1 lateral mass screws.

The more frequently cited risks associated with the placement of bicortical C1 lateral mass screws include vertebral or carotid artery injury with accompanied cerebellar infarcts, C2 nerve root irritation with associated occipital headaches, cerebrospinal fluid leak and spinal cord injury. Relatively scant data exists on the incidence of injury to structures ventral to the anterior C1 arch including ICA, hypoglossal nerve, and the aerodigestive tract.

Hypoglossal nerve topographical anatomy with anatomical variants

The hypoglossal nerve emerges from the hypoglossal canal at the skull base and passes downward between the internal carotid artery (ICA) and the internal jugular vein (IJV). Ebraheim et al. [9] demonstrated that, typically, the hypoglossal nerve is located posterior to the ICA and 2-3 mm lateral to the middle to the anterior aspect of the lateral mass of C1. More distally, it courses superficially to the ICAs and deep to the IJV.

Based on a morphometric study where Hong et al. [10] evaluated the anatomical relationships between the HN and the C1 bony structures (midline, lateral margin of the C1 lateral

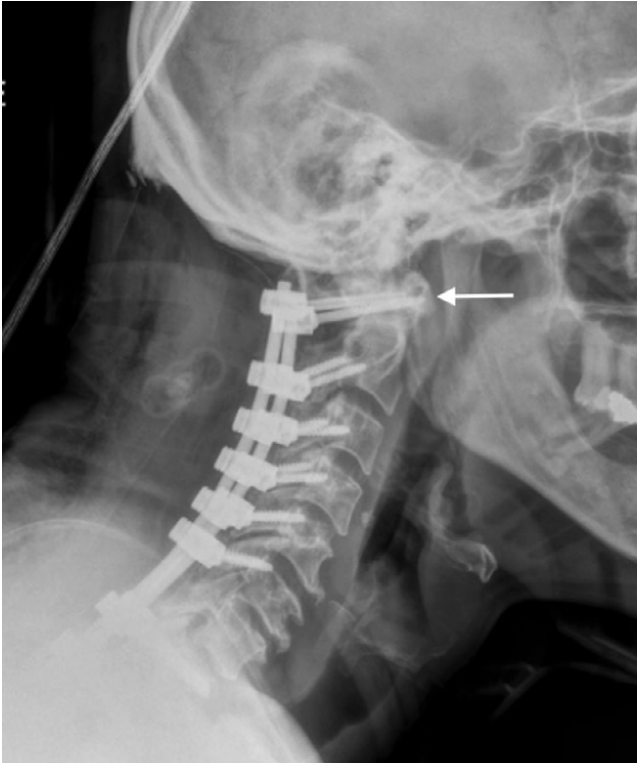

Fig. 4 – Postoperative lateral cervical radiograph following C1 screw replacement (white arrow).

mass, and C1 transverse process) the average diameter of the HN was 2.4 mm (SD 0.5 mm). The HN was located lateral to the C1 lateral mass in 85% of cases and in front of the lateral half of the lateral mass in 15% of cases. The ICA was located lateral to the C1 lateral mass in 44.4% of cases and in front of the lateral half of the lateral mass in 55.6% of cases. There was a statistically significant correlation between HN and ICA in terms of the distance from the midline, C1 lateral mass and transverse process. Consequently, medially located ICA was demonstrated to be a risk factor for HN located ventral to the lateral half of the C1 lateral mass.

In another anatomical study conducted by Cirpan et al. [11] the mean distance between the midline and the ICAs was 26.13 mm at the level of the axis. The mean distance between the midline and the HN was 33.3 mm on average at the level of the axis. This confirmed that the HN and the ICA proceeded ventrally and laterally along the lateral aspect of the lateral mass of C1. Hence, the area located ventrally along the medial components of the C1 lateral mass was the safe zone for anterior cervical approaches and for bicortical purchase of C1 lateral mass screws.

Optimal C1 lateral mass screw placement

One often overlooks the need to orient the C1 lateral mass screw medially during its placement. Hong et al. [12] suggested that optimal medial angulation of C1 lateral mass screws is essential to obtain longer screw purchase length hence stronger pullout strength in addition to avoiding the ventral

neurovascular structures during bicortical screw fixation. This implies that pre-operative neuroimaging should be studied thoroughly and measurements should be applied on the exposed anatomy in order to assist the surgeon in predicting the optimal screw entry point, angulation and trajectory.

On the other hand, another study by Hu et al. [13] that evaluated a large series of C1 lateral mass screws to determine accuracy based on CT scanning findings and to assess perioperative complication rate related to errant screw placement demonstrated a rate of ideal/safe screw placement of 97.2%. The 2.8% of unacceptable cases were mostly due to screws that erred medially into the spinal canal. Two patients had their C1 screw penetrate the anterior cortex by approximately 4mm and neither of them had any clinical signs of ICA or HN injuries.

Fluoroscopic guidance and electrophysiologic monitoring

Sai Kiran et al. [14] demonstrated safety, reproducibility and accuracy of lateral fluoroscopic-guided placement of C1 lateral mass screws and C2 screws when compared to freehand placement. Postoperative CT images imaging confirmed perfect placement of all C1 LM screws in a cohort of 94 patients. Thus, combining anatomic and lateral fluoroscopic guided placement of C1 LM screws might be the safest technique that prevents injuries to the surrounding neurovascular structures.

Moreover, instrumentation of the cervical spine is technically challenging and more difficult than the remainder of the spine. The associated complications to screw misplacement can lead to irreversible neurological damage. Real-time confirmation of correct screw placement in the operating room should therefore be considered a quintessential tool for continuous neuromonitoring intraoperatively. One would propose continuous monitoring of the hypoglossal nerve function with free running and triggered electromyography of the tongue for the detection of HN irritation, injury, or other anatomic conflict with implanted instrumentation during the placement of C1 LM screws.

Conclusion

Hypoglossal nerve injury is a rare yet important complication of C1 bicortical LM screw placement. We described a case of right HN palsy following C1 LM screws placement that improved on short term follow up over a period of 3 months after revision and replacement of the initial problematic screw with a shorter one. The use of fluoroscopic guidance in addition to anatomic landmarks and triggered EMG of the tongue are potential solutions to prevent hypoglossal nerve injury during placement of C1 lateral mass screws.

Patient consent

Informed consent for publication of this case was obtained from the patient under Dr. Jack Jallo's service at the Neurosurgery team at Thomas Jefferson University Hospital.

REFERENCES

- [1] Keane JR. Twelfth-nerve palsy. Analysis of 100 cases. *Arch Neurol* 1996;53(6):561–6. doi:10.1001/archneur.1996.00550060105023.
- [2] Bademci G, Yaşargil MG. Microsurgical anatomy of the hypoglossal nerve. *J Clin Neurosci* 2006;13(8):841–7. doi:10.1016/j.jocn.2005.12.028.
- [3] Hong JT, Espinoza Orías AA, An HS. Anatomical study of the ventral neurovascular structures and hypoglossal canal for the surgery of the upper cervical spine. *J Clin Neurosci* 2020;71:245–9. doi:10.1016/j.jocn.2019.08.110.
- [4] Hong JT, Lee SW, Son BC, Sung JH, Kim IS, Park CK. Hypoglossal nerve palsy after posterior screw placement on the C-1 lateral mass. Case report. *J Neurosurg Spine* 2006;5(1):83–5. doi:10.3171/spi.2006.5.1.83.
- [5] Anderson LD, D'Alonzo RT. Fractures of the odontoid process of the axis. *J Bone Joint Surg Am* 1974;56(8):1663–74.
- [6] Goel A, Laheri V. Plate and screw fixation for atlanto-axial subluxation. *Acta Neurochir (Wien)* 1994;129(1-2):47–53. doi:10.1007/BF01400872.
- [7] Harms J, Melcher RP. Posterior C1-C2 fusion with polyaxial screw and rod fixation. *Spine (Phila Pa 1976)* 2001;26(22):2467–71. doi:10.1097/00007632-200111150-00014.
- [8] Jeanneret B, Magerl F. Primary posterior fusion C1/2 in odontoid fractures: indications, technique, and results of transarticular screw fixation. *J Spinal Disord* 1992;5(4):464–75. doi:10.1097/00002517-199212000-00012.
- [9] Ebraheim NA, Misson JR, Xu R, Yeasting RA. The optimal transarticular c1-2 screw length and the location of the hypoglossal nerve. *Surg Neurol* 2000;53(3):208–10. doi:10.1016/s0090-3019(00)00160-9.
- [10] Hong JT, Espinoza Orías AA, An HS. Anatomical study of the ventral neurovascular structures and hypoglossal canal for the surgery of the upper cervical spine. *J Clin Neurosci* 2020;71:245–249. doi:10.1016/j.jocn.2019.08.110.
- [11] Cirpan S, Sayhan S, Yonguc GN, Eyuboglu C, Güvençer M, Naderi S. Surgical anatomy of neurovascular structures related to ventral C1-2 complex: an anatomical study. *Surg Radiol Anat* 2018;40(5):581–6. doi:10.1007/s00276-017-1961-5.
- [12] Hong X, Dong Y, Yunbing C, Qingshui Y, Shizheng Z, Jingfa L. Posterior screw placement on the lateral mass of atlas: an anatomic study. *Spine (Phila Pa 1976)*. 2004;29(5):500–503. doi:10.1097/01.brs.0000113874.82587.33.
- [13] Hu Y, Kepler CK, Albert TJ, Yuan ZS, Ma WH, Gu YJ, et al. Accuracy and complications associated with the freehand C-1 lateral mass screw fixation technique: a radiographic and clinical assessment. *J Neurosurg Spine* 2013;18(4):372–7. doi:10.3171/2013.1.SPINE12724.
- [14] Sai Kiran NA, Sivaraju L, Vidyasagar K, Aryan S, Raj V, Rajagopal N, et al. Safety and accuracy of anatomic and lateral fluoroscopic-guided placement of C2 pars/pedicle screws and C1 lateral mass screws, and freehand placement of C2 laminar screws. *World Neurosurg* 2018;118:e304–15. doi:10.1016/j.wneu.2018.06.184.