

Retinal Vascular Caliber as a Biomarker for Diabetes Microvascular Complications

M. KAMRAN IKRAM, MD, PHD^{1,2,3,4}
 CAROL Y. CHEUNG, PHD^{1,2,4}
 MARA LORENZI, MD⁵
 RONALD KLEIN, MD, MPH⁶
 TERESA L.Z. JONES, MD⁷

TIEN YIN WONG, MD, PHD^{1,2,4,8}
 FOR THE NIH/JDRF WORKSHOP ON
 RETINAL BIOMARKER FOR DIABETES
 GROUP*

Globally, the number of people with diabetes is expected to reach 552 million in 2030 (1). Both the macrovascular (coronary artery disease, peripheral artery disease, and stroke) and microvascular (retinopathy, nephropathy, and neuropathy) complications of diabetes are major causes of morbidity and mortality (2). In theory, the long preclinical phase should provide a window to apply interventions that preempt progression to clinical disease, but to date no strategy achieves this aim for diabetes complications. Intensive control of hyperglycemia and blood pressure implemented with the imperfect means available today delays the appearance and reduces the severity of most complications, but does not prevent their development (3). Drugs such as fenofibrate have reduced the risk of diabetic retinopathy (DR) progression in type 2 diabetic patients, and inhibitors of the renin-angiotensin system (e.g., enalapril, losartan) have reduced the risk of progression in type 1 diabetic patients, but have not reduced the risk of DR incidence. Thus, new approaches are required to derive further benefit from current interventions

at an earlier stage of diabetes and to support the development of new interventions. One such approach is to identify biomarkers that will enable systematic patient surveillance and the identification of high-risk patients and also surrogate end points that will accelerate the discovery of new interventions.

The retinal vessels are early and prevalent targets of diabetic damage. They can be seen, measured, and tested by non-invasive means (4). Hence, investigators have attempted over the decades to identify early changes in the retinal vessels in diabetes and determine whether they could inform about the development of retinopathy and other complications. New measuring techniques have steadily come along, and others are in development. It seems timely to assess which concepts have emerged and which needs must be met toward fulfilling the expectation that retinal vessels may be able to predict the clinical onset of complications. The National Institutes of Health (NIH)/JDRF convened a workshop on 3–4 October 2011, in Bethesda, Maryland, titled “Seeing the Development of Diabetes Complications: Retinal Vessels

as Biomarkers.” From the presentations and discussions at the workshop emerged that, to date, changes in retinal vascular caliber appear to be among the earliest changes detected in the retina in diabetes. In addition, changes in vascular caliber have implications relevant to the pathophysiology of the vascular and end-organ damage observed in the eye and elsewhere in diabetes. Thus they fulfill important requirements for being investigated as biomarkers of diabetes complications (3). In this review we will focus on retinal vascular caliber as a potential biomarker for the three major microvascular complications of diabetes: retinopathy, nephropathy, and neuropathy.

CURRENT STATUS OF EARLY BIOMARKERS FOR DIABETES COMPLICATIONS

Biomarker definition and assessment

A biomarker is defined as “a characteristic that is objectively measured and evaluated as an indicator of normal biological processes, pathogenic processes, or pharmacological responses to a therapeutic intervention” (5). A biomarker useful in the prevention of a clinical end point (e.g., retinopathy) would 1) noninvasively detect early preclinical disease before the first clinical signs of the end point (e.g., microaneurysms) appear, 2) be causally linked or be an indicator of a causal mechanism that leads to the development of this end point, and 3) be consistently and strongly associated with the end point (5). Additional characteristics would expand its clinical usefulness: a marker informative for an individual patient would facilitate clinical decision making while a marker that reliably measures reversibility of the disease process could become a surrogate end point in drug development and preventative treatment. Finally, the incremental value of a novel biomarker over standard available biomarkers should be assessed not only with standard statistical measures such as the area under the curve (AUC) of the receiver operating characteristic curve or C-statistic, but also with more recently

From the ¹Singapore Eye Research Institute, Singapore National Eye Centre, Singapore; the ²Saw Swee Hock School of Public Health, National University of Singapore, Singapore; the ³Departments of Epidemiology and Ophthalmology, Erasmus Medical Center, Rotterdam, the Netherlands; the ⁴Department of Ophthalmology, National University of Singapore, Singapore; the ⁵Schepens Eye Research Institute and Department of Ophthalmology, Harvard Medical School, Boston, Massachusetts; the ⁶Department of Ophthalmology and Visual Sciences, School of Medicine and Public Health, University of Wisconsin, Madison, Wisconsin; the ⁷National Institute of Diabetes and Digestive and Kidney Diseases, National Institutes of Health, Bethesda, Maryland; and the ⁸Centre for Eye Research Australia, University of Melbourne, Melbourne, Victoria, Australia.

Corresponding author: Tien Yin Wong, ophwty@nus.edu.sg.

Received 2 August 2012 and accepted 30 September 2012.

DOI: 10.2337/dc12-1554

*A complete list of the NIH/JDRF Workshop on Retinal Biomarker for Diabetes Group collaborators and members can be found in the APPENDIX.

© 2013 by the American Diabetes Association. Readers may use this article as long as the work is properly cited, the use is educational and not for profit, and the work is not altered. See <http://creativecommons.org/licenses/by-nc-nd/3.0/> for details.

developed measures such as weighted net reclassification index (wNRI) and net benefit (NB) (5). Standard measures such as AUC give information on the overall improvement in discrimination over the full range of potential decision thresholds, whereas decision/analytic performance measures such as wNRI and NB indicate clinical usefulness over a smaller range of medically relevant thresholds. Furthermore, it is important to realize the distinction between the assessment of the quality of predictions from a model and decisions (or classifications) from a rule (5). This distinction between a “prediction model” and a “prediction rule” is unclear in most of the current literature. The key element is that going from a prediction model to a prediction rule requires the definition of a decision threshold or cutoff. Standard measures such as AUC deal with models and not rules. In contrast, these novel measures such as wNRI and NB try to incorporate medically relevant thresholds. A good model is, however, the first step in creating a good rule (5).

DR

DR does not currently have risk biomarkers that satisfy the above criteria, but there is research in several areas. Measurements of retinal hemodynamics at steady state show variable directions of the abnormalities in diabetic patients (6), in part attributable to the influence of blood glucose levels at the time of testing (7). Measurements of retinal hemodynamics in response to stimuli have shown abnormal autoregulation of retinal blood flow in DR patients, with flow increasing in parallel with the severity of retinopathy (8). However, further development of abnormal autoregulation as a biomarker will need to address the scant data available in patients without retinopathy, the inconsistency of abnormalities detected, and the longitudinal validation with the development of clinical retinopathy.

Measurements of retinal oxygen metabolism—which is thought to be affected in DR—using a noninvasive retinal oxymeter have shown elevated oxygen saturation levels in both retinal arterioles and venules in DR patients, suggesting that maldistribution and shunting and thus decreased delivery of oxygen from blood to tissue may be a feature of clinically overt DR. However, not all studies have been able to demonstrate these elevated oxygen saturation levels. Furthermore, it is not known whether retinal oxymetry is useful in the preclinical phase

of DR as an indicator of disease risk. Controversial is whether markers of inflammation and endothelial dysfunction increase in the systemic circulation before the appearance of clinical retinopathy, especially in type 1 diabetic patients (9,10), and it is unknown whether one or more of those abnormalities can predict clinical DR.

Fluorescein angiography has aided in the assessment of DR for several decades by enhancing the sensitivity of detection of the classical DR lesions: microaneurysms, increased capillary permeability, focal areas of capillary nonperfusion, and retinal neovascularization. However, the invasive nature of angiography discourages the use of this technique in the search for preclinical abnormalities with biomarker potential.

Diabetic nephropathy

Similar efforts are underway to discover biomarkers for diabetic nephropathy (11). Biomarkers such as albuminuria, which can predict rate of progression of overt nephropathy, have limited predictive precision at earlier stages of disease. Microalbuminuria, even after persisting for up to two years or more, can spontaneously regress to normoalbuminuria, and patients may remain microalbuminuric for many years without progression to overt diabetic nephropathy. Therefore, microalbuminuria, although a strong indicator of increased diabetic nephropathy risk, is not a sufficiently reliable predictor of diabetic nephropathy, and other biomarkers are needed to supplement the measure of urinary albumin in diabetic patients (12). Kidney biopsy samples can show early disease but the predictive power is limited and the biopsy procedure is too invasive for routine use (13,14). Some promising diabetic nephropathy biomarkers currently being studied include the decline of glomerular filtration rate and serum uric acid (11).

Diabetic neuropathy

Diabetic neuropathy encompasses a wide array of clinical conditions including autonomic neuropathy and distal sensorimotor polyneuropathy. For the latter, two biomarkers show potential in the detection of damage to small, unmyelinated fibers, an early sign of diabetic neuropathy (15). The intraepidermal nerve fiber density (IENFD) from 3-mm skin biopsies is a sensitive but invasive method for detecting early changes in neuropathy (16). Corneal confocal microscopy is a

noninvasive ophthalmic method that detects corneal nerve fiber abnormalities in early and more advanced neuropathy and that relates to IENFD and measures of neuropathy (17). More recently corneal confocal microscopy has shown an improvement in corneal nerve abnormalities but with no change in IENFD or electrophysiology 12 months after pancreas transplantation in patients with type 1 diabetes (18).

ABNORMALITIES OF RETINAL VASCULAR CALIBER AS A BIOMARKER OF DIABETES MICROVASCULAR COMPLICATIONS

—Since the invention of the ophthalmoscope nearly 150 years ago and the first reports of retinal vascular changes (e.g., retinal arteriolar narrowing, venular widening, hemorrhages, microaneurysms) being linked with systemic diseases, numerous studies have advanced the concept that retinal measurements may predict a range of systemic diseases. Within the last decade, these retinal measurements have become increasingly sophisticated and computer based, leading to the development of software that measures quantitatively retinal arteriolar and venular calibers. Typically, these softwares (e.g., Interactive Vessel Analysis [IVAN]) measure the width of the erythrocyte column, which approximates the internal lumen diameter. These are usually summarized and expressed as the central retinal artery (CRAE) and the central retinal vein (CRVE) equivalents (Fig. 1) (4). These software methods have been applied in multiple population-based studies, comprising more than 50,000 people from different racial/ethnic groups in the general population and diabetic cohorts. These data have provided a clearer understanding of epidemiology, risk factor associations, and prognostic significance of “static measurements of retinal vascular caliber.” The broad understanding is that changes in retinal vascular caliber reflect a range of subclinical pathophysiologic responses to hyperglycemia, hypertension, inflammation, hypoxia, and endothelial dysfunction, and can predict not only different diabetes microvascular complications, but also stroke and coronary heart disease (19–22). This review will not cover the latter relationship of retinal vascular caliber with stroke and coronary heart disease.

Retinal vascular caliber and DR

In terms of diabetes microvascular complications, studies have primarily focused

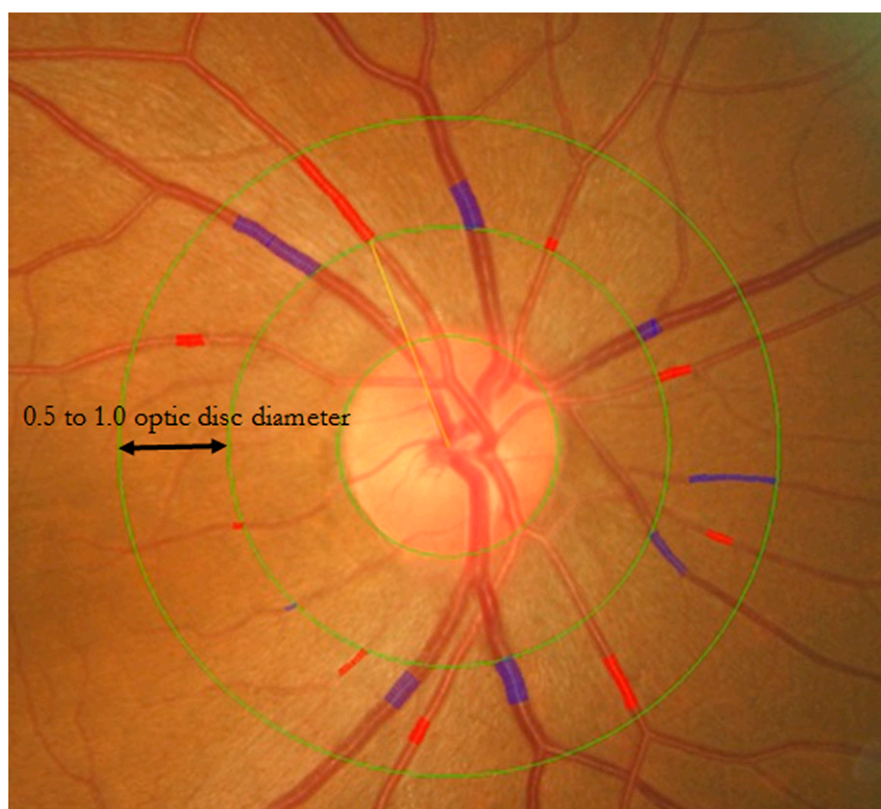

Figure 1—Retinal fundus photograph assessed quantitatively by the IVAN software (University of Wisconsin). The measured area of retinal vascular parameters was standardized as the region from 0.5 to 1.0 disc diameters away from the disc margin. Retinal arteriolar and venular calibers were summarized as CRAE and CRVE, respectively, from retinal fundus photograph. CRAE and CRVE were defined based on the revised Knudtson-Parr-Hubbard formula.

on the association between retinal vascular calibers and the risk of DR both in type 1 and type 2 diabetes. Table 1 presents an overview of these studies (23–27). For type 1 diabetes, the Wisconsin Epidemiologic Study of Diabetic Retinopathy (WESDR) was the first to investigate the relationship of arteriolar and venular caliber to the incidence and progression of DR (23). In this study, while controlling for glycosylated hemoglobin A_{1c}, duration of diabetes, blood pressure level, and other risk factors, larger retinal arteriolar and venular calibers measured at baseline were associated with an increased risk of progression of DR but were not associated with the 4-year incidence of DR. Similarly, in the New Jersey 725 study, which included 468 African Americans, neither arteriolar nor venular calibers were related to incident DR (24). In contrast, a study of 645 Australian children and adolescents (aged 12–20 years) with type 1 diabetes who were initially free of retinopathy showed that larger retinal arteriolar caliber at baseline was associated with a more than threefold higher

risk of DR after a median follow-up of 2.5 years (hazard rate ratio [HR] 3.44 [95% CI 2.08–5.66]) (25). The increased risk was recorded after adjusting for a variety of vascular risk factors, diabetes duration, glycemic control, and retinal arteriolar caliber (25). In this study no association was found for retinal venular caliber with incident retinopathy. In summary, there are indications that retinal vascular calibers may be associated with the risk of both incidence and progression of DR-related outcomes in type 1 diabetes, though the data are not entirely consistent.

For type 2 diabetes, data from WESDR and Australian Diabetes, Obesity and Lifestyle (AusDiab) studies show that neither retinal arteriolar nor venular calibers measured at baseline were associated with the incidence or progression of DR (26,27). Several factors may underlie the discrepancy between the findings in patients with type 1 and 2 diabetes. Although four out of these five studies used the same procedures and definitions to obtain DR cases, differences across these studies in the distribution of age and

other cardiovascular risk factors, sample sizes, and follow-up periods may partially explain this discrepancy. In these studies, patients with type 1 diabetes were below the age of 30 years, whereas those with type 2 diabetes had a mean age of >60 years. Accompanying this wide age distribution, the most important difference between patients with type 1 and 2 diabetes was the prevalence of hypertension. In WESDR, for example, 74% of the patients with type 2 diabetes were diagnosed with hypertension, whereas the corresponding figure in type 1 diabetes patients was about 17% (23,27). Because the effect of hypertension on retinal vascular calibers may be in the opposite direction than found in diabetes, this confounding effect of hypertension may have led to the inconclusive results found in type 2 diabetes.

In addition to measuring the predictive capabilities of baseline retinal vascular calibers, two studies have examined whether longitudinal changes in these calibers are related to the risk of DR. Widening of the venules over the first 4 years of WESDR was independently associated with increased risk of subsequent 6-year incidence and progression of DR as well as incidence of proliferative DR and diabetic macular edema in both type 1 and 2 diabetes, which is similar to the results from a Swedish study (28,29). In view of the wide range of calibers normally exhibited by retinal vessels, changes occurring over time in the same individual may be more robust and sensitive informers of ongoing vascular processes than the mere caliber at baseline. Additional prospective studies should be undertaken to confirm and investigate a role for longitudinal changes in retinal vascular calibers in predicting the risk of DR.

Retinal vascular caliber and diabetic nephropathy

The Renin Angiotensin System Study (RASS), a randomized controlled clinical trial of angiotensin-converting enzyme inhibition or angiotensin receptor blockade versus placebo in normoalbuminuric, normotensive people with type 1 diabetes, showed that both retinal arteriolar caliber at baseline and changes in retinal arteriolar and venular calibers over a 5-year period are independently related to changes in renal structural parameters (such as glomerular basement membrane width, mesangial matrix fractional volume, and glomerulopathy index) measured in sequential biopsies over the same time period (30). These renal structural

Table 1—Relationship of baseline retinal vascular calibers with incidence and progression of DR in type 1 and type 2 diabetes

Study	Age range at baseline	DR ascertainment & definitions	Mean follow-up time	Retinal vessel caliber	Incidence of DR [‡]	Incidence of PDR [‡]	Incidence of ME [‡]	Progression of DR [‡]	Progression to PDR [‡]
Type 1 diabetes									
WESDR (USA) (23) (n = 891)	<30 years	7-field retinal images;	4 years*	CRAE 4th vs. 1st quartile CRVE 4th vs. 1st quartile	2.03 (0.82–5.03) 1.42 (0.47–4.24)	1.18 (0.46–.04)	S	2.04 (1.20–3.47) 2.33 (1.37–3.95)	—
New Jersey 725 (USA) (24) (n = 468)	27.2 (10.7) years [†]	7-field retinal images;	6 years	CRAE 1st vs. 4th quartile CRVE 4th vs. 1st quartile	NS	NS	NS	NS	1.99 (0.87–4.55) 4.63 (2.02–10.63)
Children's Hospital Westmead (Australia) (25) (n = 645)	12–20 years	7-field retinal images;	2.5 years	CRAE 4th vs. 1st quartile CRVE 4th vs. 1st quartile	3.44 (2.08–5.66) 0.78 (0.50–1.23)	—	—	—	—
Type 2 diabetes									
WESDR (USA) (26) (n = 962)	≥30 years	7-field retinal images;	10 years	CRAE 1st vs. 4th quartiles CRVE 4th vs. 1st quartiles	0.64 (0.41–1.01) 1.41 (0.92–2.15)	—	0.70 (0.37–1.34) 0.66 (0.38–1.17)	0.76 (0.54–1.06) 1.07 (0.79–2.25)	0.80 (0.40–1.60) 1.33 (0.79–2.25)
AusDiab (Australia) (27) (n = 243)	≥25 years	2-field retinal images; Simplified Wisconsin System	5 years	CRAE 4th vs. 1st quartiles CRVE 4th vs. 1st quartiles	3.41 (0.69–6.80)	—	—	—	—

ME: macular edema; PDR: proliferative DR; RR: relative risk; NS: nonsignificant; RR not reported; S: significant; RR not reported. *Associations also examined with 10- and 14-year follow-up, however, only RR for 4-year incidence and progression reported. [†]Mean age (SD). [‡]Values are RR (95% CI).

parameters reflect important pathological processes which, if progressive, ultimately lead to renal dysfunction in diabetic nephropathy. Among 927 persons with type 2 diabetes from WESDR, retinal venular caliber was independently associated with the 10-year incidence of diabetic nephropathy, which was defined as the development of gross proteinuria, initiation of renal dialysis, or renal transplantation during follow-up (26). Compared with persons in the first quartile of retinal venular caliber, those in the fourth were nearly twice as likely to develop diabetic nephropathy (HR 2.08 [95% CI 1.47–2.94]). In contrast, retinal arteriolar caliber was not related to the risk of diabetic nephropathy (26). In the same WESDR study, these associations were also confirmed in 557 patients with type 1 diabetes and 16-year incidence of gross proteinuria and renal insufficiency (31).

Retinal vascular caliber and diabetic neuropathy

Thus far, only a few studies have examined the link between retinal vascular caliber and diabetic neuropathy. A study of a multiethnic Asian population with diabetes showed that wider arteriolar caliber, but not venular caliber, was independently and cross-sectionally associated with peripheral neuropathy as defined from neurothesiometer or monofilament sensory testing (multivariable adjusted odds ratio [OR] 2.81 [95% CI 1.38–5.73]) (32). In contrast, a population-based Danish study among 208 long-surviving type 1 diabetic patients showed that persons with smaller retinal arteriolar caliber were more likely to have nephropathy (OR per SD decrease 2.17 [95% CI 1.29–3.68]), but not neuropathy (1.10 [0.70–1.71]) (31). Retinal venular caliber was not associated with nephropathy or neuropathy (33). Prospective studies are needed to define the link between retinal vascular caliber and diabetic neuropathy.

NOVEL STATIC RETINAL VESSEL CHARACTERISTICS AS BIOMARKERS FOR DIABETES COMPLICATIONS

While most current studies have focused on the measurement of retinal vascular caliber, there are other measurable parameters in the retinal vascular architectural network (34). Changes in the retinal vascular architecture may result in impaired space-filling and microcirculatory transport,

nonuniform shear distribution across bifurcations, and reduced energy efficiency in blood flow and may therefore be an indicator of early disease (35,36).

A number of retinal vascular “architectural” parameters, including fractal dimension, tortuosity, branching angle and length-to-diameter ratio, and measures of bifurcation optimality have been studied using computer-assisted software (37,38). Figures 1–4 show a currently available semiautomated computer-based program, the Singapore I Vessel Assessment (SIVA), that measures a spectrum of retinal vascular parameters in addition to vascular caliber.

At present, the clinical utility of changes in retinal vascular architecture is limited, as it remains unknown what constitutes an abnormal or pathological value of these retinal vascular parameters. Recent studies indicate that some of the newer quantitative retinal vascular parameters are associated with diabetes (39) and associated complications, such as hypertension (40), stroke (41), and cardiovascular mortality (42). However, at present there are few studies on the relationship of these measures with DR and other microvascular complications. Furthermore, the small number of studies, lack of overall consistency, the relatively small increase in predictive value, and the costs of measuring these additional vascular characteristics, limit extending their use more broadly and point to the need for more research in this area.

For example, fractal geometry can be used to quantify the branching pattern that exhibits the property of self-similarity (Fig. 2). Fractal parameters may be a useful way of determining microvascular density by assessing its space-filling properties. To date, although fractal analysis studies of the retinal vasculature have demonstrated

excellent reproducibility (43), the ability of this method to predict clinical outcomes is less clear. Cross-sectional studies have identified fairly weak relationships (relative risks ranging from 1.37–1.45 per SD decrease in fractal dimension) with clinical disease (chronic kidney disease, diabetic macroalbuminuria, and diabetic neuropathy) (39,44), while a prospective study found no association between retinal vascular fractal dimension and incident retinopathy (45). The use of fractals in assessing retinal vasculature may be limited by several factors 1) vascular beds are multifractal rather than single fractal and 2) differences in the various methods used to image and compute fractal dimension (43,45,46).

The tortuosity of vessels is difficult to quantify (Fig. 3) and multiple measures have been described (e.g., simple, curvature) (42). Nonetheless, some cross-sectional studies show modest associations between tortuosity and DR, and between tortuosity and diabetic kidney disease (47,48). Other geometric parameters (Fig. 4), such as the length-to-diameter ratio, optimality deviation, and branching angle, also demonstrate modest associations with retinopathy in cross-sectional and prospective studies (49), as well as with cerebral white matter hyperintensities and coronary heart disease (50). Thus, although advances in image analysis provide an opportunity to quantify additional aspects of retinal vasculature, the value of these measurements as biomarkers or surrogate end points is not yet known.

ABNORMALITIES OF RETINAL VASCULAR CALIBER AS BIOMARKERS OF DIABETES COMPLICATIONS—DYNAMIC MEASUREMENTS

Recent functional studies have tested the behavior of retinal vessels in response to stimuli and




Figure 2—a: Fractal dimension is a measure of a fractal structure that exhibits the property of self-similarity, characterizing the distribution of the branching vascular system in two-dimensional space. In SIVA, fractal dimension is calculated from a skeletonized line tracing that uses the box-counting method and divides each digital photograph into a series of squares for various side lengths, and the number of boxes is counted. b: Low fractal dimension. c: High fractal dimension.

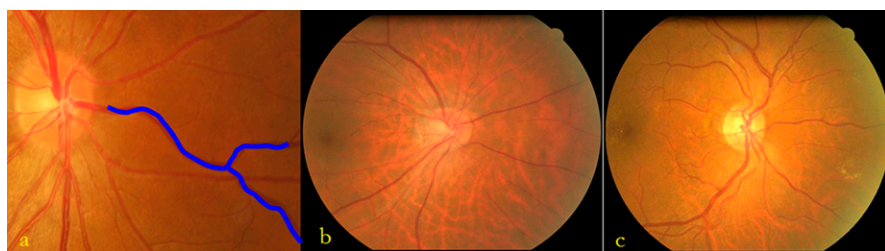


Figure 3—a: Simple tortuosity and curvature tortuosity are defined to quantify retinal vascular tortuosity in SIVA. Simple tortuosity is estimated as the actual path length of the vessel segment divided by the straight line length. Curvature tortuosity is derived from the integral of the curvature square along the path of the vessel, normalized by the total path length, which takes into account the bowing and points of inflection. b: Low tortuosity. c: High tortuosity.

measured the changes in vascular diameter with the laser Doppler flowmeter or the dynamic retinal vessel analyzer (IMEDOS, Germany). Their results complement the static measurements in identifying retinal vascular caliber changes as early consequences of diabetes with the potential to become biomarkers of risk for diabetes complications. The functional abnormalities detected in patients with relatively well-controlled type 1 diabetes

and no retinopathy consist of reduced or absent dilation of retinal vessels in response to light stimulation and reduced or absent constriction of retinal arteries in response to increased intraluminal pressure (51–54).

Flickering light stimulates activity of the neural retina and the increased metabolic demand activates autoregulatory mechanisms that dilate retinal blood vessels and enhance blood flow. Whereas in healthy individuals retinal arterioles and venules increase their diameter by 2–4% in response to diffuse luminance flicker, diabetic patients show a minimal or absent response to this stimulus (51,52). The relative reduction in retinal vessel dilation seen in diabetic patients occurs in vessels with resting diameters not

different from those of normal control subjects and may therefore precede morphological widening of retinal vessels. The dilation of retinal vessels to flickering light reflects both retinal neural activity and the vascular response, hence the reduced or absent dilation seen in diabetes could be due to defects in either or both of these components.

Responses to increased intraluminal pressure are easier to attribute to vascular mechanisms. Normal arteries respond to elevations in intraluminal pressure with constriction and to pressure reduction with dilation via mechanisms that are inherent to vascular smooth muscle and independent of neural, metabolic, and hormonal influences. This behavior is termed the myogenic response (53). Figure 5 illustrates the role of the normal myogenic response in maintaining constant retinal blood flow when ocular perfusion pressure is increased by a change in posture from sitting to reclining. A clinical study showed that when such postural change was tested in well-controlled patients with type 1 diabetes without retinopathy only about half of the 17 patients examined manifested the normal vasoconstrictor response to increased pressure. The other half reproducibly failed to constrict the retinal arteries, and some showed paradoxical vasodilation (54). Of note, in the same study, only the patients who failed to vasoconstrict in

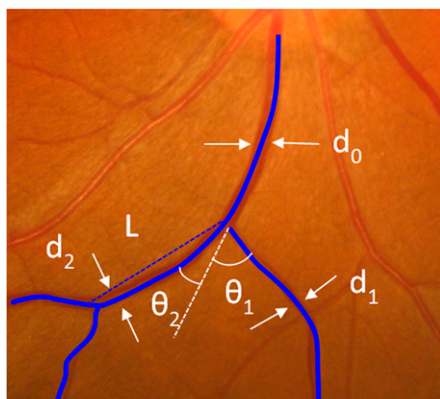


Figure 4—A series of parameters are defined to quantify bifurcation of retinal vessels in SIVA (not bounded by the measured zone). At each bifurcation, the widths of the trunk vessel (d_0) and its two branching vessels (d_1 , d_2) are measured, as well as the branching angle. Branching angle ($\theta_1 + \theta_2$) is defined as the first angle subtended between two daughter vessels at each bifurcation. Angular asymmetry is defined as the difference between two daughter angles ($\theta_1 - \theta_2$). Branching coefficient is defined as the ratio of the branching vessel widths to trunk vessel width $(d_1 + d_2)^2/d_0^2$. Asymmetry ratio is defined as the ratio of the two branching vessel widths d_2^2/d_1^2 . Junctional exponent deviation is defined using the value of three in healthy vascular networks $[(d_0^3 - d_1^3 - d_2^3)^{1/3}]/d_0$. Length-to-diameter ratio is defined as the ratio of the length between two branching points to the trunk vessel width (L/d_0).

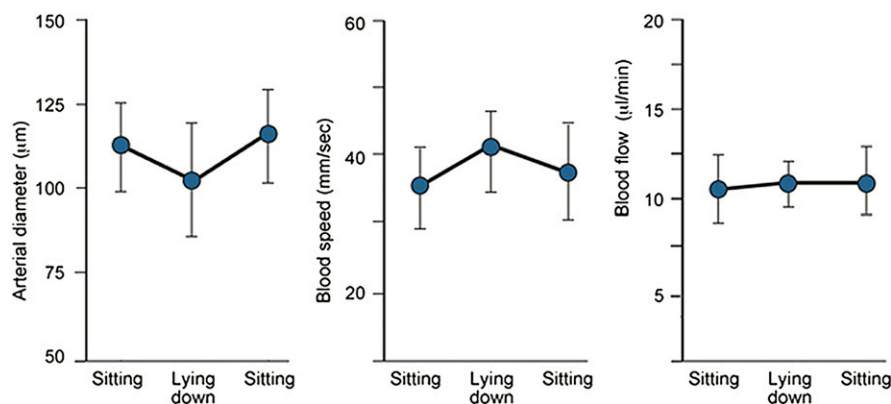


Figure 5—Normal response of retinal arterial diameter, blood speed, and blood flow to a postural change that increases ocular perfusion pressure. The hemodynamic parameters were measured using a laser Doppler flowmeter in the superior temporal retinal artery of healthy subjects while sitting (baseline), after lying down for 30 min, and again after sitting for 20 min. The change in posture from sitting to reclining increased ocular perfusion pressure and elicited the myogenic response, measured as a decrease in the arterial diameter. The arterial diameter decreased in each subject, the decrease ranging from -2.8 to -9.9% of baseline values. Blood speed increased in each subject, and blood flow—calculated as the product of the cross-sectional area of the artery at the measurement site and the average blood speed—did not change. Values are the means \pm SD of measurements in 11 subjects. (A high-quality color representation of this figure is available in the online issue.)

response to pressure showed an increase in resting arterial diameter over a 12-month period (54), suggesting that the loss of myogenic responsiveness may be an initial step in the process that widens the caliber of retinal vessels. According to Poiseuille law, flow is related to the fourth power of the vessel radius. Thus, the loss of myogenic response and subsequent increased arterial diameter would permit unphysiologically high blood flow to reach the capillaries and affect the regulation of hydrostatic pressure and eventually the integrity of the capillary wall. Further studies are required to test if the defective myogenic response is in fact causally linked to the development of clinical retinopathy and to validate its usefulness as a biomarker of risk. Also to be investigated is whether an abnormal myogenic response of retinal vessels to pressure could be a biomarker for the development of diabetic nephropathy because the kidney, akin to the retina, has autoregulatory mechanisms to maintain stable blood flow despite variations in systemic blood pressure (55).

NEWER METHODS FOR DYNAMIC STUDIES OF RETINAL VESSELS

—Further, the development of retinal vascular caliber changes as a robust biomarker of risk for retinopathy and other microvascular complications of diabetes depends, in part, on the capability to detect in vivo subclinical changes caused by diabetes. Instruments and strategies that can probe the vessels with enhanced resolution and functional yield will be able to reconstruct mechanisms and consequences of the early widening of retinal vascular caliber and to identify additional early abnormalities with biomarker potential. The newer approaches briefly described below are poised to widen the accessibility of hemodynamic measurements, permit observations of discrete vascular structures at very high resolution, and test molecular events occurring on the vascular endothelium.

Doppler Fourier domain optical coherence tomography to measure retinal blood flow

Doppler Fourier domain optical coherence tomography (OCT) imaging is now widely used for clinical purposes, and the continuous enhancement of the speed of image acquisition and resolution are

making OCT an important tool for dynamic measurements. As a coherent detection technique, OCT can detect the Doppler frequency shift of backscattered light and thus measure the speed of moving objects such as erythrocytes that scatter light and thereby provide information on blood flow velocity. The high-speed and ultrahigh-speed Fourier domain OCT enables acquisition of blood velocity and vessel volumes that permit measurements of pulsatile blood flow. Comparisons in normal and diseased human retinas have been performed (56). The Doppler OCT, which is still in development at this time, may eventually offer significant advantages over the methods used to date to measure retinal blood flow. By measuring flow over the central retinal artery or at vessels at the optic nerve head, Doppler OCT can provide total retinal blood flow as opposed to flow in individual vessels. The measurements are depth-resolved, increasing the accuracy of the data. The blood flow measuring capability is compatible with existing standard OCT patient interfaces, and new strategies and software will likely render the blood flow calculations completely automatic and facilitate the testing of its use as a risk biomarker for diabetes complications (57). This will make it possible to test and compare retinal autoregulatory responses and their longitudinal changes in larger cohorts of patients using standardized instruments and methods as opposed to instruments with different characteristics developed in different research laboratories.

Adaptive optics for detailed live imaging of human retinal vessels

The adaptive optics approach is based upon the optical properties of the eye and is applied to small fields at any particular instant of measurement. Derived from astronomical research tools, the technique offers the opportunity to visually “correct” for the imperfect optics of the eye that result in a blurred point spread function. Real-time, confocal scanning laser ophthalmoscope with adaptive optics currently achieves with research-grade instruments resolution on the order of 2 microns in the human retina. Structural imaging of the retina using adaptive optics enables the visualization of vascular walls, vascular crossings, vascular cells, nerve fiber crossings, cells in the vicinity of arcades, and capillaries (Fig. 6) (58). Dynamic blood flow can also be measured with this approach, and flow maps can be obtained (59,60). Observations are restricted to small fields at any given time, but this potential limitation is counterbalanced by the high resolution and dynamic nature of the imaging. Adaptive optics could be used to gain new insights into diabetes microvascular complications through correlations between vascular cells or vessel function and topography within the vascular network and within the retina. Currently only a few adaptive optics systems exist worldwide, but with the recent appearance of commercial instruments there will be more widespread testing of this technology in the pursuit of identifying the subclinical changes that

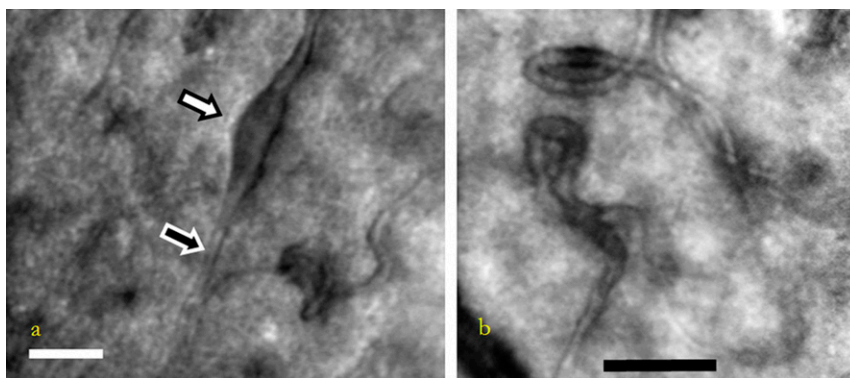


Figure 6—Example of adaptive optics imaging results from diabetic patients. a: Example of the variability of capillary diameter in a diabetic patient. A single capillary can range from a normal caliber (black-filled arrow) to distended (white-filled arrow) within a few hundred microns. Scale bar = 50 microns. b: Examples of capillary tortuosity and remodeling. Here we see capillaries that are tortuous and reverse directions. Also visible are the variations in capillary diameter as seen in panel a. Scale bar = 50 microns.

may become biomarkers of diabetes complications.

Fluorescent nanoparticle imaging to probe retinal vascular endothelium in vivo

The transition from physiology to pathology is likely to involve first a sequence of molecular changes, eventually followed by cellular changes and structural damage. Therefore, capturing the initial or very early molecular changes occurring in the endothelium of retinal vessels in diabetes is of keen interest to the field. Recently, new tools have been introduced that measure in vivo monomolecular interactions using highly sensitive probes (61). The probes mimic the interaction of immune cells with the retinal endothelium, a common event in the pathogenesis of several eye diseases, including early DR. The transient interaction of these probes with the endothelial ligands is detected by light-based fundus imaging, such as in scanning laser ophthalmoscopy. This technology has permitted the quantitative evaluation of discrete molecular interactions on the endothelium of rodent retinal vessels with a sensitivity that is comparable to immunohistochemistry or PCR (62). A current challenge is to bring the technique to testing in humans. The strategy is to custom design molecular probes using biodegradable polymers in combination with fluorophores that are approved for human use. The advantages of sensitivity and specificity inherent in the molecular probes, the quantitative nature of the attained signal, and the automated image processing could make this technique a unique tool for screening and monitoring early cellular events in diabetic retinal microangiopathy, as well as measuring early responses to therapeutic interventions. These, in turn, could expand the number of potential biomarkers of retinopathy risk and early interventions to be tested.

CONCLUSIONS—Retinal blood vessels can be noninvasively observed and monitored and show changes reflecting early pathophysiology of diabetes, supporting the concept that these changes could translate into biomarkers of risk and surrogate targets for preemptive interventions. In experimental diabetic animals, the investigation has yielded a large number of biochemical, molecular, and cellular changes, and some of the changes were proven to be of pathogenic importance in the development of experimental

DR. But translation to human diabetes has been slow and difficult, with the result that to date clinical medicine does not have one validated and usable biomarker of retinopathy risk nor drugs to help prevent the development of retinopathy.

Over the last decade, advances in retinal imaging techniques have allowed the measurement and quantitative analysis of static retinal vessel characteristics. Testing of these characteristics in large population-based studies shows that the caliber of the retinal vessels provides information on the risk for DR and other microvascular complications beyond traditional risk factors. Dynamic studies contribute complementary and mechanistic data showing that defective vasoconstrictor and vasodilator responses to stimuli are often the first detectable changes in the retinal vessels of diabetic patients without retinopathy. One direction that builds on this information is to continue to develop better and newer approaches to retinal vascular imaging and to enhance the power of detection and the accuracy of quantification of retinal microvascular changes. A second direction is to seek validation for the promising candidate biomarkers. For example, longitudinal changes in retinal vascular caliber and dynamic responses to stimuli should be tested against the development of clinical retinopathy as well as other microvascular complications of diabetes. A third strategy is to quantify early molecular changes using highly sensitive and specific molecular probes. The results of these studies will tell whether retinal vessels can be used to “see” the early development of diabetes complications. Positive results will generate the much sought-after opportunity to implement cost-effective preventative and interventional strategies.

Acknowledgments—No potential conflicts of interest relevant to this article were reported.

M.K.I., C.Y.C., and M.L. wrote the manuscript. R.K., T.L.Z.J., and T.Y.W. reviewed and edited the manuscript. All authors and collaborators approved the final version of the manuscript.

APPENDIX—Collaborators and members of the NIH/JDRF Workshop on Retinal Biomarker for Diabetes Group (in alphabetical order): Michael Abramoff, Shashi Amur, David Antonetti, Kerstin Bettermann, Julia Brosnan, Brian Bucca,

Stephen Burns, Roberto Calle, Emily Chew, Mary Frances Cotch, Ronald P. Danis, Alison Davis, Peter J. Dyck, Gilbert T. Feke, Saul Genuth, Juan Grunwald, Anthony M. Haegerty, Ali Hafezi-Moghadam, Sonia Hernandez, Eleanor Hoff, Alun D. Hughes, Hillary Keenan, George L. King, Barbara E. Klein, John Lachin, Mary Lott, David Maahs, Rayaz A. Malik, Michael Mauer, Kevin McGeechan, Taiji Nagaoka, Helen Nickerson, Trevor J. Orchard, Patricia Parsons-Wingerter, Bruce Perkins, Weier Qi, Marian Rewers, Leopold Schmetterer, Richey Sharrett, Grace Shen, Angela Shore, Anne K. Sjolie, Janet Snell-Bergeon, Frank Swenson, Maria Vassileva, and David Vera.

References

1. Whiting DR, Guariguata L, Weil C, Shaw J. IDF diabetes atlas: global estimates of the prevalence of diabetes for 2011 and 2030. *Diabetes Res Clin Pract* 2011;94:311–321
2. Terry T, Ravavikar K, Chokrungravanon N, Reaven PD. Does aggressive glycemic control benefit macrovascular and microvascular disease in type 2 diabetes? Insights from ACCORD, ADVANCE, and VADT. *Curr Cardiol Rep* 2012;14:79–88
3. Blonde L. Benefits and risks for intensive glycemic control in patients with diabetes mellitus. *Am J Med Sci* 2012;343:17–20
4. Hubbard LD, Brothers RJ, King WN, et al. Methods for evaluation of retinal microvascular abnormalities associated with hypertension/sclerosis in the Atherosclerosis Risk in Communities Study. *Ophthalmology* 1999;106:2269–2280
5. Steyerberg EW, Pencina MJ, Lingsma HF, Kattan MW, Vickers AJ, Van Calster B. Assessing the incremental value of diagnostic and prognostic markers: a review and illustration. *Eur J Clin Invest* 2012;42:216–228
6. Pournaras CJ, Rungger-Brändle E, Riva CE, Hardarson SH, Stefansson E. Regulation of retinal blood flow in health and disease. *Prog Retin Eye Res* 2008;27:284–330
7. Bursell SE, Clermont AC, Kinsley BT, Simonson DC, Aiello LM, Wolpert HA. Retinal blood flow changes in patients with insulin-dependent diabetes mellitus and no diabetic retinopathy. *Invest Ophthalmol Vis Sci* 1996;37:886–897
8. Kohner EM, Patel V, Rassam SM. Role of blood flow and impaired autoregulation in the pathogenesis of diabetic retinopathy. *Diabetes* 1995;44:603–607
9. Calles-Escandon J, Cipolla M. Diabetes and endothelial dysfunction: a clinical perspective. *Endocr Rev* 2001;22:36–52
10. Schram MT, Chaturvedi N, Schalkwijk CG, Fuller JH, Stehouwer CD; EURODIAB

- Prospective Complications Study Group. Markers of inflammation are cross-sectionally associated with microvascular complications and cardiovascular disease in type 1 diabetes—the EURODIAB Prospective Complications Study. *Diabetologia* 2005;48:370–378
11. Jim B, Santos J, Spath F, Cijiang He J. Biomarkers of diabetic nephropathy, the present and the future. *Curr Diabetes Rev* 2012;8:317–328
 12. Perkins BA, Ficociello LH, Silva KH, Finkelstein DM, Warram JH, Krolewski AS. Regression of microalbuminuria in type 1 diabetes. *N Engl J Med* 2003;348:2285–2293
 13. Thomas MC. Pathogenesis and progression of proteinuria. *Contrib Nephrol* 2011;170:48–56
 14. Cohen-Bucay A, Viswanathan G. Urinary markers of glomerular injury in diabetic nephropathy. *Int J Nephrol* 2012;2012:146987
 15. Tesfaye S, Boulton AJ, Dyck PJ, et al.; Toronto Diabetic Neuropathy Expert Group. Diabetic neuropathies: update on definitions, diagnostic criteria, estimation of severity, and treatments. *Diabetes Care* 2010;33:2285–2293
 16. Narayanaswamy H, Facer P, Misra VP, et al. A longitudinal study of sensory biomarkers of progression in patients with diabetic peripheral neuropathy using skin biopsies. *J Clin Neurosci* 2012;19:1490–1496
 17. Quattrini C, Tavakoli M, Jeziorska M, et al. Surrogate markers of small fiber damage in human diabetic neuropathy. *Diabetes* 2007;56:2148–2154
 18. Tavakoli M, Mitu-Pretorian M, Petropoulos IN, et al. Corneal confocal microscopy detects early nerve regeneration in diabetic neuropathy after simultaneous pancreas and kidney transplantation. *Diabetes* 2013;62:254–260
 19. Ikram MK, Witteman JC, Vingerling JR, Breteler MM, Hofman A, de Jong PT. Retinal vessel diameters and risk of hypertension: the Rotterdam Study. *Hypertension* 2006;47:189–194
 20. Wong TY. Is retinal photography useful in the measurement of stroke risk? *Lancet Neurol* 2004;3:179–183
 21. Wong TY, Klein R, Sharrett AR, et al. Retinal arteriolar narrowing and risk of coronary heart disease in men and women. The Atherosclerosis Risk in Communities Study. *JAMA* 2002;287:1153–1159
 22. Klein R, Klein BE, Moss SE, Wong TY, Sharrett AR. Retinal vascular caliber in persons with type 2 diabetes: the Wisconsin Epidemiological Study of Diabetic Retinopathy: XX. *Ophthalmology* 2006;113:1488–1498
 23. Klein R, Klein BE, Moss SE, et al. The relation of retinal vessel caliber to the incidence and progression of diabetic retinopathy: XIX: the Wisconsin Epidemiologic Study of Diabetic Retinopathy. *Arch Ophthalmol* 2004;122:76–83
 24. Roy MS, Klein R, Janal MN. Retinal venular diameter as an early indicator of progression to proliferative diabetic retinopathy with and without high-risk characteristics in African Americans with type 1 diabetes mellitus. *Arch Ophthalmol* 2011;129:8–15
 25. Cheung N, Rogers SL, Donaghue KC, Jenkins AJ, Tikellis G, Wong TY. Retinal arteriolar dilation predicts retinopathy in adolescents with type 1 diabetes. *Diabetes Care* 2008;31:1842–1846
 26. Klein R, Klein BE, Moss SE, Wong TY. Retinal vessel caliber and microvascular and macrovascular disease in type 2 diabetes: XXI: the Wisconsin Epidemiologic Study of Diabetic Retinopathy. *Ophthalmology* 2007;114:1884–1892
 27. Rogers SL, Tikellis G, Cheung N, et al. Retinal arteriolar caliber predicts incident retinopathy: the Australian Diabetes, Obesity and Lifestyle (AusDiab) study. *Diabetes Care* 2008;31:761–763
 28. Klein R, Myers CE, Lee KE, Gangnon R, Klein BE. Changes in retinal vessel diameter and incidence and progression of diabetic retinopathy. *Arch Ophthalmol* 2012;130:749–755
 29. Falck A, Laatikainen L. Retinal vasodilation and hyperglycaemia in diabetic children and adolescents. *Acta Ophthalmol Scand* 1995;73:119–124
 30. Klein R, Knudtson MD, Klein BE, et al. The relationship of retinal vessel diameter to changes in diabetic nephropathy structural variables in patients with type 1 diabetes. *Diabetologia* 2010;53:1638–1646
 31. Wong TY, Shankar A, Klein R, Klein BE. Retinal vessel diameters and the incidence of gross proteinuria and renal insufficiency in people with type 1 diabetes. *Diabetes* 2004;53:179–184
 32. Sabanayagam C, Tai ES, Lee J, Lim SC, Wong TY. Retinal vessel caliber and peripheral neuropathy in diabetic participants. *Microcirculation* 2010;17:297–302
 33. Grauslund J, Hodgson L, Kawasaki R, Green A, Sjølie AK, Wong TY. Retinal vessel calibre and micro- and macrovascular complications in type 1 diabetes. *Diabetologia* 2009;52:2213–2217
 34. Pries AR, Secomb TW. Modeling structural adaptation of microcirculation. *Microcirculation* 2008;15:753–764
 35. Murray CD. The physiological principle of minimum work: I. The vascular system and the cost of blood volume. *Proc Natl Acad Sci USA* 1926;12:207–214
 36. Rossiti S, Löfgren J. Optimality principles and flow orderliness at the branching points of cerebral arteries. *Stroke* 1993;24:1029–1032
 37. Witt NW, Chapman N, Thom SA, Stanton AV, Parker KH, Hughes AD. A novel measure to characterise optimality of diameter relationships at retinal vascular bifurcations. *Artery Res* 2010;4:75–80
 38. Cheung CY, Tay WT, Mitchell P, et al. Quantitative and qualitative retinal microvascular characteristics and blood pressure. *J Hypertens* 2011;29:1380–1391
 39. Grauslund J, Green A, Kawasaki R, Hodgson L, Sjølie AK, Wong TY. Retinal vascular fractals and microvascular and macrovascular complications in type 1 diabetes. *Ophthalmology* 2010;117:1400–1405
 40. Hughes AD, Martinez-Perez E, Jabbar AS, et al. Quantification of topological changes in retinal vascular architecture in essential and malignant hypertension. *J Hypertens* 2006;24:889–894
 41. Doubal FN, MacGillivray TJ, Patton N, Dhillon B, Dennis MS, Wardlaw JM. Fractal analysis of retinal vessels suggests that a distinct vasculopathy causes lacunar stroke. *Neurology* 2010;74:1102–1107
 42. Witt N, Wong TY, Hughes AD, et al. Abnormalities of retinal microvascular structure and risk of mortality from ischemic heart disease and stroke. *Hypertension* 2006;47:975–981
 43. Cosatto VF, Liew G, Rochtchina E, et al. Retinal vascular fractal dimension measurement and its influence from imaging variation: results of two segmentation methods. *Curr Eye Res* 2010;35:850–856
 44. Cheung N, Donaghue KC, Liew G, et al. Quantitative assessment of early diabetic retinopathy using fractal analysis. *Diabetes Care* 2009;32:106–110
 45. Lim SW, Cheung N, Wang JJ, et al. Retinal vascular fractal dimension and risk of early diabetic retinopathy: A prospective study of children and adolescents with type 1 diabetes. *Diabetes Care* 2009;32:2081–2083
 46. Stosić T, Stosić BD. Multifractal analysis of human retinal vessels. *IEEE Trans Med Imaging* 2006;25:1101–1107
 47. Sasongko MB, Wong TY, Nguyen TT, Cheung CY, Shaw JE, Wang JJ. Retinal vascular tortuosity in persons with diabetes and diabetic retinopathy. *Diabetologia* 2011;54:2409–2416
 48. Sasongko MB, Wong TY, Donaghue KC, et al. Retinal arteriolar tortuosity is associated with retinopathy and early kidney dysfunction in type 1 diabetes. *Am J Ophthalmol* 2012;153:176–183, e1
 49. Benitez-Aguirre P, Craig ME, Sasongko MB, et al. Retinal vascular geometry predicts incident retinopathy in young people with type 1 diabetes: a prospective cohort study from adolescence. *Diabetes Care* 2011;34:1622–1627
 50. Doubal FN, de Haan R, MacGillivray TJ, et al. Retinal arteriolar geometry is associated with cerebral white matter hyperintensities on magnetic resonance imaging. *Int J Stroke* 2010;5:434–439

51. Garhöfer G, Zawinka C, Resch H, Kothly P, Schmetterer L, Dorner GT. Reduced response of retinal vessel diameters to flicker stimulation in patients with diabetes. *Br J Ophthalmol* 2004;88:887–891
52. Mandecka A, Dawczynski J, Blum M, et al. Influence of flickering light on the retinal vessels in diabetic patients. *Diabetes Care* 2007;30:3048–3052
53. Hill MA, Meininger GA, Davis MJ, Laher I. Therapeutic potential of pharmacologically targeting arteriolar myogenic tone. *Trends Pharmacol Sci* 2009;30:363–374
54. Lorenzi M, Fekete GT, Pitler L, Berisha F, Kolodjaschna J, McMeel JW. Defective myogenic response to posture change in retinal vessels of well-controlled type 1 diabetic patients with no retinopathy. *Invest Ophthalmol Vis Sci* 2010;51:6770–6775
55. Khavandi K, Greenstein AS, Sonoyama K, et al. Myogenic tone and small artery remodeling: insight into diabetic nephropathy. *Nephrol Dial Transplant* 2009;24:361–369
56. Wang Y, Fawzi AA, Varma R, et al. Pilot study of optical coherence tomography measurement of retinal blood flow in retinal and optic nerve diseases. *Invest Ophthalmol Vis Sci* 2011;52:840–845
57. Choi W, Baumann B, Liu JJ, et al. Measurement of pulsatile total blood flow in the human and rat retina with ultrahigh speed spectral/Fourier domain OCT. *Biomed Opt Express* 2012;3:1047–1061
58. Huang G, Qi X, Chui TY, Zhong Z, Burns SA. A clinical planning module for adaptive optics SLO imaging. *Optom Vis Sci* 2012;89:593–601
59. Zhong Z, Song H, Chui TYP, Petrig BL, Burns SA. Noninvasive measurements and analysis of blood velocity profiles in human retinal vessels. *Invest Ophthalmol Vis Sci* 2011;52:4151–4157
60. Zhong Z, Huang G, Chui TY, Petrig BL, Burns SA. Local flicker stimulation evokes local retinal blood velocity changes. *J Vis* 2012;12:3
61. Sun D, Nakao S, Xie F, Zandi S, Schering A, Hafezi-Moghadam A. Superior sensitivity of novel molecular imaging probe: simultaneously targeting two types of endothelial injury markers. *FASEB J* 2010;24:1532–1540
62. Garland RC, Sun D, Zandi S, et al. Noninvasive molecular imaging reveals role of PAF in leukocyte-endothelial interaction in LPS-induced ocular vascular injury. *FASEB J* 2011;25:1284–1294