

CASE REPORT

Open Access

Female urethral diverticulum: cases report and literature

Omar Riyach^{1*†}, Mustapha Ahsaini^{1†}, Mohammed Fadl Tazi¹, Soufiane Mellas², Roos Stuurman-Wieringa³, Abdelhak Khallouk¹, Mohammed Jamal El Fassi¹ and Moulay Hassan Farih¹

Abstract

Introduction: A female urethral diverticulum is an uncommon pathologic entity. It can manifest with a variety of symptoms involving the lower urinary tract. Our objective is to describe the various aspects of the diverticulum of the female urethra such as etiology, diagnosis and treatment.

Cases presentation: We report five female patients, without prior medical history. They had different symptoms: dysuria in four cases, recurrent urinary tract infection in three cases, stress incontinence in two cases and hematuria in two cases. All patients had dyspareunia. The physical exams found renitent mass located in the endovaginal side of urethra which drained pus in two cases. Urethrocytography found a diverticulum of urethra in all cases. Our five patients underwent diverticulotomy by endovaginal approach. The course after surgical treatment was favorable. The urinary catheter was withdrawn after ten days. Some recurrent symptoms were reported.

Conclusion: Evaluation of recurrent urinary complaints in young women can lead to the finding of a diverticulum of urethra. Urethrocytography can reveal this entity. Diverticulectomy by endovaginal approach is the best choice for treatment.

Keywords: Urethra, Diverticulum, Woman, Diverticulectomy, Endovaginal approach

Introduction

Originally described by William Hey in 1786, the urethral diverticulum in women is a rare disease. Its diagnosis is based on clinical presentation and examination with additional cystoscopy and urethral opacification. Treatment is considered strictly surgical.

Through presenting the five cases of female urethral diverticulum and literature review, we reviewed the diagnostic, therapeutic and evolutive aspects of this pathology.

Case presentation

From 2000 to 2012, five women (mean age 40 years, range 23–58) with an urethral diverticula were diagnosed and treated at our institution. The diagnosis was based on reported symptoms, physical examination (Table 1), retrograde and voiding cysto- urethrography.

Case presentation 1

A 37-year-old Berber woman presented with a three year history of progressive urinary symptoms consisting of dysuria, urinary frequency, recurrent urinary tract infections as well as dyspareunia.

Clinical examination revealed a clean perineum, a tender cystic lesion located in the anterior vaginal wall with purulent vaginal discharge on palpation.

The retrograde and voiding urethrocytography revealed a urethral diverticulum at the middle third of the urethra (Figure 1).

The patient underwent transvaginal diverticulectomy by incision of the anterior vaginal wall and excision of the diverticulum after locating the connection to the urethra. An urethrovesical catheter was left 10 days. Follow-up examination after a few months showed no abnormality.

Case presentation 2

A 32 years old Arab mother, with no previous gynaecological history, consulted our clinic with multiple urinary complaints: dysuria, haematuria, recurrent urinary tract infections and dyspareunia. The physical examination

* Correspondence: riyach2@hotmail.com

†Equal contributors

¹Department of Urology, University Hospital Center Hassan II-FES, Fès, Morocco

Full list of author information is available at the end of the article

Table 1 Summary of the clinical signs in reported patients

| Symptoms | Number of patients |
|------------------------------------|--------------------|
| Dysuria | 4 |
| Vaginal mass | 3 |
| Recurrent urinary tract infections | 3 |
| Dyspareunia | 5 |
| Stress or urge incontinence | 2 |
| Haematuria | 2 |
| Discharge of pus per urethra | 2 |

revealed a renitent mass filled with pus at the distal segment of the urethra.

The patient underwent a retrograde and voiding urethrocytography that revealed a compound diverticulum of the urethra (Figure 2).

A transvaginal diverticulectomy was performed using the previously described procedure. The urethral catheter was left 10 days. Recurring dyspareunia was reported at follow-up examinations.

Case presentation 3

A 40 years old Berber woman, with three homebirth children, presented with a four months history of stress urinary incontinence, recurrent urinary infections, dyspareunia and intermittent drainage of pus from the urethral meatus. Physical examination showed renitent mass located in the endovaginal side of urethra that drained pus.

The patient underwent a retrograde and voiding urethrocytography revealing a diverticulum at the proximal third of urethra.

A transvaginal diverticulectomy was performed by opening, dissecting and excising the diverticulum with no post-operative complications. The urethrovesical catheter was

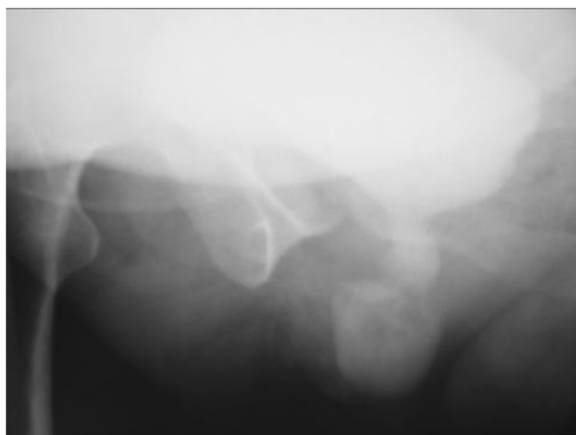


Figure 1 Voiding cystourethrogram shows a diverticulum filled with contrast agent at the level of the midurethra.

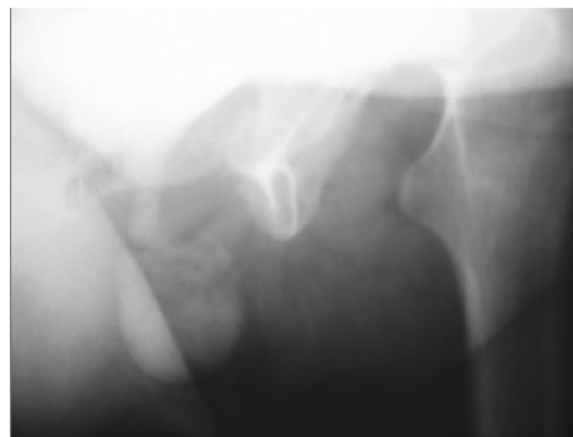


Figure 2 Urethrovesical opacification reveals a diverticulum of the urethra.

removed 10 days later. Recurring urinary tract infection was reported at follow up examination.

Case presentation 4

A 23-year-old Berber woman presented with history of dysuria, urinary frequency, urge incontinence and dyspareunia.

Clinical examination revealed a clean perineum, and renitent vaginal mass with no inflammatory aspect.

The retrograde and voiding urethrocytography revealed a septed diverticulum at the distal third of urethra.

A transvaginal diverticulectomy was performed after incision of the anterior vaginal wall and excision of the diverticulum after locating the connection to the urethra. The urethrovesical catheter was left for 10 days. Follow-up examinations showed recurrent stress incontinence six months after surgery.

Case presentation 5

A 58 years old woman married mother with a salpingectomy as gynecological antecedent consulted our clinic for urinary complaints consisting of haematuria, dysuria, and dyspareunia.

The physical examination was normal.

The patient underwent a retrograde and voiding urethrocytography revealing two diverticula at the proximal and distal third of the urethra.

The patient underwent a transvaginal diverticulectomy by opening, dissecting, and excising the diverticulum. The urethral catheter was left 10 days with no abnormality at follow-up examinations.

Discussion

What is the origin of the Female Urethral Diverticulum? Is it congenital, iatrogenic, traumatic or infectious [1-5]?

The search for the origin of a diverticulum of the female urethra arouses from the passion of understanding its

pathogenesis and many studies have been initiated to answer this question.

The congenital hypothesis is highlighted if the diagnosis is made in girls or in the neonatal period where the diverticulum is usually located on the roof of the urethra [6]. The diverticulum is considered to develop from embryonic remnants (Gartner's duct).

But the Routh's [7] hypothesis is more supported. It highlights the role of iterative infection and obstruction of periurethral glands. This leads to the cysts and then diverticulum formation by breaking and spilling their contents into the urethral lumen giving way to a pocket that is covered with epithelial component.

A well conducted interview and physical examination are able to raise the hypothesis of the diagnosis of urethral diverticulum. The classic triad (dribbling, dyspareunia, dysuria) [6,8-10], recurrent urinary tract infections and irritable signs are all very supportive signs of urethral diverticulum [1].

Investigations include, as we report in our observations, the retrograde and voiding urethrocytography but also retrograde urethrocytography with positive pressure tests. This has the advantage of being easy accessible and allowing the urologist to participate in the interpretation. Other diagnostic techniques require specific hardware and remain operator dependent, such as MRI with endorectal coil [11-13]. This investigation is good to detect and locate small diverticulum with a sensitivity between 70 and 100%, but a limited specificity.

Ultrasound is a non-invasive examination with no risk of allergy or risk of radiation and some studies have shown sensitivity between 86 and 100% [14,15] in the diagnosis of diverticulum. However ultrasound remains to be an operator-dependent investigation which can miss small diverticula.

The additional advantage of an urethrocytography is the possibility of the diverticular neck localization and its urethral topography [1,6].

Clinical presentation, imaging and urethrocytography can confirm the diagnosis of urethral diverticulum and eliminate other diseases that can be confused with the diverticulum such as Gartner duct cysts, peri-meatal lesions and Skene para-urethral glands abscesses.

The treatment is strictly surgical consisting of a diverticulectomy [16-18], by transvaginal approach. Some surgical teams advise a prone position [1,16,19,20] with the argument that it allows better exposure of the diverticulum. However a supine position, which we adapt for our patients, allows a better exposure of distal lesions and allows an easy and complete excision of the diverticulum. We can consecutively treat an associated stress urinary incontinence by performing a colposuspension (anim). This position has also the undeniable advantage of a locoregional anesthesia [1].

By opting for a U incision, which is our personal choice and recommended by Raz [5], our objective was to reduce the risk of overlapping suture lines, fistula and postoperative stenosis.

The type of incision, the vaginal transverse incision, arcuate or inverted U, remains a choice of the surgical team without major outcome changes. The best way to close the diverticular collar is in three layers: the urethra, the periurethral fascia and vaginal wall. This technique reduces significantly [1] the risk of fistula or postoperative incontinence.

For urine drainage, we opted for the urethral catheter for 10 days but some authors recommend cystostomy alone [1] or the combination of a cystostomy and urethral catheter [6].

Like any surgery, treatment of an urethral diverticulum has complications consisting of fistula, urethral stenosis and urinary incontinence or lower urinary tract symptoms with a frequency reported between 3 and 10% [8,21]. Recurrence is rare [4,6], the literature highlights some predisposing factors as: urethral infection, local inflammation and urine drainage problems [5].

The surgical diverticulectomy is the gold standard in the treatment of this disease however there are some other therapeutic treatments such as vaginal marsupialization of Spence and Duckett and endoscopic incision of the diverticular neck, technique. These involve a significant risk of postoperative incontinence and are restricted to the distal diverticula.

Conclusion

A urethral diverticulum is a rare disease with poorly understood pathogenesis. Clinical presentation with diagnostic, retrograde and voiding urethrocytography can confirm the diagnosis. The treatment is purely surgical.

Consent

Written informed consent was obtained from all patients (case 1,2,3,4,5) for publication of this manuscript and accompanying images.

Competing interests

Authors declare that they have no competing interests.

Authors' contributions

OR, MA: the principal authors, major contributions in writing the manuscript. MFT, SM, RSW, AK, MJF, MHF: analysed and interpreted the patient data and the reviews of the literature. All authors read and approved the final manuscript.

Author details

¹Department of Urology, University Hospital Center Hassan II-FES, Fès, Morocco. ²Department of Anatomy, Faculty of Medicine and Pharmacy of FES, Fès, Morocco. ³Department of Urology, Reinier de Graaf Gasthuis, P.O. Box 5011, 2600, GA Delft, The Netherlands.

Received: 10 July 2013 Accepted: 10 February 2014

Published: 15 February 2014

References

1. El Khader K, Ouali M, Nouri M, Koutani A, Hachimi M, Lakrissa A: **Diverticules de l'urèthre chez la femme. Analyse de 15 cas.** *Prog Urol* 2001, **11**:97–102.
2. Baert L, Willems P, Vynen R: **Endovaginal sonography: new diagnostic approach for urethral diverticula.** *J Urol* 1992, **147**:464–466.
3. Glassman TA, Weinerth JL, Glen JF: **Neonatal female urethral diverticulum.** *Urology* 1975, **5**:249–251.
4. Marshall S: **Urethral diverticula in young girls.** *Urology* 1981, **17**:243–245.
5. Young GPH, Wahle GR, Raz D: **Female urethral diverticulum.** In *Shlomo Raz. Female urology*. Philadelphia: SaundersWB; 1996:477–489.
6. Leach GE, Bavendam TG: **Female urethral diverticula.** *Urology* 1987, **30**:407–415.
7. Routh A: **Urethral diverticulum.** *Br Med J* 1890, **1**:360–365.
8. Davis HF, Cian LG: **Positive pressure urethrography: a new diagnostic method.** *J Urol* 1956, **75**:753–755.
9. Jensen LM, Aabech J, Lundvall F, Iversen HG: **Female urethral diverticulum, clinical aspects and a presentation of 15 cases.** *Acta Obstet Gynecol Scand* 1996, **75**:748–752.
10. Stewart M, Bretland PM, Stidolph NE: **Urethral diverticulum in the adult female.** *Br J Urol* 1981, **53**:353–359.
11. Daneshgari F, Zimmern PE, Jacomides L: **Magnetic resonance imaging detection of symptomatic non communicating intraurethral wall diverticula in woman.** *J Urol* 1999, **161**:1259–1261.
12. Kim B, Hricak H, Tanagho EA: **Diagnosis of urethral diverticula in woman: value of MR imaging.** *AJR Am J Roentgenol* 1993, **161**:809–815.
13. Neitlich JD, Foster HE, Glickman MG, Smith RC: **Detection of urethral diverticula in women: comparison of a high resolution fast spin echo technique with double balloon urethrography.** *J Urol* 1998, **159**:408–410.
14. Chancelor MB, Liu JB, Rivas DA, Karasick S, Bagley DH, Golodberg BB: **Intraoperative endo-luminal ultrasound evaluation of urethral diverticula.** *J Urol* 1995, **153**:72–75.
15. Siegel CL, Middleton WD, Teeffey SA, Wainstein MA, McDougall EM, Klutke CG: **Sonography of the female urethra.** *AJR Am J Roentgenol* 1998, **170**:1269–1274.
16. Boccon-Gibod L, Benoit G, Steg A: **Les poches sous urétrales sont-elles une affection bénigne?** *Ann Urol* 1983, **17**:151–152.
17. Dmochowski R, Gabanathi K, Zimmern PE, Leach GE: **Benign female periurethral masses.** *J Urol* 1994, **152**:1943–1951.
18. Ganabathi K, Dmochowski R, Sirls LT, Zimmern PE, Leach GE: **Diverticules de l'urèthre féminin.** *Prog Urol* 1995, **5**:335–351.
19. Sasnett RB, Mins VW, Whitherington R: **Jackknife prone position for urethral diverticulectomy in woman.** *Urology* 1978, **11**:183–185.
20. Zerbib M, Steg A, Debre B, Benoit G, Boccon-Gibod L: **Traitement chirurgical des poches sous urétrales. Etude critique rétrospective: intérêt de la cure en décubitus ventral.** *Ann Urol* 1989, **23**:349–351.
21. Sachot JL, Rata Jcza JA: **Les urétérocèles féminines. Difficultés diagnostiques et thérapeutiques. A propos de 10 cas.** *Ann Urol* 1989, **23**:156–157.

doi:10.1186/1750-1164-8-1

Cite this article as: Riyach et al.: Female urethral diverticulum: cases report and literature. *Annals of Surgical Innovation and Research* 2014 **8**:1.

Submit your next manuscript to BioMed Central and take full advantage of:

- Convenient online submission
- Thorough peer review
- No space constraints or color figure charges
- Immediate publication on acceptance
- Inclusion in PubMed, CAS, Scopus and Google Scholar
- Research which is freely available for redistribution

Submit your manuscript at
www.biomedcentral.com/submit

