

Subcutaneous immunoglobulin replacement therapy in a patient with 18q deletion syndrome, primary immune deficiency, and type I diabetes

International Journal of
Immunopathology and Pharmacology
Volume 35: 1–6
© The Author(s) 2021
Article reuse guidelines:
sagepub.com/journals-permissions
DOI: 10.1177/20587384211039400
journals.sagepub.com/home/iji
SAGE

Anna Hogendorf¹ , Agnieszka Szadkowska¹, Arkadiusz Michalak¹, Marta Surman², Karolina Trojan-Borczynska³, Wojciech Młynarski⁴ and Szymon Janczar⁴

Abstract

18q deletion syndrome (OMIM #601808) results from a deletion of a part of a long arm of 18 chromosome and is characterized by mental retardation and congenital malformations. We present an exceptional case of a 12-year-old girl with severe phenotype of 18q deletion syndrome, frequent infections, type I diabetes, autoimmune thyroiditis, and vitiligo. At first, the patient was diagnosed with selective immunoglobulin A (sIgAD) which explained her susceptibility to both infections and autoimmunity. With time, sIgAD progressed to common variable immune deficiency-like (CVID-like) disorder. She had a minimum of 12 infections per year, approximately twice as many courses of different antibiotics and up to three hospitalizations annually, making the treatment of diabetes difficult. Due to safety issues (increased risk of adverse reaction to blood products) and patient's convenience, subcutaneous IgG (SCIG) replacement therapy was initiated. We noticed a substantial decrease in the number of infections and improvement of metabolic control of diabetes.

Keywords

18q deletion syndrome, immune deficiency, immunoglobulin replacement therapy, SCIG, IgAD, CVID

Introduction

Chromosome 18q deletion syndrome (de Grouchy syndrome type II, OMIM #601808) occurs when a fragment of the long (q) arm of chromosome 18 is missing. Its prevalence is estimated to be 1 in 40,000 live births.^{1–3} The syndrome's heterogeneous presentation most commonly includes short stature, microcephaly, facial dysmorphism, mental retardation, hypotonia, hand and foot deformities, hearing impairment and genital anomalies. Frequently, cleft lip and palate, congenital heart disease, hypertelorism, umbilical and inguinal hernia, convulsions are also observed in the affected individuals.^{2,4} Several case reports and series also suggest that autoimmune diseases and immunoglobulin A deficiency (IgAD) may also be attributed to this genetic aberration.^{4–8}

Our team has recently reported a case of a girl with severe phenotype of 18q deletion syndrome due to *de novo* deletion at 18q21.32-q23 (chr18:58,660,699–78,012,870)

¹Department of Pediatrics, Diabetology, Endocrinology and Nephrology, Medical University of Lodz, Lodz, Poland

²Department of Clinical Immunology, University Children's Hospital, Kraków, Poland

³Regional Blood Donation and Transfusion Center of Lodz, Lodz, Poland

⁴Department of Pediatrics, Oncology and Hematology, Medical University of Lodz, Lodz, Poland

Corresponding author:

Anna Hogendorf, Department of Pediatrics, Diabetology, Endocrinology and Nephrology, Medical University of Lodz, Sporna Str. 36/50 91-738, Lodz 90-419, Poland.

Email: anna.hogendorf@umed.lodz.pl



Creative Commons Non Commercial CC BY-NC: This article is distributed under the terms of the Creative Commons Attribution-NonCommercial 4.0 License (<https://creativecommons.org/licenses/by-nc/4.0/>) which permits non-commercial use, reproduction and distribution of the work without further permission provided the original work is attributed as specified on the SAGE and Open Access pages (<https://us.sagepub.com/en-us/nam/open-access-at-sage>).

(detected by microarray oligonucleotide comparative genomic hybridization (aCGH) at 5 kbp resolution (Nimblegen, Roche)), coexisting with primary immune deficiency and autoimmunity. She was found, moreover, to have hypogammaglobulinemia and CD4⁺CD25⁺FoxP3⁺regulatory T cells deficiency.⁹

Here, we would like to present our experience with subcutaneous immunoglobulin IgG (SCIG) replacement therapy in this patient, which has resulted in the decrease in the number of infections as well as in a better metabolic control of diabetes.

Case Report

The girl of Caucasian ethnicity, who is now 12 years old, displays severe phenotype of the syndrome: she is mentally disabled, short-statured, has microcephaly, deeply set eyes, hypoplasia of the mid-section of the face, and wide carp-like mouth with cleft lip and palate. Her hands are slender with tapering fingers and proximally placed thumbs. She has club feet and planovalgus. Moreover, she has atrial septal defect (ASDII) with moderate pulmonary stenosis, hypotonia, and hearing impairment.

Her compromised immune system has posed serious medical problems since the first day of her life. Shortly after birth, she was diagnosed with an inborn infection. Since then she has suffered from recurrent upper respiratory tract infections (on a monthly basis) and concomitant cold sores (*Herpes simplex*). So far she has been hospitalized over 20 times due to recurrent pneumonia (*S. pneumoniae*, *M. pneumoniae*, and *Ch. pneumoniae*), bronchitis (*RV*, *RSV*), pharyngitis (*viral*, *Streptococcus A*), sinusitis (*S. pneumoniae*, *M. pneumoniae*), otitis media (*viral*, *S. pneumoniae*, and *M. pneumoniae*), stomatitis (*Herpes spp.*, *Candida albicans*), inflammation of salivary glands and cervical lymph nodes (*S. aureus*), acute gastrointestinal tract infections (*rotavirus*, *adenovirus*, and *S. typhi*), urinary tract (*E.coli*), or skin infections (*S.aureus*). She has also had recurrent *H. pylori* infection and positive stool culture for *Gardia lamblia* and *Candida* spp.

Each hospitalization was challenging not only for the mentally disabled patient and her parents but also for the health care professionals. The girl reacted with huge emotional distress to admissions and medical procedures. She was screaming, was unable to remain still and calm down. Apart from recurrent infections, at the age of 3.5, she was diagnosed with type 1 diabetes mellitus (T1D), autoimmune thyroiditis (AIT) and, subsequently, with vitiligo.

Soon after the onset of diabetes, she was found to have selective IgAD (defined as IgA <0.07 g/L, with normal levels of IgM and IgG in a patient above 4 years of age), which explained her susceptibility to infections and

autoimmunity.¹⁰ Since her IgG levels during infections were elevated, there were no indications for IVIG therapy. The girl was vaccinated according to the Polish immunization schedule.

The treatment of both hypothyroidism (replacement with thyroxine) and diabetes was hindered by the recurrent infections. Trimethoprim-sulphamethoxazole prophylaxis was attempted with a moderate clinical effect. She had a minimum of 12 infections per year, and approximately twice as many courses of different antibiotics and up to three hospitalizations annually. We also noted a few episodes of urticaria without trigger.

Despite insulin pump therapy and all efforts of her careful, compliant, and well-trained mother, her glycated hemoglobin A1c (HbA1c) level reflecting average concentration of blood sugar over the past 3 months, and used for metabolic control assessment, was constantly above 90th percentile for age-matched Polish pediatric population with type 1 diabetes (Figure 1).

At the age of 10, she underwent the reconstruction of the alveolar process and palate with autogenous bone block graft from the iliac crest. Unfortunately, the procedure was complicated by hemorrhage and infection which led to subsequent removal of the graft. She had severe anemia and required packed red blood cells transfusion. The initial serological studies showed the presence of warm auto-antibodies on the patient's erythrocytes and irradiated leukocyte-depleted phenotype-matched red blood cells concentrate was used. Despite this, an acute febrile reaction occurred during the transfusion. She also had positive Coombs test but with no signs of autoimmune hemolytic anemia.

Further immunological evaluation revealed that the immune deficiency progressed, mimicking CVID. She had IgG deficiency with low IgG₁, IgG₂, IgG₄ levels, IgAD, low IgE, and profound defect in differentiation of B lymphocytes (Table 1). Taking into consideration the patient's complex medical history, we concluded that immunoglobulin replacement therapy might be beneficial. After obtaining informed consent, the SCIG therapy was initiated with ready-to-use 20% liquid preparation of human IgG, specifically formulated for subcutaneous infusions (Hizentra[®], IgPro20; CSL Behring, Bern, Switzerland).

Although Hizentra[®] is usually applied by rapid-push method without pump, in this case, we decided to administer it with Micropump mlh+ Multi Syringe driver (Micrel Medical Devices). This manner of administration was consistent with the Polish product characteristics and it was based on good safety profile in a patient with previous blood product reaction as well as guardian's preference (familiar with insulin pump). We applied a starting dose of 2 g weekly, up to 0.4 g/kg monthly, and the rate of the injection was 20 mL/hr.

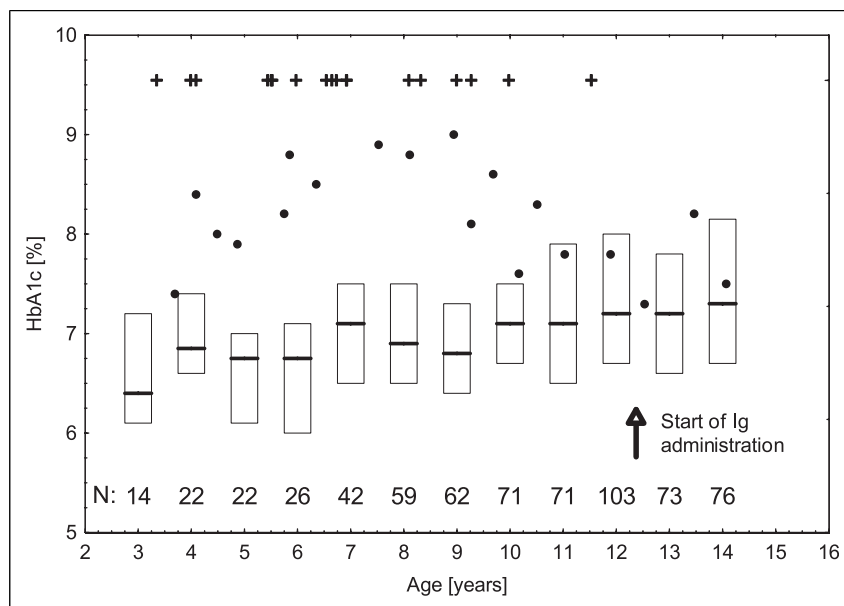


Figure 1. Overtime changes in HbA1c (black dots) and number of infection-related hospitalizations (each event—one black cross) of the girl with 18q deletion syndrome and type 1 diabetes. The vertical arrow denotes the time of SiVG commencement. For reference, historical age-appropriate HbA1c ranges for Polish population with T1D are presented (lines—medians, boxes—25–75%). Each range was calculated based on the sample of N children, as denoted in the bottom of the graph. The data were collected in a cross-sectional fashion from a majority of Polish reference centers for childhood diabetes in 2018 and covered ~8% of total Polish pediatric population with T1D.

Luckily, no adverse reactions after the drug application have been observed, apart from minor and transient edema and redness in the injection area.

Immunoglobulin IgG levels (including the subclasses, with the exception of IgG4) have reached the normal value (the results after 12 months of substitution are shown in Table 2). After a year since the beginning of the SCiG replacement, the girl has not required any hospitalizations due to infections and antibiotics have been administered only twice as a prophylaxis at the time of a planned tooth extraction. Moreover, we noticed a decrease in the number of infections (from 12 annually to one in the past year) and the improvement of metabolic control of diabetes (lowering of HbA1c level) (Figure 1).

Discussion

Although the 18q deletion syndrome has been known since 1964 (1), the literature is devoid of studies on the prevalence of other than IgAD immune system anomalies associated with this genetic aberration.

The clinical and laboratory picture of our patient (recurrent/severe infections, three autoimmune disorders occurring at an early age, low IgG, IgA, and defective B lymphocytes differentiation) suggest coexisting CVID.¹¹ Taking into account existence of numerous similar reports on autoimmune disorders, IgAD, as well as conversion of

IgAD to more profound hypogammaglobulinemia in patients with 18q deletion, this is rather not a matter of coincidence, but a result of haploinsufficiency of certain genes located distally to 18q21.^{5,8,9,12,13}

Therefore, we suggest that patients with 18q abnormalities, recurrent infections, and/or already diagnosed IgAD should be regularly screened by repeated measurement of immunoglobulin A, M, G, E and IgG₁₋₄ levels which is generally available and relatively not expensive. Antibody deficiency should be dealt with as early as possible to establish indications for immunoglobulin replacement therapy (IGRT) and prevent many years of severe clinical problems. If possible, the undertaken procedures should also include more detailed diagnostics, for example, toward selective antibody deficiency against bacterial polysaccharides (SPAD), which we were not able to determine. Such abnormality was documented in a patient with 18 chromosome short arm deletion.¹⁴ It should be highlighted, however, that the confirmation of SPAD is not necessary to initiate IViG/SCiG replacement. The increased frequency of severe respiratory bacterial infections is absolutely sufficient indicating criteria for SCiG/IViG substitution. Vaccination against pneumococci and regular vaccination against flu should also be recommended for such patients.

To our knowledge, this is the first description of SCiG treatment in a patient with 18q deletion syndrome. In this case, clinical benefit from IGRT is clear and no complications

Table I. Lymphocyte subsets in peripheral blood of a girl with 18q del syndrome.

		Percentage (%) (normal range)	Cells/ul (normal range)
White blood cells (WBCs)	—	—	7850 (4400–8100)
Lymphocytes	—	28.7 (36.0–43.0)	2253 (1400–3300)
Lymphocytes T Subpopulations	—	%(normal range)	Cells/ul (normal range)
CD3	—	70 (56–84)	1577 (1000–2200)
CD4	—	46 (31–52)	1036 (530–1300)
CD8	—	20 (18–35)	451 (330–920)
TCR α/β	—	67	1510
TCR γ/δ	—	3	68
CD3/HLADR	—	24.7 (8–15)	556 (73–162)
Lymphocytes T memory/naive	—	—	—
CD45RA	—	22	—
CD45RO	—	78	—
Lymphocytes T double-negative	—	3.5 ^c	—
NK Cells (CD3-16+56+)	—	21 (3–22)	473 (70–480)
Lymphocyte B subpopulations	Lymphocytes B (%) (normal range)	Lymphocytes (%) (normal range)	Cells/ul (normal range)
B cells CD19 ⁺	—	8 (9.40–22.8)	180 (200–600)
Memory B cells CD19 ⁺ CD27 ⁺	1.85 (13.3–47.9) ^a	0.15	3 (50–200) ^a
Marginal zone B cells CD19 ⁺ CD27+IgD+	0.83 (4.60–18.20) ^a	0.07	1 (20–70) ^a
Class-switched memory B cells CD19 ⁺ CD27+IgD-IgM-	0.2 (8.7–25.6) ^a	0.02 (1.7–5.4) ^b	0 (30–110) ^a
Activated B cells CD21lowCD38lowCD19high	22.75 (2.70–8.70) ^a	1.82	41 (10–30) ^a
Total transitional B cells CD38++IgM high	6.49 (1.40–13.0) ^a	0.52	12 (10–60) ^a
Plasmablasts CD38+++IgM-CD21lowCD19low	0.14 (0.60–6.5) ^a	0.01	0 (<20) ^a
CD19+/CD27-/IgD+ Naive B cells	85.96 (51.3–82.5)	6.88	155

Normal range for T/NK cells based on local reference, B cell maturation according to:

^aPiätosa B et al. B cell subsets in healthy children: reference values for evaluation of B cell maturation process in peripheral blood. *Cytometry B Clin Cytom.* 2010 Nov; 78 (6):372-381. doi: 10.1002/cyto.b.20536. PMID: 20533385.

^bFreiburg classification. Warnatz K, et al. Severe deficiency of switched memory B cells (CD27 (+) IgM (-) IgD (-)) in subgroups of patients with common variable immunodeficiency: a new approach to classify a heterogeneous disease. *Blood.* 2002 Mar 1; 99 (5):1544-1551. doi: 10.1182/blood.v99.5.1544. PMID: 11861266.

^cAlthough the patient had no clinical features of ALPS (autoimmune lymphoproliferative syndrome) such as lymphadenopathy or splenomegaly, we noticed an abnormally increased proportion of CD3⁺CD4⁻CD8⁻ “double-negative” T cells (3.5% of all lymphocytes). While the patient has no features of lymphoproliferation, this might be another piece of evidence for immune dysregulation in 18q deletion syndrome. Apart from ALPS, the increased percentage of double-negative T cells might be present in various autoimmune disorders, infection, and persistent inflammation, which is consistent with the situation of our patient.

have been observed, despite the potential risk of transfusion-related adverse events. Taking into account our patient's safety (recent reaction to irradiated leukocyte-depleted phenotype-matched RBC concentrate, increased risk of anaphylaxis to blood products, in patient with IgA deficiency (potential immunization to IgA present in the donor plasma)),¹⁵ we decided to try subcutaneous IgG (SCIG) replacement therapy which is known to have a better safety profile than IVIG.¹⁶

The incidence of anti-IgA-mediated anaphylactic reaction includes one in 1.3 million blood components transfused,¹⁷ while isolated IgA deficiency, on the other

hand, is very common with the prevalence of one in 500 Caucasians, indicating that rare factors such as special anti-IgA antibodies might be involved in addition to the IgAD in the pathophysiology of the systemic inflammatory response.¹⁸ Our patient was not tested for the presence of anti-IgA antibodies as this test is currently not offered by any laboratory in Poland.

The maximal IgA concentration of the chosen SCIG formulation according to the manufacturer is 0.05 mg/mL, which is relatively low in comparison with other products. Another advantage of using SCIG was its convenience. It can be self-administered at home once a week via personal

Table 2. Clinical and laboratory characteristics prior to and a year after the introduction of SCIG treatment.

Clinical parameter	Before SCIG	A year after the introduction of SCIG	Reference range
Number of infections per year	12	2	N/A
Number of antibiotic courses per year	24	2	N/A
Number of hospitalizations per year (mean)	4	0	N/A
Number of hospitalizations due to infections per year (mean)	3	0	N/A
Laboratory parameter	Before SCIG	Six months after the introduction of SCIG	Reference range
IgA (g/l)	<0.05	<0.05	0.5–3.5
IgM (g/l)	1.0	0.65	0.4–2.4
IgG (g/l)	4.29(↓)	10.162	7.5–14
IgE (IU/l)	<2	<2	<85
IgG subclasses (g/l)			
IgG1	4.67(↓)	5.47	4.9–10.5
IgG2	0.63(↓)	2.59	1.32–3.71
IgG3	1.23	1.95	0.29–0.87
IgG4	<0.02(↓)	<0.07(↓)	0.14–1.48
Post hepatitis B virus vaccine antibody titer (anti-HBs) (IU/l)	< 0.01(↓)	361	>100
HbA1c (%)	8.25+/-0.5	7.5	≤6.5
Protein (g/l)	67.0		66.0–83.0
Albumin (g/l)	36.1		31.2–52.1
Globulin (g/l)			
α ₁	3.2		0.60–2.40
α ₂	12.9		5.70–11.50
β1	7.4		3.60–7.80
β2	3.2		1.60–4.60
γ	4.1 (↓)	—	6.40–16.2

pump, is easy to handle, and can be stored at a temperature of up to 25°C.¹⁹ The girl had been already treated with a pump for continuous insulin infusion (MiniMed Paradigm Veo, Medtronic, Northridge, CA, USA), which facilitated the education of her mother.

One may wonder if the observed improvement in metabolic control of T1D may solely be attributed to the decreased infections rate due to SCIG therapy and not to other factors, for example, physical and mental growing up. It should be stressed, however, that the patient's cognitive function and treatment adherence have not improved with age. Moreover, since puberty is generally associated with metabolic control worsening (Figure 1), the SCIG effectiveness (and reduced number of infections) seems to be the only justified explanation for the lowering of HbA1c level in this case.

Conclusion

SCIG substitution in a patient with 18q deletion syndrome, immune deficiency symptoms, and hypogammaglobulinemia proved to be safe, efficacious as well as a convenient form of protection from recurrent infections and contributed to better metabolic control of diabetes. Patients with

18 chromosome abnormalities and recurrent infections and/or already diagnosed IgAD should be regularly screened by repeated measurement of immunoglobulins in order to provide immunoglobulin replacement therapy (IGRT) and prevent many years of severe clinical problems.

Declaration of conflicting interests

The author(s) declared no potential conflicts of interest with respect to the research, authorship, and/or publication of this article.

Funding

The author(s) received no financial support for the research, authorship, and/or publication of this article.

ORCID iD

Anna Hogendorf  <https://orcid.org/0000-0001-8536-9381>

References

- De Grouchy J, Royer P, Salmon C and Lamy M (1964) (Partial deletion of the long arms of the chromosome 18). *Pathol Biol* 12: 579–582.

2. Cody JD, Ghidoni PD, DuPont BR, Hale DE, Hilsenbeck SG, Stratton RF, et al. (1999) Congenital anomalies and anthropometry of 42 individuals with deletions of chromosome 18q. *Am J Med Genet* 85(5): 455–462.
3. Cody JD, Hale DE, Brkanac Z, Kaye CI and Leach RJ (1997) Growth hormone insufficiency associated with haploinsufficiency at 18q23. *Am J Med Genet* 71(4): 420–425.
4. Cody JD, Heard PL, Crandall AC, Carter EM, Li J, Hardies LJ, et al. (2009) Narrowing critical regions and determining penetrance for selected 18q-phenotypes. *Am J Med Genet* 149a(7): 1421–1430.
5. Stricker RB and Linker CA (1982) Pernicious anemia, 18q deletion syndrome, and IgA deficiency. *Jama* 248(11): 1359–1360.
6. Dostal A, Linnankivi T, Somer M, Kahkonen M, Litzman J and Tienari P (2007) Mapping susceptibility gene locus for IgA deficiency at del (18) (q22.3-q23); report of familial cryptic chromosome t (18q; 10p) translocations. *Int J Immunogenet* 34(3): 143–147.
7. Cody JD, Hasi M, Soileau B, Heard P, Carter E, Sebold C, et al. (2014) Establishing a reference group for distal 18q: clinical description and molecular basis. *Hum Genet* 133(2): 199–209.
8. Lomenick JP, Smith WJ and Rose SR (2005) Autoimmune thyroiditis in 18q deletion syndrome. *J Pediatr* 147(4): 541–543.
9. Hogendorf A, Lipska-Zietkiewicz BS, Szadkowska A, Borowiec M, Koczkowska M, Trzonkowski P, et al. (2016) Chromosome 18q deletion syndrome with autoimmune diabetes mellitus: putative genomic loci for autoimmunity and immunodeficiency. *Pediatr Diabetes* 17(2): 153–159.
10. Wang N, Shen N, Vyse TJ, Anand V, Gunnarson I, Sturfelt G, et al. (2011) Selective IgA deficiency in autoimmune diseases. *Mol Med* 17(11–12): 1383–1396.
11. Seidel MG, Kindle G, Gathmann B, Quinti I, Buckland M, van Montfrans J, et al. (2019) The European society for immunodeficiencies (esid) registry working definitions for the clinical diagnosis of inborn errors of immunity. *J Allergy Clin Immunol Pract* 7(6): 1763–1770.
12. Slyper AH and Pietryga D (1997) Conversion of selective IgA deficiency to common variable immunodeficiency in an adolescent female with 18q deletion syndrome. *Eur J Pediatr* 156(2): 155–156.
13. Calvo Campoverde K, Gean E, Piquer Gibert M, Martinez Valdez L, Deyà-Martínez A, Rojas Volquez M, et al. (2016) Humoral deficiency in three paediatric patients with genetic diseases. *Allergol Immunopathol* 44(3): 257–262.
14. Browning MJ (2010) Specific polysaccharide antibody deficiency in chromosome 18p deletion syndrome and immunoglobulin A deficiency. *J Investig Allergol Clin Immunol* 20(3): 263–266.
15. Hammarström L, Vorechovsky I and Webster D (2000) Selective IgA deficiency (SIgAD) and common variable immunodeficiency (CVID). *Clin Exp Immunol* 120(2): 225–231.
16. Radinsky S and Bonagura VR (2003) Subcutaneous immunoglobulin infusion as an alternative to intravenous immunoglobulin. *J Allergy Clin Immunol* 112: 630–633.
17. Latiff AH and Kerr MA (2007) The clinical significance of immunoglobulin A deficiency. *Ann Clin Biochem* 44(Pt 2): 131–139.
18. Webb C, Norris A and Hands K (2018) An acute transfusion reaction. *Clin Med* 18(1): 95–97.
19. Canessa C, Iacopelli J, Pecoraro A, Spadaro G, Matucci A, Milito C, et al. (2017) Shift from intravenous or 16% subcutaneous replacement therapy to 20% subcutaneous immunoglobulin in patients with primary antibody deficiencies. *Int J Immunopathol Pharmacol* 30(1): 73–82.