

Case Report

Open Access

Rafal Zielinski*, Anna Zakrzewska

Submental epidermoid cysts in children

Abstract: Epidermoid cysts are lesions, which form as a result of implantation of the epidermis in the layers of the dermis or the mucous membrane. The lesions are rare in adults with 7% occurring in the head and neck area and most often located in the submental region. In children population submental epidermoid cysts are extremely rare. The differential diagnosis of the lesions is necessary as it affects the choice of treatment methods. Among the pathological conditions occurring in that region, salivary retention cyst (ranula), thyroglossal duct cyst, vascular lymphatic malformation (cystic hygroma), median neck cyst, lymphadenopathy, thyroid gland tumor, laryngeal cyst, epidermoid and dermoid cysts, submental abscess, sialolithiasis and salivary gland inflammation should be considered. The authors of the present report demonstrate two cases of submental epidermoid cysts in children. Differential diagnosis in case of suspected submental epidermoid cyst in a child with proposed clinical practice and literature review is provided.

Keywords: Epidermoid, Cyst, Submental, Children

DOI 10.1515/med-2015-0013

Received: July 29, 2013; accepted: June 26, 2014

1 Introduction

Epidermoid and cutaneous cysts are lesions, which form as a result of implantation of the epiderm in the layers of the dermis or the mucous membrane. The lesions are infrequently observed in the regions of the head and neck (7%), in the oral cavity floor and rarely in the submental or submental regions [1, 2]. They can mimic or

be mimicked by dermoid cyst or ranula in the region. A ranula is a retention cyst of the sublingual salivary gland, which usually occurs as a unilateral transparent lesion in the oral cavity floor. Sometimes the cyst can move under the mylohyoid muscle and appears in the cervical region. Such a cyst has been referred to as a cervical ranula or plunging/ diving ranula [3]. A plunging or cervical ranula is a retention cyst of the sublingual salivary gland, which occurs below the floor of the oral diaphragm. Unlike epidermoid and dermoid cysts, it has been reported in children more frequently [4]. The differential diagnosis of the lesions is necessary as it affects the choice of treatment methods.

2 Case reports

2.1 Case 1

A 6-year-old boy was admitted to Department of Pediatric Otolaryngology because of a nodular swelling in the left submental region, which appeared 3 months prior to the admission. Previously, the boy's mother, who also denied any trauma or surgery in the area of the oral cavity floor, had observed a cystic lesion in the left side of the oral cavity floor for about 9 months. On admission a hard, elastic, painless lesion, which was mobile and unattached to the overlying normal skin was found on the physical examination in the submental region. No cyst-like lesions were observed in the floor of the mouth. The ultrasound examination showed an encapsulated structure of 38 x 31 mm in size, volume=9.4 ml, in the floor of oral cavity at the base of the tongue, with echogenic or solid contents. Small blood vessels covered the nodule capsule, no blood flow was observed in its lumen in Doppler Ultrasound examination. MRI of the head was also performed. T1- and T2-weighted images in the coronal, frontal and sagittal planes revealed a lesion, which was located slightly to the left and described as a cystoid, smooth lesion of approximately AP=25 mm, T= 27mm, H=19 mm with a maximum diameter 31 mm in the floor of the mouth. Features of the

*Corresponding author: Rafal Zielinski: Department of Pediatric Otolaryngology, Medical University of Lodz, ul. Sporna 36/50, 91-738 Lodz, Poland, tel./fax: +48-426177720, E-mail: rafalziel@gmail.com

Anna Zakrzewska: Department of Pediatric Otolaryngology, Medical University of Lodz, ul. Sporna 36/50, 91-738 Lodz, Poland

signal intensity were unusual for salivary gland retention cysts, high-protein, dermoid or solid lesions: high T1-weighted and quite low T2-weighted signal intensity. A winding tubular structure up to 4 mm wide, which reached the tongue was observed in the frontal and upper outline of the lesion –most probably that was the widened sublingual salivary gland duct. The posterior pole of the cyst bordered on the left submental salivary gland, however no features of communication were noted (Figure 1).

Based on the clinical examination and results of additional investigations the boy was qualified for surgical excision of the lesion in the floor of the mouth. A cystoid lesion 4.2-3 cm in size was dissected from the mylohyoid muscle under general anesthesia by the left-sided submental approach. The cyst wall was punctured and a moderate amount of serous content was obtained. The lesion was connected with the left sublingual salivary gland duct by a thin duct. The lesion was removed totally and cut off at the juncture with the sublingual gland. The postoperative wound was subsequently cleansed with sterile saline and an antibiotic and sutured in layers. Single sutures were placed on the skin and wound drainage was inserted. The postoperative course was uncomplicated (Figure 2, 3).

Histopathological examination confirmed the diagnosis of epidermoid cyst, which was filled with cheesy epidermoid material. No cutaneous elements were found.

The boy remains under the care of the hospital otolaryngological clinic. No signs of recurrence in the left submental region have been observed.

2.2 Case 2

A 15-year-old girl was admitted to Department of Pediatric Otolaryngology because of nodular swelling in the midline of submental region, which appeared 6 months prior to the admission. The parent of the girl denied any trauma or surgery in the area of the oral cavity floor. On admission a hard, elastic, painless lesion, which was mobile and unattached to the overlying normal skin was found on the physical examination in the submental region. The ultrasound examination showed an encapsulated structure of 35 x 28x18 mm in size, with both partially echogenic and partially solid contents. No blood flow was observed in its lumen in Doppler Ultrasound examination. Computed tomography of the head was also performed. In uni-phase

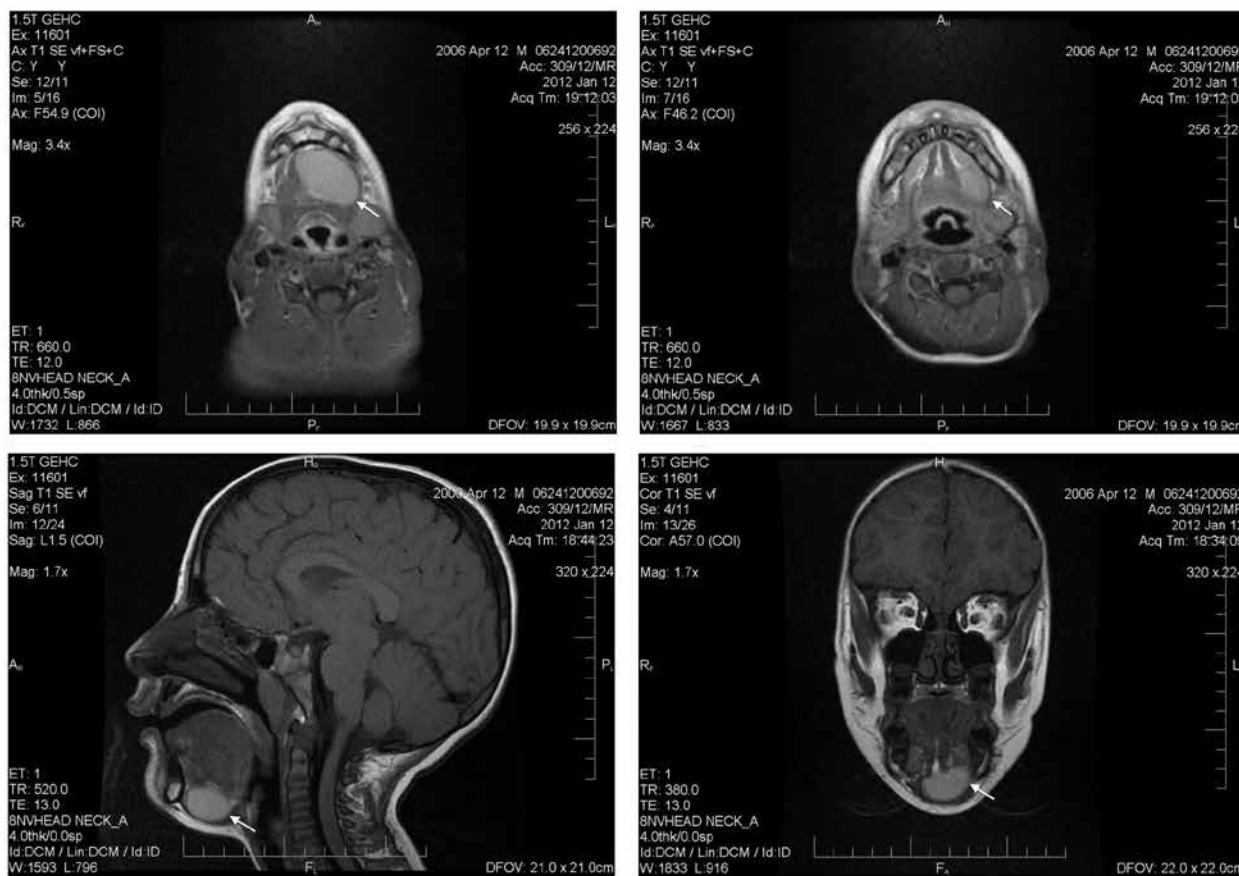


Figure 1: A 6-year old boy. MR image of the head. The arrow points a cystoid lesion in the left submental region

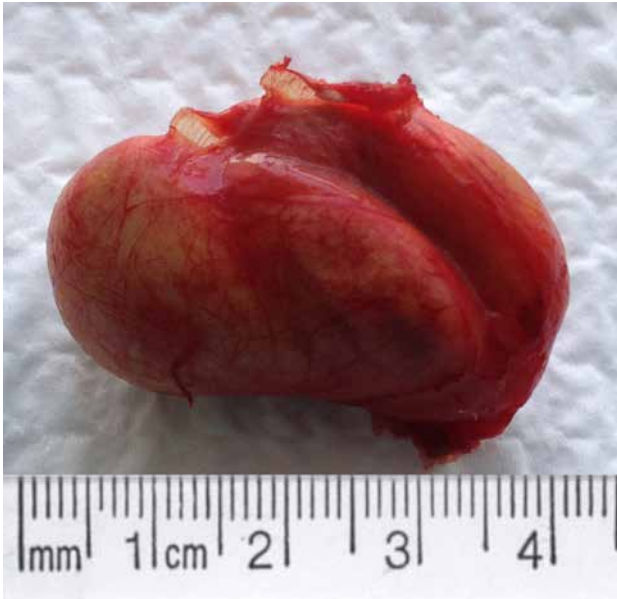

Figure 2: A 6-year old boy. A surgical specimen of the lesion in the left submental region



Figure 3: A 6-year old boy. Dissected surgical specimen of the lesion in the left submental region. Cheesy, epidermoid content can be seen

contrast computed tomography well shaped, capsulated and probably filled with fluid structure was visualized of approximately AP=29 mm, T=26 mm, H=24 mm. No infiltration of surrounding tissues was noted (Figure 4).

Based on the clinical examination and results of additional investigations the girl was qualified for surgical excision of the lesion in the submental region. A cystoid lesion 3-2,6 cm in size was dissected from the mylohyoid muscle under general anesthesia by the submental approach. The cyst wall was punctured and a moderate amount of serous and purulent content was obtained. The lesion was connected with the fund of oral cavity in the midline. The lesion was removed totally and cut off at the juncture with the oral cavity mucosa. The postoperative

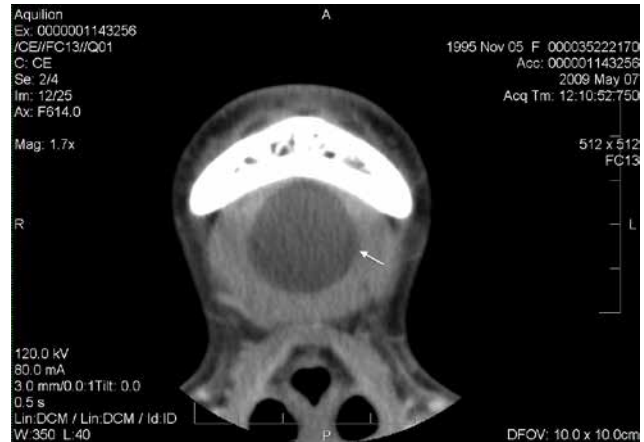


Figure 4: A 15-years old girl. Computed tomography image of the head. The arrow points a cystoid lesion in the submental region

wound was subsequently cleansed with sterile saline and an antibiotic and sutured in layers. Single sutures were placed on the skin and wound drainage was inserted. The postoperative course was uncomplicated.

Histopathological examination confirmed the diagnosis of epidermoid cyst with, which was filled with cheesy epidermoid material. No cutaneous elements were found.

The girl remains under the care of the hospital otolaryngological clinic. No signs of recurrence in the submental region have been observed.

Ethical approval: The research related to human use has been complied with all the relevant national regulations, institutional policies and in accordance the tenets of the Helsinki Declaration, and has been approved by the authors' institutional review board or equivalent committee.

Informed consent: Informed consent has been obtained from all individuals included in this study.

3 Discussion

Differential diagnosis for cystoid lesions of the floor of the oral cavity or the submental regions can be difficult due to their presentation diversity [5]. Among the pathological conditions occurring in that region, thyroglossal duct cyst, vascular lymphatic malformation (cystic hygroma), median neck cyst, lymphadenopathy, thyroid gland tumor, laryngeal cyst, epidermoid and dermoid cysts, submental abscess, sialolithiasis and salivary gland inflammation should be considered. Diagnostics is based on detailed history, the ENT examination and additional investigations such as ultrasound examination, magnetic

resonance imaging or computed tomography in doubtful cases and sometimes biopsy and aspiration of the cyst contents with subsequent examination for amylase [6]. We propose biopsy and aspiration of the cyst content also intraoperatively in uncertain cases. According to some authors, any unilateral lesion visualized on CT or MRI and described as a cyst located below the mylohyoid muscle or in the parapharyngeal space, which is linked with the sublingual salivary gland and often displaces the submental salivary gland can be practically recognized as a plunging ranula [7]. A retention cyst of the sublingual gland is usually visible as a smooth, bluish translucent swelling in the floor of the mouth. The form of plunging ranula without cystic component in the floor of the mouth also seems quite common [8]. The lesion is usually unilateral, although bilateral ranulas have also been reported [9]. The path of plunging ranula from the oral cavity floor may lead behind the rear edge of the mylohyoid muscle or via its fibers. The lesion may expand and infiltrate the parapharyngeal space, causing life-threatening complications [10]. Retention cysts of the sublingual salivary gland occur due to disturbances in the drainage of saliva from the gland via one or more draining ducts. A ranula may be the effect of post-operational trauma in the area of the floor of the mouth [11]. Pre-operative diagnosis of plunging ranula is suggested by young age of the patient, typical findings in imaging examinations and

lateral location of the lesion in the submental space [5]. A midline asymptomatic cystic lesion with the history of trauma in the region of the floor of the mouth in an adult patient is indicative of epidermoid cyst. Such cysts are very rare and account only for 0.01% of all cyst lesions of that area [12]. Such lesions usually occur in the floor of the oral cavity and are less frequently found in submental or submandibular regions [13]. Implantation of epithelium into deeper layers of the mucous membrane in the cases of epidermoid and cutaneous cysts takes place as a result of local trauma or surgery. Some theories suggest the innate character of epidermoid and dermoid lesions or types of cysts deriving from the thyroglossal duct. Cases of epidermal cysts originating from the submental duct have also been reported in the literature [14]. A thin wall, compact material containing epithelial masses and midline or, very rarely lateral- submental location suggests the diagnosis of epidermoid cyst. A dermoid cyst is always recognized as a midline lesion, often with a thickened wall, containing epithelial masses and frequently cutaneous elements such as hair. Connective tissue junctions between the cyst walls and the overlying skin have sometimes been demonstrated [15] (Table 1).

Management of epidermoid and dermoid cysts is exclusively surgical and involves excision of the lesion. The choice of surgical approach depends on the location of the cyst in relation to the mylohyoid muscle. In the

Table 1: Differential diagnosis of submental cystic lesions

	Epidermoid Cyst	Dermoid Cyst	Plunging Ranula
Incidence in head and neck	Less common in head and neck region	More common in head and neck region	Very common, especially in younger patients
Location	Midline and Non Midline	Midline	Non Midline
Type of cyst	Inclusion cysts lined by ectoderm	Inclusion cysts lined by ectoderm	Pseudocysts of the floor of the mouth, visible in submental region, parapharyngeal space and then described as plunging ranula
Thickness of the wall of the lesion	Thin lining because of lack of dermal appendages	Thick lining	Thick Lining
Presence of skin appendages	Skin appendages are absent within the wall of the lesion	Skin appendages are present	Skin appendages not present
Contents	Keratinaceous cheesy material due to squamous epithelium	Keratinaceous cheesy material due to squamous epithelium, often with cutaneous elements	consists of collected mucin from a ruptured salivary gland/duct.
Treatment	Excision	Excision	Includes excision in continuity with the sublingual and sometimes submandibular gland of origin.

case of cysts located below the oral diaphragm an extra-oral approach is preferred [13, 16]. Most authors agree that removal of a plunging ranula includes excision of both the lesion and the associated sublingual gland via an extraoral and intraoral approach [17]. In the presented case the course and extent of the surgery were determined by the intraoperative assessment with cyst wall puncture. The biopsy of the lesion and assessment of its contents determine the diagnosis and contribute to decide about the extent of surgery in cases of uncertain diagnosis of a plunging ranula [18].

Conflict of interest statement: All authors disclose any financial and personal relationships with other people or organisations that could inappropriately influence (bias) their work.

References

- [1] Lyngdoh T.S., et al., Giant sublingual epidermoid cyst—An unusual case report, *Indian J Surg*, 2010, 72(Suppl 1), p. 318-320
- [2] Ozan F., et al., Epidermoid cyst of the buccal mucosa: a case report, *J Contemp Dent Pract*, 2007, 8(3), p. 90-96
- [3] Kalra V., Mirza K., and Malhotra A., Plunging ranula, *J Radiol Case Rep*, 2011, 5(6), p. 18-24
- [4] Zhi K., Wen Y., and Zhou H., Management of the pediatric plunging ranula: results of 15 years' clinical experience, *Oral Surg Oral Med Oral Pathol Oral Radiol Endod*, 2009, 107(4), p. 499-502
- [5] Jain R., Morton R.P., and Ahmad Z., Diagnostic difficulties of plunging ranula: case series, *J Laryngol Otol*, 2012, 126(5), p. 506-510
- [6] Gupta A. and Karjodkar F.R., Plunging ranula: a case report, *ISRN Dent*, 2011, p. 806928
- [7] Coit W.E., et al., Ranulas and their mimics: CT evaluation, *Radiology*, 1987, 163(1), p. 211-216
- [8] Shine N. and Lacy P., Large plunging ranula with no intraoral component: a rare clinical entity, *Ir Med J*, 2005, 98(4), p. 117
- [9] Saheeb B.D., Recurrent congenital bilateral ranula: a case report, *SADJ*, 2001, 56(8), p. 366-368
- [10] Kinoshita M., Kida W., and Nakahara H., Plunging ranula intruding into the parapharyngeal space treated with OK-432, *Am J Otolaryngol*, 2012, 33(3), p. 345-348
- [11] Dietrich E.M., et al., Sublingual-plunging ranula as a complication of supraomohyoid neck dissection, *Int J Surg Case Rep*, 2011, 2(6), p. 90-92
- [12] Kandogan T., et al., Sublingual epidermoid cyst: a case report, *J Med Case Rep*, 2007, 1, p. 87
- [13] Tsirevelou P., et al., Epidermoid cyst of the floor of the mouth: two case reports, *Cases J*, 2009, 2, p. 9360
- [14] Prepageran N., Rahmat O., and Kuljit S., Epidermal cyst of submandibular gland, *Med J Malaysia*, 2005, 60(4), p. 483-484
- [15] Chaturvedi J., et al., Submental Epidermoid Cyst- A Case Report, *Int J Head and Neck Surg*, 2010, 4(2)
- [16] Bataineh A.B. and Mansour M.J., Extraoral epidermoid cysts, *Br J Oral Maxillofac Surg*, 1997, 35(1), p. 49-51
- [17] Sigismund P.E., et al., Management of Ranula: 9 Years' Clinical Experience in Pediatric and Adult Patients, *J Oral Maxillofac Surg*, 2012
- [18] Samant S., Morton R.P., and Ahmad Z., Surgery for plunging ranula: the lesson not yet learned?, *Eur Arch Otorhinolaryngol*, 2011, 268(10), p. 1513-1518