

The Middle Glenohumeral Ligament Test for the Diagnosis of Subscapularis Lesions



Laurent Nové-Josserand, M.D., Thomas Chauvet, M.D., Emil Haritnian, M.D., Philippe Collotte, M.D., Lorenzo Merlini, M.D., and Thais Dutra Vieira, M.D.

Abstract: Arthroscopy has improved the diagnosis of subscapularis tendon lesions, and the outcomes of arthroscopic repair are satisfactory. Nonetheless, the diagnosis of some partial- and full-thickness subscapularis tears remains challenging. The middle glenohumeral ligament inserts distally into the articular surface of the subscapularis tendon and can be displaced when the subscapularis tendon is torn with retraction. This article describes the middle glenohumeral ligament test, which allows retracted lesions of the subscapularis tendon to be detected even if the superior edge is visible and normally placed. In addition, it allows control of the subscapularis tendon repair.

Whereas isolated subscapularis (SSC) tendon tears are rare, studies have reported that combined supraspinatus and SSC tears are more frequent than expected.^{1,2} The existence of partial tears and tears in continuity that are poorly diagnosed, paired with the fact that the lesser tuberosity is difficult to fully visualize using a 30° arthroscope from the standard posterior portal, can make an accurate diagnosis difficult and underestimate the true incidence of these partial tears of the SSC^{1,3,4}; to mitigate this, indirect signs of SSC lesions have been described.⁵

The Lafosse classification is most commonly applied for SSC lesions.² However, its application can be especially challenging when (1) there is a complete lesion and retraction of the SSC tendon to the glenoid,

preventing optimal visualization, and (2) the superior horizontal part of the tendon is observed, falsely suggesting the integrity of the SSC.

The middle glenohumeral ligament (MGHL) interacts closely with the SSC tendon, notably through its insertion into the latter, crossing it perpendicularly. Apart from rare cases in which the MGHL is truly absent and any other factors preventing normal exploration of the joint, non-observation of the MGHL may be a sign of a retracted SSC tear.⁶

Surgical Technique

Positioning

The patient is placed supine in the beach-chair position on the operating table (Maquet, Rastatt, Germany), with 3 kg of constant traction applied in women and 4 kg applied in men. This traction orients the arm in neutral rotation and 30° to 40° of forward flexion.

Portal Placement

A 4-mm arthroscope (Stryker, Kalamazoo, MI) at 30° of angulation is introduced posteriorly through the soft point, allowing the different intra-articular anatomic structures to be explored. Through this approach, the horizontal part of the SSC tendon is immediately reached between the humeral head and glenoid, with the MGHL crossing the tendon perpendicularly (Fig 1). The anterolateral portal is then created, and exploration is possible either through the rupture of the superior rotator cuff or through access created in the bicipital groove in cases in which there is an isolated SSC tear.

From Centre Orthopédique Santy (L.N.-J., T.C., P.C., L.M., T.D.V.), Lyon, France; Hopital Privé Jean Mermoz, Ramsay-Générale de Santé (L.N.-J., T.C., P.C., L.M., T.D.V.), Lyon, France; and "Carol Davila" University of Medicine and Pharmacy, Foisor Clinical Hospital of Orthopedics (E.H.), Bucharest, Romania.

The authors report the following potential conflicts of interest or sources of funding: L.N.-J. receives royalties from 35 Ortho and performs consulting for Mitek. Full ICMJE author disclosure forms are available for this article online, as supplementary material.

Received August 3, 2019; accepted September 13, 2019.

Address correspondence to Laurent Nové-Josserand, M.D., Centre Orthopédique Santy, 24 Avenue Paul Santy, Lyon 69008, France. E-mail: lnovejosserand.md@orthosanty.fr

© 2019 by the Arthroscopy Association of North America. Published by Elsevier. This is an open access article under the CC BY-NC-ND license (<http://creativecommons.org/licenses/by-nc-nd/4.0/>).

2212-6287/19952

<https://doi.org/10.1016/j.eats.2019.09.013>

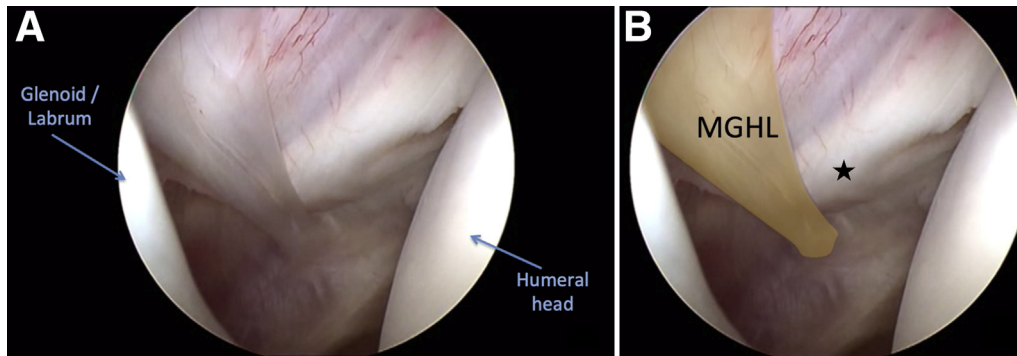


Fig 1. Arthroscopic view of a right shoulder in the beach-chair position from the posterior portal with a 30° arthroscope visualizing the space between the humeral head and glenoid (A) and showing the middle glenohumeral ligament (MGHL) crossing the subscapularis tendon (star) perpendicularly (B).

Arthroscopic Exploration and MGHL Test

Visualization of the MGHL crossing the SSC superior tendon perpendicularly is the first objective. The MGHL can be followed until its distal insertion, at a variable height, in the articular surface of the SSC tendon.⁶ The absence of proper visualization of the MGHL is a warning for a retracted lesion of the SSC tendon; therefore, in these cases, complete investigation of the SSC tendon is mandatory.

The integrity of the upper edge of the SSC tendon does not eliminate the possibility of a partial lesion of the SSC tendon; in fact, it can be a trap during the arthroscopic inquiry. The detachment of the SSC fibers off the lesser tuberosity leads to a naked appearance of the bone and corresponds to a partial lesion limited to the deeper articular layer of the SSC tendon. This lesion can be variably located, and sometimes it is necessary to position the shoulder in internal rotation to relax the SSC tendon, aiding arthroscopic exploration. In the event of non-visualization of the upper edge of the SSC

tendon, a complete tear of the SSC tendon retracted to the glenoid is suggested (Fig 2). In both situations, a soft traction gesture by an arthroscopic grasper in the parallel tendon axis toward the humerus can reduce the lesion and expose the MGHL, which returns to its anatomic position, crossing the upper SSC tendon. Such a maneuver configures the MGHL test as positive and allows a retraction quantification, regardless of the lesion type.

The MGHL test fails in the rare cases of agenesis of the MGHL (2%).⁶ Moreover, the MGHL test can be used as a control for the SSC tendon repair. Anatomic reattachment of the SSC tendon in the lesser tuberosity is achieved, along with restoration of the anatomic position of the MGHL. At the time of the repair, when the suture passes through the SSC, it is mandatory to avoid the MGHL because this could restrict external rotation (Fig 3). After the repair, the SSC tendon is visible in its anatomic position and the MGHL crosses it perpendicularly (Video 1). Table 1 lists pearls and pitfalls of the

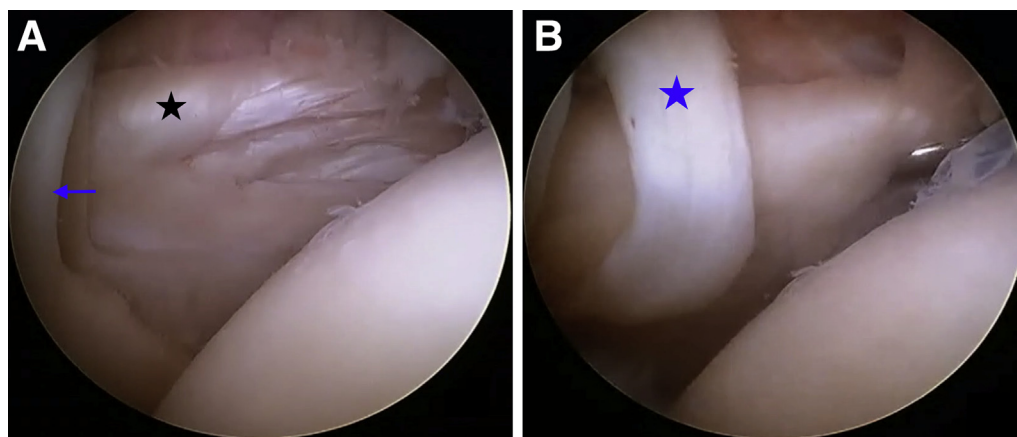


Fig 2. Arthroscopic view of a right shoulder in the beach-chair position from the posterior portal with a 30° arthroscope. (A) Partial lesion of the subscapularis tendon (star) and its relation with the glenoid (arrow). (B) Positive test finding. Traction can reduce the lesion and expose the middle glenohumeral ligament (star) previously retracted behind the glenoid, which returns to its anatomic position, crossing the upper subscapularis tendon.

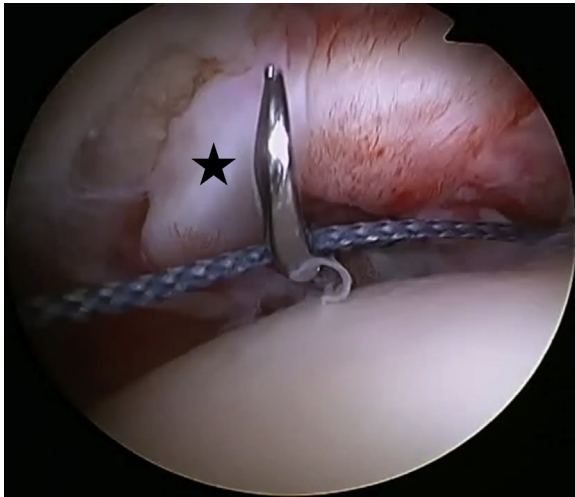


Fig 3. Arthroscopic view of a right shoulder in the beach-chair position from the posterior portal with a 30° arthroscope visualizing the repair. The repair suture should not pass through the middle glenohumeral ligament (star) because this could restrict external rotation.

described technique, and [Table 2](#) presents advantages and disadvantages.

Discussion

The main interest in the MGHL test lies in the challenging diagnosis of retracted tears of the SSC. For massive tears retracted to the glenoid (Lafosse stage 4), neither the MGHL nor the SSC tendon is visible during initial arthroscopic exploration, showing the great relevance of the MGHL test. The MGHL test is also helpful for retracted tears of Lafosse stages 2 and 3,² in which the superior horizontal border of the SSC can falsely suggest that the whole tendon is intact, leading to a potential misdiagnosis.

Table 1. Pearls and Pitfalls

Pearls

- The MGHL is one of the first structures observed through the posterior portal.
- The MGHL should be avoided when the suture passes through the SSC tendon.

Pitfalls

- The MGHL was absent in 2% of a previously studied population.⁶
- If the MGHL is fixed to the lesser tuberosity, this could restrict external rotation.
- MGHL resection should be avoided during debridement of the SSC tendon tear.

MGHL, middle glenohumeral ligament; SSC, subscapularis.

Table 2. Advantages and Disadvantages

Advantages

- The MGHL test is a simple maneuver that detects retracted lesions of the SSC tendon, which can be easily missed.
- The MGHL test allows control of the anatomic repair of the SSC.

Disadvantages

- The MGHL test is only helpful for retracted lesions of the SSC.
- If a retracted lesion of the SSC is located superiorly to the MGHL distal insertion, the test might yield a false-negative result.

MGHL, middle glenohumeral ligament; SSC, subscapularis.

An additional pearl of the MGHL test involves controlling the anatomic repair of the SSC tear. The MGHL can be used as a dynamic marker during reduction of the retracted tendon using a grasper. The test highlights the need for reduction of the tendon back to its anatomic position before reattachment to the lesser tuberosity. In these cases, the repositioning of the MGHL will restore the anatomic features represented by the MGHL crossing the superior horizontal border of the SSC. Moreover, the distal insertion of the MGHL should not be shifted onto the humerus during tendon repair because this nonanatomic position risks limiting external rotation. Two limitations are related to the MGHL test: First, it has been described that 2% of a previously studied population had MGHL agenesis.⁶ Second, SSC lesions located superiorly to the MGHL distal insertion will be missed by the described test (false-negative result).

References

1. Lee J, Shukla DR, Sánchez-Sotelo J. Subscapularis tears: Hidden and forgotten no more. *JSES Open Access* 2018;2:74-83.
2. Lafosse L, Jost B, Reiland Y, Audebert S, Toussaint B, Gobezie R. Structural integrity and clinical outcomes after arthroscopic repair of isolated subscapularis tears. *J Bone Joint Surg Am* 2007;89:1184-1193.
3. Koo SS, Burkhart SS. Subscapularis tendon tears: Identifying mid to distal footprint disruptions. *Arthroscopy* 2010;26:1130-1134.
4. Denard PJ, Burkhart SS. Arthroscopic recognition and repair of the torn subscapularis tendon. *Arthrosc Tech* 2013;2:e373-e379.
5. Sahu D, Fullick R, Giannakos A, Lafosse L. Sentinel sign: A sign of biceps tendon which indicates the presence of subscapularis tendon rupture. *Knee Surg Sports Traumatol Arthrosc* 2016;24:3745-3749.
6. Collette P, Nové-Josserand L. Arthroscopic anatomy of the middle glenohumeral ligament. *Surg Radiol Anat* 2018;40:1363-1370.