

Post Filtering Surgery Globe Massage-induced Keratoconus in an Eye with Iridocorneal Endothelial Syndrome: A Case Report and Literature Brief Review

Ghasem Fakhraie, MD; Zakieh Vahedian, MD

Glaucoma Service, Farabi Eye Hospital, Tehran University of Medical Sciences, Tehran, Iran

Abstract

Purpose: To report a case of unilateral post trabeculectomy globe massage-induced keratoconus (KCN).

Case Report: A 52-year-old lady with a history of trabeculectomy due to iridocorneal endothelial syndrome in her right eye was instructed to massage her globe to control gradual rise of intraocular pressure 1.5 years after surgery. The patient experienced high astigmatism and marked inferior corneal steepening after 3 years of globe massage. The left eye was normal in all aspects. Findings in different visual examinations were compatible with the diagnosis of unilateral KCN in the right eye of our patient.

Conclusion: Chronic forceful frequent eye rubbing particularly with fingertips can be assumed to be the most important causative factor for KCN formation in this patient.

Keywords: Globe Massage; Iridocorneal Endothelial Syndrome; Keratoconus; Trabeculectomy

J Ophthalmic Vis Res 2016; 11 (3): 319-322.

INTRODUCTION

Keratoconus (KCN) is a common ectatic corneal disorder characterized by the corneal protrusion and thinning which is associated with several systemic conditions. Some of them are characterized with abnormal collagen fibers such as Ehlers–Danlos syndrome, osteogenesis imperfecta, or nail patella syndrome; others are associated with abnormal recurrent oculodigital stimulation and eye rubbing due to abnormal retinal function, mental disorders or atopy and eczema.^[1] Eye rubbing is one of the most common environmental factors to be associated with KCN. In a multivariate analysis of potential risk factors of KCN, only eye rubbing was a significant predictor of KCN development,^[2] which is one of the potential causes of recurrent KCN in transplanted corneas as well.^[3,4] The majority of KCN cases have been reported to be related to vigorous eye rubbing due to various causes such as atopy,^[5] Tourette syndrome,^[6,7] Down syndrome^[8] or the necessity for eye wiping in nasolacrimal duct obstruction^[9] and punctual agenesis.^[10]

Correspondence to:

Zakieh Vahedian, MD. Glaucoma Service, Farabi Eye Hospital, Qazvin Square, South Kargar Avenue, Tehran 13366, Iran. E-mail: vahedian.z@gmail.com

Received: 16-08-2014 Accepted: 12-02-2015

Herein, we report a case of acquired unilateral KCN in a middle-aged lady secondary to a forceful persistent globe massage after trabeculectomy.

CASE REPORT

A 52-year-old lady was referred to our clinic for uncontrolled intraocular pressure (IOP) in her right eye. Her family history and personal medical history were not significant. Uncorrected visual acuity was 10/10 in both eyes. Refraction was +0.50–0.50 × 90° and Plano -0.50 × 165° in the right and left eyes, respectively. IOP was 38 mmHg with full topical antiglaucoma medications in the right eye and 16 mmHg without any medication in the left eye. Slit lamp biomicroscopy of the right eye showed a clear cornea and mild corectopia. High peripheral anterior synechiae extending 360 degrees was noted on gonioscopy of the right eye. Fundus examination showed cup to disc ratio of about 0.8 in this eye. Examination of the left eye was

Access this article online

Quick Response Code:



Website:
www.jovr.org

DOI:
10.4103/2008-322X.158896

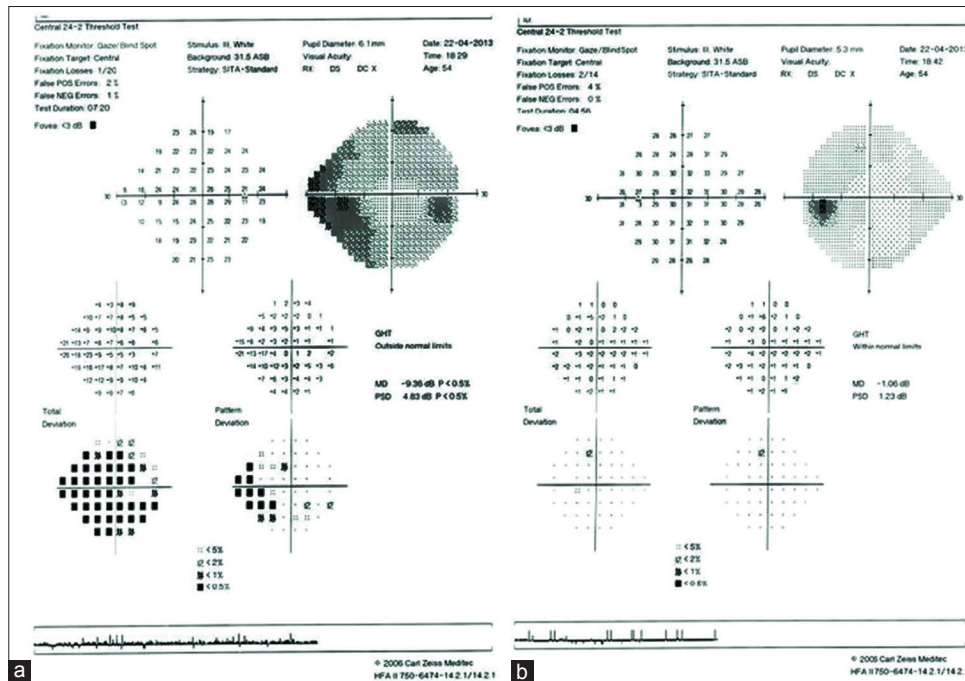


Figure 1. Central 24-2 standard automated perimetry of the patient at presentation. (a) Right eye; (b) left eye.

completely normal. Standard automated perimetry of both eyes is presented in Figure 1. The diagnosis of iridocorneal endothelial (ICE) syndrome for the right eye was made. She underwent standard trabeculectomy with mitomycin C (MMC) in the right eye using two releasable sutures for closure of the scleral flap. IOP was less than 15 mmHg with diffuse functioning bleb and without medication or globe massage for 1.5 years post-operatively. After this period, IOP started to rise, and the bleb was anteriorly localized. She was instructed to massage her right globe with her fingertip from the inferior aspect 10 times a day, 10 seconds each time. IOP was relatively controlled thereafter. IOP-lowering agents were also administered in follow-up visits due to gradually IOP rising. Three years after globe massage, the patient complained of vision loss in her right eye which was due to high astigmatism. Retinoscopic refraction was $+1.25-4.50 \times 20^\circ$ with a scissor motion and slit lamp examination revealed Vogt's striae in the right cornea [Figure 2]. Pentacam corneal images of the two eyes at this time are shown in Figures 3 and 4; which is compatible with KCN in the right eye. Corneal imaging of the left eye was within normal limits. Needle bleb revision with adjunctive MMC was performed at that time and IOP remained controlled for about 4 months. Finally, our patient underwent a shunting procedure with Ahmed glaucoma valve insertion.

DISCUSSION

Keratoconus is a usually bilateral keratectasia which may be markedly asymmetric at presentation. Nevertheless, many monocular cases of KCN have also been reported;

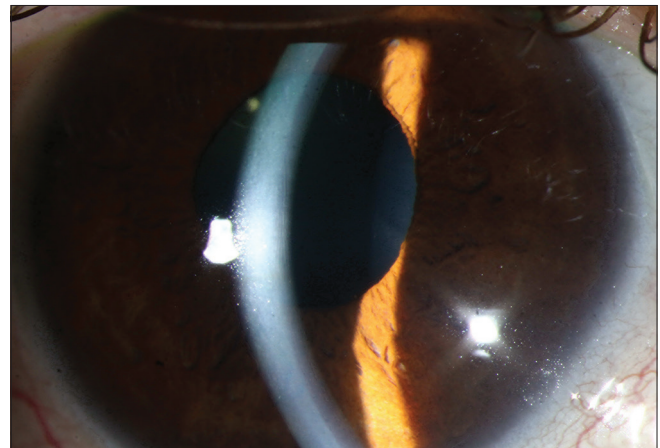


Figure 2. Slit photograph of the right eye after 3 years of the globe massage showing Vogt's striae.

mostly attributed to persistent eye rubbing. In The Dundee University Scottish Keratoconus Study, 89% of the keratoconic patients reported eye rubbing, nearly half of them (48%) classified this habit as either "frequently or great deal", whereas 39% of the control subjects reported the same classification; this difference was statistically significant ($P = 0.018$).^[11] In the Collaborative Longitudinal Evaluation of keratoconus study, the rate of vigorous eye rubbing was 50.4% (48.2% in both eyes, 2.2% in one eye).^[12] Rabinowitz has also reported higher rate of eye rubbing in KCN patients than normal ones (80% vs. 58%; $P < 0.001$).^[13] Although none of these studies confirm a cause and effect relationship between eye rubbing and KCN, the many reports with unilateral KCN^[9,10,14] or more

severe corneal steepening^[7,15,16] in cases of unilateral eye rubbing lead us to conclude a strong predisposing role for eye rubbing in development or progression of KCN.

KCN is generally classified as a noninflammatory condition; however, many inflammatory proteins such as matrix metalloproteinases (MMP) -1, -3, -7, -13, interleukins (IL) -4, -5, -6, -8 and tumor necrosis factor (TNF) - α , - β are present in excess amounts in the tear film of KCN patients compared to the normal individuals.^[17] Furthermore, collagenolytic and gelatinolytic activity of the tear film^[17] as well as cultured corneal cells^[18] of the keratoconic eyes is higher than normal subjects. In a recent

experimental study, Balasubramanian et al have shown that level of tear MMP-13, IL-6, and TNF- α increase after 60 seconds of eye rubbing in normal individuals and have suggested that this elevated protease activity and inflammatory mediators level after eye rubbing may be more pronounced even after persistent and vigorous eye rubbing.^[19] This, in turn, may explain higher levels of these proteins in tear film of KCN patients and may contribute to development or progression of the disease in response to eye rubbing.

In a detailed review of the potential mechanisms of eye rubbing induced KCN, McMonnies has mentioned

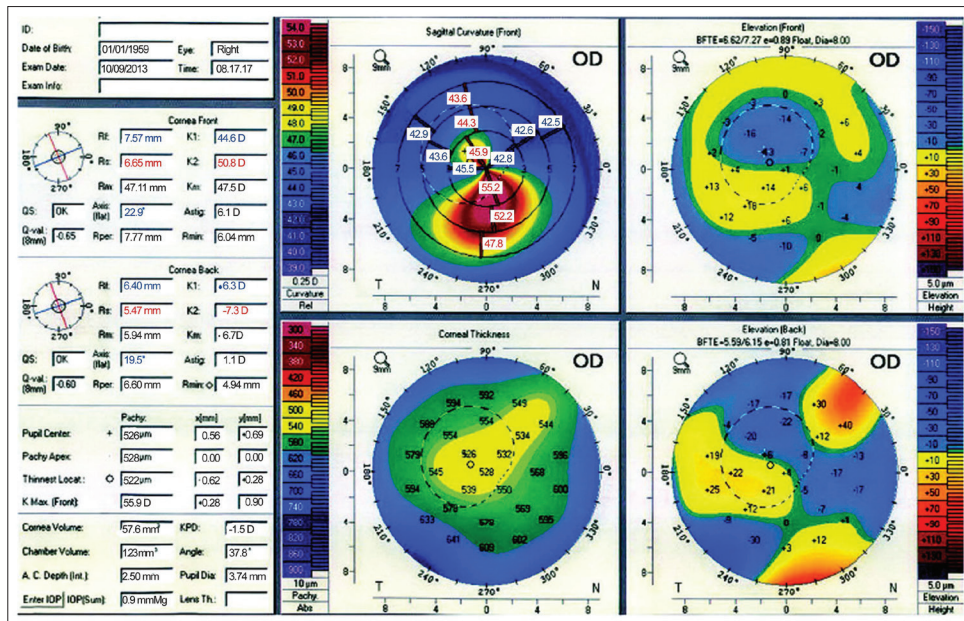


Figure 3. Pentacam corneal imaging of the right eye after 3 years of the globe massage. Marked inferior steepening is present in the sagittal curvature view.

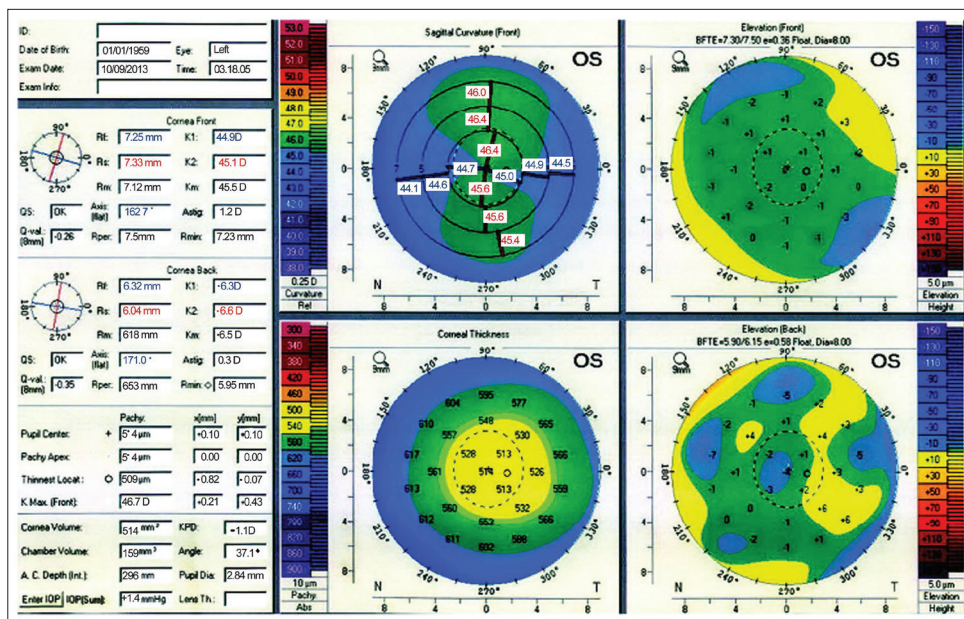


Figure 4. Pentacam corneal imaging of the left eye after 3 years of the globe massage of the right eye.

that apart from inflammatory and cellular theories, some mechanical theories may also be postulated.^[20] Forced eye rubbing along with eyelid closure may lead to high IOP spikes^[20] which together with compressive forces of rubbing itself increases the corneal hydrostatic tissue pressure to very high levels. This hydrostatic pressure is the maximum at the corneal apex. Some other rubbing-induced changes that are more pronounced at the apex are displacement of ground substance, buckling and flexure of fibrils associated with waves of corneal indentation. Due to higher stability of corneal collagen fibers at the limbus, curvature transfer to the cone apex, and slippage between collagen fibrils occurred.^[20] Therefore, KCN may develop due to the mechanical fatigue which may result from shear and tensile stress, caused by eye rubbing and IOP fluctuation, respectively.^[21]

The frequency of eye rubbing and its force are important especially in genetically predisposed subjects.^[20,21] The more forceful and frequent, the higher the risk of KCN formation. Eye rubbing habit has been categorized into two groups; 1) rubbing with a flat instrument such as palms broadly over the eyelids which usually occurs in allergic people, and 2) rubbing with a tipped pointed instrument such as fingertips or knuckles against a small area of globe often directed posteriorly. The second type is commonly seen in keratoconic patients and results in transmission of a great amount of force to a small surface leading to high pressures.^[22] Herein, we have reported a case of KCN formation secondary to globe massage after trabeculectomy. Globe massage technique is similar to the second type of ocular rubbing described above. The patient should apply focal pressure constantly and firmly using the fingertip to the undersurface of the globe for about ten seconds^[23] to push aqueous outward through the sclerostomy site. Our patient stated that she massaged her globe very forcefully to achieve better IOP control, and this fact may be contributing to KCN formation in her right eye. To the best of our knowledge, only one case report of post trabeculectomy globe massage induced keratectasia has been reported in the literature,^[24] and our case is the first case which has occurred in an eye with ICE syndrome. As there was no sign of even subclinical KCN in the left eye, it can be assumed that right eye KCN was acquired and secondary to globe massage.

REFERENCES

- Sugar J, Macsai MS. What causes keratoconus? *Cornea* 2012;31:716-719.
- Bawazeer AM, Hodge WG, Lorimer B. Atopy and keratoconus: A multivariate analysis. *Br J Ophthalmol* 2000;84:834-836.
- Koenig SB. Bilateral recurrent self-induced keratoconus. *Eye Contact Lens* 2008;34:343-344.
- Yeniad B, Alparslan N, Akarcay K. Eye rubbing as an apparent cause of recurrent keratoconus. *Cornea* 2009;28:477-479.
- Gasset AR, Hinson WA, Frias JL. Keratoconus and atopic diseases. *Ann Ophthalmol* 1978;10:991-994.
- Kandarakis A, Karampelas M, Soumplis V, Panos C, Makris N, Kandarakis S, Karagiannis D. A case of bilateral self-induced keratoconus in a patient with Tourette syndrome associated with compulsive eye rubbing: Case report. *BMC Ophthalmol* 2011;11:28.
- Mashor RS, Kumar NL, Ritenour RJ, Rootman DS. Keratoconus caused by eye rubbing in patients with Tourette syndrome. *Can J Ophthalmol* 2011;46:83-86.
- Ozcan AA, Ersoz TR. Severe acute corneal hydrops in a patient with Down syndrome and persistent eye rubbing. *Ann Ophthalmol (Skokie)* 2007;39:158-160.
- Diniz CM, Tzelikis PF, Rodrigues Júnior A, Alvim Hda S, Dantas RR, Figueredo AR. Unilateral keratoconus associated with continual eye rubbing due to nasolacrimal obstruction – Case report. *Arq Bras Oftalmol* 2005;68:122-125.
- Lindsay RG, Bruce AS, Gutteridge IF. Keratoconus associated with continual eye rubbing due to punctal agenesis. *Cornea* 2000;19:567-569.
- Weed KH, MacEwen CJ, Giles T, Low J, McGhee CN. The Dundee University Scottish Keratoconus study: Demographics, corneal signs, associated diseases, and eye rubbing. *Eye (Lond)* 2008;22:534-541.
- Zadnik K, Barr JT, Edrington TB, Everett DF, Jameson M, McMahon TT, Shin JA, Sterling JL, Wagner H, Gordon MO. Baseline findings in the Collaborative Longitudinal Evaluation of Keratoconus (CLEK) study. *Invest Ophthalmol Vis Sci* 1998;39:2537-2546.
- Rabinowitz YS. Keratoconus. *Surv Ophthalmol* 1998;42:297-319.
- Ioannidis AS, Speedwell L, Nischal KK. Unilateral keratoconus in a child with chronic and persistent eye rubbing. *Am J Ophthalmol* 2005;139:356-357.
- Jafri B, Lichter H, Stulting RD. Asymmetric keratoconus attributed to eye rubbing. *Cornea* 2004;23:560-564.
- Zadnik K, Steger-May K, Fink BA, Joslin CE, Nichols JJ, Rosenstiel CE, Tyler JA, Yu JA, Raasch TW, Schechtman KB; CLEK Study Group. Collaborative Longitudinal Evaluation of Keratoconus. Between-eye asymmetry in keratoconus. *Cornea* 2002;21:671-679.
- Balasubramanian SA, Mohan S, Pye DC, Willcox MD. Proteases, proteolysis and inflammatory molecules in the tears of people with keratoconus. *Acta Ophthalmol* 2012;90:e303-309.
- Balasubramanian SA, Pye DC, Willcox MD. Are proteinases the reason for keratoconus? *Curr Eye Res* 2010;35:185-191.
- Balasubramanian SA, Pye DC, Willcox MD. Effects of eye rubbing on the levels of protease, protease activity and cytokines in tears: Relevance in keratoconus. *Clin Exp Optom* 2013;96:214-218.
- McMonnies CW. Mechanisms of rubbing-related corneal trauma in keratoconus. *Cornea* 2009;28:607-615.
- Norouzpour A, Mehdizadeh A. A novel insight into keratoconus: Mechanical fatigue of the cornea. *Med Hypothesis Discov Innov Ophthalmol* 2012;1:14-17.
- Carlson AN. Expanding our understanding of eye rubbing and keratoconus. *Cornea* 2010;29:245.
- Quaranta L. A new device for ocular massage after trabeculectomy. *Acta Ophthalmol Scand* 1999;77:355-356.
- Baldassare RD, Brunette I, Desjardins DC, Amyot M. Corneal ectasia secondary to excessive ocular massage following trabeculectomy with 5-fluorouracil. *Can J Ophthalmol* 1996;31:252-254.

How to cite this article: Fakhraie G, Vahedian Z. Post filtering surgery globe massage-induced keratoconus in an eye with iridocorneal endothelial syndrome: A case report and literature brief review. *J Ophthalmic Vis Res* 2016;11:319-22.

Source of Support: Nil. **Conflict of Interest:** None declared.