



Received: 2016.02.06
Accepted: 2016.02.22
Published: 2016.09.20

Authors' Contribution:

- A** Study Design
- B** Data Collection
- C** Statistical Analysis
- D** Data Interpretation
- E** Manuscript Preparation
- F** Literature Search
- G** Funds Collection

Tuberculosis Penis with 'Watering Can Penis' Appearance: Report of a Rare Case with Retrograde Urethrography and Voiding Cystourethrography Findings

Kamala Retnam Mayilvaganan^{DE}, Naren Satya Srinivas M.^{AD}, Vikram N. Reddy^{BC},
Ranjeet Kumar Singh^{DE}

Department of Radiodiagnosis, M.V. Jayaram Medical College and Research Hospital, Hosakote, Bangalore, India

Author's address: Kamala Retnam Mayilvaganan, Department of Radiodiagnosis, M.V. Jayaram Medical College and Research Hospital, Hosakote, Bangalore, India, e-mail: kamalret2@gmail.com

Background:

A 'watering can penis' secondary to penile tuberculosis is an extremely rare clinical entity. Retrograde Urethrography – Voiding Cystourethrography evaluation of the urethra and the urinary bladder plays a very important role in the diagnostics as well as further management of the urethral abnormalities. To the best of our knowledge, this is only the second case in literature where a 'watering can penis' was noted secondary to penile TB. This is also the first documented case of 'watering can penis' as a consequence of venereal transmission of TB.

Case Report:

A 50-year-old male presented with multiple discharging sinuses along the penis. RGU revealed multiple, contrast-filled, narrow, irregular, fistulous tracts arising from the pendulous part of the anterior urethra. This distal segment of the pendulous part of the anterior urethra also showed significant distortion and irregular, beaded narrowing. VCUG showed a markedly-contracted and small-capacity urinary bladder with a thickened, irregular and edematous wall with multiple hypertrophied trabeculae along its walls. The patient was administered anti-tubercular treatment. At the end of this treatment regimen, a repeat RGU-VCUG will be performed and decision regarding urethroplasty and further management will be planned depending upon the presence of any remaining fistulas or strictures involving the urethra.

Conclusions:

'Watering can penis' as a result of penile TB is a very rare clinical entity. The differential diagnoses of a 'watering can penis' should be kept in mind in the evaluation of these patients. RGU and VCUG evaluation is an important conventional imaging modality used in the evaluation of urethral strictures and fistulas in case of 'watering can penis'.

MeSH Keywords:

Cutaneous Fistula • Tuberculosis, Male Genital • Urethral Stricture

PDF file:

<http://www.polradiol.com/abstract/index/idArt/897943>

Background

A 'watering can penis' secondary to penile tuberculosis is an extremely rare clinical entity. Retrograde Urethrography – Voiding Cystourethrography (RGU-VCUG) evaluation of the urethra and the urinary bladder plays a very important role in the diagnostics as well as further management of the urethral abnormalities. Despite its rarity, it is imperative for a radiologist to be aware of this radiological appearance as well as of possible differential diagnoses of this entity. In this paper, we aimed to describe a case of 'watering can penis' with conventional RGU-VCUG

findings. We also discussed the role of other imaging modalities in case of a 'watering can penis'. To the best of our knowledge, this is only the second case in literature where a 'watering can penis' was noted secondary to penile TB. This is also the first documented case of 'watering can penis' as a consequence of venereal transmission of TB.

Case Report

A 50-year-old, homeless male presented to the Department of General Surgery with complaints of multiple discharging sinuses along the penis for 1 month. He also gave a

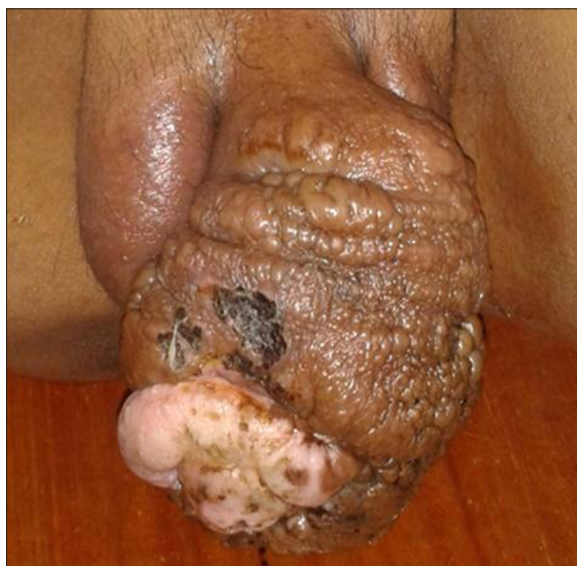

Figure 1. Clinical photograph showing an ulceroproliferative growth of the penis.

history of gradually increasing swelling of the penis for 1 year and a purulent discharge per urethra for the last 6 months. At physical examination, there was an ulceroproliferative growth of the penis (Figure 1). The penis and the glans penis were tender, edematous and indurated. However, both the testes and the epididymis were normal. The vas deferens was normal on palpation. The prostate was normal on rectal examination. Preliminary laboratory investigations revealed high sedimentation, C-reactive protein (CRP) and leukocytosis. He was referred to our Radio-Diagnosis Department for Retrograde Urethrography – Voiding Cystourethrography (RGU-VCUG) evaluation.

RGU was performed through the distorted external urethral meatus which was first identified by asking the patient to micturate to observe the main stream of urine. RGU revealed multiple (around 15 to 20), contrast-filled, narrow, irregular, fistulous tracts (urethrocutaneous fistulas) arising from both the dorsal and ventral aspects of the pendulous (penile) part of the anterior urethra (Figure 2). This distal segment of the pendulous part of the anterior urethra also showed significant distortion and irregular, beaded narrowing. The proximal segment of the pendulous part of the anterior urethra showed smooth and regular dilation. The bulbous part of the anterior urethra as well as the prostatic and the membranous parts of the posterior urethra showed adequate filling of contrast and a regular outline with no evidence of communicating sinus/fistulous tracts. The VCUG showed a markedly-contracted and small-capacity urinary bladder with a thickened, irregular and edematous wall. There were multiple nodular densities in the bladder lumen suggestive of hypertrophied trabeculae along its anterior, posterior and lateral walls, representative of a ‘thimble bladder’ (Figure 3). There was no evidence of reflux into the ureters during micturition.

Chest radiograph (posteroanterior view) ruled out presence of pulmonary Koch’s (both active as well as old, healed pulmonary Koch’s). Scrotal ultrasound revealed normal testes and epididymis. Renal ultrasound showed no calyceal or

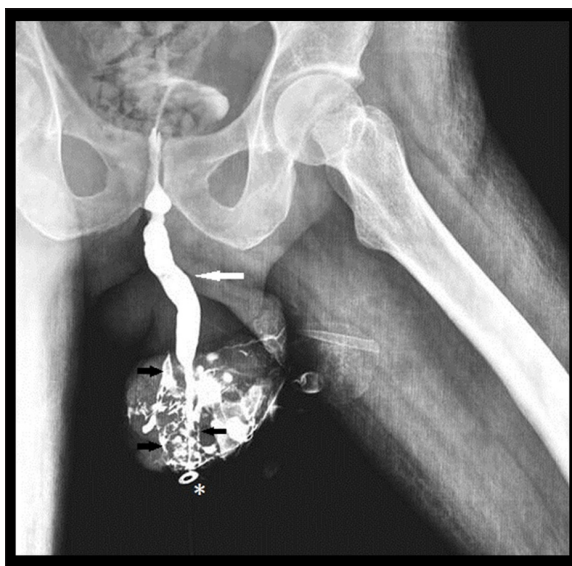

Figure 2. Retrograde urethrogram showing multiple, contrast-filled, narrow, irregular, fistulous tracts (black arrows) arising from the pendulous part of the anterior urethra with significant distortion and irregular, beaded narrowing. The proximal segment of the pendulous part of the anterior urethra shows smooth and regular dilation (white arrow). The distorted external urethral meatus (asterisk) was identified by asking the patient to micturate to observe the main stream of urine.

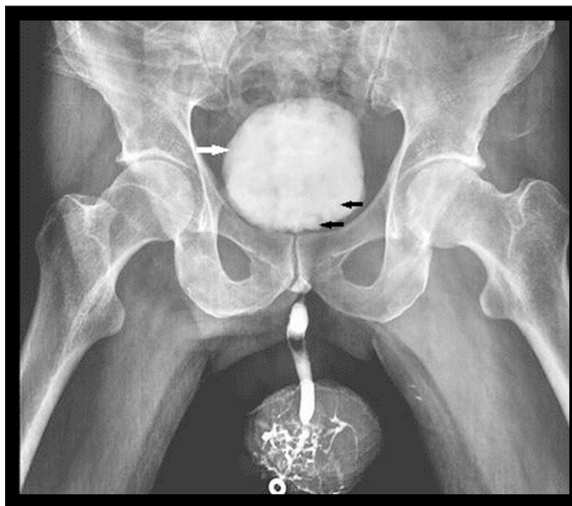


Figure 3. A ‘thimble bladder’ on voiding cystourethrogram showing a markedly-contracted and small-capacity urinary bladder with a thickened, irregular and edematous wall (white arrow) and multiple nodular densities in the bladder lumen suggestive of hypertrophied trabeculae (black arrows) along its walls. No reflux into the ureters during micturition was seen.

papillary abnormality/hydronephrosis. Intravenous urography showed no evidence of renal or ureteric tuberculosis. Mantoux test was strongly positive while pathological examination of discharge per urethra revealed caseating granulomas. Gram stain and culture examinations for gonorrhoea were negative while schistosomiasis was ruled out on the basis of microbiological studies of stool and urine

samples. Pseudoepitheliomatous, Keratotic and Micaceous Balanitis (PKMB) was excluded as the patient had not undergone prior circumcision and also because histopathological examination after an incisional biopsy revealed no evidence of acanthosis, papillomatosis, elongated rete ridges or cellular atypia. Balanitis Xerotica Obliterans (BXO) was ruled out on the basis of a normal Tzanck smear test.

The patient was administered anti-tubercular treatment (Isoniazid 300 mg, Rifampicin 600 mg, Pyrazinamide 1500 mg, and Ethambutol 800 mg per day). The patient started to show signs of improvement by 6 weeks. There was partial obliteration of the sinus and fistulous tracts. Since the patient's symptoms regressed, he was discharged and is being currently followed up as an out-patient. At the end of this treatment regimen, a repeat RGU-VCUG will be performed and decision regarding urethroplasty and further management will be planned depending upon the presence of any remaining fistulas or strictures involving the urethra.

Discussion

Tuberculosis (TB) can virtually affect any organ in the body. It demonstrates a wide spectrum of clinical and radiological findings and can hence mimic numerous other disease entities. In the recent years, there has been a resurgence of tuberculosis due to the acquired immunodeficiency syndrome (AIDS) epidemic and the increasing number of drug-resistant strains of *Mycobacterium tuberculosis*. The population groups at an increased risk of TB include immunocompromised patients, alcoholics, immigrants from third-world countries, elderly patients, poor, undernourished and homeless people living in unhygienic conditions [1].

Although pulmonary TB is the most common form of TB, it can involve multiple extrapulmonary sites including the central nervous system, heart, gastrointestinal system, bones and joints and genitourinary tract. The term 'genitourinary TB' was introduced by Wildbolz in 1937. Genitourinary system is the most common extrapulmonary system to be affected by this disease and genitourinary TB comprises 20% of all cases of extrapulmonary TB [2].

In males, genitourinary TB can be anatomically classified into renal TB (renal parenchyma, calyces and pelvis), bladder and ureteric TB, prostatic TB, scrotal TB (testes, epididymis, seminal vesicles, vas deferens) and penile TB. However, the involvement of the penis secondary to urethral TB is very, very rare. The aetiopathogenesis, clinical presentation and imaging features vary according to the specific part affected by TB. Patients with penile involvement mainly present with ulceration, painful/painless swelling of the penis, nodular lesions on the penis, burning micturition, urinary incontinence and/or frequency of micturition, difficulty in micturition, purulent discharge per urethra, hematuria and passing of urine through multiple urethrocuteaneous fistulae.

Genital TB usually results from antegrade infection within the urinary tract. The possible routes of infections include spread via infected urinary tract (descending infection

from the kidneys), spread via lymphatic system and spread through the blood stream (hematogenous spread) [2]. Female to male transmission (venereal transmission of TB) is very rare. In our case, only the urethra was affected by TB while the kidneys, prostate, seminal vesicles, epididymis and testes were all normal. This could be attributed to venereal transmission of TB which is extremely rare. The patient's wife who was evaluated for fever, weight loss and infertility was confirmed to have endometrial TB on the basis of an endometrial biopsy performed during the late secretory phase of her menstrual cycle.

We believe our case is only the second case in literature where 'watering can penis' was noted secondary to penile TB. K Karthikeyan, et al. first reported a case of 'watering can penis' secondary to urethral TB [3]. This is also the first documented case of 'watering can penis' as a consequence of venereal transmission of TB. A 'watering can penis' and/or 'watering can perineum' appearance on Retrograde Urethrography - Voiding Cystourethrography (RGU-VCUG) can be observed in genital TB, gonorrhoea, schistosomiasis, Pseudoepitheliomatous, Keratotic and Micaceous Balanitis (PKMB) and Balanitis xerotica obliterans (BXO) [4]. Fungal infections (eumycotic mycetoma or actinomycotic mycetoma) and lymphogranuloma venereum (LGV) infections can mimic watering can perineum by presenting as multiple discharging sinuses [5].

Diagnosis mainly relies on the clinical, pathological and radiological findings. RGU is the primary imaging tool used to image anterior urethral strictures. RGU helps define the location, length, number, and degree of strictures as well as the periurethral abnormality - important factors for determining appropriate treatment. During RGU, if the patient is not placed in a steep oblique position, the length of the stricture will be underestimated. More than one projection may be necessary to visualize the stricture [6]. An anterior urethral stricture can be observed on RGU as a narrowed segment of the urethra with inadequate contrast opacification and pre-stenotic dilation. There may also be periurethral abscesses appearing as regions of extravasated contrast material within the adjacent periurethral soft tissues in communication with the urethra. Urethroperineal fistulas are most often the consequence of a periurethral abscess. In general, the initial abscess cavity contracts by means of healing fibrosis, which leaves only a narrow fistulous tract from the urethra to the penis and/or the perineum. Consequently, urination usually occurs through the penile fistulas, which results in the so-called 'watering can penis'. Similar appearance in the perineum refers to 'watering can perineum'. VCUG is the most commonly used imaging method in the evaluation of the urinary bladder and the posterior urethral abnormalities. Ultrasonography can demonstrate the presence of periurethral abscess, and computed tomography (CT) and magnetic resonance imaging (MRI) are also useful adjuncts for assessing the extent of the periurethral abscess and complications such as fasciitis and Fournier gangrene [6]. In few cases, fistulography in addition to RGU may be useful for assessing the entire urethra because most of the contrast material exits the urethra through the urethroperineal fistulas, which may prevent visualization of the entire urethra [6]. Sonourethrography is also an increasingly utilized imaging

modality in the evaluation of anterior urethral strictures and 'watering can penis'. Mandal et al. observed that sonourethrography is a reliable investigation for evaluation of anterior urethral strictures in men. They also concluded that retrograde urethrography and sonourethrography are almost equally effective in detecting anterior urethral stricture but further characterization of the stricture such as stricture length and periurethral soft tissue abnormalities can be done with greater confidence and accuracy by sonourethrography. RGU has inherent limitations of exposure to radiation and risk of severe reaction to contrast medium. Also, alteration of patient posture and penile traction during injection of contrast medium before imaging can alter the radiographic appearance of the urethra and stricture area underestimating the actual length of the stricture [7]. Nash et al. and Choudhary et al. also observed that sonourethrography is more sensitive than RGU in characterization of strictures in terms of length, diameter and periurethral pathologies, like spongiofibrosis and false tracts [8,9].

Medical management mainly depends on treating the infection by targeting the causative organism. Anti-tubercular

regimen is started in cases of tuberculosis. Urethral dilators are used in treatment of cases where the urethral strictures are less severe. In more advanced and chronic cases, open urethroplasty is done to repair the narrowed segment of the urethra. Urinary flow diversion by a catheter placed in the abdomen to divert and drain urine flow is very rare and considered a last-resort option.

Conclusions

Genitourinary Tuberculosis (TB) has a wide spectrum of clinical and radiological manifestations. 'Watering can penis' appearance as a result of penile TB is a very rare clinical entity. The differential diagnoses of 'watering can penis' should be kept in mind in the evaluation of these patients. Retrograde urethrography and voiding cystourethrography (RGU-VCUG) evaluation is an important conventional imaging modality used in the evaluation of urethral strictures and fistulas in case of 'watering can penis'.

Conflicts of interest

None.

References:

1. Harisinghani MG, McLoud TC, Shepard JA et al: Tuberculosis from head to toe. *Radiographics*, 2000; 20: 449–70
2. Das P, Ahuja A, Gupta SD: Incidence, etiopathogenesis and pathological aspects of genitourinary tuberculosis in India: A journey revisited. *Indian J Urol*, 2008; 24(3): 356–61
3. Karthikeyan K, Thappa DM, Shivaswamy KN: Water can penis caused by tuberculosis. *Sex Transm Infect*, 2004; 80: 75
4. Adya KA, Palit A, Inamadar AC: Pseudoepitheliomatous keratotic and micaceous balanitis. *Indian J Sex Transm Dis*, 2013; 34(2): 123–25
5. Gupta S, Jain K, Parmar C et al: Mycetoma: Nonvenereal perineal lesions. *Indian J Sex Transm Dis*, 2010; 31(1): 39–41
6. Kawashima A, Sandler CM, Wasserman NF et al: Imaging of urethral disease: A pictorial review. *Radiographics*, 2004; 24(Suppl. 1): S195–216
7. Mandal SK, Bhattacharyya SK, Mandal A et al: Sonourethrography in the evaluation of anterior urethral stricture: Correlation with retrograde urethrography in male. *Int J Pharm Biomed Res*, 2012; 3(2): 77–80
8. Nash PA, McAninch JW, Bruce JE, Hanks DK: Sono-urethrography in the evaluation of anterior urethral strictures. *J Urol*, 1995; 154(1): 72–76
9. Choudhary S, Singh P, Sundar E et al: A comparison of sonourethrography and retrograde urethrography in evaluation of anterior urethral strictures. *Clin Radiol*, 2004; 59(8): 736–42