

## CASE REPORT

# Tendon rupture associated with concomitant simvastatin and gemfibrozil use: Biological and pharmacokinetic implications

Edison Jose Cano Cevallos<sup>1</sup>  | Danial Haris Shaikh<sup>2</sup> | Jose Gonzalez<sup>3</sup> | William Sanchez<sup>2</sup> | Madanmohan Patel<sup>2</sup>

<sup>1</sup>Division of Infectious Diseases, Mayo Clinic, Rochester, Minnesota

<sup>2</sup>BronxCare Health System, Bronx, New York

<sup>3</sup>Parkview Medical Center, Pueblo, Colorado

## Correspondence

Edison Jose Cano Cevallos, Division of Infectious Diseases, Mayo Clinic, 200 1st Street SW, Rochester, MN 55905.  
Email: ecanocevallos@gmail.com

## Abstract

Tendon or muscle rupture is a rare complication of statins that could potentially be disabling and result in a significant burden to patients. The co-administration of statin and gemfibrozil should warrant prescribers' awareness of tendon-related complications of statin use, particularly in high-risk populations with poor renal function or musculoskeletal comorbidities.

## KEYWORDS

adverse effects, gemfibrozil, muscle rupture, statin, tendon rupture

## 1 | INTRODUCTION

Statins remain a widely used lipid-lowering drug class. They have shown a reduction in all-cause mortality, major vascular events, and revascularizations in people with and without cardiovascular disease.<sup>1-3</sup> Combination with fibrates, such as gemfibrozil and fenofibrate, has shown even greater reductions in total cholesterol, LDL cholesterol, and triglycerides than either type of drug alone; however, this combination therapy is associated with an increased risk of hepatic dysfunction, renal insufficiency, and disorders of the musculoskeletal system.<sup>4</sup> Muscle and tendon rupture has been described as a very rare complication of statin therapy, yet has not been reported in association with fibrates. We present a patient with normal kidney function and long-standing use of simvastatin presenting with spontaneous myotendinous junction rupture of the plantaris muscle after recent initiation of gemfibrozil.

## 2 | CASE HISTORY/EXAMINATION

A 53-year-old female presented to the emergency department complaining of sudden onset right calf pain. Her pain occurred after standing from a sitting position. It was intense, pressure-like, nonradiating, and worsened by movement. The patient denied any history of direct or indirect trauma. Her medical comorbidities included hypertension, dyslipidemia, anemia, and right rotator cuff tear.

Her home medications included simvastatin 10 mg daily, hydrochlorothiazide, amlodipine, benazepril, naproxen, ferrous sulfate, multivitamins, and calcium supplements. Three weeks ago, she was started on gemfibrozil 600 mg twice a day and had since reported worsening of her right shoulder pain, for which she did not seek medical attention.

Work carried at BronxCare Health System, 1650 Grand Concourse; Bronx, NY 10457. All the authors were affiliated with the above institution at the time the work was performed.

This is an open access article under the terms of the Creative Commons Attribution-NonCommercial-NoDerivs License, which permits use and distribution in any medium, provided the original work is properly cited, the use is non-commercial and no modifications or adaptations are made.

© 2019 The Authors. *Clinical Case Reports* published by John Wiley & Sons Ltd.

On examination, she was awake, alert, oriented, and vital signs were within normal limits. The right lower extremity was bruised, tender, deformed, and warm in the calf area. Pain on palpation and passive movement was out of proportion to the apparent injury. The surgeon was called for assessment, and his impression was muscle rupture with suspected compartment syndrome due to intense pain and stiffness on examination. Pulses and sensations were preserved distally. Intracompartmental pressure measured on admission was 22 mm Hg, which would improve to <10 mm Hg in the following days.

## 2.1 | Differential diagnosis, investigations, and treatment

On laboratory (Table 1), kidney and liver tests were normal, serum creatinine kinase levels were 103, 167, and 180 units/L on days 1, 2, and 4, respectively. Serum aldolase values remained negative. Lipid panel was normal. Ultrasound of right lower extremity was negative for deep vein thrombosis and showed intermuscular hematoma with a possible muscle tear. Magnetic resonance imaging of the right lower extremity (Figures 1 and 2) showed an acute large hematoma within the posteromedial right lower leg, superficial to the soleus muscle and deep to the medial gastrocnemius, deemed secondary to rupture of the myotendinous junction of the plantaris muscle, with an otherwise intact musculature and no fracture.

The patient was provided analgesics and strict limb elevation. A diagnosis of tendon rupture was made and an association to statin and fibrate combination was suspected, necessitating discontinuation of these medications. Pain improved notably in the following days. The orthopedic team deemed surgical intervention as not necessary and recommended evaluation for physical therapy with outpatient follow-up. Discontinuation of gemfibrozil was ensured at the time of discharge.

## 2.2 | Outcome and follow-up

At the 3-month follow-up with her primary care physician, she was able to walk with minimal support, had received 10 weeks of physical therapy and decided not to take any lipid-lowering therapy but instead start a low-fat diet and implement lifestyle changes. Her calculated 10-year ASCVD risk was 2.6%.

## 3 | DISCUSSION

Lipid-lowering medications can adversely induce myopathy, tendinopathy, and rhabdomyolysis secondary to their inhibitory effect on the conversion of hydroxymethyl glutaryl coenzyme A (HMG-CoA) to mevalonic acid, a rate-limiting

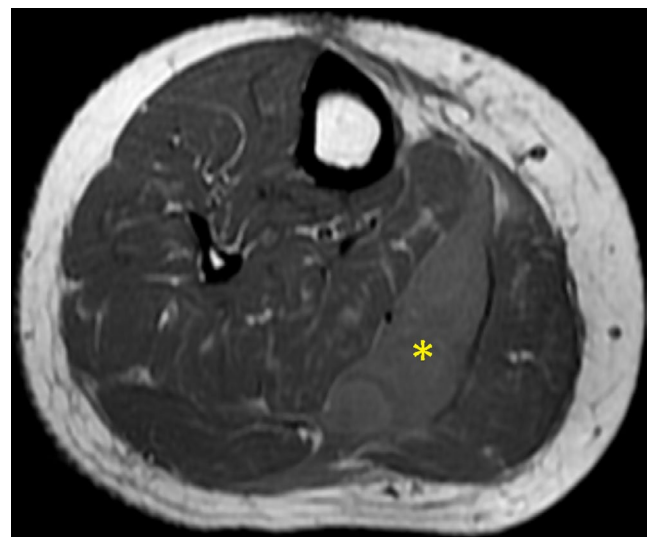
**TABLE 1** Laboratory results

Laboratory test	Value	Normal range
White blood cells	12.0 k/ $\mu$ L	4.8-10.8 k/ $\mu$ L
Neutrophils (%)	78.6%	40%-70%
BUN	10 mg/dL	6-20 mg/dL
Serum creatinine	0.5 mg/dL	0.5-1.5 mg/dL
Estimated GFR	133 mL/min/1.73m <sup>2</sup>	51-120 mL/min/1.73m <sup>2</sup>
C-reactive protein	<5 mg/dL	<5 mg/dL
Creatine kinase	167 units/L	20-200 units/L
Aldolase	4.6 units/L	<8.1 units/L
AST	20 units/L	9-36 units/L
ALT	15 units/L	5-40 units/L
Total cholesterol	163 mg/dL	162-240 mg/dL
HDL cholesterol	43 mg/dL	34-82 mg/dL
LDL cholesterol	100 mg/dL	<160 mg/dL
Triglycerides	102 mg/dL	25-150 mg/dL

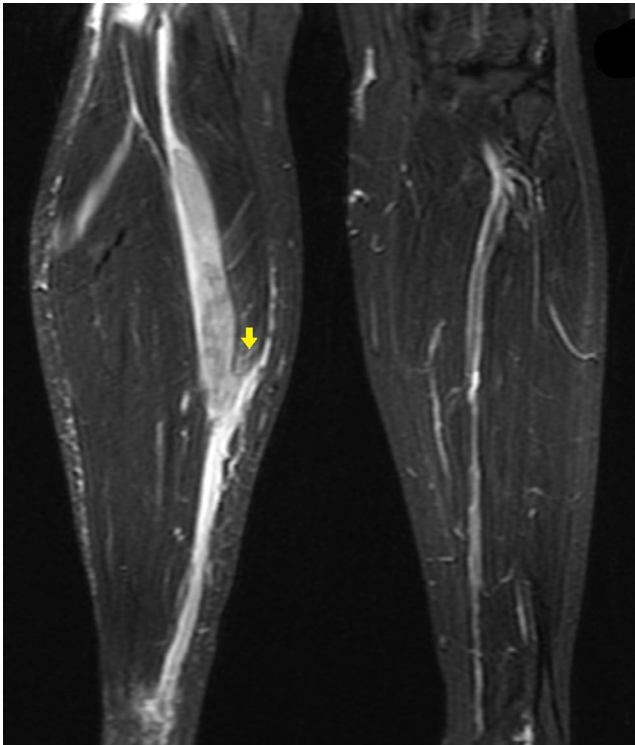
Abbreviations: ALT, alanine aminotransferase; AST, aspartate aminotransferase; BUN, blood urea nitrogen.

step in the cholesterol synthesis pathway. This decreases the production of coenzyme Q10, an important element in the electron transport chain, ultimately impairing myocyte energy production. Mitochondrial dysfunction, genetic predisposition, and alterations in gene expression may also play a role in the pathogenic mechanisms.<sup>5</sup>

Tendons' extracellular matrix consists mainly of type 1 collagen which is highly resistant to proteolytic cleavage. Statins promote an imbalance between the synthesis and



**FIGURE 1** Acute hematoma (\*) within the posteromedial right lower leg measuring 5.0 × 1.9 cm transversely and approximately 15 cm craniocaudally, lying superficially to the soleus muscle and deep to the medial gastrocnemius, secondary to rupture of the myotendinous junction of the plantaris muscle



**FIGURE 2** Redemonstrated hematoma and mild edema-like signal (arrow) noted within the medial gastrocnemius muscle adjacent to the hematoma probably representing a partial tear or strain of the medial gastrocnemius; otherwise intact musculature and no fracture

degradation of matrix metalloproteinases, which can induce microdamage in muscles and tendons alike. They are also known to inhibit tendon cell proliferation, thus having a negative impact on tendon healing.<sup>6</sup> Simvastatin use has also been shown to promote apoptosis in fibroblasts of patients with rheumatoid arthritis and induce arrest at the G1/S transition of the cell cycle, further suggesting an association between statin use and tendon disorders.<sup>7</sup>

Gemfibrozil is responsible for PPAR $\alpha$  activation and is rarely (<1%) associated with myopathy or rhabdomyolysis. Skeletal muscle toxicity has been described in type I muscle fibers in rats and the proposed mechanism might include oxidative stress and tissue damage from elevated peroxisomal and mitochondrial  $\beta$ -oxidation.<sup>8</sup> Gemfibrozil inhibits the metabolism of all statins, including simvastatin, and has shown to increase plasma concentrations of simvastatin acid (the active form of simvastatin) in pharmacokinetic studies.<sup>9</sup> Some studies reported an increased risk of muscle toxicity, as high as 1 to 5 percent when statins were co-administered with Gemfibrozil.<sup>10,11</sup>

Myopathy secondary to statin use has been described in the presence of normal creatine kinase, as seen in this patient, with microscopic evidence of ragged red fibers, abnormally increased lipid stores and lack of fibers staining for cytochrome oxidase activity.<sup>12</sup>

Studies have implicated atorvastatin as the most commonly involved statin, and diseases such as rheumatoid

arthritis, systemic lupus erythematosus, gout, diabetes mellitus, hyperparathyroidism, and chronic kidney disease are inherent risk factors for tendon rupture.

Tendinopathy most often occurs within the first year of statin initiation and the Achilles tendon is usually the most frequent site of rupture. A pharmacovigilance study from France reported 30 possible cases of spontaneous tendon rupture attributed to the use of simvastatin.<sup>13</sup> As of April 2018, the Food and Drug Administration adverse event reporting system (FAERS) database contained 280 reports of tendon rupture associated with simvastatin therapy, and one case of tendon rupture associated with gemfibrozil, since 1994.<sup>14</sup> Despite a considerable number of cases in which simvastatin was involved, cases with concomitant use of fibrates, particularly gemfibrozil, remain unknown.

Fenofibrate appears to be safer than gemfibrozil because renal excretion of statins appears to be significantly inhibited by gemfibrozil but not by fenofibrate.<sup>15,16</sup> Meta-analyses of randomized trials have found no increase in muscle or tendon-related adverse events in patients taking fenofibrate plus a statin compared with a statin alone.<sup>17,18</sup> Studies have also failed to show an increase in the incidence of myopathy or tendinopathy in patients with combined hyperlipidemia who were prescribed pravastatin plus gemfibrozil.<sup>19</sup>

Although myopathy and myositis are common adverse outcomes, tendon rupture remains a seldom reported entity of statin-gemfibrozil combination use. Even more unusual is that our patient did not possess any comorbidities predisposing to tendon rupture and endured the injury in an uncommon location. This case represents a probable adverse drug reaction (Naranjo score of 7).<sup>20</sup> She was on simvastatin therapy for about a year and had only recently been started on gemfibrozil with unchanged liver or kidney function. Her triglyceride level prior to starting gemfibrozil was unknown, however, when she presented to us her level was 102 mg/dL. To our knowledge, this is the first case of tendon rupture associated with gemfibrozil and simvastatin combination use.

In conclusion, we suggest that prescribers should be aware of the tendon-related complications of statin use, especially with co-administration of gemfibrozil, and particularly so in patients with comorbidities that are known to increase the risk. Routine musculoskeletal examination may be beneficial in statin-treated patients on gemfibrozil, especially during the first year of combination therapy. The use of fenofibrate in patients who require combined therapy with a statin appears safe, whereas pravastatin appears to have little muscle/tendon toxicity when used in combination with gemfibrozil.

## CONFLICT OF INTEREST

No conflicts of interest have been declared.

## AUTHOR CONTRIBUTIONS

Edison J. Cano: resident who admitted the patient and carried initial assessment and management. Contributed by conceptualizing idea of case report; gathering and interpreting clinical data; drafting and critically reviewing the manuscript before submission. Danial H. Shaikh: resident who took care of the patient and carried subsequent management. Contributed by conceptualizing idea of case report; gathering and interpreting clinical data; drafting and critically reviewing the manuscript before submission. Jose A. Gonzalez: resident who took care of the patient and carried subsequent management. Contributed by conceptualizing idea of case report; gathering and interpreting clinical data; drafting and critically reviewing the manuscript before submission. William Sanchez: resident who carried follow-up of the patient. Contributed by conceptualizing idea of case report; gathering and interpreting clinical data; drafting and critically reviewing the manuscript before submission. Madanmohan Patel: attending on file that assessed and managed the patient. Contributed by conceptualizing idea of case report; gathering and interpreting clinical data; drafting and critically reviewing the manuscript before submission.

## ORCID

Edison Jose Cano Cevallos  <https://orcid.org/0000-0002-0154-2544>

## REFERENCES

- Taylor F, Huffman MD, Macedo AF, et al. Statins for the primary prevention of cardiovascular disease. *Cochrane Database Syst Rev*. 2013;1:CD004816. <https://doi.org/10.1002/14651858.CD004816.pub5>
- Cholesterol Treatment Trialists' (CTT) Collaborators, Mihaylova B, Emberson J, et al. The effects of lowering LDL cholesterol with statin therapy in people at low risk of vascular disease: meta-analysis of individual data from 27 randomised trials. *Lancet*. 2012;380:581-590.
- Heart Protection Study Collaborative Group. MRC/BHF Heart Protection Study of cholesterol lowering with simvastatin in 20,536 high-risk individuals: a randomised placebo-controlled trial. *Lancet*. 2002;360:7-22.
- Choi HD, Shin WG, Lee J-Y, Kang BC. Safety and efficacy of fibrate-statin combination therapy compared to fibrate monotherapy in patients with dyslipidemia: a meta-analysis. *Vascul Pharmacol*. 2015;65-66:23-30.
- Auer J, Sinzinger H, Franklin B, Berent R. Muscle- and skeletal-related side-effects of statins: tip of the iceberg? *Eur J Prev Cardiol*. 2016;23:88-110.
- de Oliveira LP, Vieira CP, Guerra F, de Almeida M, Pimentel ER. Statins induce biochemical changes in the Achilles tendon after chronic treatment. *Toxicology*. 2013;311:162-168.
- Yokota K, Miyoshi F, Miyazaki T, et al. High concentration simvastatin induces apoptosis in fibroblast-like synoviocytes from patients with rheumatoid arthritis. *J Rheumatol*. 2008;35:193-200.
- Burri L, Hege Thoresen G, Berge RK. The role of PPAR $\alpha$  activation in liver and muscle. *PPAR Research*. 2010;2010:1-11.
- Backman JT, Kyrklund C, Kivistö KT, Wang JS, Neuvonen PJ. Plasma concentrations of active simvastatin acid are increased by gemfibrozil. *Clin Pharmacol Ther*. 2000;68:122-129.
- Duell PB, Barton Duell P, Connor WE, Roger ID. Rhabdomyolysis after taking atorvastatin with gemfibrozil. *Am J Cardiol*. 1998;368-369.
- Pierce LR, Ross PL. Myopathy and Rhabdomyolysis Associated With Lovastatin-Gemfibrozil Combination Therapy. *JAMA: J Am Med Assoc*. 1990;264(1):71.
- Phillips PS, Haas RH, Bannykh S, et al. Statin-associated myopathy with normal creatine kinase levels. *Ann Intern Med*. 2002;137:581-585.
- Marie I, Delafenêtre H, Massy N, Thuillez C, Noblet C, Network of the French Pharmacovigilance Centers. Tendinous disorders attributed to statins: a study on ninety-six spontaneous reports in the period 1990-2005 and review of the literature. *Arthritis Rheum*. 2008;59:367-372.
- Qlik Sense. [cited 25 Apr 2018]. Available: <https://fis.fda.gov/sense/app/777e9f4d-0cf8-448e-8068-f564c31baa25/sheet/33a0f68e-845c-48e2-bc81-8141c6aaf772/state/analysis>.
- Prueksaritanont T, Zhao JJ, Ma B, et al. Mechanistic studies on metabolic interactions between gemfibrozil and statins. *J Pharmacol Exp Ther*. 2002;301(3):1042-1051.
- Ballantyne CM, Davidson MH. Possible differences between fibrates in pharmacokinetic interactions with statins. *Arch Intern Med*. 2003;163(19):2394.
- Geng Q, Ren J, Chen H, Lee C, Liang W. Adverse events following statin-fenofibrate therapy versus statin alone: A meta-analysis of randomized controlled trials. *Clin Exp Pharmacol Physiol*. 2013;40(3):219-226.
- Guo J, Meng F, Ma N, et al. Meta-analysis of safety of the coadministration of statin with fenofibrate in patients with combined hyperlipidemia. *Am J Cardiol*. 2012;110:1296-1301.
- Athyros VG, Papageorgiou AA, Hatzikonstandinou HA, et al. Safety and efficacy of long-term statin-fibrate combinations in patients with refractory familial combined hyperlipidemia. *Am J Cardiol*. 1997;80(5):608-613.
- Naranjo CA, Busto U, Sellers EM, et al. A method for estimating the probability of adverse drug reactions [Internet]. *Clin Pharmacol Ther*. 1981;30(2):239-245.

**How to cite this article:** Cano Cevallos EJ, Shaikh DH, Gonzalez J, Sanchez W, Patel M. Tendon rupture associated with concomitant simvastatin and gemfibrozil use: Biological and pharmacokinetic implications. *Clin Case Rep*. 2019;7:1919-1922. <https://doi.org/10.1002/ccr3.2387>