

CASE REPORT

# Giant adrenal myelolipoma

S.C. Gautam, H. Raafat, S. Sriganesh, I. Zaffar, I. Olude, F. Komolafe, F. Qazi

Address for Correspondence:

**S.C. Gautam**

Fujairah Hospital, Fujairah, United Arab Emirates

Email: scgautam@gmail.com

<http://dx.doi.org/10.5339/qmj.2013.2>

Submitted: 15 May 2013

Accepted: 29 May 2013

© 2013 Gautam, Raafat, Sriganesh, Zaffar, Olude, Komolafe, Qazi, licensee Bloomsbury Qatar Foundation Journals. This is an open access article distributed under the terms of the Creative Commons Attribution license CC BY 3.0, which permits unrestricted use, distribution and reproduction in any medium, provided the original work is properly cited.

Cite this article as: Gautam SC, Raafat H, Sriganesh S, Zaffar I, Olude I, Komolafe F, Qazi F. Giant adrenal myelolipoma, Qatar Medical Journal 2013;1 <http://dx.doi.org/10.5339/qmj.2013.2>

 **QSCIENCE.com**  
Member of Qatar Foundation

## ABSTRACT

A fifty-two years old male presenting with a history of abdominal pain of six months duration was found on investigation to have a large non-functioning adrenal mass. Adrenal myelolipoma was diagnosed preoperatively and surgical resection was carried out. Only a small number of cases of giant adrenal myelolipoma (> 3500 grams) have been reported. A brief review of literature is done.

## INTRODUCTION

Adrenal myelolipomas are uncommon nonfunctioning tumors with varying proportions of mature fat and hematopoietic elements. They are usually small, asymptomatic and unilateral. Giant forms are extremely rare. They can be mistaken radiologically for a retroperitoneal liposarcoma. Giant myelolipomas can be asymptomatic or present with dragging abdominal pain, feeling of an abdominal mass, compression of surrounding structures and retroperitoneal hemorrhage.

## CASE REPORT

A 52 years old Filipino male, obese (BMI 32.5), chronic smoker for over 15 years, presented with dull aching abdominal pain of six months and headache of one-month duration. He was found to be hypertensive and a newly detected diabetic. On clinical examination, a firm fixed, non-tender mass was palpable in the right flank. Ultrasound scan showed a largely hyper-echoic mass interposed between the liver and the right kidney, which was markedly displaced inferiorly. Contrast-enhanced computed tomography (CT) revealed a 26 cm × 16 cm × 9 cm hypo-dense mass interspersed with foci of soft-tissue density. It was located in the retroperitoneal space, markedly displacing the right kidney downwards, the liver, gall bladder and part of the transverse colon upwards, and the inferior vena cava, head of pancreas and right renal vessels stretched along its medial margin (Figure 1A & 1B). Magnetic resonance imaging (MRI) confirmed the CT findings and showed in the fat suppression sequences the heterogeneous nature of the mass and its large lipid content (Figure 2A & 2B).

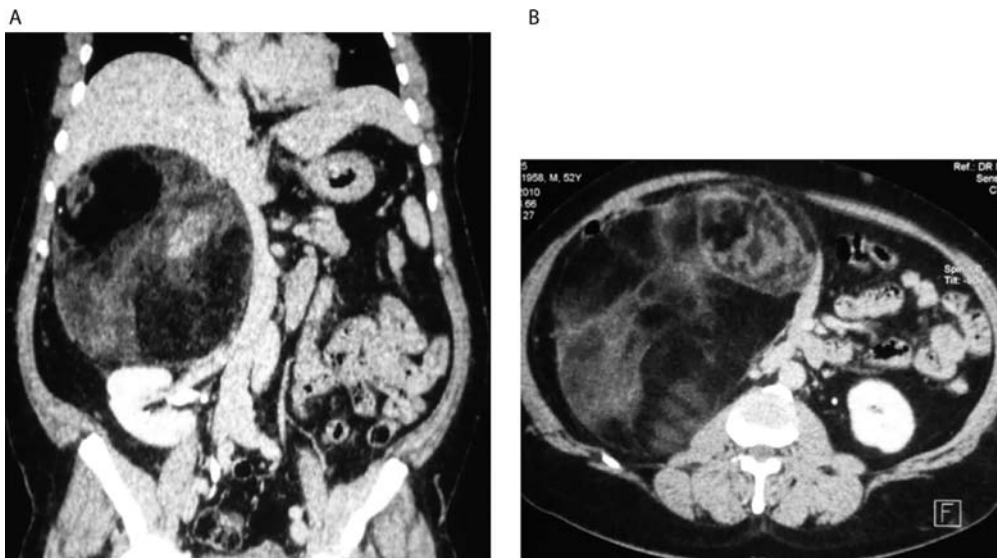


Figure 1A. Coronal reformatted contrast enhanced CT showing the large right adrenal mass. Note the extrinsic compression of the liver and inferior vena cava and inferior displacement of the right kidney. Figure 1B: Axial CT at the level of L 1 vertebra. Note the largely hypodense mass, indicating the lipid content. The iso-dense areas represent the myeloproliferative tissues.

Both imaging parameters indicated that the mass was of low vascularity. The diagnosis of a giant right adrenal myelolipoma was made. Endocrine evaluation was within normal limit. In the preoperative period, diabetes and hypertension were controlled with medications and smoking cessations and physiotherapy were instituted.

Operative procedure: Modified Kocher's incision, by anterior transperitoneal approach, mobilized hepatic flexure, ascending colon, caecum and terminal ileum medially. Kocherisation of duodenum was performed to expose the mass. Arterial supply to mass was from the aorta directly and venous drainage to the inferior vena cava (IVC). The blood vessels were stretched. Ligation and division of blood vessels was done close to aorta and IVC. Surgical excision was done. At surgery, a large encapsulated tumor mass was found in the region of the right adrenal gland. The right kidney was displaced inferiorly and the inferior vena cava medially and the

tumor adherent with soft adhesions to the surrounding structures (Figure 3A & 3B).

Gross and microscopic findings: Gross examination of the surgically excised specimen showed 28 cm × 18 cm × 12 cm thinly encapsulated tumor weighing 3850 grams, which was yellow with a few brown areas on its external surface (Figure 4). The section showed encapsulated sheets of lipocytes interspread by thin fibrovascular septae. In a circumscribed area, islands of normal haemopoietic elements such as erythroblasts, immature lymphoid cells and megakaryocytes were seen (Figure 5).

The patient made an uneventful recovery and became normotensive without medication after four weeks.

## DISCUSSION

Gierke was the first to describe this retroperitoneal tumor in 1905. It was not until 1929 that the name was

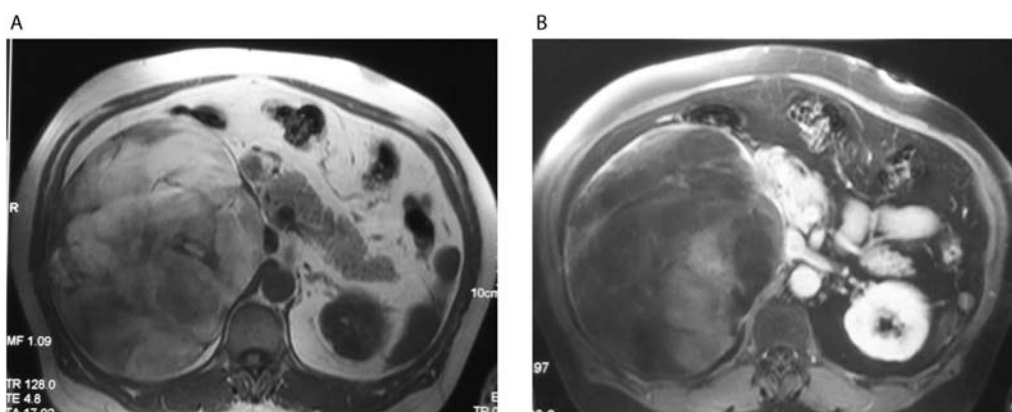


Figure 2A. Axial T1 weighted MRI showing most of the mass to be of high signal intensity, consistent with fat. Figure 2B: Axial T1 weighted fat saturated post-gadolinium MRI image. Note that the areas of the mass previously showing high intensity are hypointense.

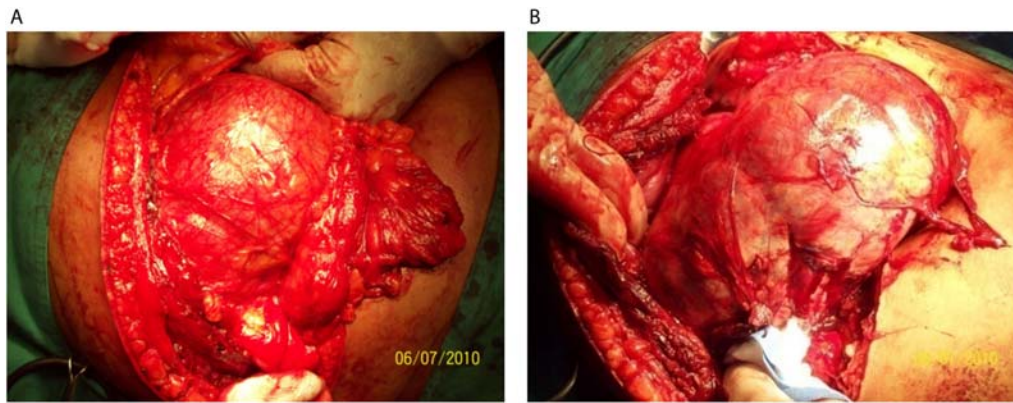


Figure 3. Operative photographs of the large right adrenal mass displacing the bowels and the right kidney.

coined by Oberling.<sup>1</sup> These tumors were composed of lipoid tissue and hematopoietic elements in varying percentage. The fatty tissue is distinguished by the presence of reticulum. These tumors are increasingly reported due to the wide use of ultrasound and other radiodiagnostic modalities. The hematopoietic components cannot enter the general circulation because they are not in the reticulum sinusoids.<sup>2</sup> Adrenal myelolipoma comprised 5.8% of adrenal tumours with a male:female ratio of 1.3:1.<sup>3</sup> Autopsy studies have reported the incidence of 0.03 %–0.2 % in the general population.<sup>4</sup> The age range of the affected patients is 20–90 years; most are men in their fourth to sixth decade.<sup>5</sup> They are usually unilateral but may be bilateral and may also develop in extraadrenal sites like the retroperitoneum, thorax and pelvis.<sup>6</sup> The synchronous occurrence of two separate tumors is a rare occurrence in the adrenal gland where functioning adenoma co-exists with myelolipoma. These cases may exhibit signs and symptoms of Cushing's, Conn's syndromes, Addison's disease, hirsutism, hermaphroditism, inborn deficiencies of 17- and 21-hydroxylase.<sup>5,7,8</sup> It is also more frequent in patients

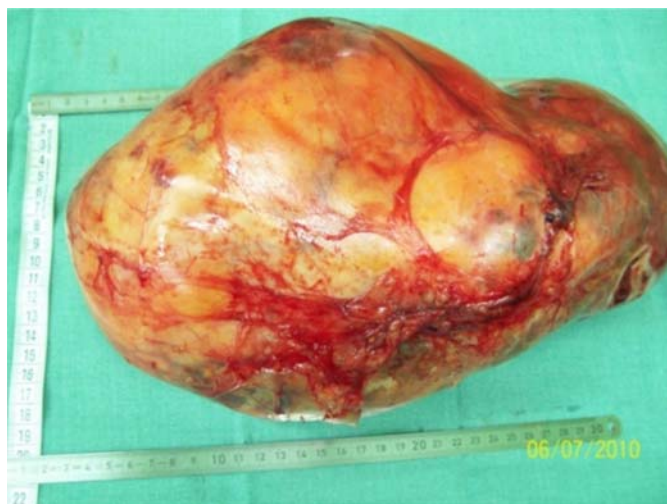

Figure 4. Gross appearance of the tumour after resection.

with obesity, hypertension and those leading stressful life.<sup>5</sup> The existence of myelolipoma within an adrenal cortical adenoma is a rare occurrence.<sup>2</sup> The aetiology of myelolipomas in general is unknown. Recent experimental evidence suggests that both the myeloid and lipomatous elements have a monoclonal origin, which strongly supports the hypothesis that myelolipomas are neoplastic lesions.<sup>9</sup> Malignant degeneration of myelolipomas has not been reported so far.<sup>10</sup>

Ultrasound (US), CT and MRI are effective in diagnosing adrenal myelolipomas in about 90% of cases.<sup>11</sup> In most cases, the diagnosis of adrenal myelolipoma is readily made because of the high fat content.<sup>12,13</sup> This manifests on ultrasonography as hyper-echoic areas, but a heterogeneous pattern may be seen. On CT the fat shows as areas of low attenuation (in the order of – 50 Hounsfield units). CT may also occasionally demonstrate punctate calcifications. On MRI, the fat content is hyper-intense on T1w, intermediate on T2w and shows low signals on fat saturation technique.<sup>13,14</sup> Difficulties with making a correct diagnosis may arise when the fat content is low, the mass consisting mainly of hematopoietic tissue. In such instances, biopsy may be required to exclude adrenal tumors.<sup>12,15</sup> Imaging differential diagnoses include retroperitoneal lipoma or liposarcoma, and renal angiomyolipoma. In the latter situation, the multiplanar capability of MRI helps in differentiation.

Adrenal myelolipomas rarely measure more than five cm in diameter, although giant tumors have been occasionally reported.<sup>1,16</sup> Giant myelolipomas are quite rare lesions, which may be asymptomatic; because of their large size, they may lead to dragging abdominal pain, an abdominal mass, compression on neighboring organs, and even acute intratumoral or retroperitoneal hemorrhage.<sup>17</sup> Our patient presented with dull, aching abdominal pain. In the literature many of these patients are male, hypertensive and newly discovered diabetics as was in our case.<sup>3,5</sup> Case reports indicate that some of the larger myelolipomas have been misinterpreted as



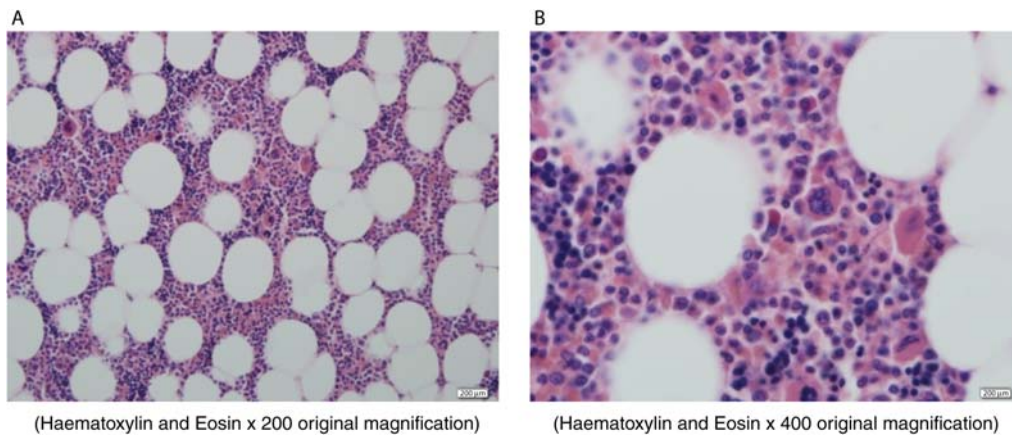


Figure 5. Histological examination of the mass shows islands of normal hematopoietic cells, such as megakaryocytes associated with stromal fat cells.

retroperitoneal liposarcomas on radiological examinations.<sup>18</sup> Giant adrenal myelolipomas are usually treated by simple adrenalectomy and are completely curable.<sup>17</sup>

## CONCLUSION

This case report describes the clinical presentation of a rare tumour of the adrenal gland. The investigation modalities, which conclusively diagnose myelolipoma of the adrenal gland are discussed. The large tumour could be completely removed successfully by surgery.

Hence the importance of an awareness of this rare adrenal entity and its correct diagnosis is highlighted.

## ACKNOWLEDGEMENTS

The authors gratefully acknowledge the services rendered by the late Dr Abdu Rehman Showki, Consultant Anaesthesiologist who administered anesthesia for this patient. Acknowledgements are also due to Dr. Munaf Desai, Specialist Histopathologist at Al Qassimi Hospital for the histomicrographs.

## REFERENCES

1. Wilhelmus JL, Schrodt GR, Alberhasky MT, Alcorn MO. Giant adrenal myelolipoma: case report and review of literature. *Arch Pathol Lab Med.* 1981;105:532 – 535.
2. Ong K, Tan KB, Putti TC. Myelolipoma within a non – functional adrenal cortical adenoma. *Singapore Med J.* 2007;48(7):200 – 202.
3. Sharma MC, Kashyap S, Sharma R, Chumber S, Sood R, Chahal R. Symptomatic adrenal myelolipoma. Clinicopathological analysis of 7 cases and brief review of literature. *Urol Int.* 1997;59(2):119 – 124.
4. Thompson LDR. In: Thompson LDR, ed. Endocrine Pathology. In: Goldblum JR, series ed. *Foundations in Diagnostic Pathology.* Vol 5. Philadelphia, PA: Churchill Livingstone Elsevier, 2006:205 – 238.
5. Bednarek-Tupikowska G, Tupikowski K, Akinpelumi BF. Adrenal myelolipoma. *Pol Merkur Lekarski.* 2005;18(103):107 – 110.
6. Patel VG, Babalola OA, Fortson JK, Weaver WL. Adrenal myelolipoma: report of a case and review of literature. *Am Surg.* 2006;72(7):649 – 654.
7. Goetz SP, Niemann TH, Robinson RA, Cohen MB. Hematopoietic elements associated with adrenal glands, a study of the spectrum of change in nine cases. *Arch Pathol Lab Med.* 1994;118: 895 – 896.
8. Pasimeni G, Rossi F, Ragazzo M, Guerrini L, Markouizou A, Santiemma V. Adrenal adenoma and myelolipoma in an elderly patient with Conn's syndrome. *Recenti Prog Med.* 2000;91:116 – 118.
9. McNicol A. A diagnostic approach to adrenal cortical lesions. *Endocr Pathol.* 2008;19:241 – 251.
10. Kammen BF, Elder DE, Fraker DL, Siegelman ES. Extraadrenal myelolipoma: MR imaging findings. *AJR Am J Roentgenol.* 1998;171:721 – 723.
11. Porcaro AB, Novella G, Ficarra V, Cavalleri S, Antonioli SZ, Curti P. Incidentally discovered adrenal myelolipoma. Report on 3 operated patients and update of the literature. *Arch Ital Urol Androl.* 2002;74(3):146 – 151.
12. Boland GW. L, Blake MA, Hahn PF, Mayo-Smith WW. Incidental adrenal lesions: principles, techniques and

- algorithms for image characterization. *Radiology* 2008;249(3):756–775.
13. Cyran KM, Kenney PJ, Memel DS, Yacoub I. Adrenal myelolipoma. *AJR Am J Roentgenol.* 1996;166(2):395–400.
  14. Yip L, Tublin ME, Falcone JA, Nordman CR, Stang MT, Ogilvie JB, Carty SE, Yim JH. The adrenal mass: correlation of histopathology with imaging. *Ann Surg Oncol.* 2010;17(3):846–852.
  15. Bharwani N, Rockall AG, Sahdev A, Gueorguiev M, Drake W, Grossman AB, Reznik RH. Adrenocortical carcinoma: the range of appearances on CT and MRI. *AJR Am J Roentgenol.* 2011;196(6):706–714.
  16. Yildiz L, Akpolat I, Erzurumlu K, Aydin O, Kandemir B. Giant adrenal myelolipoma: case report and review of literature. *Pathol Int.* 2000;50:502–504.
  17. Fernandes GC, Gupta RK, Kandalkar BM. Giant adrenal myelolipoma. *Indian J Pathol Microbiol.* 2010;53:325–326.
  18. Fernandez-Sanz J, Galera H, Garcia-Donas A, Gonzalez-Campora R, Llamas R, Matilla A. Adrenal myelolipoma simulating a retroperitoneal malignant neoplasm. *J Urol.* 1981;126:780–782.