

Value of Ultrasound-Guided Closed Reduction and Minimally Invasive Fixation in the Treatment of Metacarpal Fractures

Suhong Shen, MD , Xiaohui Wang, MD, Zhuo Fu, MD

Received August 14, 2018, from the Department of Ultrasound (S.S., Z.F.) and Hand Microsurgery Unit (X.W.), Luoyang Orthopedic Hospital of Henan Province (Orthopedic Hospital of Henan Province), Luoyang, China. Manuscript accepted for publication January 31, 2019.

We thank the others involved in the study as well as colleagues from the Department of Ultrasound for their support.

Address correspondence to: Suhong Shen, MD, Department of Ultrasound, Luoyang Orthopedic Hospital of Henan Province (Orthopedic Hospital of Henan Province), 82 Qiming South Rd, 471000 Luoyang, Henan, China.

E-mail: lyssh115@sina.com

Abbreviations

US, ultrasound

doi:10.1002/jum.14967

This is an open access article under the terms of the Creative Commons Attribution-NonCommercial-NoDerivs License, which permits use and distribution in any medium, provided the original work is properly cited, the use is non-commercial and no modifications or adaptations are made.

Objectives—To investigate the value of ultrasound-guided closed reduction and minimally invasive fixation in the treatment of metacarpal fractures.

Methods—Twenty-four patients with acute metacarpal fractures were randomly divided into experimental and control groups, with 12 patients in each group. Ultrasound-guided closed reduction and fixation were performed in the experimental group, whereas C-arm fluoroscopy-assisted fixation was performed in the control group. Patients in both groups were followed to compare the treatment efficacy.

Results—The success rates of ultrasound-guided closed reduction of fractures were 75.00% (9 of 12) in the experimental group and 83.33% (10 of 12) in the control group, and the difference was not statistically significant ($\chi^2 = 0.253$; $P = .615$) between the groups. The mean numbers of C-arm fluoroscopy-assisted procedures \pm SD were 1.50 ± 0.67 times in the experimental group and 2.50 ± 0.80 in the control group, and the difference was statistically significant ($t = -3.317$; $P = .003$). The mean healing times of fractures were 5.47 ± 0.67 weeks in the experimental group and 5.73 ± 0.81 weeks in the control group; the excellence rates of total active motion were 83.33% (10 of 12) in the experimental group and 91.67% (11 of 12) in the control group; the mean grip strength values were 31.78 ± 3.13 kg in the experimental group and 33.43 ± 3.30 kg in the control group. There were no significant differences in those 3 parameters between the groups ($P > .05$ in each comparison).

Conclusions—Ultrasound-guided closed reduction and minimally invasive fixation is an effective treatment of metacarpal fractures and can reduce exposure to x-ray radiation.

Key Words—closed reduction; fracture; metacarpal bones; minimally invasive surgery; ultrasound

Metacarpal fractures are common in clinical practice. The treatments include open reduction, secondary internal fixation removal surgery, trauma surgery, and extensor tendon delay.¹ As one of the commonly used clinical treatments, closed reduction with Kirschner wire fixation under fluoroscopy is a minimally invasive surgical procedure with a good fixation effect that allows early functional exercises and no need for internal fixation removal surgery.² However, there are also disadvantages, such as x-ray exposure during surgery for both surgeons and patients.

Ultrasound (US) imaging is a convenient method without radiation that can be used for real-time, dynamic, multidirectional

scanning. In recent years, US has been widely used in the diagnosis of lesions in the muscle, bone, joint, synovial sac, tendon, and peripheral nerves. Ultrasound has also had great clinical value in the diagnosis of hand fractures and tendon, muscle, palm, nerve, and collateral ligament injuries.^{3–12} It has also been applied to the reduction of children's limb fractures and Kirschner wire fixation^{13–16} and has achieved good results. Ultrasound is also valuable in terms of preventing ulnar nerve injuries resulting from closed needle threading of supracondylar fractures of the humerus.¹⁷ Research indicates that high-frequency US has high sensitivity and specificity in the assessment of hand fractures.^{3,5} However, there are few reports on its use in the treatment of metacarpal fractures in adults. We attempted to conduct a clinical study of US-guided closed reduction and minimally invasive Kirschner wire fixation of metacarpal fractures in adults, and we achieved satisfactory results. The purpose of this study was to investigate the value of US-guided minimally invasive closed reduction and fixation in the treatment of metacarpal fractures.

Materials and Methods

General Data

Twenty-four patients with acute metacarpal fractures treated in our hospital were enrolled in this study. The inclusion criteria were as follows: (1) untreated metacarpal closed fracture (fracture time \leq 3 weeks) or fracture displacement after a simple reduction; (2) type of fracture consistent with 1 of the 3 subtypes (A1, spiral; A2, oblique; and A3, transverse) of type A simple fractures in the AO classification¹⁸ that could be treated by closed reduction; (3) age from 18 to 60 years; (4) no history of hand injury or deformity; and (5) normal hand function before the injury. The exclusion criteria were as follows: (1) pathologic fracture; (2) old fracture (fracture time $>$ 3 weeks); (3) severe comminuted fracture that could not be treated by closed reduction; (4) presence of a concurrent serious skin crush injury or vascular, nerve, or tendon injury that needed to be treated; and (5) patients with severe chorionic diseases who could not tolerate anesthesia and surgery. Enrolled patients were randomly assigned to an experimental or a control group by a random-number table, 12 in each group, and underwent fracture reduction by a US-guided or C-arm

fluoroscopy-guided procedure, respectively. This work was a prospective study. The study was approved by the Ethics Committee of our hospital, and all the patients signed an informed consent form.

Ultrasound Imaging

A LOGIQ E9 US machine with a linear array transducer (6–15 MHz; GE Healthcare, Chicago, IL) was used for multidirectional and multisectional viewing of the fracture type, displacement of the fragment, and surrounding soft tissue before the operation, so that the surgeon fully understood the condition to make appropriate surgical plans. If necessary, color Doppler flow imaging was used to view the blood flow surrounding the fragment ends (the scale range was ± 5 cm/s, filter to the best state).

Surgical Procedure in the Experimental Group

In the experimental group, an Esaote- α portable color diagnostic US apparatus with a high-frequency linear array transducer (4–12 MHz; Esaote SpA, Genoa, Italy) was used. The surface of the transducer was covered with a medical disinfecting US gel and placed in a sterile glove. The cable connected to the transducer was wrapped with sterile plastic film. Sterile normal saline, instead of the US gel, was applied on the back and sides of the fracture site. Ultrasound examinations were performed to view the fragment ends and surrounding soft tissue. After longitudinal traction, manual reduction in the opposite direction of the fracture displacement and correction of displacement or angulation of the fracture fragments were performed. If necessary, Kirschner wire poking reduction was performed at the end of a fracture. A Kirschner wire can also be used to transversely pierce through the fracture fragment and reduce the fracture with a rotating wire technique. Ultrasound examinations were performed to view the bone fragment alignment at the time of reduction and to confirm the cortical bone continuity or good cortical alignment between the fragment ends. A 1.0- or 1.2-mm Kirschner wire was used for antegrade or retrograde fixation (Figure 1).

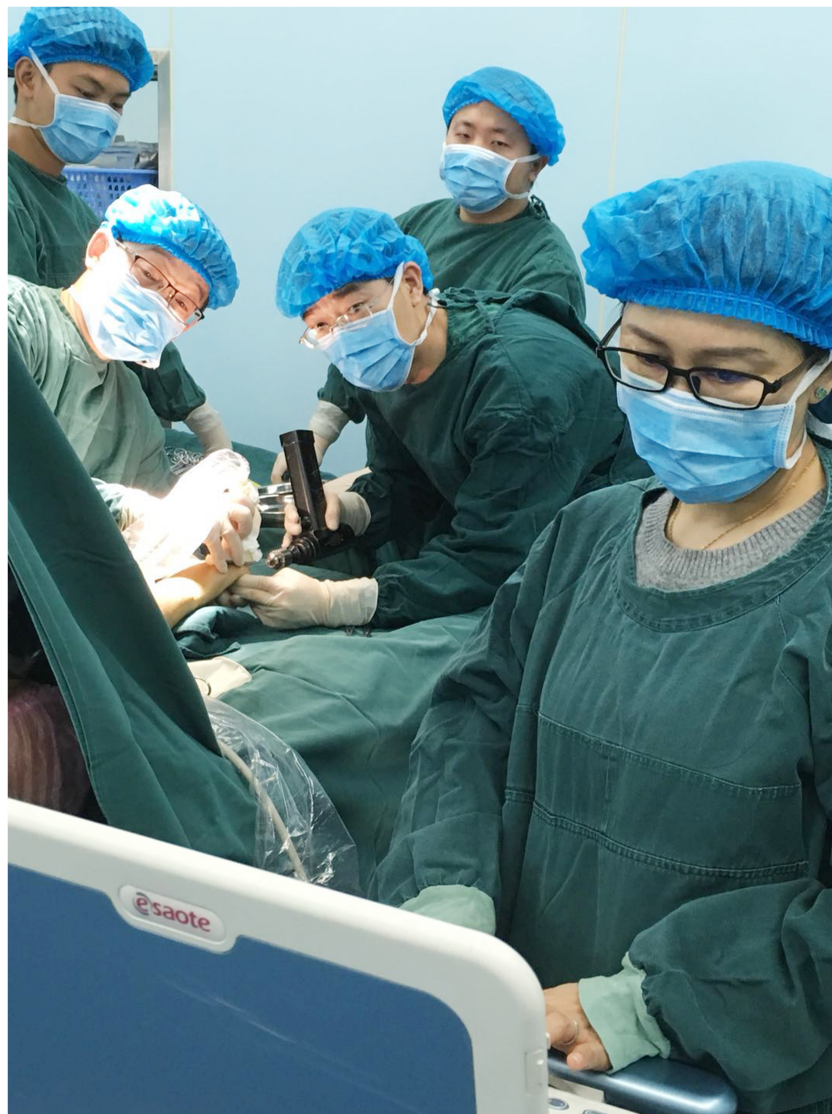Because US can penetrate the fracture end and cancellous bone near the metacarpal head, a strong echo from the Kirschner wire can be seen at the fracture site and the metacarpal head near the metacarpophalangeal joint; thus, the position of the Kirschner wire can be judged. For some patients whose

metacarpal bone density is not very high, deep Kirschner wire echoes can also be seen through the metacarpal bone (Figure 2). At the completion of fracture fixation, radiography was performed to verify whether the fracture reduction was satisfactory. If a poor repositioning (index and middle finger residual angulation deformity $>10^\circ$, ring finger $>20^\circ$ – 30° , and little finger $>30^\circ$ – 40°)¹⁹ was noted, US-guided reduction was repeated. Reduction under C-arm fluoroscopy or open reduction was performed on patients with unsuccessful US-guided reduction.

Surgical Procedure in the Control Group

The fracture was reduced by manipulation according to the direction and degree of displacement of the fracture fragments (same method as in the experimental group). Radiography was performed to view bone fragment alignment at the time of reduction. If functional reduction failed, reduction under C-arm fluoroscopy or Kirschner wire poking reduction was performed. Once good fragment alignment was achieved, a 1.0- or 1.2-mm Kirschner wire was used for antegrade or retrograde cross-fixation.

Figure 1. Metacarpal fracture reduction and Kirschner wire fixation.



Postoperative Management

After fracture reduction by manipulation, a plaster cast or small splint was used for fixation. After closed reduction with Kirschner wire fixation, a plaster cast or supportive device was used for fixation. According to the stability of the fracture fixation, functional exercises (flexion or extension) were started. (If the fracture fixation is stable, functional exercises can be started on the same day; if not, functional exercises can be started after 3 weeks).

Follow-up

Ultrasound and radiographic examinations were performed at 1.5, 3, 6 to 9, and 9 to 12 months after surgery. The follow-up was completed when the fractures healed. Ultrasound was used to observe callus formation and fragment healing. Plain radiography was used to observe fracture healing. At the final follow-up after the fracture healed, the patient was evaluated for total active motion: finger total active motion = degree of total active flexion – restricted degree of total active extension. In addition, grip strength was measured by a grip meter. The assessment criteria were as follows: excellent, normal flexion motion with total active motion of greater than 220°; good, function recovered to 75% of the unaffected corresponding finger with total active motion of greater than 200° to 220°; medium, function recovered to 50% to 75% of the unaffected corresponding finger with total active motion of greater than 180° to 200°; and poor, function recovered to less than 50% of the unaffected corresponding finger with total active motion of less than 180°.

Statistical Analysis

The SPSS version 19.0 package for Windows (IBM Corporation, Armonk, NY) was used for the statistical

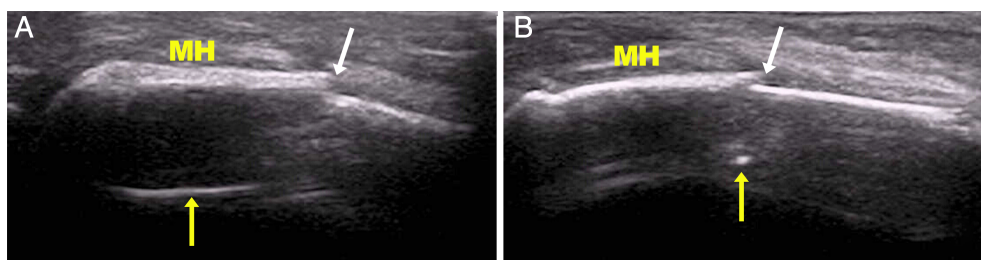
analysis. Quantitative data are expressed as mean \pm standard deviation. Independent-sample tests were used to compare the differences between the groups. Frequency data were compared by χ^2 tests. $P < .05$ was considered statistically significant.

Results

The 24 patients enrolled in this study included 16 male and 8 female patients with a median age of 32 years (range, 18–56 years). Of the patients in the experimental group, 6 had a diagnosis of metacarpal shaft fractures; 4 had metacarpal base fractures; and 2 had metacarpal neck fractures. Of the patients in the control group, 7 had a diagnosis of metacarpal shaft fractures; 2 had metacarpal base fractures; and 3 had metacarpal neck fractures. There were no significant differences in sex, age, or fracture type between the groups ($P < .05$; Table 1).

Ultrasound-guided closed fracture reduction was successfully performed in 9 patients in the experimental group (Figure 3), and the success rate was 75.00%. One patient with a metacarpal base fracture and severe soft tissue swelling underwent reduction under C-arm fluoroscopy, and 1 patient with metacarpal head comminuted fractures underwent open reduction. In the control group, C-arm fluoroscopy-guided closed reduction was successfully performed in 10 patients, and the success rate was 83.33%. One patient with a metacarpal base comminuted fracture and 1 patient with metacarpal shaft comminuted fractures underwent open reduction. There was no significant difference in the success rate of reduction between the groups (Table 2). The mean numbers of

Figure 2. Ultrasound images of a metacarpal fracture reduction in a 36-year-old male patient with a fifth metacarpal fracture of the right hand. **A**, The Kirschner wire can be seen deep in the metacarpal head. **B**, The Kirschner wire can be seen at the fracture site. Kirschner wire echoes can also be seen through the metacarpal bone. MH indicates fifth metacarpal head; white arrows, fracture site; and yellow arrows, Kirschner wire.



C-arm fluoroscopy-assisted procedures performed in the experimental and control groups were 1.50 ± 0.67 and 2.50 ± 0.80 , respectively. The difference was statistically significant (Table 3).

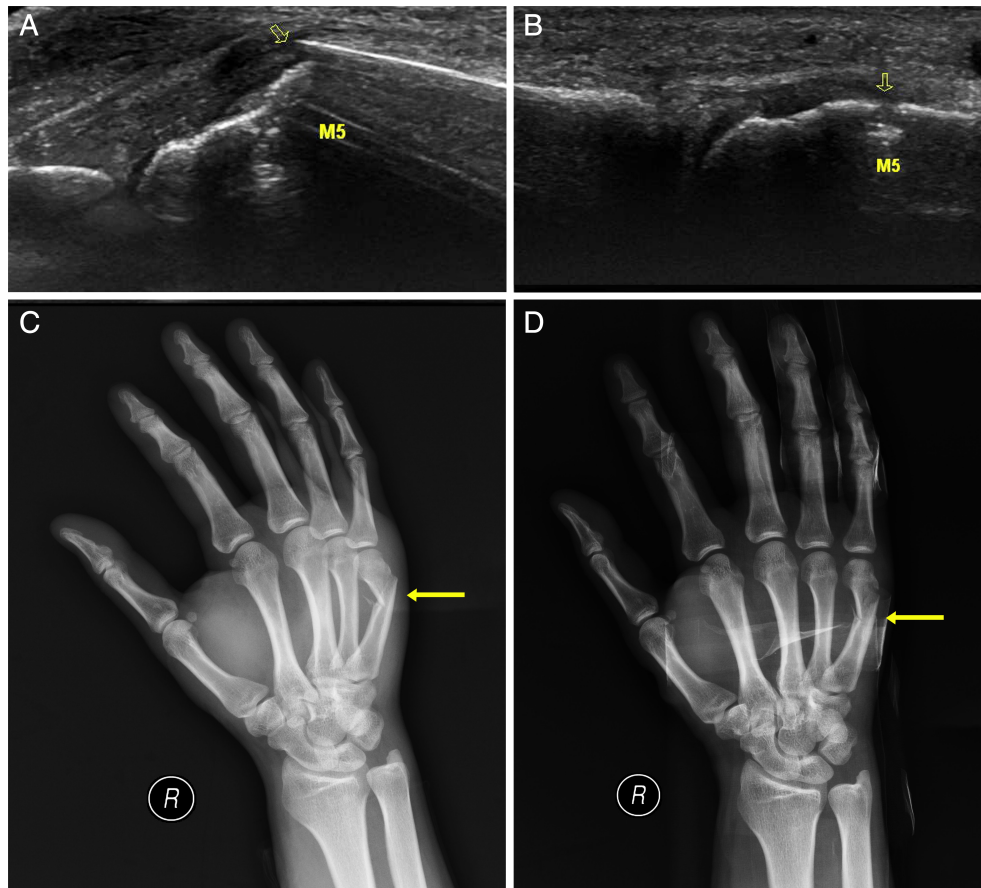
The follow-up period was between 6 and 12 months with a median of 9 months. At 1.5 months after surgery, 7 patients (58.33%) in the experimental group and

6 patients (50.00%) in the control group were examined by US, and callus formation between the fractured ends was noted. The number of patients with callus formation was not statistically significant different between the groups ($\chi^2 = 0$; $P > .99$). Excellent fracture healing was achieved in both groups (Figure 4). Radiography showed that the fractures were functionally reduced.

Table 1. Comparison of Sex, Age, and Fracture Site Between the Groups

Group	n	Sex, n (%)		Age, y	Fracture Site, n (%)		
		Female	Male		Middle	Basal	Neck
Experimental	12	3 (25.00)	9 (75.00)	32.83 ± 11.00	6 (50.00)	4 (33.33)	2 (16.67)
Control	12	4 (33.33)	8 (66.67)	34.50 ± 10.43	7 (58.33)	2 (16.67)	3 (25.00)
		$P > .99$		$t = 0.381$ $P = .707$	$\chi^2 = 0.958$ $P = .619$		

Figure 3. Images from a 32-year-old male patient with a fifth metacarpal fracture of the right hand. **A** and **B**, Ultrasound images of the fifth metacarpal fracture before (**A**) and after (**B**) reduction. Radiographic assessment of the fifth metacarpal fracture before (**C**) and after (**D**) reduction. Arrows indicate fracture site; and M5, fifth metacarpal.



The mean healing times were 5.47 ± 0.67 weeks in the experimental group and 5.73 ± 0.81 weeks in the control group. In the experimental group, the total active motion scores were excellent in 8 patients (66.67%), good in 2 patients (16.67%), and moderate in 2 patients (16.67%). The excellent and good rates were 83.33% (10 of 12). In the control group, the total active motion scores were excellent in 8 patients (66.67%), good in 3 patients (25.00%), and moderate in 1 patient (8.33%). The excellence rate was 91.67% (11 of 12). The mean grip strength values were 31.78 ± 3.13 kg in the experimental group and 33.43 ± 3.30 kg in the control group. There were no significant differences in the fracture-healing time, total active motion score, or mean grip strength between the groups (Tables 2 and 3).

Discussion

In recent years, with the continuous advancement of US technology and its extensive application in the musculoskeletal field, US is not only widely used in the diagnosis of hand fractures and injuries of muscles, tendons, palms, nerves, and collateral ligaments,³⁻¹⁰ but also can be used to assist in closed reduction and fixation of fractures,^{20,21} especially for the diagnosis and closed reduction of limb fractures in children.¹³⁻¹⁶ These studies have confirmed the advantages of

US and its value in fracture reduction treatment. In addition, our recent research also shows that high-frequency US cannot only be used in the diagnosis of nasal bone fractures but also has high clinical value in guiding treatment.^{22,23} In this study, the success rate of US-guided closed reduction and fixation was 75.00% (9 of 12) in 12 patients with metacarpal fractures in the experimental group. We noticed that US was good for viewing metacarpal shaft fractures and contributed to a high success rate of reduction of this type of fracture. Fractures at the metacarpal base and neck, especially comminuted fractures, can interfere with US diagnosis because of bone irregularities that can cause multiple echo reflections. In this study, 2 patients (one with a metacarpal base fracture and soft tissue swelling and the other with a metacarpal head comminuted fracture) had failed reduction under US guidance and underwent reduction under C-arm fluoroscopy. For those who have soft tissue incarceration between the bone fragments, the success rate of closed reduction is low, and open reduction is often required. In this study, 2 patients in the control group had failed closed reduction and had to undergo open reduction. The reason for failure in one of them (with a metacarpal head fracture) was incarceration of soft tissues between the fragments; in the other (with a metacarpal base comminuted fracture), a complex fracture of the metacarpal base, multiple echo reflections, and severe injury to the surrounding soft tissue were blamed for causing failure of completely closed reduction. Because the metacarpal bone is small, radiography may not easily show callus formation. This study has shown that high-frequency US can show callus formation in the early stage of fracture healing (≈ 1.5 months), as well as the blood flow signal at the sites of the callus formation. This study has also shown that there were no significant differences in the fracture-healing time, total active motion score, or grip strength between the groups ($P > .05$ for each comparison), suggesting that US-

Table 2. Comparison of Excellence and Success Rates Between the Groups

Group	n	Excellence, % ^a	Success, % (n)
Experimental	12	83.33	75.00 (9/12)
Control	12	91.67	83.33 (10/12)
χ^2		0.381	0.253
P		.537	.615

^aTotal active motion.

Table 3. Comparison of Fracture-Healing Time, Number of C-Arm Fluoroscopy-Assisted Procedures, and Postoperative Grip Strength Between the Groups

Group	n	Healing Time, wk	C-Arm Procedures, n ^a	Grip Strength, kg
Experimental	12	5.47 ± 0.67	1.50 ± 0.67	31.78 ± 3.13
Control	12	5.73 ± 0.81	2.50 ± 0.80	33.43 ± 3.30
t		-0.852	-3.317	-1.256
P		.403	.003	.222

^aOne procedure included anteroposterior and oblique views.

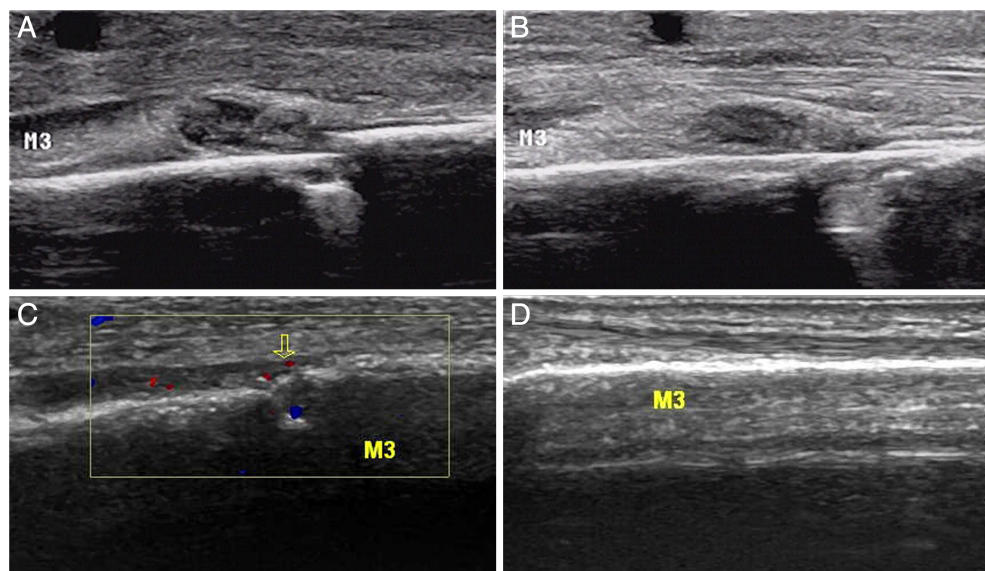
guided closed reduction and minimally invasive fixation of metacarpal fractures is an effective approach.

However, the obvious limitation of this study was that the sample size was too small. We only conducted a preliminary study on 24 patients with different types of metacarpal fractures. Because there are no similar studies in this field, we had no experience and methods to refer to. We expect that our team or other authors will have a larger sample size and more in-depth research in future work.

Ultrasound-guided fracture reduction has the following advantages: (1) No radiation is involved during a US examination. Thus, this procedure can also be used for pregnant women or children who are sensitive to radiation injury. (2) Ultrasound produces high-definition imaging of soft tissue, which can display subtle tissue structures and has great diagnostic value for occult fractures.²⁴ Neri et al²⁵ suggested that US can show a fracture displacement as small as 1 mm. (3) Ultrasound can clearly show the courses of blood vessels and nerves and thus avoid iatrogenic injury. During reduction of a hand/wrist fracture, the peripheral nerves of the hand/wrist can be injured as well. High-frequency US can clearly display peripheral nerves of the hand/wrist, and the use of US can prevent them from injury.²⁶ (4) Ultrasound can show fracture fragments and assess fracture reduction in a

multidirectional, multiangle, real-time dynamic scan. Thus, the position of the fragment can be easily adjusted until reaching a satisfactory reduction. (5) Ultrasound can be used to determine whether there is soft tissue incarceration between fracture fragments after reduction. (6) Ultrasound can be used to view callus formation during fracture healing. However, US cannot penetrate the bones to show an overall perspective of bones and intramedullary conditions. Therefore, the drawbacks of US in diagnosing fractures and guiding fracture reduction are as follows: (1) It is difficult to assess the alignment of comminuted fractures, neck, or base fractures because of multiple crossings, overlay of the strong cortical echo reflection, and irregularities in the surface of the bone. (2) The metacarpal bones are small and tightly arranged, and soft tissue swelling after fracture decreases the operating space of a US transducer. Missed diagnoses and misdiagnoses are very common in the diagnosis of second, third, and fourth metacarpal fractures. (3) The uneven bone surface of the joints causes overlapped echo reflections. Moreover, the joint surfaces are located at the sites where the two bone segments are connected. Ultrasound images cannot show a complete view of the joint surface, limiting the application of US in the diagnosis of fractures with intra-articular extensions.²⁷ A US examination is not applicable to patients with open fractures and severe

Figure 4. Ultrasound images from a 21-year-old male patient with a third metacarpal fracture of the left hand. **A**, Image before reduction. **B**, Image after reduction. **C**, At 1.5 months after the procedure, a partial bone scab and blood flow signal (arrow) were seen in the fracture gap. **D**, At 6 months after the procedure, the fracture was completely healed. M3 indicates third metacarpal.



soft tissue injury and those with external fixation, such as a plaster cast or splint. (4) Ultrasound-guided fracture reduction is more dependent on the surgeon's hand skill and experience.²⁸

In summary, the use of US-guided closed reduction to treat metacarpal fractures has advantages, including no x-ray radiation and a high success rate of reduction. This procedure is easy to perform and worthy of promoting its clinical application.

References

- Liu L, Lv Y, Wei Y, et al. Treatment of noncomminuted phalanx fracture with closed reduction AO Kirschner's needle. *Chin J Hand Surg* 2014; 30:151–152.
- Ozçelik D, Toplu G, Unveren T, Kaçağan F, Senyuva CG. Long-term objective results of proximal phalanx fracture treatment. *Ulus Travma Acil Cerrahi Derg* 2011; 17:253–260.
- Wang X, Shen S, Li D, et al. Ultrasound guided closed reduction and pinning for adult phalangeal fractures. *Chin J Ultrason* 2016; 25:804–807.
- Tayal VS, Antoniazzi J, Pariyadath M, Norton HJ. Prospective use of ultrasound imaging to detect bony hand injuries in adults. *J Ultrasound Med* 2007; 26:1143–1148.
- Becciolini M, Bonacchi G. Fracture of the sesamoid bones of the thumb associated with volar plate injury: ultrasound diagnosis. *J Ultrasound* 2015; 18:395–398.
- Mohseny B, Nijhuis TH, Hundepool CA, Janssen WG, Selles RW, Coert JH. Ultrasonographic quantification of intrinsic hand muscle cross-sectional area: reliability and validity for predicting muscle strength. *Arch Phys Med Rehabil* 2015; 96:845–853.
- Fodor D, Lungu A. Ultrasonography of the non-traumatic lesions of the fingers: pictorial essay. *Med Ultrason* 2013; 15:147–153.
- Shinohara T, Horii E, Majima M, et al. Sonographic diagnosis of acute injuries of the ulnar collateral ligament of the metacarpophalangeal joint of the thumb. *J Clin Ultrason* 2007; 35:73–77.
- Zhang GY, Zhuang HY, Wang LX. Value of high frequency ultrasonography in diagnosis and surgical repair of traumatic finger tendon ruptures. *Med Princ Pract* 2012; 21:472–475.
- Yalcin E, Akyuz M, Onder B. Early radial digital neuropathy of the thumb due to flexor pollicis longus tendinitis: value of ultrasound in an uncommon mild neuropathy. *Muscle Nerve* 2013; 47:772–775.
- Hung CY, Hsiao MY, Özçakar L, et al. Sonographic tracking of the lower limb peripheral nerves: a pictorial essay and video demonstration. *Am J Phys Med Rehabil* 2016; 95:698–708.
- Chang KV, Wu WT, Huang KC, Jan WH, Han DS. Limb muscle quality and quantity in elderly adults with dynapenia but not sarcopenia: an ultrasound imaging study. *Exp Gerontol* 2018; 108:54–61.
- Patel DD, Blumberg SM, Crain EF. The utility of bedside ultrasonography in identifying fractures and guiding fracture reduction in children. *Pediatr Emerg Care* 2009; 25:221–225.
- Shen X, Chen X, Li X, et al. Ultrasound guided percutaneous Kirschner-wire leverage and reduction for radial neck fracture in children. *Chin J Pediatr Surg* 2015; 36:363–367.
- Zhang J, Yang Y, Wu D. B-ultrasound was used to diagnose and guide closed reduction of forearm fracture in children. *J Pract Orthop* 2014; 20:347–349.
- Wellsh BM, Kuzma JM. Ultrasound-guided pediatric forearm fracture reductions in a resource-limited ED. *Am J Emerg Med* 2016; 34:40–44.
- Soldado F, Knorr J, Haddad S, et al. Ultrasound-guided percutaneous medial pinning of pediatric supracondylar humeral fractures to avoid ulnar nerve injury. *Arch Bone Jt Surg* 2015; 3:169–172.
- Wang M, Zeng B. *AO Principles of Fracture Management. Chapter 1: AO concept and basic principles, Part 5: classification of fractures*. Shanghai, China: Shanghai Science and Technology Publishing House; 2010: 53–67.
- Wolfe S, Pederson W, Kozin SH. *Green's Operative Hand Surgery*. Chapter 8: metacarpal and phalangeal fractures. Beijing, China: People's Military Medical Publisher; 2012:218–236.
- Zhang Z, Shen S, Hu C, et al. Feasibility of long bone fractures with intramedullary nail fixation under ultrasound monitoring. *Chinese medical Devices* 2014; 29(3):161–163.
- Lan J, Zhou M, Zhou C, et al. Value of ultrasonography in guiding closed reduction and intramedullary nail fixation for femoral shaft fractures. *Chin J Ultrason* 2016; 25:616–619.
- Shen S, Ma L, Fu Z, et al. Clinical value of high frequency ultrasound in diagnosis of nasal fracture and guided closed reduction. *Chin J Ultrason* 2018; 27:914–915.
- Ma L, Shen S, Hu P, Wu ZQ. The observation of curative effect on closed reduction of nasal bone fracture under ultrasound guidance: report of 38 cases [in Chinese]. *Zhonghua Er Bi Yan Hou Tou Jing Wai Ke Za Zhi* 2017; 52:933–935.
- Wang L, Wang X, Li W, et al. Diagnostic value of ultrasound for closed metacarpal fractures in adults. *J Trad Chin Orthop Traumatol* 2017; 29:28–30.
- Neri E, Barbi E, Rabach I, et al. Diagnostic accuracy of ultrasonography for hand bony fractures in paediatric patients. *Arch Dis Child* 2014; 99:1087–1090.
- Chang KV, Wu WT, Özçakar L. Ultrasound imaging for dorsal ulnar cutaneous neuropathy with extensor carpi ulnaris tendinopathy. *Am J Emerg Med Rehabil* 2017; 96:191–192.
- Wang L, Wang X, Shen S, et al. Progresses of ultrasound guided closed reduction and minimally invasive fixation of limb fractures. *Chin J Med Imaging Technol* 2017; 33:48–51.
- Aksay E, Kilic TY, Yesilaras M, Tur FC, Sever M, Kalenderer O. Accuracy of bedside ultrasonography for the diagnosis of finger fractures. *Am J Emerg Med* 2016; 34:809–812.