

# Presence of SARS-CoV-2 RNA in human corneal tissues donated in Italy during the COVID-19 pandemic

Stefano Ferrari ,<sup>1</sup> Elena Franco ,<sup>2,3</sup> Claudia Del Vecchio,<sup>4</sup> Ilaria Zorzi,<sup>1</sup> Elisa Fasolo,<sup>1</sup> Andrea Crisanti,<sup>4</sup> Diego Ponzin<sup>1</sup>

**To cite:** Ferrari S, Franco E, Del Vecchio C, *et al.* Presence of SARS-CoV-2 RNA in human corneal tissues donated in Italy during the COVID-19 pandemic. *BMJ Open Ophthalmology* 2022;7:e000990. doi:10.1136/bmjophth-2022-000990

Received 7 February 2022  
Accepted 31 May 2022

## ABSTRACT

**Objective** To analyse corneal tissues from asymptomatic donors with a postmortem nasopharyngeal swab tested positive for the presence of SARS-CoV-2 RNA, and therefore, understand the role that corneal transplantation may have in viral transmission.

**Methods and analysis** Between March 2020 and October 2021, 101 corneas (out of 8154 collected in Italy) from 51 donors (out of a total of 4155 Italian donors) positive for SARS-CoV-2 after postmortem nasopharyngeal swab tests were analysed for the presence of SARS-CoV-2 RNA through real-time RT-PCR. When available, the corneal tissue storage media were also assessed. Corneas and/or storage media with confirmed presence of SARS-CoV-2 RNA were further investigated by isolating SARS-CoV-2 virions, which were used to infect VeroE6 target cells.

**Results** Only N=4 corneas and/or storage media out of 101 showed presence of SARS-CoV-2 RNA. No VeroE6 cell infection was detected with viral isolates, thus suggesting no presence of SARS-CoV-2 virions in corneal specimens and storage media.

**Conclusions** The presence of SARS-CoV-2 in cornea specimens would seem to be more likely due to prolonged detection of RNA rather than to active viral replication, with very low risk of infectivity and transmission through keratoplasty.

## WHAT IS ALREADY KNOWN ON THIS TOPIC?

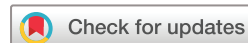⇒ During the COVID-19 pandemic, there has been a substantial change in the corneal tissue procurement and processing in eye banks worldwide, due to the potential risk of SARS-CoV-2 transmission through corneal transplantation.

## WHAT THIS STUDY ADDS?

⇒ The presence of SARS-CoV-2 in corneal specimens and/or storage media from patients with a positive postmortem nasopharyngeal swab tests seems to be mostly related to prolonged detection of viral RNA, with a negligible risk of infectivity.

## HOW THIS STUDY MIGHT AFFECT RESEARCH, PRACTICE OR POLICY?

⇒ Considering the minor risk of transmission of SARS-CoV-2 through keratoplasty, in the near future a call for an update of the current guidelines would be desirable. Corneas from SARS-CoV-2-positive donors could be treated similarly to those obtained from deceased donors with influenza or influenza-like symptoms that are not excluded from tissue donation.



© Author(s) (or their employer(s)) 2022. Re-use permitted under CC BY-NC. No commercial re-use. See rights and permissions. Published by BMJ.

<sup>1</sup>Fondazione Banca degli Occhi del Veneto, Venice, Italy

<sup>2</sup>Department of Translational Medicine, University of Ferrara, Ferrara, Italy

<sup>3</sup>Istituto Internazionale per la Ricerca e Formazione in Oftalmologia (IRFO), Forlì, Italy

<sup>4</sup>Department of Molecular Medicine, University of Padua, Padua, Italy

## Correspondence to

Dr Stefano Ferrari; stefano.ferrari@fbov.it

## INTRODUCTION

There is a limited knowledge about the presence of SARS-CoV-2 in corneal tissues. While some authors reported that viral RNA could not be found in the cornea of patients who died from COVID-19,<sup>1</sup> other identified viral genomic and subgenomic RNA (sgRNA) in the cornea of patients with COVID-19 viraemia.<sup>2,3</sup>

Corneal, conjunctival and limbal epithelial cells can exhibit the coexpression of ACE2 and transmembrane protease serine type 2 (TMPRSS2), which are the two entry factors for SARS-CoV-2, but this may not result in an effective infectivity, because the host genes required for genome replication are either absent or expressed at very low level.<sup>4</sup> Corneal tissue seems to be less permissive to SARS-CoV-2 infection compared with conjunctiva.<sup>5</sup>

In order to minimise the risks of SARS-CoV-2 transmissibility through corneal transplantation, guidelines and recommendations for corneal donor screening were released. The Global Alliance of Eye Bank Associations recommended to avoid tissues from donors infected with or recently exposed to COVID-19.<sup>6</sup> In Italy, the National Transplant Service (Centro Nazionale Trapianti, Rome, Italy) issued binding guidelines that, in case of donors with a documented or undocumented history of COVID-19 or with close contacts with subjects with confirmed SARS-CoV-2 infection, donor tissues could be considered eligible only 14 days after documented healing (resolution of symptoms and two negative swabs at least 24 hours apart) and with a nasopharyngeal swab performed within 24–48 hours, prior to recovery (on 24 February 2021 such interval was reduced to 14 days).

Due to these restrictions, COVID-19 pandemic has significantly affected corneal tissue procurement and processing in eye banks worldwide.<sup>7–9</sup> Despite this, to date, there have been no reported cases of transmission of SARS-CoV-2 through corneal transplantation. In addition, we and others have previously reported the low risk of SARS-CoV-2 transmission through corneal transplantation also from donors who contracted the SARS CoV-2 during lifetime.<sup>2 10</sup>

In this study, we have investigated the presence of SARS-CoV-2 RNA and potential infectious virions in 101 corneal tissues (out of 8154 corneas) isolated from 51 asymptomatic donors with positive postmortem nasopharyngeal swab test (out of a total of 4155 donors) throughout the pandemic period, between March 2020 and October 2021.

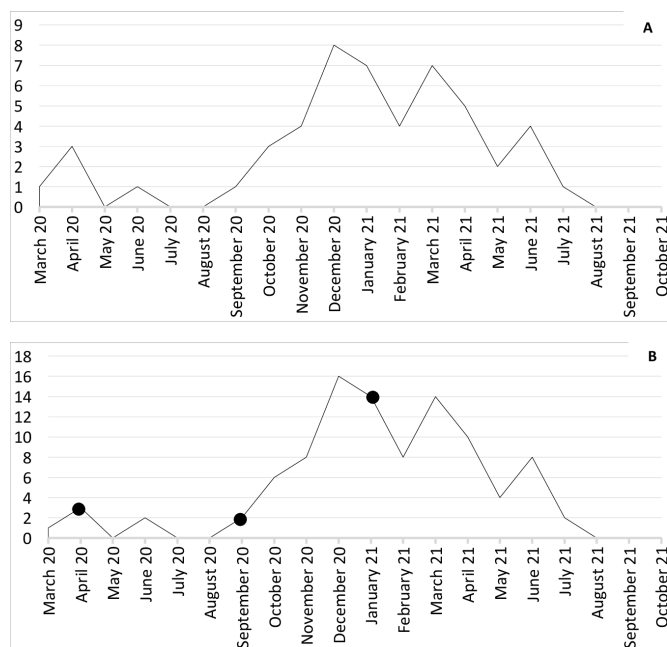
## MATERIALS AND METHODS

From March 2020 to October 2021, the Veneto Eye Bank Foundation (Venice, Italy) identified N=51 asymptomatic corneal donors who had neither medical evidence nor epidemiological links to COVID-19 cases, but were found positive for the presence of SARS-CoV-2 RNA after a postmortem nasopharyngeal swab test. Nasopharyngeal postmortem samples were collected using liquid-based transport systems (FLOQSwabs, COPAN SpA, Brescia, Italy), as previously described.<sup>11</sup>

The ocular specimens were recovered and used for this study in accordance with the laws of the Italian National Transplant Service (Centro Nazionale Trapianti, Rome, Italy) and after a written informed consent was obtained from the donors' next of kin.

Real-time RT-PCRs on nasopharyngeal swabs, corneal specimens and storage media were carried out using One Step Real-Time kits (Thermo Fisher Scientific, Waltham, Massachusetts, USA) to detect SARS-CoV-2 RNA and (s-gRNA, as previously described.<sup>12</sup>

Corneas and/or storage media, which were found positive for SARS-CoV-2 RNA, were further evaluated for the presence infectious virus able to be transmitted following keratoplasty. In detail, Vero CCL-E6 cells (<https://www.lgcstandards-atcc.org/>; ATCC#CRL-1586) were grown to confluent monolayer into a 25 cm<sup>2</sup> tissue culture flask maintained in Dulbecco's Modified Eagle Medium (DMEM) supplemented with 10% fetal bovine serum (FBS), penicillin (100 U/mL) and streptomycin (100 mg/mL). The cornea or 500 µL of liquid storage medium were added to 80% confluent Vero E6 cells monolayer. Mock-infected cells were used as a negative control. After 1-hour adsorption at 37°C, 3 mL of DMEM supplemented with 2% FBS and antibiotics were added. One-day postinfection, the monolayer was washed in PBS, and 4 mL of DMEM supplemented with 2% FBS and antibiotics were added. The cytopathic effect was monitored in inverted phase-contrast microscopy every day and supernatants collected. The presence of SARS-CoV-2 viruses in the harvested supernatants was then verified by quantitative RT-PCR, as reported previously.<sup>12–14</sup>



**Figure 1** (A) Corneal donors (n=51) with positive postmortem nasopharyngeal swab test between March 2020 and October 2021; (B) corneas (n=101) isolated from donors with positive postmortem nasopharyngeal swab test between March 2020 and October 2021. Closed circles in April 2020 (n=2), September 2020 (n=1) and January 2021 (n=1) indicate when corneas and/or storage media with positive SARS-CoV-2 RNA were found.

The study adhered to the 2013 tenets of the Declaration of Helsinki.

## RESULTS

### Donor cohort

From March 2020 to October 2021, the Veneto Eye Bank Foundation isolated 8154 corneas from 4155 donors (of these 7464 corneas from 3800 donors were from the north-eastern regions of Veneto and Friuli-Venezia Giulia). As required by the guidelines set by the Italian National Transplant Service, all tissue donors have to undergo compulsory postmortem nasopharyngeal swab tests, with the aim of reducing the risk of SARS-CoV-2 transmission following transplantation.<sup>15 16</sup> Among these 4155 donors, we found 51 asymptomatic donors (figure 1A) with positive postmortem nasopharyngeal swab test (1.2% of all the cornea donors between March 2020 and October 2021). Mean age of the donors was 64±11 years, with 36 males and 15 females. As required by the national legislation for eligibility to donate tissues, none of the donors died because of COVID-19 or was diagnosed with COVID-19-related symptoms at the time of death. In addition, all donors had the last positive swab test at least 14 days before the cornea was isolated, but N=20/51 (39%) presented at least one positive swab test during lifetime. Donors' demographics, cause of death and results of nasopharyngeal swab-tests are reported in table 1. No ocular conditions associated with COVID-19 were listed in the medical record of any of the 51 donors.

**Table 1** Characteristics and demographics of donors (n=51) with positive postmortem nasopharyngeal swab test.

Characteristic	Donors (n=51)
Age (years, mean±SD)	63.9 (±10.9)
Gender (M/F)	36/15
Cause of death:	
Cancer	28 (55%)
HF	13 (26%)
Aspiration pneumonia	2 (4%)
MOF	2 (4%)
ARDS	2 (4%)
Cirrhosis	1 (2%)
Polytrauma	1 (2%)
Suicide	1 (2%)
Cerebral haemorrhage	1 (2%)
Influenza-like symptoms	12 (24%)
Premortem positive nasopharyngeal swab-test	20 (39%)
SARS-CoV-2 sgRNA (n=20)*	3 (15%)

\*sgRNA testing applies to nasopharyngeal swab specimens, not corneal tissues or storage media.  
ARDS, acute respiratory distress syndrome; F, female; HF, heart failure; M, male; MOF, multiorgan failure; sgRNA, subgenomic RNA.

As expected, the frequency of the donors with positive postmortem nasopharyngeal swab test over the months (from March 2020 to October 2021) mirrored the pandemic curve observed in Veneto (available at <https://coronavirus.gimbe.org/regioni.it-IT.html#Veneto>), the Italian region of origin of 46 out of 51 donors.

### SARS-CoV-2 RNA in corneal tissues

A total of 101 corneas were isolated (figure 1B), with 1 not retrieved because of previous phacoemulsification procedure during the donor's lifetime. When the 101 corneas and the corresponding storage media were analysed, the presence of SARS-CoV-2 RNA was detected in the following samples from 4 donors (table 2):

- ▶ One cornea isolated in April 2020 from a donor (female) diagnosed with lung cancer and no COVID-19 related symptoms at the time of death. The contralateral cornea was negative for the presence of SARS-CoV-2 RNA.
- ▶ One cornea isolated in April 2020 and the corresponding storage medium from a donor (female) diagnosed with glioblastoma and no COVID-19-related symptoms at the time of death. The contralateral cornea (and the corresponding storage medium) was negative for the presence of SARS-CoV-2 RNA.
- ▶ The storage medium of one cornea isolated in September 2020 from a donor (male) diagnosed with lung adenocarcinoma and no COVID-19-related symptoms at the time of death. Both corneas were negative for the presence of SARS-CoV-2 RNA.
- ▶ One cornea isolated in January 2021 and the corresponding storage medium from a donor (male) who died following acute myocardial infarction due to hypertension and no COVID-19-related symptoms at the time of death. The contralateral cornea (and the corresponding storage medium) was negative for the presence of SARS-CoV-2 RNA.

Despite the presence of SARS-CoV-2 RNA in the tissue or the medium, viral-induced cytopathic effects and plaque formation were not reported when viral isolates from the corneal specimens of these four donors were tested on VeroE6 target cells, thus suggesting no presence of SARS-CoV-2 infective virions.

### Analysis of SARS-CoV-2 sgRNA

In order to discriminate between prolonged detection of viral RNA and ongoing viral infection, from February 2021, we started evaluating the presence of sgRNA in those donors with positive postmortem nasopharyngeal swab test. Out of 20 postmortem nasopharyngeal swabs, only N=3 resulted positive also for the presence of sgRNA (table 1), but neither the corresponding corneas nor the storage media showed any positivity for SARS CoV-2 RNA. As a consequence, none of the corneal specimens was analysed for the presence of SARS-CoV-2 sgRNA.

**Table 2** Details of corneas/liquid storage media (n=4) in which SARS-CoV-2 RNA was detected

Case no	Gender	Cause of death	Month of death	Cornea		Liquid storage medium		Viral-induced cytopathic effects/ plaque formation
				Right	Left	Right	Left	
1	F	Lung cancer	April 2020	-	+	-	-	NO
2	F	Glioblastoma	April 2020	-	+	-	+	NO
3	M	Lung adenocarcinoma	September 2020	-	-	+	-	NO
4	M	Acute myocardial infarction	January 2021	+	-	+	-	NO

F, female; M, male.

## DISCUSSION

From March 2020 to October 2021, when in Italy there was a predominant circulation of the Delta variant of SARS-CoV-2, we received corneal tissues from 4155 donors. Among these, 1.2% had a positive postmortem swab test, but only four corneas and/or storage media showed the presence of SARS-CoV-2 RNA. Considering that no signs of infective viral particles in the corneal specimens and storage media were ever detected, our results suggest a low risk of transmission following keratoplasty.

The effective infection of corneal tissues by SARS-CoV-2 is controversial and the results currently reported are heterogeneous, likely because of the small number of corneas analysed. Bayoud *et al* reported that no SARS-CoV-2 RNA was detected following quantitative RT-PCR in conjunctiva, anterior chamber fluid and corneal tissues (epithelium, stroma and endothelium) of five patients who died for respiratory insufficiency due to COVID-19.<sup>1</sup> On the contrary, Casagrande *et al* analysed 11 deceased patients with COVID-19 and high viral load (more than  $10^4$  copies per cell) in the throat swab and highlighted SARS-CoV-2 RNA in the corneal discs of 6 of 11 patients.<sup>3</sup> Subgenomic SARS-CoV-2 RNA was present in four of these six eyes (67%), but infectivity or presence of viral structural proteins could not be detected in any eye. The authors hypothesised a viral contamination occurring through the limbal vascular arcade and related to the high viral haematic loads, rather than a real corneal infection. Similarly, Miner JJ and colleagues reported no SARS-CoV-2 replication in human corneas.<sup>5</sup> In comparison with these studies, we analysed a larger group of donors and over a longer period, with a higher ratio of corneas analysed/corneas collected. Our results are confirmed even when including corneal tissues analysed from October 2021 to May 2022: we identified 26 more donors with a positive post-mortem swab test, with a surge between March and April 2022 (16 positive donors). This increase was related to Omicron and Omicron 2 variants diffusion, that showed greater contagiousness, but with modest or absent symptoms.<sup>17</sup> Omicron variant estimated prevalence was 99.86% in March 2022, while in April it was almost the only variant circulating in Italy.<sup>18</sup> While sgRNA was found in 8 out of these 16 cases, we did not find SARS-CoV-2 RNA in corneal tissues and/or storage media.

We ourselves previously reported similar results,<sup>2</sup> thus suggesting a low risk of SARS-CoV-2 transmission through corneal transplantation also from donors who contracted the SARS CoV-2 during lifetime.<sup>2 10</sup> A potential explanation for this may be that while the coexpression of ACE2 and transmembrane protease serine type 2 (TMPRSS2) have both been reported in cornea.<sup>4</sup> SARS-CoV-2 might not be able to replicate efficiently in human corneal cells, probably due to the lack of all the necessary replication factors.<sup>5</sup>

Our hypothesis to explain such results is that the presence of SARS-CoV-2 RNA in corneal specimens is not due to real infectivity, but to prolonged detection

of SARS-CoV-2 RNA in the tissues. The latter has been defined as viral shedding, but the concept remains controversial in the literature. Shedding can be intended as the capability of detecting viral RNA through RT-PCR, but there is not convincing evidence that duration of shedding correlates with duration of infectivity. Also, there is not a clear correlation between viral load and infectivity.<sup>19</sup> Other authors stated that the presence of nucleic acid alone cannot be used to define viral shedding or infection potential, because PCR does not distinguish between infectious virus and non-infectious nucleic acid.<sup>20</sup>

Cevik *et al*<sup>21</sup> recently reported that the mean duration of SARS-CoV-2 RNA shedding was of 17.0 days in the upper respiratory tract, 14.6 days in the lower respiratory tract 17.2 days in stool and 16.6 days in serum samples, with maximum shedding duration of up to 83 days in the upper respiratory tract and 126 days in stools. In addition, live virus was never detected after day 9 of illness. Similarly Liotti *et al*<sup>22</sup> reported that many patients who recovered from COVID-19 may still be positive for SARS-CoV-2 RNA, but only a minority (1 out of 32) carried a replicating virus in the respiratory tract, with the rest unlikely to be infectious.

Since we did not observe VeroE6 cell infection by virions isolated from the corneal specimens, it is possible that SARS-CoV-2 RNA might have contaminated the cornea via the bloodstream or through the nasolacrimal ducts. A further evidence supporting the hypothesis of prolonged detection of viral RNA as opposed to infectivity is that we did not detect SARS-CoV-2 RNA (and virions therefore) in corneas from those donors (n=3/20) with positive subgenomic SARS-CoV-2 RNA after postmortem nasopharyngeal test, that is, donors potentially having infectious virus circulating before death. In the future, it might be interesting to evaluate the presence of SARS-CoV-2 RNAs and virions in corneas from donors who died for COVID-19 and had ocular symptoms.

To date, there have been no reported cases of transmission of SARS-CoV-1, Middle East respiratory syndrome coronavirus or any other coronaviruses through transplantation of ocular tissues. Only a case of proven donor-to-recipient transmission of SARS-CoV-2 by lung transplantation despite negative donor upper respiratory tract testing has been reported and described.<sup>23</sup> If our results were confirmed on larger cohorts, they would open up new perspectives for eye banking as SARS-CoV-2-positive corneas could be treated similarly to those obtained from deceased donors with influenza or influenza-like symptoms that are not excluded from tissue donation. Downstream effect would be that eye banks would not lose corneas otherwise suitable for transplantation, as is already the case with other influenza viruses.

Additional important information arising from our results is the similarity between our graphs shown in figure 1A,B and the pandemic curve of the Venetian area, the Italian region of origin of 46 out of the 51 asymptomatic donors with positive postmortem nasopharyngeal swab test identified between March 2020 and



October 2021. As typical for respiratory viruses, a drop in the rate of positivity was seen both in the summer of 2020 and 2021, as expected since the circulation of the virus among the population is normally lower during the warmest months of the year. Instead, a great difference was observed when data from autumn 2020 are compared with those of autumn 2021. What are now known as the second and third waves of COVID-19 infections hit the Italian population (and the rest of Europe) severely, as clearly visible in the rise of donors with positive post-mortem tests starting from September 2020 and peaking up between December 2020 and March 2021. Differently, we did not see a similar increase after the summer of 2021, probably linked to a lower circulation of the SARS-CoV-2 virus in the population following vaccination (approximately 80% in Italy at September–October 2021). This further strengthens the benefits of vaccination. As the fourth wave of COVID-19 infections is expected in winter 2021, higher percentages of vaccination and third dose boosters might help reducing the number of positive subjects (and therefore positive donors), thus allowing to discard less precious corneas suitable for transplantation.

In conclusion, in our study we analysed a large cohort of donors for almost 2 years, suggesting a negligible risk of SARS-CoV-2 transmission through keratoplasty. This risk has been shown to remain very low even when considering different variants of SARS-CoV-2, thus, the increased transmissibility and morbidity seem not to influence the virus ability to infect the cornea. In the near future, a call for an update of the current guidelines about corneal donation in the COVID-19 era would be highly desirable.

**Acknowledgements** The authors would like to thank the regional transplant service (Centro Regionale Trapianti, Padova, Italy) for help and assistance with donors' screening.

**Contributors** SF and CDV collected the tissues and performed the molecular analyses; IZ and EF collected the donor's information and anamnesis; SF and EF analysed and interpreted the data and wrote the manuscript; AC and DP planned and designed the study. Stefano Ferrari (SF) acts as guarantor for the published work.

**Funding** This study was partially supported by the 5×1000 funds granted to Fondazione Banca degli Occhi del Veneto by the Italian Ministry of Health and the Italian Ministry of University and Research.

**Competing interests** None declared.

**Patient and public involvement** Patients and/or the public were not involved in the design, or conduct, or reporting, or dissemination plans of this research.

**Patient consent for publication** Not applicable.

**Provenance and peer review** Not commissioned; internally peer reviewed.

**Data availability statement** Data are available on reasonable request.

**Open access** This is an open access article distributed in accordance with the Creative Commons Attribution Non Commercial (CC BY-NC 4.0) license, which permits others to distribute, remix, adapt, build upon this work non-commercially, and license their derivative works on different terms, provided the original work is properly cited, appropriate credit is given, any changes made indicated, and the use is non-commercial. See: <http://creativecommons.org/licenses/by-nc/4.0/>.

#### ORCID iDs

Stefano Ferrari <http://orcid.org/0000-0003-3983-3328>

Elena Franco <http://orcid.org/0000-0002-3521-4290>

## REFERENCES

- 1 Bayyoud T, Iftner A, Iftner T, *et al*. Absence of severe acute respiratory Syndrome-Coronavirus-2 RNA in human corneal tissues. *Cornea* 2021;40:342–7.
- 2 Ferrari S, Del Vecchio C, Leonardi A, *et al*. Detection of severe acute respiratory syndrome coronavirus 2 in corneas from asymptomatic donors. *Acta Ophthalmol* 2021;99:e1245–6.
- 3 Casagrande M, Fitzek A, Spitzer MS, *et al*. Presence of SARS-CoV-2 RNA in the cornea of viremic patients with COVID-19. *JAMA Ophthalmol* 2021;139:383–8.
- 4 Collin J, Queen R, Zerti D, *et al*. Co-Expression of SARS-CoV-2 entry genes in the superficial adult human conjunctival, limbal and corneal epithelium suggests an additional route of entry via the ocular surface. *Ocul Surf* 2021;19:190–200.
- 5 Miner JJ, Platt DJ, Ghaznavi CM, *et al*. Hsv-1 and Zika virus but not SARS-CoV-2 replicate in the human cornea and are restricted by corneal type III interferon. *Cell Rep* 2020;33:108339.
- 6 Alert UP-DATE: coronavirus (COVID-2019) and ocular tissue donation, 2020. Available: <https://www.gaeba.org/2020/alert-coronavirus-2019-ncov-and-ocular-tissue-donation/>
- 7 Thuret G, Courrier E, Poinard S, *et al*. One threat, different answers: the impact of COVID-19 pandemic on cornea donation and donor selection across Europe. *Br J Ophthalmol* 2022;106:312–8.
- 8 Parekh M, Ferrari S, Romano V, *et al*. Impact of COVID-19 on corneal donation and distribution. *Eur J Ophthalmol* 2022;32:NP269–70.
- 9 Busin M, Yu AC, Ponzin D. Coping with COVID-19: an Italian perspective on corneal surgery and eye banking in the time of a pandemic and beyond. *Ophthalmology* 2020;127:e68–9.
- 10 Ferrari S, Del Vecchio C, Bosio L, *et al*. Absence of severe acute respiratory syndrome coronavirus 2 RNA in human corneal donor tissues: implications for transplantation. *Cornea* 2021;40:e3–4.
- 11 D'Aleo F, Arghittu M, Bandi C. Guidance to post-mortem collection and storage of biological specimens for the diagnosis of Covid-19 infection. *Microbiologia Medica* 2020;35.
- 12 Lavezzo E, Franchin E, Ciavarella C, *et al*. Suppression of a SARS-CoV-2 outbreak in the Italian municipality of VO'. *Nature* 2020;584:425–9.
- 13 Harcourt J, Tamin A, Lu X, *et al*. Severe acute respiratory syndrome coronavirus 2 from patient with coronavirus disease, United States. *Emerg Infect Dis* 2020;26:1266–73.
- 14 Huang C-G, Lee K-M, Hsiao M-J, *et al*. Culture-Based virus isolation to evaluate potential infectivity of clinical specimens tested for COVID-19. *J Clin Microbiol* 2020;58:e01068–20.
- 15 D'Amario C, Tamburini MR MF, E A. Aggiornamento delle misure di prevenzione della trasmissione dell'infezione da nuovo Coronavirus (SARS-CoV-2) in Italia attraverso il trapianto di organi e tessuti (Prot. 503/CNT 2020) [Italian Ministry of Health web site], 2020. Available: <http://www.trapianti.salute.gov.it/>
- 16 Rezza G, Tamburini MR, Maraglino FP. Aggiornamento delle misure di prevenzione della trasmissione dell'infezione da nuovo Coronavirus (SARS-CoV-2) in Italia attraverso il trapianto di organi e tessuti (Prot. 1108/CNT 2020). [Italian Ministry of Health website]. Available: <http://www.trapianti.salute.gov.it/>
- 17 Stefanelli P, Trentini F, Petrone D. Tracking the progressive spread of the SARS-CoV-2 Omicron variant in Italy, December 2021 - January 2022. *medRxiv* 2022:2022.01.27.22269949.
- 18 Stima DELLA prevalenza delle varianti VOC (variant of concern) E di altre varianti di SARS-CoV-2 in Italia (indagine del 07/03/2022).
- 19 Widders A, Broom A, Broom J. SARS-CoV-2: the viral shedding vs infectivity dilemma. *Infect Dis Health* 2020;25:210–5.
- 20 Atkinson B, Petersen E. SARS-CoV-2 shedding and infectivity. *Lancet* 2020;395:1339–40.
- 21 Cevik M, Tate M, Lloyd O, *et al*. SARS-CoV-2, SARS-CoV, and MERS-CoV viral load dynamics, duration of viral shedding, and infectiousness: a systematic review and meta-analysis. *Lancet Microbe* 2021;2:e13–22.
- 22 Liotti FM, Menchinelli G, Marchetti S, *et al*. Assessment of SARS-CoV-2 RNA test results among patients who recovered from COVID-19 with prior negative results. *JAMA Intern Med* 2021;181:702–4.
- 23 Kaul DR, Valesano AL, Petrie JG, *et al*. Donor to recipient transmission of SARS-CoV-2 by lung transplantation despite negative donor upper respiratory tract testing. *Am J Transplant* 2021;21:2885–9.