

Teaching Point (Section Editor: A. Meyrier)

Multiple renal arteries and non-contrast magnetic resonance angiography in transplant renal artery stenosis

Jair Munoz Mendoza¹, Marc L. Melcher², Bruce Daniel³ and Jane C. Tan⁴

¹Division of Nephrology and Hypertension, Department of Medicine, University of Miami, Miller School of Medicine, Miami, FL, USA, ²Department of Surgery, Stanford University School of Medicine, Stanford, CA, USA, ³Department of Radiology, Stanford University School of Medicine, Stanford, CA, USA and ⁴Department of Medicine, Stanford University School of Medicine, Stanford, CA, USA

Correspondence and offprint requests to: Jane C. Tan; E-mail: janetan@stanford.edu

Keywords: kidney transplantation; multiple renal arteries; non-contrast magnetic resonance angiography; transplant renal artery stenosis

Introduction

The reported incidence of transplant renal artery stenosis (TRAS), as high as 23% in earlier decades [1], ranges between 1.2 and 3.9% in more recent reports [2–5]. TRAS is a frequent cause of refractory hypertension and allograft dysfunction [5], but it is often treatable with percutaneous angioplasty. Therefore, its early recognition is critical. We describe the incidence of TRAS in our center over a 10-year period and report a case of TRAS to illustrate the complexity of the diagnosis in patients with slowly recovering graft function, multiple renal arteries and high immunologic risk for rejection. We highlight the utility of a novel non-contrast renal magnetic resonance angiography.

Incidence and case report

Incidence

Electronic medical records from 687 patients who underwent renal transplantation at Stanford Hospital and Clinics from January 2000 to May 2010 were reviewed. We excluded patients who received concurrently other solid organs or were transplanted in other centers. All transplant recipients were followed at least once a year and routine studies including serum creatinine (sCr) and immunosuppressant drugs levels were recorded until failure of the allograft.

Of the 687 renal transplant recipients, 7 (1.0%) underwent angiography because of clinical suspicion of TRAS. Five of the seven patients had a bruit, and all had a positive color Doppler ultrasound (CDU). The diagnosis of TRAS was confirmed in all seven cases. The clinical characteristics of the patients are described in Table 1. The mean age was 54.6 years (range 41–68 years). The mean time from transplant to angioplasty was 14.6 weeks (range 3–21 weeks). All patients presented before the sixth month

post-transplantation and the earliest intervention was performed at 3 weeks. TRAS was found in 5 (1.3%) of the 384 deceased donor recipients and in 2 (0.3%) of the 294 living donor recipients. Two patients had received a renal transplantation from an extended criteria donor and one from a donation after cardiac death. Three of the seven cases were in recipients from allografts with two renal arteries. Angioplasty was performed in all patients and three of them underwent stent placement—one with a sirolimus-eluting stent. All patients had improved allograft function after the intervention.

Case

A 44-year-old Asian man with end-stage renal disease of unknown cause underwent renal transplantation from a deceased donor. The renal allograft had a main superior renal artery and an accessory inferior renal artery. He received immunosuppression with thymoglobulin, tacrolimus, mycophenolate mofetil and prednisone. His sCr decreased from 4.7 mg/dL pre-operatively to 2.0 mg/dL throughout the first month. Approximately 4 months post-transplantation, he had an episode of acute allograft dysfunction—sCr increased to 3.8 mg/dL—associated with increased blood pressure requiring an additional anti-hypertensive drug. On physical exam, no bruit was detected overlying the allograft. A CDU demonstrated a 10.5 cm renal allograft with normal echogenicity and two patent main renal arteries both with normal velocities. Evaluation of the intra-renal segmental arteries showed ‘parvus tardus’ waveforms but normal resistive index. A renal allograft biopsy revealed mild acute tubulointerstitial cellular rejection. After treatment with steroids, sCr decreased to 2.2 mg/dL and blood pressure improved. Five months post-transplantation, his blood pressure worsened and sCr rose up to 2.9 mg/dL. A second renal allograft CDU of the superior-pole intra-renal segmental arteries showed parvus tardus waveforms and low-normal resistive index

Table 1. Clinical characteristic of patients with TRAS at a single center^a

Patient number	Age (years)	Time post-transplant (weeks)	Donor source	Number of renal arteries	Parvus tardus waveform in ultrasound	Intervention	Complications
1	58	15	Deceased/DCD	2	Yes	Angioplasty + stent	
2	65	21	Deceased/ECD	1	Yes	Angioplasty + stent	
3	64	5	Deceased	2	Yes	Angioplasty + stent	
4	76	18	Deceased/ECD	2	Yes	Angioplasty	Recurrence Pseudoaneurysm, small AVF
5	41	20	Living	1	No	Angioplasty	
6	68	20	Deceased	1	No	Angioplasty	
7	57	3	Living	1	No	Angioplasty	

^aDCD, donation after cardiac death; ECD, extended criteria donor.

(0.47–0.50). Angle-corrected peak velocities in the main superior renal artery were normal, from 73 to 85 cm/s. The inferior pole resistive index was normal (0.61) without parvus tardus waveform and the corresponding inferior accessory renal artery peak systolic velocity was not elevated (28 cm/s). A kidney allograft biopsy showed patchy mild interstitial inflammation associated with areas of atrophy, but no evidence of segmental or global glomerulosclerosis, glomerulitis, proliferation, necrosis or crescents. Focal intimal sclerosis was observed in the interlobular arteries and mild to moderate arteriosclerosis was present. A non-contrast magnetic resonance angiography was performed using inversion-recovery pulses to enhance arterial inflow and three-dimensional balanced steady-state free precession acquisition (INHANCE[®]) [6, 7]. This imaging study showed focal narrowing of the superior main renal artery 2 cm distal to the anastomosis with mild post-stenotic dilatation (Figure 1A). The inferior accessory artery was grossly normal, but assessment was limited by the small caliber of this vessel. X-ray angiography with CO₂ confirmed a 15 mm-long stenosis, 8 mm distal to the anastomosis in the superior main renal artery (Figure 1B). The peak systolic gradient of 100 mmHg was consistent with a very tight stenosis. Angioplasty was performed with excellent angiographic results and no residual pressure gradient. A decision was made not to use a stent due to the difficulty of deployment in the area of stenosis. The inferior accessory artery was normal. A post-angioplasty renal allograft CDU showed improved arterial waveforms and resistive index. The patient was continued on aspirin and clopidogrel was started. The sCr decreased to 1.8 mg/dL and his blood pressure improved. He is currently maintained on low doses of blood pressure medications.

Discussion

TRAS has been associated with almost three-fold increased risk of graft loss (including death, hazard ratio 2.8, 95% confidence interval 1.7–4.7) [4]. Its clinical presentation includes worsening or refractory hypertension and allograft dysfunction in the absence of rejection, obstruction or infection [3, 5]. The published incidence of TRAS varies widely from 1.2 to 23%, based upon the time of the study, the use of screening ultrasound, threshold for diagnosis and the studies' inclusion criteria [1, 4, 5]. We found an incidence of 1.0% over a 10-year period, which is similar to the more recent reports. The higher incidences reported in studies without the evidence of allograft dysfunction are likely overestimates of clinically significant TRAS. The reported time from transplantation to the diagnosis of TRAS or intervention ranges from 0.3 to 1.7 years [4, 8], with the most frequent

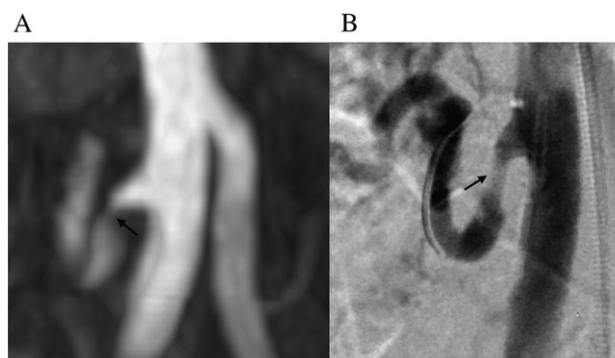


Fig. 1 (A) Non-contrast magnetic resonance angiography using inversion-recovery-prepared balanced steady-state free precession technique (INHANCE[®]) and (B) CO₂ angiogram showing narrowing of the renal artery (black arrows) with mild post-stenotic dilatation.

occurrences described within the first 6 months [3, 4], which is corroborated by our data. Early onset of TRAS has been associated with vascular anomalies such as atherosclerosis of the donor artery, long artery and short vein and traumatic lesions [3].

Delayed allograft function [4, 5, 9], older recipient and donor age [4], extended criteria donors [4], cytomegalovirus infection [5] and acute rejection [5, 9] have been associated with an increased likelihood of developing TRAS. Some studies have shown higher incidence of TRAS in deceased versus living donor renal transplant recipients [2, 8], but the opposite has also been reported [3, 4]. Benedetti *et al.* [10] reported that the presence of multiple arteries did not increase the incidence of early vascular complications, but it was a risk for late TRAS. In our center, three of the seven patients with TRAS who had allografts with two renal arteries presented early post-transplant. The presence of multiple renal arteries in the appropriate clinical scenario may be a simple useful clue for the diagnosis of TRAS.

Various non-invasive screening tests for TRAS have been described. The measurements of renin activity before and after captopril challenge have low specificity (67%) in patients with TRAS [11] likely because the volume expansion that largely contributes to hypertension in this setting inhibits renin release resulting in low or normal plasma renin activity [12]. Isotopic renography pre- and post-stimulation with captopril has also been used as screening for TRAS. However, because its limited sensitivity (75%) and specificity (84%) [11] have been replaced by CDU. The non-invasive CDU is commonly used nowadays as the initial study for the diagnosis of TRAS because it is widely available, it does not require radioactive tracers and it has good

sensitivity (87–94%) and specificity (86–100%) [12]. A prolonged systolic rise (slow upstroke) with a small amplitude waveform—the parvus tardus waveform—is a very useful ultrasonographic sign that often raises the suspicion for TRAS [13]. However, CDU has limitations and the results depend on the experience and technique of the operator. In our center, only four patients with a confirmed diagnosis of TRAS have parvus tardus waveforms in CDU (Table 1). Other useful tests for diagnosis of renal artery stenosis are the computed tomographic angiography (sensitivity 98% and specificity 94%) [14] and the magnetic resonance angiography (sensitivity 83% and specificity 97%) [15]. These two non-invasive tests are superior to CDU, but both need either iodine or gadolinium contrast agents that frequently are contraindicated in patients with impaired renal function. Recently, a novel non-contrast magnetic resonance angiography using inversion-recovery-prepared balanced steady-state free precession technique (INHANCE[®]) [6, 7] has been shown to have good agreement with contrast-enhanced magnetic resonance angiography, with a sensitivity and specificity for detection of significant stenosis of 82–94% and 82–87%, respectively [6]. This new technique uses spatially-selective pulses to magnetically label arterial blood and provides intrinsically high contrast images of arterial anatomy without needing exogenous contrast agents that carry risks of worsening renal dysfunction and nephrogenic systemic fibrosis. Furthermore, this new non-contrast magnetic resonance angiography is non-invasive; as opposed to the CO₂ angiography that avoids use of iodine contrast agents but is not exempt of procedure-related complications alike the conventional angiography that remains the ‘gold standard’ for the diagnosis of TRAS. The use of this novel technology contributed to the diagnosis and treatment of our patient and may be an important tool to evaluate patients with suspected TRAS in whom iodine and gadolinium contrast agents are usually contraindicated.

Percutaneous transluminal angioplasty is commonly used for the management of TRAS. The majority of studies have shown impressively high technical success [2, 5, 9], improvement in blood pressure and renal function [3, 5, 9] and reduction in the number of anti-hypertensive drugs [3, 5]. However, studies reporting outcomes after angioplasty for the management of TRAS have found divergent results. Some studies [5] reported worse graft survival in patients with TRAS after angioplasty compared with controls, others [4] found no difference in graft survival between patients treated with or without angioplasty, and more recently, Ghazanfar et al. [8] reported better long-term graft survival in patients with TRAS treated with percutaneous angioplasty alone or with stent placement compared with medical treatment (86 versus 63%, respectively). Failure to consistently detect a benefit in outcomes from angioplasty contrasts with the excellent reports improving serum creatinine and blood pressure. These conflicting results may be related to the expertise and experience of the interventionists and perhaps because many interventions are performed in clinically non-significant stenosis. Angioplasty alone or with stent placement carries risks of complications that include renal artery dissection, perforation, peripheral embolus, thrombosis, distal branch renal artery embolus, hematomas, pseudoaneurysm and stent migration/dislocation or thrombosis and graft loss [3, 5]. The rate of these complications is usually <10% [3, 4, 9].

The case reported here illustrates the challenges in the timely diagnosis of TRAS, the importance of clinical presentation and the utility of a novel non-contrast renal magnetic resonance angiography using inversion-recovery-

prepared balanced steady-state free precession technique (INHANCE[®]) to detect TRAS before proceeding to angiographic evaluation. Although we report a low incidence (1%) of angiographically confirmed clinically significant TRAS, the possibility of this diagnosis should be always entertained especially in the presence of multiple renal arteries and in the early post-transplant period when common confounders such as acute rejection and nephrotoxic effects of medications frequently alter blood pressure and allograft function.

Teaching points

- (i) The diagnosis of TRAS may be initially overlooked in patients with slowly recovering graft function and high immunologic risk for rejection. However, the possibility of TRAS must always be entertained when worsening hypertension and acute allograft dysfunction are present.
- (ii) The presence of multiple renal arteries in the appropriate clinical scenario may be a simple useful clue for the diagnosis of TRAS.
- (iii) Because the risks of worsening renal dysfunction and nephrogenic systemic fibrosis with exogenous contrast agents, the use of inversion-recovery-prepared balanced steady-state free precession non-contrast magnetic resonance angiography may be advisable.

Conflict of interest statement. None declared.

References

1. Lacombe M. Arterial stenosis complicating renal allotransplantation in man: a study of 38 cases. *Ann Surg* 1975; 181: 283–288
2. Patel NH, Jindal RM, Wilkin T et al. Renal arterial stenosis in renal allografts: retrospective study of predisposing factors and outcome after percutaneous transluminal angioplasty. *Radiology* 2001; 219: 663–667
3. Voiculescu A, Schmitz M, Hollenbeck M et al. Management of arterial stenosis affecting kidney graft perfusion: a single-centre study in 53 patients. *Am J Transplant* 2005; 5: 1731–1738
4. Hurst FP, Abbott KC, Neff RT et al. Incidence, predictors and outcomes of transplant renal artery stenosis after kidney transplantation: analysis of USRDS. *Am J Nephrol* 2009; 30: 459–467
5. Audard V, Matignon M, Hemery F et al. Risk factors and long-term outcome of transplant renal artery stenosis in adult recipients after treatment by percutaneous transluminal angioplasty. *Am J Transplant* 2006; 6: 95–99
6. Glockner JF, Takahashi N, Kawashima A et al. Non-contrast renal artery MRA using an inflow inversion recovery steady state free precession technique (Inhance): comparison with 3D contrast-enhanced MRA. *J Magn Reson Imaging* 2010; 31: 1411–1418
7. Lanzman RS, Voiculescu A, Walther C et al. ECG-gated non-enhanced 3D steady-state free precession MR angiography in assessment of transplant renal arteries: comparison with DSA. *Radiology* 2009; 252: 914–921
8. Ghazanfar A, Tavakoli A, Augustine T et al. Management of transplant renal artery stenosis and its impact on long term allograft survival: a single centre experience. *Nephrol Dial Transplant* 2011; 26: 336–343
9. Halimi JM, Al-Najjar A, Buchler M et al. Transplant renal artery stenosis: potential role of ischemia/reperfusion injury and long-term outcome following angioplasty. *J Urol* 1999; 161: 28–32

10. Benedetti E, Troppmann C, Gillingham K et al. Short- and long-term outcomes of kidney transplants with multiple renal arteries. *Ann Surg* 1995; 221: 406–414
11. Erley CM, Duda SH, Wakat JP et al. Noninvasive procedures for diagnosis of renovascular hypertension in renal transplant recipients—a prospective analysis. *Transplantation* 1992; 54: 863–867
12. Bruno S, Remuzzi G, Ruggenti P. Transplant renal artery stenosis. *J Am Soc Nephrol* 2004; 15: 134–141
13. Richardson D, Foster J, Davison AM et al. Parvus tardus waveform suggesting renal artery stenosis—remember the more proximal stenosis. *Nephrol Dial Transplant* 2000; 15: 539–543
14. Olbricht CJ, Paul K, Prokop M et al. Minimally invasive diagnosis of renal artery stenosis by spiral computed tomography angiography. *Kidney Int* 1995; 48: 1332–1337
15. Gedroyc WM, Negus R, al-Kutoubi A et al. Magnetic resonance angiography of renal transplants. *Lancet* 1992; 339: 789–791

Received for publication: 21.11.11; Accepted in revised form: 21.2.12