



# Hip Arthroplasty Using the Bencox<sup>®</sup> Hip System: An Evaluation of a Consecutive Series of One Thousand Cases

Joong-Myung Lee, MD, PhD, Young-Suk Sim, MD, Dae-Sung Choi, MD

*Department of Orthopaedic Surgery, CHA Bundang Medical Center, CHA University, Seongnam, Korea*

**Purpose:** This is a report on the outcomes associated with a consecutive series of 1,000 cementless hip arthroplasties utilizing the Bencox<sup>®</sup> hip stem—the first Korean-developed hip prosthesis.

**Materials and Methods:** A consecutive series of 1,000 hip arthroplasties using the Bencox<sup>®</sup> hip stem were analyzed, starting from its initial release (September 2006) until June 2014. Patients in this consecutive series underwent surgery for fractures (n=552), arthritis (n=155), avascular necrosis (n=209), and revisions (n=84). Of these 1,000 cases, patients with a minimum follow-up of at least 1 year (n=616) were retrospectively analyzed for radiographic and clinical outcomes (i.e., Harris hip score). The stability of the prosthesis was evaluated by examining subsidence.

**Results:** During the follow-up period (mean follow-up period of 54.8 months), there were 2 cases requiring revision of the femoral stem—both were caused by periprosthetic fractures and neither involved stem loosening. The mean Harris hip score during follow-up was 95.5. Bone ongrowth occurred in 95% of patients; no cases of subsidence or aseptic loosening of the stem were detected, and no cases of postoperative complications such as ceramic breakage were observed.

**Conclusion:** Clinical and radiographic evaluations of hip arthroplasty using the Bencox<sup>®</sup> hip stem revealed excellent outcomes with an average of 54.8 month follow-up in a consecutive series of 1,000 cases.

**Key Words:** Bencox<sup>®</sup> hip system, Cementless hip arthroplasty

**Submitted:** October 27, 2018 **Final acceptance:** November 5, 2018

**Address reprint request to**

**Joong-Myung Lee, MD, PhD**

(<https://orcid.org/0000-0001-6241-9534>)

Department of Orthopaedic Surgery, CHA Bundang Medical Center, CHA University, 59 Yatap-ro, Bundang-gu, Seongnam 13496, Korea

**TEL:** +82-31-780-5289 **FAX:** +82-31-708-3578

**E-mail:** drjmlee@naver.com

This is an Open Access article distributed under the terms of the Creative Commons Attribution Non-Commercial License (<http://creativecommons.org/licenses/by-nc/4.0>) which permits unrestricted non-commercial use, distribution, and reproduction in any medium, provided the original work is properly cited.

## INTRODUCTION

Total hip arthroplasty (THA) was first introduced by Sir John Charnley in the 1960s, and has been accepted as the most common surgical procedure used worldwide for the management of hip-joint diseases<sup>1</sup>. A cemented femoral stem used for THA in the early period achieved firm fixation; however, this approach was associated with high rates of revision surgery due to complications at long-term follow-up (e.g., aseptic loosening and severe osteolysis around cemented components) and was also associated with fatal complications caused by fat embolisms and bone cement embolisms<sup>2,3</sup>. For these reasons, beginning in the early 1980s, cementless femoral stems were developed with

the goal of improving biomechanical fixation; since their development, these stems have been widely used<sup>4</sup>. Many attempts have been made to develop and manufacture femoral stems in Korea and in 2006, the Bencox<sup>®</sup> hip stem (Corentec, Seoul, Korea) became the first total hip prosthesis domestically commercialized. The authors of this study aimed to verify the stability and efficacy of the Bencox<sup>®</sup> hip system by reviewing a consecutive series of 1,000 cementless hip arthroplasties using the Bencox<sup>®</sup> hip stem<sup>5</sup>.

## MATERIALS AND METHODS

### 1. Materials

A consecutive series of 1,000 THA performed using the Bencox<sup>®</sup> hip stem by a single surgeon between September 2006 (following its approval) and July 2014 were included in this study. Since a wide range of patients of different ages, bone qualities and muscle strengths were included in the study; an analysis of those patients at the same time may not obtain meaningful results. Patients were classified into groups based on reason for surgery (i.e., fracture, osteoarthritis [OA], avascular necrosis [AVN] and re-operation). This study reviewed medical and test records for a retrospective analysis of patients and was approved by the institutional review board of our institution (IRB No. CHAMC 2017-11-017).

Breakdown of patient groups is as follows: OA (n=155), AVN (n=209), and fracture including femoral neck, intertrochanteric femur and other fractures (n=552). Bipolar hemiarthroplasty was performed in most cases and THA was done in some patients. Revision surgery was carried out in 84 cases. The re-operation group included patients who underwent surgery for aseptic loosening, periprosthetic fracture and conversion THA after THA infection. As shown in Table 1, of the patients included in this study, 616 were followed up for a minimum of one year (mean, 54.8 months; range, 12-309 months).

The Bencox<sup>®</sup> hip stem used in this study is the first artificial hip arthroplasty implant developed in Korea. The Bencox<sup>®</sup> hip stem design has a straight, double-tapered, wedge shape figure with a rectangular-shaped cross-section and no collars, and three vertical ribs in the lateral aspect of the proximal body of the stem. This stem has adopted a trapezoidal neck design patented in the United States. to offer increased range of motion (ROM) of the femoral neck, and is made of titanium alloy (Ti6Al4V) and treated with micro arc oxidation (MAO)-blasted surface coating to maximize bone ongrowth<sup>6</sup> (Fig. 1). In THA, the Bencox<sup>®</sup> cup is coated with titanium plasma spray on the surface and hemisphere-shaped, and three screw holes are anatomically designed for more effective fixation. Since the Bencox<sup>®</sup> hip system was first manufactured in September 2006, the offset was increased in 2009 and the stem shoulder edge was chamfered for easy insertion. In the current study, arthroplasties were performed using the initial design (n=296) and the modified design (n=704). However, since these two stem systems were fundamentally the same, we did not analyze them independently.

All operations were performed by a single surgeon via a transgluteal approach with patients in the supine position. For anatomical reconstruction, the height of the greater trochanter was determined based on the distance from the center of femoral head and the lesser trochanter (head-lesser trochanter distance)<sup>7</sup>. Given the possibility of lesser trochanter fracture in fracture patients, insertion of the femoral component was carried out by measuring the distance from the tip of the fracture to the center of the femoral head by adding fragment size and head-lesser trochanter distance measured preoperatively. The size of the rasp was gradually increased according to the measured values before surgery to expand the canal, and the stem size was determined for firm fixation. After insertion of the femoral stem, a trail head was placed. After temporary reduction, adequate leg tension was determined by measuring leg length discrepancy.

**Table 1.** Material (Patient) information & follow up period of group

Variable	Group 1 (OA)	Group 2 (ONFH)	Group 3 (Fracture)	Group 4 (Rev. or Def.)
Sex, male/female	52/103	146/63	183/369	54/30
Average age (yr)	57.2	53.3	76.0	59.3
Patients with at least 12 mo of follow up	126/155 (81.2%)	173/209 (82.7%)	248/552 (44.9%)	69/84 (82.1%)
Average follow-up (mo)	57.8	60.3	49.2	55.6
Total cases	155	209	552	84

OA: osteoarthritis, ONFH: osteonecrosis of the femoral head, Rev: revision, Def: deformity.

Since the lesser and greater trochanters are important muscle insertion points within the hip, anatomical reconstruction and firm fixation of the trochanters are crucial for postoperative function. For this reason, fixation was additionally carried out with a candy-package wiring technique originally designed by the authors in cases with lesser trochanter fractures<sup>8,9</sup>. Since the fracture line of the greater trochanter runs more in the coronal plane, reduction of bone fragments were performed after insertion of the femoral stem. Fragments were then fixed firmly using cables and wires to help achieve stability<sup>10</sup>.

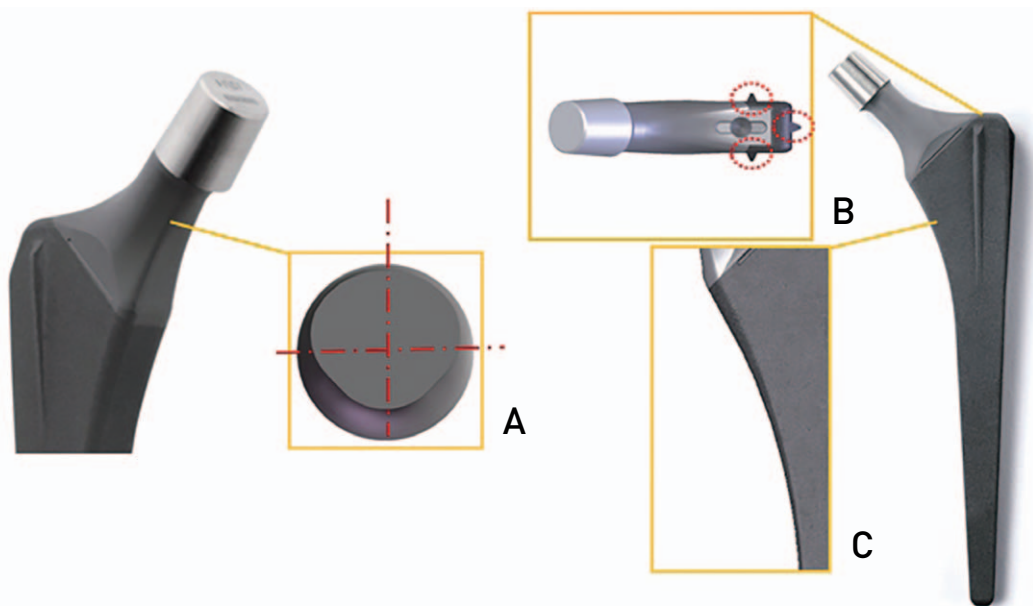
Prophylactic antibiotics were administered immediately and for 3 to 5 days after surgery. On the second or third postoperative day, the Hemovac drain was removed and partial weight bearing ambulation using crutches was allowed. Total weight bearing ambulation was allowed from the fourth or sixth postoperative week.

## 2. Methods

Radiographic examinations were performed during the patient's hospital stay, 6 weeks, 3, 6 and 12 months after surgery and annually. Evaluations were conducted based on clinical outcome indicators including Harris hip scores (HHS), postoperative thigh pain, and complications (e.g., infection and dislocation). Radiographic assessment was carried out based on anteroposterior (AP) and lateral X-

rays of the hip and radiographic appearance of endosteal bone ongrowth on both AP and lateral views, osteolysis and subsidence. Bone ongrowth was determined by gross observation of bone-bridge formation that indicates bone growth at the border between the femur and an implant and on the stem surface. The presence of osteolysis was confirmed with cortical reaction to the femoral stem. The stability of the femoral stem was determined with subsidence. Subsidence of the stem was determined by measuring the distance from the tip of the greater trochanter to the shoulder of the femoral prosthesis (superior lateral aspect of the proximal body of the stem). If the distance increased by more than 5 mm in sequential radiographs taken immediately after surgery and at the final follow-up, it was considered as a significant subsidence. The severity of heterotopic ossification was evaluated according to the Brooker classification<sup>11</sup>. Radiographic evaluations were independently conducted by three orthopedic surgeons who had not participated in any surgery.

HHS were measured to evaluate clinical outcomes. HHS was calculated in 175 cases, and hips with a score of >90 points were considered an excellent result, 80 to 90 points defined as a good result, 70 to 80 points as fair, and <70 points as poor.



**Fig. 1.** Bencox® (Corentec, Seoul, Korea) cementless femoral stem design, straight, rectangular, double wedged, tapered, titanium-alloy stem with a rough, grit-blasted surface. Note the smaller neck diameter (A), three vertical ribs in the stem shoulder area (B) and anatomical contour medial-proximal portion (C).

RESULTS

1. Clinical Results

Postoperative laboratory exam, blood chemistry, and infection and medical findings in immunologic tests revealed no abnormal findings. The results of the HHS measurements are as follows, excellent (n=126), good (n=32), fair (n=14) and poor (n=3); the average HHS at the final follow-up was 95.5—a score in the excellent range (Table 2). No complications were observed (e.g., stem breakage, ceramic breakage, dislocation).

Stem subsidence or aseptic loosening was not seen postoperatively. Periprosthetic fractures were determined by using the Vancouver classification. A total of 19 patients had a periprosthetic fracture. A hip classified as Vancouver type A was managed with cable fixation. The 9 hips classified as Vancouver type B1 were managed as follows: cable fixation (n=5), open reduction and internal fixation with plate (n=3),

and conservative treatment due to old age and poor systemic condition (n=1). Of 2 cases classified as Vancouver type B2, 1 had a stem change with a longer stem and the other case received a cemented stem change due to poor bone quality around the prosthesis (Fig. 2). Seven hips were classified as Vancouver type C, and bone union was achieved with open reduction and internal fixation with plate. No patients experienced complications (e.g., postoperative dislocation, infection, complaints of persistent hip pain).

2. Radiological results

Bony ongrowth around the femoral component was observed in 235 (94.8%) of 248 patients in the fracture group, 120 (95.2%) of 126 in the OA group, 166 (96.0%) of 173 in the AVN group, and 64 (92.8%) of 69 in the re-operation group. Of the 616 patients who were followed up for a minimum of 1 year, 585 (95.0%) experienced bony ongrowth. Although there was variation in the healing time

Table 2. Summary of Clinical Outcome (i.e., Harris hip score)

	Group 1 (OA)	Group 2 (ONFH)	Group 3 (fracture)	Group 4 (Rev. or Def.)	Total
Length of follow-up (mo)	64.4	50.1	75.9	77.8	54.8
Average HHS	97	97	92	94	95.5
Cases	56	51	39	29	175
Proportion	56/155 (36.1%)	51/209 (24.4%)	39/552 (7.1%)	29/84 (34.5%)	175/1,000 (17.5%)

OA: osteoarthritis, ONFH: osteonecrosis of the femoral head, Rev: revision, Def: deformity.

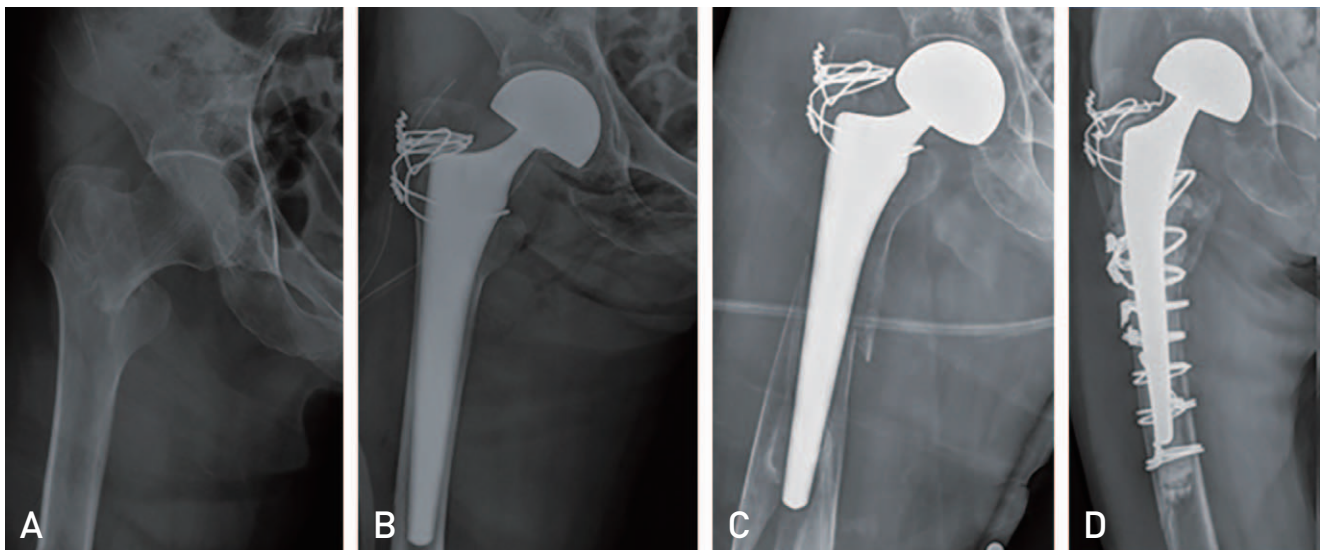


Fig. 2. (A) Radiograph of a 74-year-old female with right intertrochanter fracture. (B) Postoperative anteroposterior (AP) hip radiograph. (C) Six years after periprosthetic fracture (Vancouver type B2) AP hip radiograph. (D) Cemented stem bipolar hemiarthroplasty.

of fractures, bone ongrowth occurred between 6 months and 1 year postoperatively and observed mainly in the intermediate and distal regions of the femoral component. Bony ongrowth is easily visible in the radiographs where the femoral stem and femoral bone are in contact with each other.

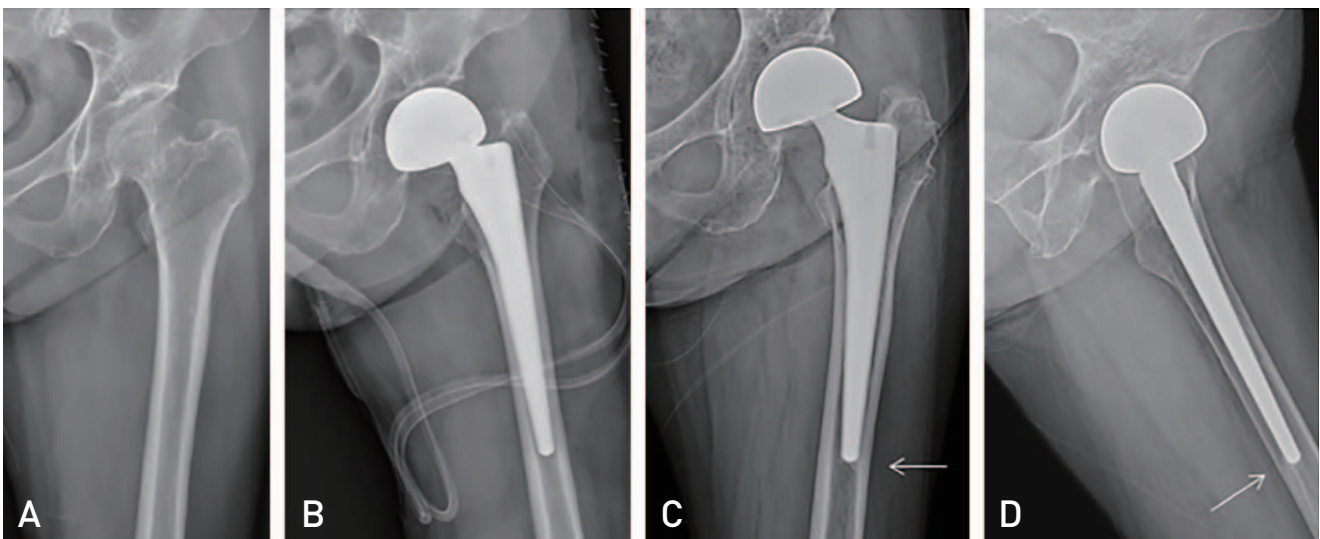
On hip AP X-ray, bony ongrowth was easily visible within the mediolateral region, and Hip lateral X-ray bony ongrowth was well founded in the posterior aspect of the distal region (Fig. 3). No patients experienced osteolysis affecting stem stability and vertical subsidence of the femoral stem. Some cases had varus insertion less than 5°; however, in all cases, these patients achieved stable bony fixation with no specific findings (Fig. 4). There were 2 cases of heterotopic ossification. The first was Brooker class II heterotopic ossification that occurred after surgery; however, no reduction in ROM was observed. The other patients experiencing heterotopic ossification were classified as Brooker class IV; ROM returned following ossification excision surgery.

## DISCUSSION

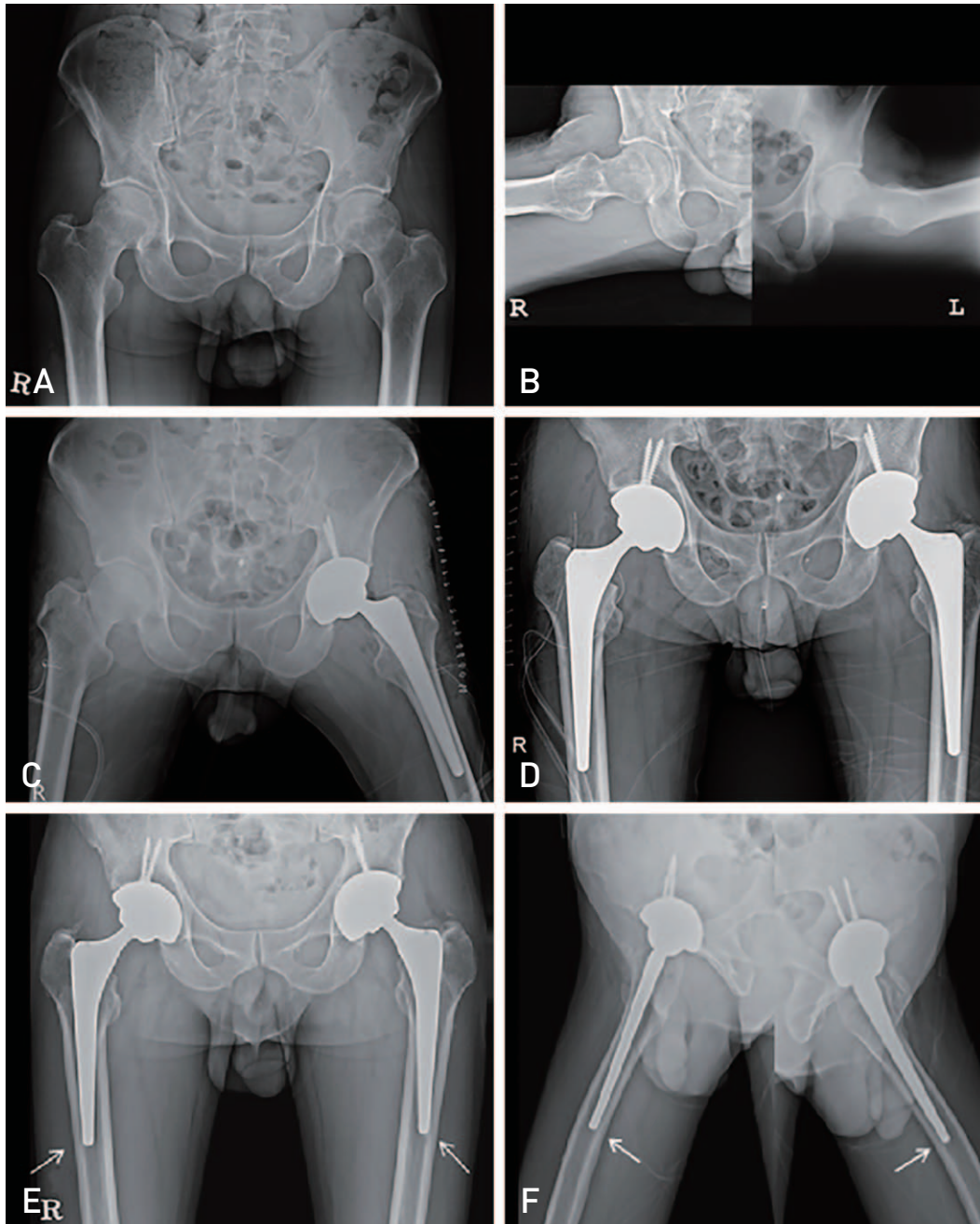
In THA, the femoral stem should be selected according to patient's diagnosis, BMD and shape of the femur. The use of a cemented stem allows early ambulation by obtaining initial firm fixation<sup>12-14</sup>. However, cardiovascular complications have been associated with this approach (e.g., intraoperative fat embolism, bone cement embolism, vasodilation due to autonomic reflex); additionally, failure of biologic fixation,

thigh pain, stress-shielding, bone resorption and loosening, and difficulty of stem extraction in revision surgery have been reported at both mid- and long-term follow-up<sup>15,16</sup>. Cortical atrophy, proximal stress-shielding, bone loss and other problems produced in early-designed cemented femoral stems have been reported to be significantly associated with cylindrical shape and extensive porous coating of a stem<sup>17,18</sup>. To help overcome these potential complications, many studies have been performed using cementless femoral stems, and tapered cementless femoral stems are now widely used in THA.

The Bencox<sup>®</sup> hip system used in this study is the first cementless femoral stem developed and manufactured in Korea. We reviewed the results of a consecutive series of 1,000 cementless hip arthroplasties utilizing the Bencox<sup>®</sup> hip stem and report favorable clinical and radiological outcomes in all patient groups encountered. In particular, no stem failure caused by subsidence or aseptic loosening occurred—a satisfactory result. Moreover, bony ongrowth was shown in 95.0% of patients (585 of 616 cases) with follow up for at least one year. Our previous 5-year follow-up study revealed good results of the Bencox<sup>®</sup> stem (e.g., excellent bone ongrowth rates [86.6% in the fracture group, 99.6% in the OA group without subsidence or complications requiring revision operation])<sup>19</sup>. In another study, 78% of patients with an unstable intertrochanteric fracture experienced restoration of their ambulation ability to a pre-injury state, and the combined use of wiring fixation has been described to help obtain support in the posterolateral aspect including



**Fig. 3.** (A) Radiograph of a 72-year-old female with left femoral neck fracture. (B) Postoperative anteroposterior (AP) hip radiograph. (C, D) Seven years after follow up hip AP and lateral radiograph reveals stable bony fixation without no subsidence or osteolysis.



**Fig. 4.** (A, B) Radiograph of a 47-year-old male with both osteonecrosis of femoral head. (C, D) Serially bilateral total hip arthroplasty post-operative anteroposterior (AP) hip radiograph. (E, F) Four years after follow up hip AP and lateral radiograph reveals stable joint.

the lesser trochanter<sup>5,10</sup>. These results compare favorably to the long-term follow-up results of a study involving the Cementless Spotorno (CLS; Protek AG, Berne, Switzerland) stem and Zweymüller stem (Alloclassic; Sulzer Orthopedics, Basel, Switzerland) that resemble the tapered wedge design and blasted surface coating of the Bencox<sup>®</sup> hip stem. Cruz-Pardos et al.<sup>20</sup> reported that the survival rate of Zweymüller

stems was 95.9% at a minimum follow-up of 25 years. Furthermore, CLS stem had a survival rate of 98.5% at an average follow-up of 17 years in a study of Müller et al.<sup>21</sup> and bone ongrowth at 93.6% and a survival rate of 100% at an average follow-up of 17 years and 3 months in a previous study by this group<sup>22</sup>. The results achieved seem to be attributed to the unique design and features of the

Bencox<sup>®</sup> hip stem. A Bencox<sup>®</sup> hip stem is straight, double wedged and tapered with a rectangular cross-section and designed to achieve press-fit at the metaphysis and initial rigid compression reduction in the femoral intramedullary canal by increasing axial and rotational stability within the cylindrical shape of the medullary cavity. Solid fixation can be obtained in patients with arthritis and in elderly patients with hip fractures<sup>9)</sup>. The stem with three vertical ribs on its proximal end improves early rotational stability, and this design can prevent stress shielding with no contact to the distal cortex by increasing proximal stability and surface contact rate and help preserve the femur bone stock. In addition, the slim diaphyseal part—designed to not fill the distal medullary cavity—reduces stress shielding and induces bone ongrowth on all surfaces. In this study, we report a high bone ongrowth rate of 94%.

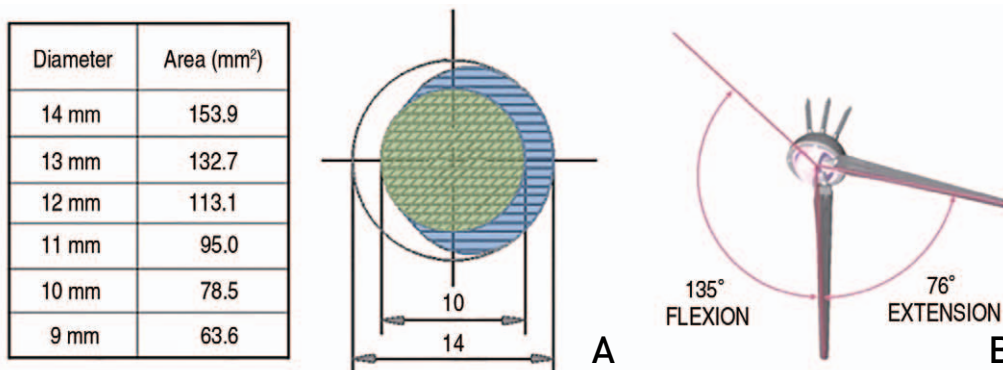
Haentjens et al.<sup>23)</sup> suggested that bipolar hemiarthroplasty in the elderly with intertrochanter femur fracture significantly reduced the occurrence of cardiovascular complications by allowing early ambulation compared to open reduction internal fixation (ORIF). In the current study, the high bone ongrowth rate in the fracture group implies that the femoral stem is maintaining good fixation in the hip. Although surgeons may hold different opinions about what type of surgery to perform, we think that cementless THA could be an appropriate surgical option (along with ORIF) for the management of osteoporotic fractures occurring in elderly patients.

No patients in the current study complained of hip pain after surgery. This outcome, comparable to previous findings, is thought to be attributable to the fact that the stem with a tapered design serves a critical role in more evenly distributing weight load to the proximal and distal femur, thus providing

a gradual decrease of stiffness from the proximal to the distal regions. Moreover, osseointegration, rigid fixation at the proximal portion, anatomical reduction of fracture fragments of the greater and lesser trochanters<sup>24,25)</sup>, and a surgical procedure of adjusting leg length discrepancy by checking adequate stress on the legs in a trial reduction after stem insertion seem to reduce pain and limping.

In addition, the surface treatment of the Bencox<sup>®</sup> hip stem and the unique neck design with an increased head-neck ratio seem to contribute to favorable outcomes. MAO used in surface coating results in numerous porosity structures (diameter of 15  $\mu$ m) that maximize the contacting area with the surrounding bone, assists in adhering the osteoblast and facilitates bone ongrowth. These design features that improve biocompatibility and fixing force provide an excellent environment for bone ongrowth. The Bencox<sup>®</sup> hip stem is designed with an increased head-neck ratio by reducing a femoral stem neck diameter in order to minimize prosthetic impingement during hip joint motion and a trapezoidal neck design to maintain an optimized neck diameter and minimize neck impingement. This specialized design is expected to be an appropriate hip prosthesis for both Asians with a sedentary lifestyle and Westerners with a standing lifestyle. Since indications for THA have broadened to include active young patients, the Bencox<sup>®</sup> hip system is expected to meet the worldwide trends of increasing long-term implant survival rates (Fig. 5).

Complications such as infection or dislocation did not occur, and no observed loosening caused by subsidence appears even more impressive. However, periprosthetic fractures occurred in 19 cases. In a comparative study on Vancouver B1 and B2 periprosthetic fractures occurring after well-fixed cementless grit-blasted tapered-wedge stems were



**Fig. 5.** (A) A specially designed trapezoidal shape implant to increase range of motion. (B) Photographs revealing excellent prosthetic range of motions when simulated with smaller neck and 36-mm alumina head. In the sagittal plane, flexion and extension can be increased to 135° and 76°, respectively.

used, there was a 4-fold increased rate of Vancouver type B2 fractures (80.4%) compared with Vancouver B1 fractures. In the present study, there were only 9 cases of Vancouver type B1, 2 cases of Vancouver type B2, and 7 cases with Vancouver type C; stem stability was maintained in the majority of patients<sup>26</sup>). Since fracture type is determined by complex factors including the degree of comminution, the level of bone ongrowth, the onset time of postoperative fracture, bone quality and others, the distribution of periprosthetic fractures may differ despite the use of the same stem. Of 19 patients experiencing periprosthetic fractures, 12 were from the fracture group, perhaps as a result of older age at the time of surgery and poorer bone quality in this group. Moreover, those patients experienced periprosthetic fractures resulting from a simple fall due to poor walking ability before surgery. The poor general health condition of the fracture group is thought to be another cause. Except for two cases that underwent revision of femoral stem change due to periprosthetic fracture, no cases of stem failure caused by subsidence or aseptic loosening was a satisfactory outcome of this study.

There are some notable limitations in this study. Statistical analyses were unable to be performed because it was difficult to establish a control group and select patient groups due to the nature of the study. The number of withdrawals from the study was high due to high mortality rates among older patients. In addition, it was difficult to compare pre- and post-operative conditions because the study involved a large number of fracture patients.

## CONCLUSION

The Bencox® hip stem is the first developed in Korea and designed as a double wedged, tapered stem which enables rigid fixation and rotational stability and evenly distributed stress as it has almost no stress shielding. Another advantage of the stem is the neck design made to optimize the ROM. Clinical and radiographic evaluations of hip arthroplasty using the Bencox® hip stem revealed excellent outcomes in a consecutive series of 1,000 cementless hip arthroplasties performed in patients requiring surgery for a number of different injuries.

## CONFLICT OF INTEREST

The authors declare that there is no potential conflict of interest relevant to this article.

## REFERENCES

1. Learmonth ID, Young C, Rorabeck C. *The operation of the century: total hip replacement. Lancet.* 2007;370:1508-19.
2. Banaszkiwicz PA. *Radiological demarcation of cemented sockets in total hip replacement. In: Banaszkiwicz PA, Kader D, ed. Classic Papers in Orthopaedics. London: Springer; 2014. 39-41*
3. Rothman RH, Cohn JC. *Cemented versus cementless total hip arthroplasty. A critical review. Clin Orthop Relat Res.* 1990;(254):153-69.
4. Malik A, Maheshwari A, Dorr LD. *Impingement with total hip replacement. J Bone Joint Surg Am.* 2007;89:1832-42.
5. Kim S, Lee JM, Kim WH, Han JK, Lee JY, Choi BI. *Focal peliosis hepatis as a mimicker of hepatic tumors: radiological-pathological correlation. J Comput Assist Tomogr.* 2007;31:79-85.
6. Kim JT, Yoo JJ. *Implant design in cementless hip arthroplasty. Hip Pelvis.* 2016;28:65-75.
7. Lim Y, Chang YJ, Kwon SY, Kim YS. *A simple method using a PACS to minimize leg length discrepancy in primary THA: a method to minimize leg length discrepancy. J Arthroplasty.* 2013;28:1791-5.
8. Bourne RB, Rorabeck CH. *Soft tissue balancing: the hip. J Arthroplasty.* 2002;17(4 Suppl 1):17-22.
9. Masonis JL, Bourne RB. *Surgical approach, abductor function, and total hip arthroplasty dislocation. Clin Orthop Relat Res.* 2002;(405):46-53.
10. Lee JM, Cho Y, Kim J, Kim DW. *Wiring techniques for the fixation of trochanteric fragments during bipolar hemiarthroplasty for femoral intertrochanteric fracture: Clinical study and technical note. Hip Pelvis.* 2017;29:44-53.
11. Banaszkiwicz PA. *Ectopic ossification following total hip replacement: incidence and a method of classification. In: Banaszkiwicz PA, Kader D, ed. Classic Papers in Orthopaedics. London: Springer; 2014. 105-7.*
12. Chan KC, Gill GS. *Cemented hemiarthroplasties for elderly patients with intertrochanteric fractures. Clin Orthop Relat Res.* 2000;(371):206-15.
13. von Roth P, Abdel MP, Harmsen WS, Berry DJ. *Cemented bipolar hemiarthroplasty provides definitive treatment for femoral neck fractures at 20 years and beyond. Clin Orthop Relat Res.* 2015;473:3595-9.
14. Hong CC, Nashi N, Makandura MC, Krishna L. *Cemented hemiarthroplasty in traumatic displaced femoral neck fractures and deep vein thrombosis: is there really a link? Singapore Med J.* 2016;57:69-72.
15. Stauffer RN. *Ten-year follow-up study of total hip replacement. J Bone Joint Surg Am.* 1982;64:983-90.
16. Sutherland CJ, Wilde AH, Borden LS, Marks KE. *A ten-year follow-up of one hundred consecutive Müller curved-stem total hip-replacement arthroplasties. J Bone Joint Surg Am.* 1982;64:970-82.
17. Bourne RB, Rorabeck CH, Ghazal ME, Lee MH. *Pain in the thigh following total hip replacement with a porous-coated anatomic prosthesis for osteoarthritis. A five-year follow-up study. J Bone Joint Surg Am.* 1994;76:1464-70.
18. Lavernia C, D'Apuzzo M, Hernandez V, Lee D. *Thigh pain in primary total hip arthroplasty: the effects of elastic moduli.*



- J Arthroplasty*. 2004;19(7 Suppl 2):10-6.
19. Lee JM, Jeon JB. Result of a minimum five-year follow-up of hip arthroplasty using the Bencox<sup>®</sup> hip stem. *J Korean Orthopaedic Assoc*. 2014;49:126-32.
  20. Cruz-Pardos A, García-Rey E, García-Cimbrelo E. Total hip arthroplasty with use of the cementless Zweymüller Alloclassic System: A concise follow-up, at a minimum of 25 years, of a previous report. *J Bone Joint Surg Am*. 2017;99:1927-31.
  21. Lee JM, Park YS. Long-term follow-up results after hip arthroplasty using a Cementless Spotorno (CLS) femoral stem. *J Korean Orthop Assoc*. 2008;43:710-7.
  22. Müller LA, Wenger N, Schramm M, Hohmann D, Forst R, Carl HD. Seventeen-year survival of the cementless CLS Spotorno stem. *Arch Orthop Trauma Surg*. 2010;130:269-75.
  23. Haentjens P, Casteleyn PP, De Boeck H, Handelberg F, Opdecam P. Treatment of unstable intertrochanteric and subtrochanteric fractures in elderly patients. Primary bipolar arthroplasty compared with internal fixation. *J Bone Joint Surg Am*. 1989;71:1214-25.
  24. Barrack RL, Butler RA. Current status of trochanteric reattachment in complex total hip arthroplasty. *Clin Orthop Relat Res*. 2005;441:237-42.
  25. Koyama K, Higuchi F, Kubo M, Okawa T, Inoue A. Reattachment of the greater trochanter using the Dall-Miles cable grip system in revision hip arthroplasty. *J Orthop Sci*. 2001;6:22-7.
  26. Lim SJ, Lee KJ, Min BW, Song JH, So SY, Park YS. High incidence of stem loosening in association with periprosthetic femur fractures in previously well-fixed cementless grit-blasted tapered-wedge stems. *Int Orthop*. 2015;39:1689-93.