

Imaging the eye and its relevance to diabetes care

Nicola Quinn^{1,2†} , Alicia Jenkins^{1,2,*†}, Chris Ryan^{1,3}, Andrzej Januszewski^{1,3}, Tunde Peto^{2,‡}, Laima Brazionis^{1,3,‡}

¹National Health and Medical Research Council Clinical Trials Center, The University of Sydney, Sydney, New South Wales, Australia, ²Center for Public Health, Queen's University Belfast, Belfast, UK, and ³Department of Medicine, The University of Melbourne, Melbourne, Victoria, Australia

Keywords

Artificial intelligence, Diabetic retinopathy, Retinal vessels

*Correspondence

Alicia Jenkins

Tel: +61-2-9562-5000

Fax: +61-2-9562-1863

E-mail address:

alicia.jenkins@ctc.usyd.edu.au

J Diabetes Investig 2021; 12: 897–908

doi: 10.1111/jdi.13462

ABSTRACT

Diabetes is a major cause of vision loss globally, yet this devastating complication is largely preventable. Early detection and treatment of diabetic retinopathy necessitates screening. Ocular imaging is widely used clinically, both for the screening and management of diabetic retinopathy. Common eye conditions, such as glaucoma, cataracts and retinal vessel thrombosis, and signs of systemic conditions, such as hypertension, are frequently revealed. As well as imaging by a skilled clinician during an eye examination, non-ophthalmic clinicians, such as general practitioners, endocrinologists, nurses and trained health workers, can also carry out diabetic eye screening. This process usually comprises local imaging with remote grading, mostly human grading. However, grading incorporating artificial intelligence is emerging. In a clinical research context, retinal vasculature analyses using semi-automated software in many populations have identified associations between retinal vessel geometry, such as vessel caliber, and the risk of diabetic retinopathy and other chronic complications of type 1 and type 2 diabetes. Similarly, evaluation of corneal nerves by corneal confocal microscopy is revealing diabetes-related abnormalities, and associations with and predictive power for other chronic diabetes complications. As yet, the value of retinal vessel geometry and corneal confocal microscopy measures at an individual level is uncertain. In this article, targeting non-ocular clinicians and researchers, we review existent and emerging ocular imaging and grading tools, including artificial intelligence, and their associations between ocular imaging findings and diabetes and its chronic complications.

INTRODUCTION

Diabetes mellitus is an increasingly prevalent chronic condition affecting people of both sexes across a wide age range in all ethnicities worldwide. The International Diabetes Federation estimated that globally there are 463 million adults aged 20–79 years with diabetes, with numbers predicted to rise to 700 million by 2045¹. An estimated 75% of people with diabetes live in disadvantaged regions¹, where access to optimal glucose and other risk factor management and recommended screening and monitoring of chronic complications is often limited. Even in advantaged regions, some subgroups with diabetes, such as those living in very remote regions, in nursing homes and indigenous people, might not have ready access to recommended diabetes care and screening programs.

The eye allows direct visualization of the vasculature and, with advances in technology, of the retinal neurovasculature and corneal neural networks, which might provide insights into current and future ocular and extra-ocular health. Many chronic systemic conditions (such as diabetes and hypertension) manifest in the retina, therefore imaging the retinal arterioles and venules can help provide vital diagnostic information. Globally, diabetic retinopathy (DR) is the leading cause of preventable blindness in working-age adults; however, with early detection and appropriate and timely systemic and ocular treatment, severe vision loss and blindness can be largely prevented. The presence of DR also indicates an increased risk of diabetic nephropathy, cardiovascular disease (CVD) and death^{2,3}.

Retinal fundus imaging is a valuable clinical and research tool, and has been widely implemented around the world in DR screening and research programs due to its potential cost-effectiveness, particularly when based on a non-ophthalmic workforce. As in most countries, even affluent countries,

[†]Joint first authors

[‡]Joint senior authors

Received 18 August 2020; revised 8 November 2020; accepted 10 November 2020

ophthalmologists and optometrists are not geographically well-distributed outside major cities; hence, input by non-ophthalmic imagers and tools to facilitate remote diagnosis is key. As the majority of patients with DR have no symptoms until late-stage, ocular screening of people with diabetes is important to enabling early intervention (with systemic risk control, specifically, glycemic control⁴ and where indicated of oral fenofibrate, as shown by the Fenofibrate Intervention and Event Lowering in Diabetes [FIELD] and Action to Control Cardiovascular Risk in Diabetes [ACCORD] Lipid Eye trials in Type 2 diabetes^{5,6}.

A DR screening program can also detect non-diabetes-related pathology. Nielsen *et al.*⁷ investigated patients ($n = 307$) who attended diabetes 'cycle of care' appointments in Australia, including screening for non-diabetic abnormalities, and found a higher prevalence of non-diabetic (30.6%) than DR conditions (24.9%). Non-diabetic conditions include age-related macular degeneration, glaucoma, cataract, hypertensive changes, epiretinal membranes, choroidal nevi, chorioretinal scars, vascular thrombosis or emboli, inflammation and infections⁷. Retinal vascular biomarkers have shown the potential for the early detection, monitoring, and prediction of various diabetes

complications and other conditions. In a research context, retinal fundus image analysis of retinal vessel geometry using semi-automated software has predicted the future risk of DR^{8,9}, diabetic nephropathy⁸, diabetic peripheral neuropathy⁸, stroke¹⁰, hypertension¹¹, CVD¹² and dementia¹³.

Herein, we discuss the main ocular imaging techniques for type 1 diabetes and type 2 diabetes that are used in clinical practice or as research tools. This includes clinically used imaging to detect the classic lesions of DR (microaneurysms, exudates and neovascularization) and macular edema, best assessed by optical coherence tomography (OCT) and their grading by humans or artificial intelligence (AI). Technology-based research tools in diabetes include the semi-automated analysis of retinal vessel caliber and geometry, and corneal confocal microscopy (CCM).

RETINAL IMAGING

Generally, DR screening is based on multi-field 45° field of view color retinal fundus images, with each image capturing approximately 15% of the overall retina. As shown in Figure 1a, readily seen retinal landmarks include: (i) the optic disc, exit point for the ganglion cell nerve fibers and central veins,

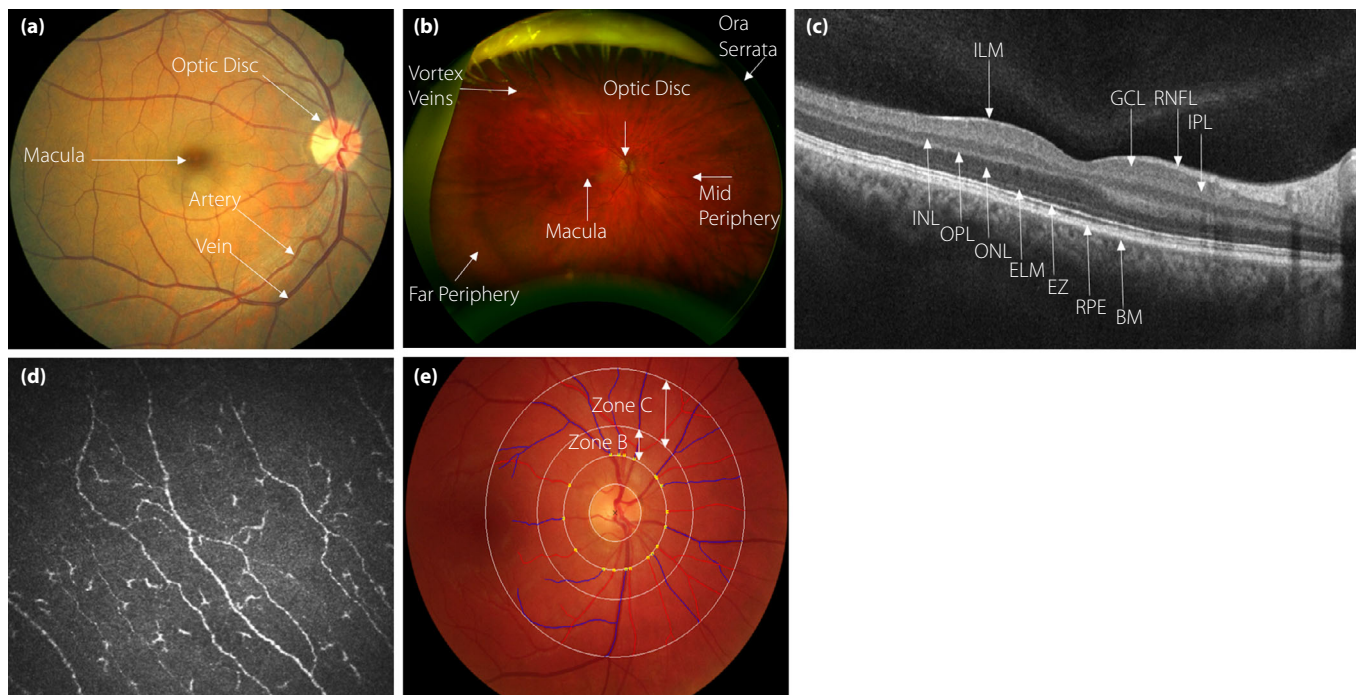


Figure 1 | (a) Standard macula-centered fundus image showing retinal landmarks (artery, vein, macula and optic disc). (b) An ultra-wide field Optos photo image ~200° field of view (~80% retinal coverage). (c) Optical coherence tomography image showing a high-resolution cross-sectional image of 11 different structural layers of the normal retina. BM, Bruch's membrane; ELM, external limiting membrane; EZ, ellipsoid zone; GCL, ganglion cell layer; ILM, internal limiting membrane; INL, inner nuclear layer; IPL, inner plexiform layer; ONL, outer nuclear layer; OPL, outer plexiform layer; RNFL, retinal nerve fiber layer; RPE, retinal pigment epithelium. (d) Sub-basal nerve plexus captured using corneal confocal microscopy. (e) Optic disc centered retinal fundus image shows the overlay of the Singapore "I" Vessel Assessment retinal vessel analysis software. Zone B represents the annulus 0.5-1 disc diameter from the optic disc edge; vessel caliber is measured in this zone. Zone C represents the annulus 1-2 disc diameters from the optic disc edge; retinal vascular geometry is measured in this zone.

and entry point for arteries supplying the inner layers of the retina; (ii) the macula, an oval area surrounding the fovea in the center of the retina, which is responsible for central sharp vision; and (iii) arteries and veins. Imaging modalities viewing the peripheral retina capture more fundamental retinal landmarks, the vortex veins that are responsible for draining the choroid and the ora serrata, which is the jagged junction between the retina and the ciliary body (Figure 1b).

DR can be detected non-invasively *in vivo* by clinicians using direct or indirect ophthalmoscopes, slit-lamp biomicroscopy and/or retinal fundus imaging to visualize the retinal fundus. A range of different imaging protocols has been introduced; the gold standard for grading DR lesions is the seven-standard stereoscopic fields defined by the Early Treatment Diabetic Retinopathy Study (ETDRS) group, with each field capturing a 30° field of view and in aggregation approximately a 75° field of view, equating to approximately 34% of the retinal surface. The UK screening program imaging protocol captures two 45° field of view images, which includes a macula and optic disc-centered image. Other imaging modalities that have been reviewed for DR screening and might in future be used in the screening setting, provided they are clinically- and cost-effective, include confocal scanning ophthalmoscopes, the most widely available (in alphabetical order) are: Clarus™ 500 (Carl Zeiss Meditech Inc., Dublin, CA, USA), Eidon (CenterVue, Padova, Italy), Heidelberg Retinal Tomograph (Heidelberg Engineering GmbH, Heidelberg, Germany) and Optomap (Optos, Dunfermline, UK)¹⁴.

A common and potentially sight-threatening cause of vision loss in DR is diabetic macular edema (DME), which in population-based studies occurs in 4.2–7.9% of people with type 1 diabetes, and 1.4–12.8% of people with type 2 diabetes¹⁵. DME is difficult to detect on standard retinal photos, as retinal thickening is difficult to identify reliably unless OCT is used.

Optical coherence tomography

The gold standard for DME detection is now OCT, which assesses 6 × 6 mm of the neurovascular retina. OCT is a non-invasive, *in vivo* ophthalmic technique that requires skilled operators (including non-ophthalmic clinicians) and captures three-dimensional images showing the structural layers of the retina (Figure 1c)¹⁶. OCT produces both qualitative and quantitative information key to the assessment of DME. OCT does not provide functional and dynamic information of the retinal vasculature, including blood flow velocity; therefore, fluorescein angiography remains the gold standard for visualizing dynamic changes in the vasculature. Fluorescein angiography is invasive, time-consuming, and does not produce three-dimensional images and image resolution. With the introduction of OCT angiography, a non-invasive technique imaging the microvasculature of the retina and choroid, several of these limitations have been resolved. OCT angiography provides three-dimensional images of the retina and visualizes the presence or absence of blood flow in the vessels, providing functional

information of the vascular network¹⁶. However, to date, fluorescein angiography captures a wider area of the retina, and images are less liable to artefacts compared with OCT angiography.

Corneal confocal microscopy

CCM can be used to capture *in vivo* images of corneal nerve fibers (Figure 1d), changes that are a less well-known feature of diabetes and are associated with diabetic peripheral neuropathy (DPN). CCM is used clinically in the management of corneal injuries and corneal dystrophies^{17,18}. The eye is also unique, as it is the only organ in the body that allows the direct and non-invasive observation of nerves. A series of clinical research studies over the past decade showed that CCM has the potential to detect¹⁹ and classify the severity of DPN²⁰, predict the development of DPN²¹, and monitor the recovery after interventions^{23–25}. The main parameters used in the assessment of corneal nerve pathology are corneal nerve fiber length (NFL), corneal nerve fiber density, corneal nerve fiber branch density and corneal nerve fiber tortuosity²². Studies have shown that corneal nerve fiber density, nerve fiber branch density and NFL are decreased in people with diabetes, and progressively decrease as the duration of diabetes and severity of neuropathy increases²³. A longitudinal study by Pritchard *et al.* showed that CCM could predict the 4-year incidence of DPN with 63% sensitivity and 74% specificity for an NFL threshold cut-off of 14.1 mm/mm²²¹. Furthermore, tighter glycemic control has been shown to significantly increase corneal nerve fiber density and NFL²⁴, highlighting the potential for CCM in diabetes care management and as a surrogate end-point in clinical trials.

Diabetic retinal disease grading in clinical practice

After image acquisition, images are primarily used for DR and maculopathy grading for DR severity and disease progression. This is heavily reliant on the expertise of the examiner. More recently, AI grading is being introduced, including into clinical practice for DR management. The various classifications of DR are determined by the presence or absence of retinal vascular changes, including microaneurysms, hemorrhages, hard and soft exudates, cotton wool spots, intraretinal microvascular abnormalities, venous beading, neovascularization, vitreous and/or preretinal hemorrhage, fibrous proliferation, tractional retinal detachment, and macular edema. The three most widely used classifications are: (i) The International Clinical Diabetic Retinopathy and Diabetic Macular Edema Disease Severity Scale; (ii) the ETDRS Severity scale; and (iii) the UK National Screening Program. For simplicity, in clinical practice, rather than 'score' simplified diagnoses, such as mild, moderate or severe background DR, or non-proliferative DR (NPDR), pre-proliferative DR or proliferative DR (PDR) are provided. Figure S1 shows examples of retinal pathology for different stages of DR severity; normal, mild, moderate and severe NPDR, PDR and DME.

AI for DR screening

AI is now being used as both a research and clinical DR grading tool to alleviate pressure on healthcare systems. In 2018, the US Food and Drug Administration approved an AI-based grading system, the IDx for DR identification using the Topcon NW400 (Topcon Medical Systems, Oakland, New Zealand) non-mydratric fundus camera²⁵. Several studies to date have used fundus retinal images to test the performance of AI grading systems in detecting DR, some of which we expand on below. These studies concentrated on the detection of various DR lesions, (microaneurysms, hemorrhages, exudates, cotton wool spots and neovascularization), and the classification of DR, such as NPDR, PDR and sight-threatening DR (STDR).

AI studies differ in AI grading systems used, outcomes measured and sample size^{26,27}. Ting *et al.*²⁸ examined a deep learning system for not only the detection of referable DR and STDR, but also identifying related eye diseases (glaucoma and age-related macular degeneration) in nearly 500,000 retinal images. The system produced a sensitivity (true positive rate) of 90.5% for detecting referable DR compared with human graders at 91.5%. A sensitivity of 100% was detected using the system compared with 88.6% for human graders for STDR. Although impressive, the specificity (true negative rate) value was 91.1% compared with humans at 99.6%²⁸. Li *et al.*²⁹ developed and validated an AI system for the detection of sight-threatening referable DR, producing a sensitivity and specificity of 92.5% and 98.5%, respectively. Ting *et al.*³⁰ carried out a meta-analysis involving eight datasets (six population-based studies and two hospital-based studies), where they compared the prevalence and systemic risk factors for DR determined using an AI system and human assessors using two-field retinal images. They found that the AI system and human assessors identified a similar DR prevalence (AI vs human assessors: 16.1% vs 15.9% any DR, 6.4% vs 6.5% referable DR and 3.7% vs 4.1% STDR) and risk factors of DR. They also found that the AI system was 360-fold faster than the human assessors in grading DR³⁰. Previous AI-based grading systems for DR have concentrated on diagnosing DR at different stages. More recently, in September 2019, Arcadu *et al.*³¹ proposed a deep learning model to predict future DR progression (2-step worsening on the ETDRS Scale) using seven color fundus images. The deep learning model was trained against DR severity scores assessed after 6, 12 and 24 months from the baseline by masked trained graders. Their deep learning model was able to predict a two-step or more ETDRS score worsening at 6, 12 and 24 months (area under the curve 0.68). They also highlighted the importance of the predictive signal located in the peripheral retinal fields, which is not routinely captured in DR screening. With further work, this could enable earlier diagnosis and referral to a retina specialist for more frequent monitoring and consideration of early intervention³¹.

As much as AI might be changing the DR grading landscape, there are significant drawbacks to consider. Although they are potentially useful in DR screening programs, they are

not yet diagnostically accurate, and clinicians and patients must be aware that false positive and/or false negative rates do not yet meet diagnostic benchmarks. For example, the US Food and Drug Administration approved the IDx AI grading system, and reported a sensitivity and specificity of 87.4 and 89.5 for mild DR, respectively, therefore one in 10 people might have a false positive or false negative result. A balance between sensitivity and specificity in AI-based grading systems is vital to make it cost-effective and acceptable to clinicians and patients. Also, in the cases of missed DR diagnosis, who is legally responsible? AI grading systems will be able to support, but not replace, clinical decision-making, with Sayres *et al.*³² reporting that deep learning algorithms improved accuracy and confidence in DR diagnosis by ophthalmologists. Currently, AI-based grading systems for DR have been developed using conventional fundus images capturing up to 60° of the retina. With the increasing use of other imaging techniques in DR, such as ultra-wide field retinal imaging, perhaps AI grading systems should also be developed for these technologies. Ideally, AI systems for DR screening should be evaluated in study populations of different races and ethnicities, varying quality of retinal images (i.e. poor focus or contrast, poor pupil dilation, or the presence of media opacities) and also images showing other sight-threatening eye diseases, such as glaucoma and age-related macular degeneration. Based on our own experience, suboptimal image quality is particularly common when images are acquired by non-ocular clinicians, as is increasingly so in very remote and disadvantaged regions³³.

RESEARCH-RELATED RETINAL ASSESSMENTS

Retinal vessel caliber and geometry, and computer-assisted grading

Changes in retinal vessel caliber were first reported by Skovborg *et al.*³⁴ in 1969. With increasingly sophisticated computer programs enabling computerized retinal measurements, we can now quantify disease-related early retinal vascular changes, including retinal vessel caliber and geometry. Historically, vessel caliber was the main parameter investigated using standard color fundus photography; namely, the central retinal arteriolar equivalent (CRAE), central retinal venular equivalent (CRVE) and arteriovenous ratio.

DR assessment has long concentrated on qualitative analysis, documenting the lesion type, severity and distribution. Although retinal vascular changes themselves do not always lead to immediate vision loss, they are useful biomarkers for the future risk of eye disease and other systemic conditions^{8,10,11}. Many studies have concentrated on associations between retinal vascular caliber and the risk of DR and other chronic diabetes complications. Other studies have shown relationships between retinal vessel caliber and concurrent or subsequent diabetic nephropathy, or CVD or mortality^{11,35}. Even in individuals without diabetes, retinal vessel caliber has been associated with and/or predictive of future cardiovascular events and dementia^{36,37}.

Abnormalities of the retinal vasculature can often be subtle and might be missed by observation of retinal fundus images. Therefore, quantitative measurements by semi-automated software might be key to finding subtle changes in earlier stages of the disease. Qualitatively, narrower arteries and/or wider venules are a consistent finding for people at a higher risk of chronic vascular disease, such as DR and CVD (Figure S2). The use of semi-automated software to measure vessel caliber might enable granularity for clinical cut-off points for 'normal' and 'abnormal' measurements in specific populations, in turn helping flag systemic dysfunction and higher-risk individuals. However, much more work remains before retinal vascular geometry can be translated into clinical practice. To be clinically useful, retinal microvasculature signs must provide prognostic information for the prediction of different systemic diseases, beyond that of previously identified traditional risk factors.

The Wisconsin Epidemiologic Study of Diabetic Retinopathy (WESDR) reported larger arteriolar and venular diameters were associated with DR progression, but not with a 4-year incidence of DR in people with type 1 diabetes³⁸. Similarly, Roy *et al.*³⁹ found no associations with the incidence of DR, but a 6-year progression of PDR was associated with larger retinal venular diameters. In contrast, in 2008, Cheung *et al.*⁴⁰ and Rogers *et al.*⁴¹ reported that larger retinal arteriolar diameters were associated with the incidence of DR in type 1 diabetes patients aged 12–20 years and type 1 diabetes patients adults in the Australian Diabetes, Obesity and Lifestyle Study (AusDiab). In most of these earlier studies, computer-assisted methods or Retinal Analysis software was used to analyze the vessel caliber only. These methods require significant user input by graders, making grading time-consuming, and also introducing the issue of grader variability.

Semi-automated software for retinal caliber and geometry grading

As well as retinal caliber changes, a range of novel retinal vascular features related to geometry can also be measured, these include: fractal dimension, branching angles, tortuosity, bifurcation and vascular length-to-diameter ratio (Table S1). With the introduction and development of semi-automated vessel analysis software applications, namely the Interactive Vessel Analyzer (IVAN), Vessel Assessment and Measurement Platform for Images of the Retina (VAMPIRE), and Singapore "I" Vessel Assessment (SIVA), there has been a decrease in the amount of user input required for grading. The underlying mathematical methodology, discovery and validation datasets are variable, and few head-to-head studies compare the software. The variation between SIVA and VAMPIRE software measurements have been investigated using the Lothian Birth Cohort 1936. They reported poor agreement for all retinal parameters, suggesting caution when making conclusions regarding the similarity of associations between retinal measures from SIVA and VAMPIRE⁴².

The IVAN, VAMPIRE and SIVA software have been described in detail elsewhere^{43–45}. Figure 1e shows zone B and zone C, where vessel measurements are calculated. IVAN software only measures the CRAE, CRVE and arteriovenous ratio in zone B (0.5–1 disc diameter from the optic disc margin). VAMPIRE and SIVA compute additional measurements, such as tortuosity and branching angles, in zone C (1–2 disc diameters from the disc margin; Figure 1e).

Limitations of retinal vascular measurements

Limitations of the currently available retinal vessel analysis technologies prevent translation into clinical practice. Retinal caliber might vary up to 15% depending on the moment in the cardiac cycle the image is captured; therefore, a complete measurement of vessel caliber is not possible due to measurements being taken from a single retinal fundus image at an undefined time-point during the cardiac cycle⁴⁶. Retinal caliber is also thought to vary according to fundus pigmentation and systemic autonomic nerve stimulation⁴⁷. Furthermore, retinal measurements are taken on a single two-dimensional fundus image, which fails to take the three-dimensional geometry of the retinal vessels into account. As retinal vessel measurements are not a direct measurement of an anatomical feature and are based on an algorithm that differs between software applications, the parameters computed are an estimation.

There is a vast amount of data on retinal vascular measurements from numerous studies; however, there is a lack of normative data for retinal vessel caliber, which varies with ethnicity⁴⁸ and other confounders. As yet, there is no classification of normal and abnormal measures, which is crucial for retinal vascular measurements to become a clinical tool. An explanation for the lack of normative data in population-based studies is the difficulty in controlling for confounding effects of life course and systemic disease processes on retinal caliber, such as diabetes, smoking and hypertension. To derive normative data, a possible option is to examine retinal caliber in young children and adults who are more likely free of many confounding and age-related processes. Previous literature also compares retinal caliber between groups of individuals. To be useful as a risk tool in the clinical setting, an assessment of absolute risk in individuals is required. Yip *et al.*⁴⁹ developed an algorithm allowing conversions of caliber measurements from Retinal Analysis and IVAN software to SIVA approximates with only a small mean difference in absolute values; however, more studies with a larger sample of images are required to further validate the proposed algorithm. This proposed algorithm might play an important role in future studies for the establishment of normative values for caliber measurements⁴⁹. Unsurprisingly, accurate retinal vessel measurements will also rely on the quality of the fundus images captured. Many different factors will affect the reliability of retinal vessel measurements, these include the presence of media opacities and pathology, pupil size, variations in focus, brightness and contrast of fundus images,

refractive error, retinal image capture technique, camera type, and grader variability.

Associations between retinal vascular changes and systemic diseases

As summarized in Table 1, different studies of the same condition can report similar or divergent outcomes. This might relate to differences in participant age, sex, differences in end-point definitions, study design, including duration of follow up, and intra- and inter-differences in graders and software applications used. Table 1 shows studies that have used IVAN, SIVA or VAMPIRE to investigate the retinal vasculature in diabetes. We now summarize related knowledge in diabetes.

IVAN

Diabetes studies of retinal vessel geometry have concentrated on microvascular complications, particularly the associations with DR in people with type 1 diabetes and type 2 diabetes. Studies have also reported changes in retinal caliber after treatment for DME, and the association between retinal vessel caliber and the incidence and development of DR. In 2008, Wickremasin *et al.*⁵⁰ investigated changes in retinal vessel caliber in response to intravitreal triamcinolone in people with DME. They reported that intravitreal triamcinolone injection had a significant narrowing effect on both CRAE and CRVE diameters over a period of 3 months when compared with baseline measurements. Lundberg *et al.*⁵¹ reported similar findings, where there was a decrease in macular vessel diameter in response to focal/grid laser treatment for DME. For type 1 diabetes, the Danish Cohort Pediatric Diabetes investigated the predictive value of retinal vascular caliber on microvascular complications. They showed that wider venular caliber and narrower arteriolar caliber were associated with the 16-year incidence of diabetic complications, namely DPN, diabetic nephropathy and PDR⁸. In contrast, in the Multi-Ethnic Study of Atherosclerosis, which included 4,955 people with both type 1 diabetes and type 2 diabetes, those with wider retinal arterioles were more likely to develop incident diabetes than those with narrower arterioles (median follow-up period of 3 years)⁵². In type 2 diabetes, the Inter99 Study found that wider CRAE and CRVE were associated with the presence of DR, and female sex was associated with a wider CRVE⁵³.

SIVA

In addition to caliber measures, SIVA can determine non-caliber geometric measures of the retinal vasculature. The Sydney Pediatric Diabetes Study detailed geometric measures of retinal vessels in people with type 1 diabetes. After adjustment, they found larger arteriolar branching angles, and increasing deviation of optimality were associated with longer diabetes duration, and a higher glycated hemoglobin was associated with more tortuous vessels⁴⁴. In another study investigating the association of retinal vessel tortuosity with DR and early nephropathy, people with a higher retinal arteriolar tortuosity more likely to have

mild DR and early kidney dysfunction, independent of risk factors⁵⁴. A study with both type 1 diabetes and type 2 diabetes found an increase in arteriolar tortuosity was associated with mild and moderate NPDR⁵⁵. A study measuring length-to-diameter ratio and simple tortuosity in type 1 diabetes found lower arteriolar length-to-diameter ratio and greater simple tortuosity predicted incident DR over a median follow-up time of 3.8 years⁵⁶, with these findings confirmed in another study⁵⁷. In the same cohort of type 1 diabetes patients, longitudinal changes of retinal vessel geometry were examined, they found that retinal vessels dilated and became more tortuous over 2.6-year follow up⁵⁸. The Singapore Malay Eye Study found that wider CRAE was associated with the incidence of referable DR at 6 years, as were changes in other geometric parameters. Greater retinal arterial simple tortuosity was associated with a 6-year incident DR and 6-year progression of DR⁹. The WESDR study confirmed that greater arteriolar simple tortuosity was associated with the incidence of DR at 5 years⁵⁹. In contrast, a Chinese population of both type 1 diabetes and type 2 diabetes patients reported higher venular fractal dimensions and higher venular tortuosity was associated with DR incidence and DR progression, respectively, at 1-year⁶⁰. Ding *et al.*⁶¹ examined the association between early retinal arteriolar abnormalities and DPN, and found that patients with suboptimal arteriolar caliber and larger arteriolar branching coefficient, as well as DR and focal arteriolar narrowing, were more likely to have DPN than those without signs.

VAMPIRE

McKay *et al.*⁶² examined the prognostic potential of retinal vessel parameters to predict estimated glomerular filtration rate decline in type 2 diabetes patients. They found no association between baseline retinal vessel parameters and change in estimated glomerular filtration rate over approximately 3 years. To the authors' knowledge, this is the only study to utilize the VAMPIRE software to investigate diabetes to date.

Several other diabetes studies using IVAN and SIVA software have reported changes in the retinal caliber and geometry in related areas, including dietary intake, renal function, renal disease and gestational diabetes mellitus to name a few (Table 1)⁶²⁻⁶⁶.

LINKS BETWEEN OCULAR IMAGING AND OTHER DIABETES TECHNOLOGY

Advances in ocular-related technology that can benefit people with diabetes are complemented by patient-held technology of insulin pumps and continuous glucose monitors. In type 1 diabetes for the same level of HbA1c, the use of insulin pumps and/or continuous glucose monitors has already been associated with substantially lower rates of DR, other microvascular complications, CVD events, and mortality and severe hypoglycemia^{67,68}. Potential mechanisms might relate to the lower dose of insulin required when delivered by an insulin pump versus multiple daily injections and potentially less glucose

Table 1 | Review of studies using retinal vessel analysis techniques to examine retinal associations with diabetes

Author, study year & country	Study design and total sample size	outcomes measured	Retinal vessel measure (software used)	Summary of findings
Wickremasinghe <i>et al.</i> ⁵⁰ ; (2008, Australia)	Randomized clinical trial (<i>n</i> = 21 patients, 28 eyes (13 IVTA, 15 eyes sham))	Changes in retinal vascular caliber in response to an IVTA injection in patients with refractory DME at baseline and 3-month follow up	CRAE, CRVE (I)	Significant narrowing of retinal arteriolar and venular diameters in IVTA-treated eyes vs baseline
Sasongko <i>et al.</i> ⁴⁴ ; (2010, Australia)	Cross-sectional (<i>n</i> = 944)	Correlates of retinal geometric parameters in youth with T1D	Tortuosity, branching angles, optimality deviation, LDR (S)	Longer diabetes duration was associated with larger arteriolar branching angles and increasing deviation of optimality. Higher HbA1c was associated with more tortuous arterioles. Higher SBP was associated with decreased arteriolar LDR and higher total cholesterol was associated with increased arteriolar LDR and decreased venular optimality deviation.
Benitez-Aguirre <i>et al.</i> ⁵⁶ ; (2011, Australia)	Longitudinal prospective cohort study (<i>n</i> = 736)	Associations between retinal vascular geometry and incident retinopathy in T1D	CRAE, CRVE, LDR and simple tortuosity (S)	Lower arteriolar LDR and greater simple tortuosity predicted incident retinopathy (median 3.8 years)
Sasongko <i>et al.</i> ⁵⁵ ; (2011, Australia)	Cross-sectional clinic-based study (<i>n</i> = 327) (224 with diabetes and 103 non-diabetic controls)	Associations of retinal vessel tortuosity with diabetes and DR	CRAE, CRVE, tortuosity (S)	People with diabetes were more likely to have tortuous arterioles and venules than non-diabetic controls. Increased arteriolar tortuosity was associated with mild and moderate NPDR.
Yau <i>et al.</i> ⁵² ; (2012, US)	Population-based study (<i>n</i> = 4,955)	Association of retinal microvascular signs with incident diabetes and impaired fasting glucose	CRAE, CRVE (I)	Widening of retinal arterioles was associated with higher rate of incident diabetes vs narrower arterioles (median follow up 3 years)
Ding <i>et al.</i> ⁶¹ ; (2012, Singapore)	Cross-sectional study (<i>n</i> = 608)	Associations between early retinal arteriolar abnormalities and diabetic peripheral neuropathy	CRAE, CRVE, branching angle and coefficient (S)	Suboptimal arteriolar caliber and larger arteriolar branching coefficient, DR and focal arteriolar narrowing were more likely to have DPN
Sasongko <i>et al.</i> ⁵⁴ ; (2012, Australia)	Cross-sectional (<i>n</i> = 944)	Association of retinal vessel tortuosity with DR and early nephropathy in T1D	Retinal vessel tortuosity (S)	Higher retinal arteriolar tortuosity was associated with mild DR and early kidney dysfunction
Sasongko <i>et al.</i> ⁷¹ ; (2012, Australia)	Clinic-based, cross-sectional study (<i>n</i> = 224)	Associations of novel risk factors with DR in T1D and T2D	Retinal vessel tortuosity (S)	ApoA1 and retinal arteriolar tortuosity were associated with DR risk independently of traditional risk factors
Cheung <i>et al.</i> ⁷² ; (2012, Singapore)	Population-based study (<i>n</i> = 2,735) No diabetes = 2,141, with diabetes = 594	Association of retinal vascular parameters with diabetes and DR	Tortuosity, branching angle, FD, CRAE, CRVE (S)	Less tortuous arterioles and wider arteriolar and venular caliber in people with diabetes. People with retinopathy had wider venular caliber.

Table 1 (Continued)

Author, study year & country	Study design and total sample size	outcomes measured	Retinal vessel measure (software used)	Summary of findings
Benitez-Aguirre <i>et al.</i> ⁵⁷ ; (2012, Australia)	Prospective cohort study (<i>n</i> = 511)	Relationship between retinal vascular geometry and incident renal dysfunction in T1D	LDR, simple tortuosity, CRAE, CRVE and branching angle (S)	Lower arteriolar LDR and greater arteriolar tortuosity were associated with incident retinopathy (median 3.7 years)
Harrison <i>et al.</i> ⁷³ ; (2013, US)	Cross-sectional study (<i>n</i> = 65, T2D = 43, non-diabetic controls = 22)	Association of BP, retinal thickness and vessel caliber in T2D and high HbA1c, +/- mild or moderate NPDR	CRAE, CRVE (I)	Greater venule diameters in patients with and without NPDR vs non-diabetic individuals
Chew <i>et al.</i> ⁷⁴ ; (2013, Australia)	Hospital-based, cross-sectional study (<i>n</i> = 289)	Relationships of retinal vessel caliber with erectile dysfunction in men with T2D	CRAE, CRVE (I)	Narrower arteriolar diameter and wider venular diameter are independently associated with erectile dysfunction
Poon <i>et al.</i> ⁷⁵ ; (2013, Australia)	Cross-sectional study (<i>n</i> = 481)	Associations between Vitamin D levels, including deficiency and retinal geometric parameters in T1D	CRAE, CRVE, branching angle, LDR, tortuosity (S)	Vitamin D deficiency was not associated with changes in retinal vascular caliber, branching angle, LDR or tortuosity DR is associated with higher CRVE
Lundberg <i>et al.</i> ⁵¹ ; (2013, Denmark)	Retrospective study (<i>n</i> = 46, 72 eyes)	Compare retinal vessel caliber changes at the macula region and surrounding the optic disc after focal/grid laser treatment for macula oedema	CRAE, CRVE (I)	Macular vessel diameters decreased after focal/laser grid treatment in most eyes
Broe <i>et al.</i> ⁸ ; (2014, Denmark)	Prospective study (<i>n</i> = 185)	Predictive value of retinal vascular calibers for microvascular complications in T1D	CRAE, CRVE (I)	Wider venule and narrower arteriolar caliber were associated with 16-year incidence of DPN, DN and PDR
Benitez-Aguirre <i>et al.</i> ⁷⁶ ; (2015, Australia)	Prospective, longitudinal study (<i>n</i> = 64)	Are sex differences in retinal vascular geometry through puberty associated with earlier-onset microvascular complications in T1D	CRAE, CRVE, LDR, simple tortuosity, curvature tortuosity (S)	Female sex was associated with wider venular caliber, lower arteriolar LDR and earlier onset of retinopathy (median 7.2 years)
Drobnjak <i>et al.</i> ⁵³ ; (2017, Denmark)	Population-based study (<i>n</i> = 878, control = 679, diabetes/high risk IHD = 199)	Associations between retinal vessel diameters and retinopathy in people with and without T2D and known retinopathy risk factors.	CRAE, CRVE (I)	Association between wider CRAE and CRVE and presence of retinopathy in participants with diabetes
Liew <i>et al.</i> ⁷⁷ ; (2017, Australia)	Longitudinal Study (<i>n</i> = 102)	Longitudinal retinal vessel geometry in T1D	CRAE, CRVE, FD, tortuosity, LDR, branching coefficient and branching angle (S)	Retinal vessels dilated and become more tortuous (mean 2.6 years)
Lim <i>et al.</i> ⁶⁰ ; (2017, China)	Prospective cohort study (<i>n</i> = 249)	Associations between retinal vessel geometry and 1-year incidence and progression of DR (in T1D & T2D)	FD, tortuosity, branching angle & coefficient (S)	Higher venular FD were associated with DR incidence (1 year). Higher venular tortuosity associated with DR progression and lower arteriolar tortuosity associated with DR regression.
Velayutham <i>et al.</i> ⁷⁸ ; (2017, Australia)	Cross-sectional study (<i>n</i> = 736)	Association between retinal vascular geometry and development of incident retinopathy in T1D	CRAE, CRVE – central zone Mean width of arterioles and venules-extended zone (S)	Wider peripheral vessels associated with higher HbA1c and SBP. Wider peripheral arterioles were associated with longer diabetes duration. CRAE and CRVE were associated with longer diabetes duration and higher SBP.

Table 1 (Continued)

Author, study year & country	Study design and total sample size	outcomes measured	Retinal vessel measure (software used)	Summary of findings
Cheung <i>et al.</i> ⁹ ; (2017, Singapore)	Population-based study (n = 427)	Incidence and progression of DR in T2D over 6 years	FD, CRAE, CRVE, tortuosity, branching angle (S)	Retinal arterial tortuosity, larger venular branching coefficient was associated with 6-year incident DR. Greater arteriolar tortuosity, larger venular branching coefficient, higher arteriolar FD and larger arteriolar caliber were associated with referable DR. Greater arteriolar tortuosity was associated with 6-year DR progression
Li <i>et al.</i> ⁶⁶ ; (2017, Singapore)	Cross-sectional (n = 542)	Associations of retinal microvascular in women with gestational diabetes mellitus	CRAE, CRVE, branching angle, FD (S)	Narrower arteriolar caliber, reduced arteriolar FD, and larger arteriolar branching angle in women with gestational diabetes vs non-diabetic mothers
Klein <i>et al.</i> ⁷⁹ ; (2018, USA)	Observational, prospective cohort study (n = 996 T1D, n = 1,370 T2D)	Relationship of retinal vessel geometric characteristics to the incidence and progression of any DR at 5 years (T1D & T2D)	Tortuosity, branching angle, angle asymmetry, branching coefficient, asymmetry factor, junctional exponent, LDR, FD (S)	Arteriolar tortuosity associated with incidence of any DR. Venular branching angle associated with DR progression and incidence of CSME. Venular tortuosity associated with incidence of PDR (5-years).
McKay <i>et al.</i> ⁶² ; (2018, Scotland)	A nested longitudinal case-control study (n = 1,068, non-progressors n = 570, progressors n = 335)	Examine the prognostic potential of retinal vessel parameters for eGFR decline in people with T2D	CRAE, CRVE, AVR, No. of first vessel branches within zone C, FD and tortuosity (V)	No association between baseline retinal vessel parameters and change in eGFR over a period of ~3 years

ACR, albumin-to-creatinine ratio; ApoA1, Apo-lipoprotein A1; AVR, arteriovenous ratio; BP, blood pressure; CRAE, central retinal artery equivalent; CRVE, central retinal vein equivalent; CSME, clinically significant DME; DME, diabetic macular edema; DN, diabetic nephropathy; DPN, diabetic peripheral neuropathy; DR, diabetic retinopathy; eGFR, estimated glomerular filtration rate; FD, fractal dimension; HbA1c, glycated hemoglobin; IVTA, intravitreal triamcinolone acetonide; I, Interactive Vessel Analyzer; LDR, length-diameter ratio; NPDR, non-proliferative diabetic retinopathy; PDR, proliferative diabetic retinopathy; S, Singapore "I" Vessel Assessment; SBP, systolic blood pressure; T1D, type 1 diabetes; T2D, type 2 diabetes; V, Vessel Assessment and Measurement Platform for Images of the Retina.

variability with pump delivery⁶⁹, which might reduce inflammation, oxidative stress and epigenetic changes⁷⁰. As chronic complications take years, indeed often decades, to develop, some of these ocular imaging and grading techniques could be used as surrogate end-points in clinical trials and, if merited, in clinical practice.

CONCLUSIONS

Although diabetes incidence and prevalence are increasing globally, the adverse effects of diabetes and related chronic complications can be ameliorated by early detection and management. The evidence presented herein suggests that retinal imaging modalities already show diagnostic and prognostic value, and could become part of standard diabetes care. Furthermore, with

research into retinal vessel analysis showing some interesting findings at the population level, retinal vessel analysis might in time also become a useful tool in the early detection and clinical management of diabetes and its complications. These and other ocular imaging modalities, such as CCM and OCT, might provide useful surrogate end-points in clinical trials, as well as in clinical practice.

DISCLOSURE

The authors declare no conflict of interest.

REFERENCES

1. Saeedi P, Petersohn I, Salpea P, *et al.* Global and regional diabetes prevalence estimates for 2019 and projections for

- 2030 and 2045: Results from the International Diabetes Federation Diabetes Atlas, 9th edition. *Diabetes Res Clin Pract* 2019; 157: 107843.
- Sabanayagam C, Chee ML, Banu R, *et al.* Association of diabetic retinopathy and diabetic kidney disease with all-cause and cardiovascular mortality in a multiethnic Asian Population. *JAMA network open.* 2019; 2: e191540-e.
 - Barlovic DP, Harjutsalo V, Gordin D, *et al.* The association of severe diabetic retinopathy with cardiovascular outcomes in long-standing type 1 diabetes: a longitudinal follow-up. *Diabetes Care* 2018; 41: 2487–2494.
 - Nathan DM, Group DER. The diabetes control and complications trial/epidemiology of diabetes interventions and complications study at 30 years: overview. *Diabetes Care* 2014; 37: 9–16.
 - Keech AC, Mitchell P, Summanen P, *et al.* Effect of fenofibrate on the need for laser treatment for diabetic retinopathy (FIELD study): a randomised controlled trial. *Lancet.* 2007; 370: 1687–1697.
 - Group AS, Group AES. Effects of medical therapies on retinopathy progression in type 2 diabetes. *N Engl J Med* 2010; 363: 233–244.
 - Nielsen N, Jackson C, Spurling G, *et al.* Nondiabetic retinal pathology: prevalence in diabetic retinopathy screening. *Aust Fam Physician.* 2011; 40: 529.
 - Broe R, Rasmussen ML, Frydkjaer-Olsen U, *et al.* Retinal vessel calibers predict long-term microvascular complications in type 1 diabetes: the Danish Cohort of Pediatric Diabetes 1987 (DCPD1987). *Diabetes* 2014; 63: 3906–3914.
 - Cheung CY-I, Sabanayagam C, Law AK-p, *et al.* Retinal vascular geometry and 6 year incidence and progression of diabetic retinopathy. *Diabetologia* 2017; 60: 1770–1781.
 - Cheung C Y-I, Tay WT, Ikram MK, *et al.* Retinal microvascular changes and risk of stroke: the Singapore Malay Eye Study. *Stroke* 2013; 44: 2402–2408.
 - Kawasaki R, Cheung N, Wang JJ, *et al.* Retinal vessel diameters and risk of hypertension: the Multiethnic Study of Atherosclerosis. *J Hypertens.* 2009; 27: 2386.
 - Arnould L, Biquet C, Guenancia C, *et al.* Association between the retinal vascular network with Singapore" I" Vessel Assessment (SIVA) software, cardiovascular history and risk factors in the elderly: The Montrachet study, population-based study. *PLoS One* 2018; 13: e0194694.
 - Liao H, Zhu Z, Peng Y. Potential utility of retinal imaging for Alzheimer's disease: a review. *Front Aging Neurosci.* 2018; 10: 188.
 - Scanlon PH. Update on screening for sight-threatening diabetic retinopathy. *Ophthalmic Res.* 2019; 62: 213–219.
 - Lee R, Wong TY, Sabanayagam C. Epidemiology of diabetic retinopathy, diabetic macular edema and related vision loss. *Eye and vision.* 2015; 2: 17.
 - Tey KY, Teo K, Tan AC, *et al.* Optical coherence tomography angiography in diabetic retinopathy: a review of current applications. *Eye Vision* 2019; 6: 1–10.
 - Chiou AG, Kaufman SC, Beuerman RW, *et al.* Confocal microscopy in cornea guttata and Fuchs' endothelial dystrophy. *Br J Ophthalmol* 1999; 83: 185–189.
 - Chiou A-Y, Beuerman RW, Kaufman SC, *et al.* Confocal microscopy in lattice corneal dystrophy. *Graefes Arch Clin Exp Ophthalmol* 1999; 237: 697–701.
 - Ahmed A, Bril V, Orszag A, *et al.* Detection of diabetic sensorimotor polyneuropathy by corneal confocal microscopy in type 1 diabetes: a concurrent validity study. *Diabetes Care* 2012; 35: 821–828.
 - Tavakoli M, Quattrini C, Abbott C, *et al.* Corneal confocal microscopy: a novel noninvasive test to diagnose and stratify the severity of human diabetic neuropathy. *Diabetes Care* 2010; 33: 1792–1797.
 - Pritchard N, Edwards K, Russell AW, *et al.* Corneal confocal microscopy predicts 4-year incident peripheral neuropathy in type 1 diabetes. *Diabetes Care* 2015; 38: 671–675.
 - Papanas N, Ziegler D. Corneal confocal microscopy: recent progress in the evaluation of diabetic neuropathy. *J Diab Invest* 2015; 6: 381–389.
 - Leppin K, Behrendt A-K, Reichard M, *et al.* Diabetes mellitus leads to accumulation of dendritic cells and nerve fiber damage of the subbasal nerve plexus in the cornea. *Invest Ophthalmol Vis Sci* 2014; 55: 3603–3615.
 - Tavakoli M, Kallinikos P, Iqbal A, *et al.* Corneal confocal microscopy detects improvement in corneal nerve morphology with an improvement in risk factors for diabetic neuropathy. *Diabet Med.* 2011; 28: 1261–1267.
 - Fda U. FDA permits marketing of artificial intelligence-based device to detect certain diabetes-related eye problems. Silver Spring, DM, Department of Health and Human Services, 2018.
 - Rajalakshmi R, Subashini R, Anjana RM, *et al.* Automated diabetic retinopathy detection in smartphone-based fundus photography using artificial intelligence. *Eye* 2018; 32: 1138.
 - Bhaskaranand M, Ramachandra C, Bhat S, *et al.* Automated diabetic retinopathy screening and monitoring using retinal fundus image analysis. *J Diabetes Sci Technol* 2016; 10: 254–261.
 - Ting DSW, Cheung CY-L, Lim G, *et al.* Development and validation of a deep learning system for diabetic retinopathy and related eye diseases using retinal images from multiethnic populations with diabetes. *JAMA* 2017; 318: 2211–2223.
 - Li Z, Keel S, Liu C, *et al.* An automated grading system for detection of vision-threatening referable diabetic retinopathy on the basis of color fundus photographs. *Diabetes Care* 2018; 41: 2509–2516.
 - Ting DS, Cheung CY, Nguyen Q, *et al.* Deep learning in estimating prevalence and systemic risk factors for diabetic retinopathy: a multi-ethnic study. *npj Digital Medicine* 2019; 2: 24.

31. Arcadu F, Benmansour F, Maunz A, *et al.* Deep learning algorithm predicts diabetic retinopathy progression in individual patients. *NPJ Digital Med* 2019; 2: 1–9.
32. Sayres R, Taly A, Rahimy E, *et al.* Using a deep learning algorithm and integrated gradients explanation to assist grading for diabetic retinopathy. *Ophthalmology* 2019; 126: 552–564.
33. Brazionis L, Jenkins A, Keech A, *et al.* Diabetic retinopathy in a remote Indigenous primary healthcare population: a Central Australian diabetic retinopathy screening study in the Telehealth Eye and Associated Medical Services Network project. *Diabet Med* 2018; 35: 630–639.
34. Skovborg F, Nielsen AV, Lauritzen E, *et al.* Diameters of the retinal vessels in diabetic and normal subjects. *Diabetes* 1969; 18: 292–298.
35. Drobnjak D, Munch IC, Glümer C, *et al.* Retinal vessel diameters and their relationship with cardiovascular risk and all-cause mortality in the Inter99 Eye Study: a 15-year follow-up. *Journal of ophthalmology*. 2016; 2016: 1–8.
36. Yip W, Sabanayagam C, Ong PG, *et al.* Joint effect of early microvascular damage in the eye & kidney on risk of cardiovascular events. *Sci Rep* 2016; 6: 27442.
37. Frost S, Kanagasalingam Y, Sohrabi H, *et al.* Retinal vascular biomarkers for early detection and monitoring of Alzheimer's disease. *Transl Psychiat* 2013; 3: e233.
38. Klein R, Klein BE, Moss SE, *et al.* The relation of retinal vessel caliber to the incidence and progression of diabetic retinopathy: Xix: The wisconsin epidemiologic study of diabetic retinopathy. *Arch Ophthalmol* 2004; 122: 76–83.
39. Roy MS, Klein R, Janal MN. Retinal venular diameter as an early indicator of progression to proliferative diabetic retinopathy with and without high-risk characteristics in African Americans with type 1 diabetes mellitus. *Arch Ophthalmol* 2011; 129: 8–15.
40. Cheung N, Rogers SL, Donaghue KC, *et al.* Retinal arteriolar dilation predicts retinopathy in adolescents with type 1 diabetes. *Diabetes Care* 2008; 31: 1842–1846.
41. Rogers SL, Tikellis G, Cheung N, *et al.* Retinal arteriolar caliber predicts incident retinopathy: the Australian Diabetes, Obesity and Lifestyle (AusDiab) study. *Diabetes Care* 2008; 31: 761–763.
42. McGrory S, Taylor AM, Pellegrini E, *et al.* Towards standardization of quantitative retinal vascular parameters: comparison of SIVA and VAMPIRE measurements in the Lothian Birth Cohort 1936. *Trans Vis Sci Technol* 2018; 7: 12.
43. Perez-Rovira A, MacGillivray T, Trucco E, editors, *et al.* VAMPIRE: vessel assessment and measurement platform for images of the REtina. 2011 Annual International Conference of the IEEE Engineering in Medicine and Biology Society; 2011: IEEE.
44. Sasongko MB, Wang JJ, Donaghue KC, *et al.* Alterations in retinal microvascular geometry in young type 1 diabetes. *Diabetes Care* 2010; 33: 1331–1336.
45. Sun C, Liew G, Wang JJ, *et al.* Retinal vascular caliber, blood pressure, and cardiovascular risk factors in an Asian population: the Singapore Malay Eye Study. *Invest Ophthalmol Vis Sci* 2008; 49: 1784–1790.
46. Knudtson M, Klein B, Klein R, *et al.* Variation associated with measurement of retinal vessel diameters at different points in the pulse cycle. *Br J Ophthalmol*. 2004; 88: 57–61.
47. Patton N, Aslam T, MacGillivray T, *et al.* Retinal vascular image analysis as a potential screening tool for cerebrovascular disease: a rationale based on homology between cerebral and retinal microvasculatures. *J Anat*. 2005; 206: 319–348.
48. Nguyen TT, Wang JJ, Sharrett AR, *et al.* Relationship of retinal vascular caliber with diabetes and retinopathy: the Multi-Ethnic Study of Atherosclerosis (MESA). *Diabetes Care* 2008; 31: 544–549.
49. Yip W, Tham YC, Hsu W, *et al.* Comparison of common retinal vessel caliber measurement software and a conversion algorithm. *Trans Vis Sci Technol* 2016; 5: 11.
50. Wickremasinghe SS, Rogers SL, Gillies MC, *et al.* Retinal vascular caliber changes after intravitreal triamcinolone treatment for diabetic macular edema. *Invest Ophthalmol Vis Sci* 2008; 49: 4707–4711.
51. Lundberg K, Kawasaki R, Sjølie AK, *et al.* Localized changes in retinal vessel caliber after focal/grid laser treatment in patients with diabetic macular edema: a measure of treatment response? *Retina* 2013; 33: 2089–2095.
52. Yau JWY, Xie J, Lamoureux E, *et al.* Retinal microvascular calibre and risk of incident diabetes: the multi-ethnic study of atherosclerosis. *Diabetes Res Clin Pract*. 2012; 95: 265–274.
53. Drobnjak D, Munch IC, Glümer C, *et al.* Relationship between retinal vessel diameters and retinopathy in the Inter99 Eye Study. *Journal of clinical & translational endocrinology*. 2017; 8: 22–28.
54. Sasongko MB, Wong TY, Donaghue KC, *et al.* Retinal arteriolar tortuosity is associated with retinopathy and early kidney dysfunction in type 1 diabetes. *Am J Ophthalmol*. 2012; 153:176–183.e1.
55. Sasongko M, Wong T, Nguyen T, *et al.* Retinal vascular tortuosity in persons with diabetes and diabetic retinopathy. *Diabetologia* 2011; 54: 2409–16.
56. Benitez-Aguirre P, Craig ME, Sasongko MB, *et al.* Retinal vascular geometry predicts incident retinopathy in young people with type 1 diabetes: a prospective cohort study from adolescence. *Diabetes Care* 2011; 34: 1622–7.
57. Benitez-Aguirre PZ, Sasongko MB, Craig ME, *et al.* Retinal vascular geometry predicts incident renal dysfunction in young people with type 1 diabetes. *Diabetes Care* 2012; 35: 599–604.
58. Liew G, Benitez-Aguirre P, Craig ME, *et al.* Progressive retinal vasodilation in patients with type 1 diabetes: a longitudinal Study of Retinal Vascular Geometry. *Invest Ophthalmol Vis Sci*. 2017; 58: 2503–9.

59. Klein R, Lee KE, Danforth L, *et al.* The relationship of retinal vessel geometric characteristics to the incidence and progression of diabetic retinopathy. *Ophthalmology* 2018; 125: 1784–92.
60. Lim LS, Chee ML, Cheung CY, *et al.* Retinal vessel geometry and the incidence and progression of diabetic retinopathy. *Invest Ophthalmol Vis Sci* 2017; 58: BIO200–BIO5.
61. Ding J, Cheung CY, Ikram MK, *et al.* Early retinal arteriolar changes and peripheral neuropathy in diabetes. *Diabetes Care* 2012; 35: 1098–104.
62. McKay GJ, Paterson EN, Maxwell AP, *et al.* Retinal microvascular parameters are not associated with reduced renal function in a study of individuals with type 2 diabetes. *Sci Rep* 2018; 8: 3931.
63. Daien V, Kawasaki R, Villain M, *et al.* Retinal vascular caliber is associated with renal function in apparently healthy subjects. *Acta Ophthalmol (Copenh)* 2013; 91: e283–e8.
64. Yip W, Sabanayagam C, Teo BW, *et al.* Retinal microvascular abnormalities and risk of renal failure in Asian populations. *PLoS One* 2015; 10: e0118076.
65. Benitez-Aguirre PZ, Wong TY, Craig ME, *et al.* The Adolescent Cardio-Renal Intervention Trial (AdDIT): retinal vascular geometry and renal function in adolescents with type 1 diabetes. *Diabetologia* 2018; 61: 968–76.
66. Li L-J, Kramer M, Tapp RJ, *et al.* Gestational diabetes mellitus and retinal microvasculature. *BMC Ophthalmol.* 2017; 17: 4.
67. Steineck I, Cederholm J, Eliasson B, *et al.* Insulin pump therapy, multiple daily injections, and cardiovascular mortality in 18 168 people with type 1 diabetes: observational study. *BMJ* 2015; 350: h3234.
68. Zabeen B, Craig ME, Virk SA, *et al.* Insulin pump therapy is associated with lower rates of retinopathy and peripheral nerve abnormality. *PLoS One* 2016; 11.
69. Scott ES, McGrath RT, Januszewski AS, *et al.* HbA1c variability in adults with type 1 diabetes on continuous subcutaneous insulin infusion (CSII) therapy compared to multiple daily injection (MDI) treatment. *BMJ Open* 2019; 9.
70. Gorst C, Kwok CS, Aslam S, *et al.* Long-term glycemic variability and risk of adverse outcomes: a systematic review and meta-analysis. *Diabetes Care* 2015; 38: 2354–2369.
71. Sasongko M, Wong T, Nguyen T, *et al.* Novel versus traditional risk markers for diabetic retinopathy. *Diabetologia* 2012; 55: 666–670.
72. Cheung CY-I, Lamoureux E, Ikram MK, *et al.* Retinal vascular geometry in Asian persons with diabetes and retinopathy. *J Diabetes Sci Technol.* 2012; 6(3): 595–605.
73. Harrison WW, Chang A, Cardenas M, *et al.* Blood pressure, vessel caliber, and retinal thickness in diabetes. *Optometry Vis Sci* 2012; 89(12): 1715.
74. Chew SK, Taouk Y, Xie J, *et al.* The relationship of retinal vessel caliber with erectile dysfunction in patients with type 2 diabetes. *Invest Ophthalmol Vis Sci* 2013; 54: 7234–7239.
75. Poon M, Craig ME, Kaur H, *et al.* Vitamin D deficiency is not associated with changes in retinal geometric parameters in young people with type 1 diabetes. *J Diab Res* 2013; 2013: 1–5.
76. Benitez-Aguirre P, Craig ME, Cass HG, *et al.* Sex differences in retinal microvasculature through puberty in type 1 diabetes: are girls at greater risk of diabetic microvascular complications? *Invest Ophthalmol Vis Sci* 2015; 56: 571–577.
77. Liew G, Benitez-Aguirre P, Craig ME, *et al.* Progressive retinal vasodilation in patients with type 1 diabetes: a longitudinal study of Retinal Vascular Geometry. *Invest Ophthalmol Vis Sci* 2017; 58: 2503–2509.
78. Velayutham V, Benitez-Aguirre PZ, Craig ME, *et al.* Innovative technology shows impact of glycaemic control on peripheral retinal vessels in adolescents with type 1 diabetes. *Diabetologia* 2017; 60(10): 2103–2110.
79. Klein R, Lee KE, Danforth L, *et al.* The Relationship of Retinal Vessel Geometric Characteristics to the Incidence and Progression of Diabetic Retinopathy. *Ophthalmology* 2018; 125: 1784–1792.

SUPPORTING INFORMATION

Additional supporting information may be found online in the Supporting Information section at the end of the article.

Figure S1 | The different severity stages of diabetic retinopathy and also diabetic retinopathy-related pathology found on the retinal fundus.

Figure S2 | Left eye images of the retinal fundus with retinal vessel analysis produced by the Singapore “I” Vessel Assessment software, where vessels are traced in a specified area (zone B, defined as the region from 0.5 to 1 disc diameter from the optic disc margin, and zone C, defined as the region 1–2 disc diameters from the optic disc margin).

Table S1 | Retinal vasculature parameters measured by semi-automated software.