

First-in-child use of the oral soluble guanylate cyclase stimulator riociguat in pulmonary arterial hypertension

Till Spreemann¹, Harald Bertram¹, Christoph M. Happel¹, Rainer Kozlik-Feldmann² and Georg Hansmann¹

¹Department of Pediatric Cardiology and Critical Care, Hannover Medical School, Hannover, Germany; ²Department of Pediatric Cardiology, University of Hamburg, Hamburg, Germany

Abstract

Riociguat has been approved for use in adults with pulmonary arterial hypertension (PAH) or chronic thromboembolic pulmonary hypertension. No clinical data on its therapeutic use in children with PAH are currently available. We report the case of a now four-year-old boy who initially presented at the age of 10 months with suprasystemic pulmonary hypertension (PH) and right ventricular (RV) failure, vomiting, peripheral cyanosis, and failure to thrive. Cardiac catheterization revealed severe PAH. At radiologic suspicion of interstitial lung disease, repeated CT scan and an open lung biopsy were performed but could not clarify the entity of PAH. Given the demonstrated vasoreactivity, the boy was started on the calcium channel blocker amlodipine, in combination with the endothelin-1 receptor antagonist bosentan. Two years later, based on persistently systemic PAH with lost vasoreactivity, PAH therapy was changed to bosentan and phosphodiesterase-5 inhibitor sildenafil. No significant improvement on the aforementioned therapy was seen, so that the patient was referred to our institution. Invasive hemodynamic evaluation showed suprasystemic PAH and marked acute vasoreactivity (PAP 127/103/83 mmHg, PVRi 23.48 WU·m² and PVR/SVR ratio 1.59 at baseline vs. PVRi 5.89 WU·m² and PVR/SVR ratio 0.93 under O₂/NO). Subsequently, we switched the patient from sildenafil to riociguat. After six months on bosentan/riociguat, the patient showed a marked decrease in PVR/SVR and transpulmonary pressure gradients, in RV hypertrophy, PA acceleration time, and left ventricular-eccentricity index. Clinically, the patient improved in pediatric functional class from 2/3 to I. In conclusion, off-label use of oral riociguat may be considered in selected children with severe PAH.

Keywords

pulmonary hypertension, right heart failure, children, riociguat

Date received: 2 October 2017; accepted: 28 October 2017

Pulmonary Circulation 2017; 8(3) 1–6

DOI: 10.1177/2045893217743123

Although pharmacotherapy of pulmonary arterial hypertension (PAH) underwent major developments in the last decade, PAH remains a complex disease with poor prognosis in children and adults.^{1–3} The pathophysiology of PAH and pulmonary vascular disease (PVD) includes early endothelial damage, excessive production and signaling of proliferative growth factors,⁴ pro-inflammatory molecules,⁵ and vasoconstrictors (endothelin-1, thromboxane),⁶ whereas circulating and intracellular levels of endogenous vasodilators, such as prostacyclin (PGI₂)⁷ and nitric oxide (NO), frequently decline. The resulting disbalance of detrimental

and beneficial signaling molecules drives obliterative pulmonary vascular remodeling, right ventricular (RV) pressure overload, heart failure, and ultimately death. Current PAH-targeted pharmacotherapy aims at three major pathways:⁶ endothelin-1, NO, and PGI₂; while novel drugs under investigation primarily aim to tackle inflammation and

Corresponding author:

Georg Hansmann, Department of Pediatric Cardiology and Critical Care, Hannover Medical School, Carl-Neuberg-Str. 1, D-30625 Hannover, Germany. Email: georg.hansmann@gmail.com



Creative Commons Non Commercial CC-BY-NC: This article is distributed under the terms of the Creative Commons Attribution-NonCommercial 4.0 License (<http://www.creativecommons.org/licenses/by-nc/4.0/>)

which permits non-commercial use, reproduction and distribution of the work without further permission provided the original work is attributed as specified on the SAGE and Open Access pages (<https://us.sagepub.com/en-us/nam/open-access-at-sage>).

© The Author(s) 2017.

Reprints and permissions:
sagepub.co.uk/journalsPermissions.nav
journals.sagepub.com/home/pul



proliferation.^{2,5,8} Riociguat is an oral soluble guanylate cyclase (sGC) stimulator that is approved for the treatment for PAH⁹ and chronic thromboembolic PH (CTEPH)¹⁰ in adults. Riociguat has a dual mode of action: while acting in synergy with endogenous NO by sensitizing sGC, the drug directly stimulates sGC independently of NO, hence increasing the generation of cyclic guanosine monophosphate (cGMP).¹¹ Soluble GC is expressed in vascular smooth muscle cells of pulmonary vessels, platelets, cardiomyocytes, and other cell types. When bound to NO, sGC catalyzes the conversion of guanosine triphosphate (GTP) to cGMP, thus promoting vasodilation, and inhibiting all, smooth muscle proliferation, leucocyte recruitment, inflammation, fibrosis, platelet aggregation, and probably pulmonary vascular remodeling. In the double-blinded phase 3 PATENT trial, riociguat—at individually adjusted dose up to 2.5 mg three times daily—was demonstrated to significantly improve exercise capacity, pulmonary vascular resistance (PVR; $P < 0.001$), serum NT-proBNP concentrations ($P < 0.001$), WHO functional class ($P = 0.003$), time to clinical worsening ($P = 0.005$), and Borg dyspnea score ($P = 0.002$) vs. placebo in adults with PAH (PATENT-1, $n = 443$ ⁹ and PATENT-2, $n = 396$ ¹²). Therefore, riociguat appears to be a promising oral PAH-targeted medication that targets the NO-sGC-cGMP pathway. However, no clinical data on the use of riociguat and its titration, adverse effects, and efficiency in children with PAH are currently available.

Here, we report on a caucasian boy who presented at the age of ten months with vomiting, failure to thrive, and peripheral cyanosis. He underwent a first catheter with acute vasoreactivity testing in an outside hospital in March 2014, when he was diagnosed with severe pulmonary hypertension (PH) in the absence of any congenital heart disease. At the radiological suspicion of interstitial lung disease, three chest computed tomography (CT) scans were performed (April 2014, July 2014, and August 2015), but neither the imaging studies nor a bronchoscopy with bronchoalveolar lavage in May 2014 or an open lung biopsy in August 2015 could clarify whether the PH should be assigned as group 3 (PH with associated lung disease) or idiopathic PAH (IPAH): histopathologic work-up showed residuals of pulmonary hemorrhage, dystelectasis, megakaryocyte embolisms, and broadened alveolar walls, but regular and non-thrombotic veins. Cardiac catheterization performed in March 2014, September 2014, and February 2016 revealed severe PAH (March 2014: systolic pulmonary arterial pressure [sPAP] = 94 mmHg, mean PAP [mPAP] = 64 mmHg, diastolic PAP [dPAP] = 41 mmHg, mean aorta ascendens pressure = 62 mmHg, PVR index [PVRi] = 19.4 WU·m²).

Given the demonstrated acute vasoreactivity in the first invasive hemodynamic measurements (March 2014), the boy was then, at the age of ten months, started on combination therapy with the endothelin-1 receptor antagonist (ERA) bosentan and the calcium channel blocker (CCB)

amlodipine. The second cardiac catheterization six months later still showed severe PAH and sustained vasoreactivity, so that the dosages of bosentan and amlodipine were adjusted and continued until the third catheterization in February 2016, when hemodynamic testing showed persistent systemic PAH (sPAP = 62 mmHg, mPAP = 45 mmHg, dPAP = 29 mmHg, aortic pressure 65/34/46 mmHg) whereas pulmonary vasoreactivity on oxygen and inhaled nitric oxide (iNO) seemed to have subsided (PVR = 12.32 WU·m² at ambient air vs. 11.94 WU·m² under 40 ppm iNO; PVR/systemic vascular resistance [SVR] = 0.92 at ambient air vs. 1.12 under 40 ppm iNO). As a consequence, amlodipine was stopped and the PDE5-inhibitor sildenafil and oral prednisolone were started.

The patient was then referred to our institution and first presented at our PAH center in August 2016 at the age of 3.5 years in a clinically stable condition (weight = 12.5 kg, 3rd percentile; height = 95 cm, 25th percentile; BMI = 13.85 kg/m²; pediatric functional PH class 2/3).¹³ A genetic panel screen was negative for ten PAH genes (ACVRL1, BMPR1B, BMPR2, CAV1, EIF2AK4, ENG, KCNK3, NOTCH3, SMAD9, TBX4). A repeat chest CT did not confirm any significant parenchymal lung disease, so that we re-classified the patient to have IPAH. The patient was then taken to our catheterization laboratory for comprehensive invasive hemodynamic evaluation under sedation (spontaneous breathing), including acute vasoreactivity testing with inhaled NO and oxygen.¹⁴ This cardiac catheterization (no. 4, on sildenafil and bosentan) revealed suprasystemic PAH, high PVR/SVR ratio, and normal cardiac index (CI) (mean right arterial pressure = 3 mmHg, RV end diastolic pressure = 6 mmHg, mean left arterial pressure = 9 mmHg, PAP = 127/103/83 mmHg, PVRi = 23.48 WU·m², PVR/SVR ratio = 1.59, CI = 4.07 L/min/m²). The patient showed pronounced vasoreactivity on the application of 40 ppm NO + 100% O₂ (PVRi = 5.89 WU·m², PVR/SVR ratio = 0.93) (Figs. 1 and 2), when mPAP dropped quickly from 1.5-fold systemic to less than half systemic (Fig. 1).

We concluded that our patient had had an inadequate response to therapy with PDE5i + ERA. Although his plasma L-arginine concentration at the time was normal (81 μmol/L, standard range = 36–139 μmol/L), we speculated he could have low endogenous NO stores, and thus insufficient synthesis of cGMP, and may therefore respond hemodynamically and clinically to a direct sGC stimulator. Hence, we decided to switch our patient from sildenafil to riociguat, keeping the patient hospitalized right after cardiac catheterization, while slowly titrating the initial riociguat dose of 3 × 0.1 mg to 3 × 0.5 mg daily within five days, and then discharged him home. Although in the adult RESPITE trial a 24-h sildenafil-free interval was intercalated before starting patients on riociguat,¹⁵ we overlapped the sildenafil and riociguat on the first day by halving the sildenafil dose from 3 × 10 mg to 3 × 5 mg, starting that same day with 2 × 0.1 mg riociguat, administered at different times than

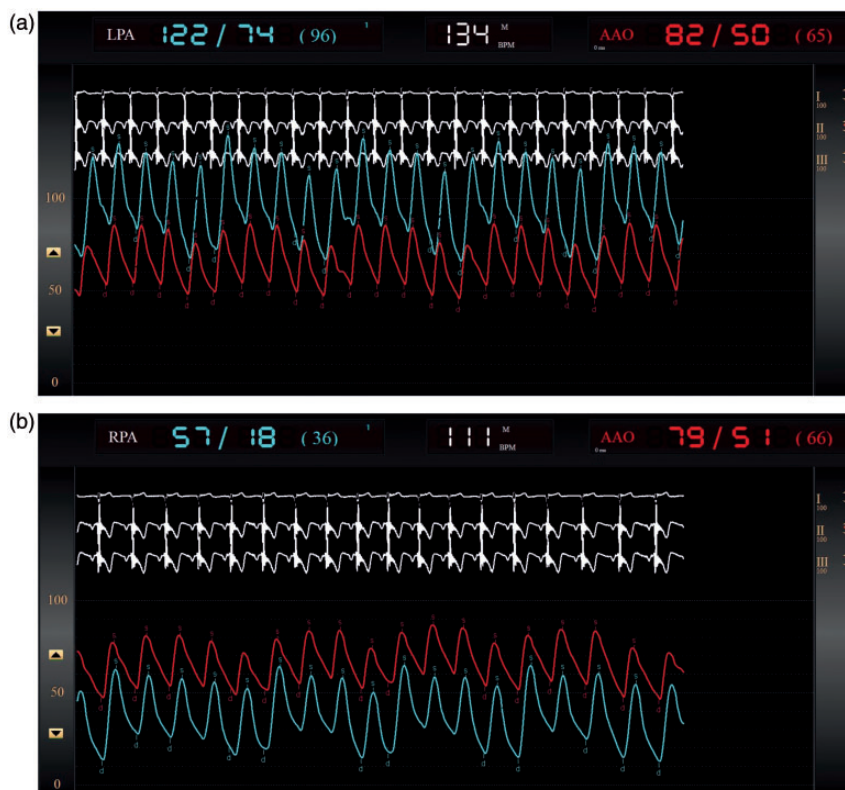

Fig. 1. Original recordings of the pulmonary artery pressure (blue) and ascending aorta pressure (red line) at baseline (a) and after starting iNO 40 ppm in combination with 100% oxygen via face mask (b). Note that a proximal stenosis or gradient between left pulmonary artery (LPA) and RPA have been excluded preliminarily, as during the second measurement the tip of the catheter has moved from right to left pulmonary artery.

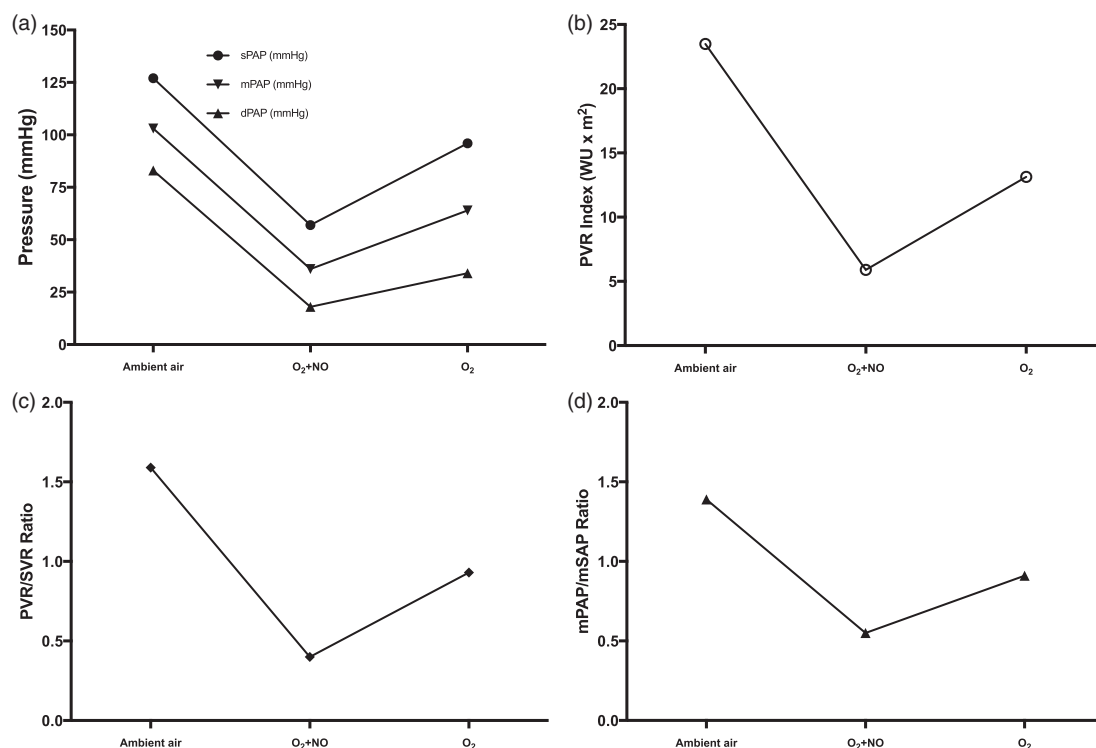


Fig. 2. Acute vasoreactivity testing at the cardiac catheterization, before switching from sildenafil to riociguat. Following our protocol, we applied oxygen (FiO₂ 1.0) and NO (40 ppm) simultaneously, resulting in a marked decrease of sPAP, mPAP, dPAP (a), PVRi (b), and PVR/SVR ratio (c), and the ratio of mPAP to mean aortic pressure (d). When stopping the insufflation of NO, the effects were greatly reversed despite the presence of oxygen.

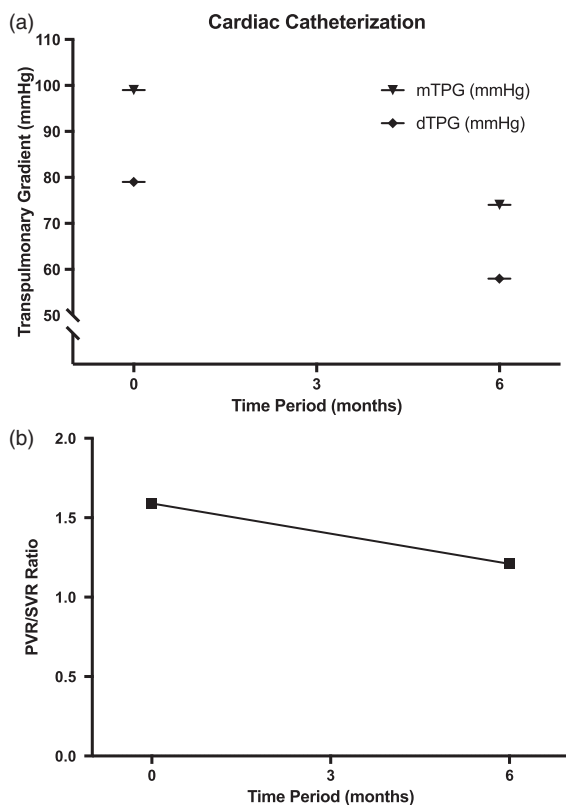


Fig. 3. Hemodynamic improvement during the first six months after reaching the target dose of riociguat, after switching from sildenafil to riociguat at timepoint 0, and concomitant therapy with bosentan. Mean and diastolic transpulmonary pressure gradient (mTPG and dTPG) decreased considerably (a) and PVR/SVR ratio (b).

sildenafil to prevent systemic hypotension. No adverse effect or event during the outpatient follow-up was observed, so that we increased the riociguat dose to 3×1 mg daily 2.5 months later (body weight was then 17.3 kg). After six months on this combination therapy (bosentan plus riociguat), the patient underwent repeat cardiac catheterization (no. 5) and an echocardiogram. We found a decrease in the mean and diastolic transpulmonary pressure gradient (TPG), and PVR/SVR ratio (from 1.59 to 1.21) (Fig. 3), sustained vasoreactivity, a reduction in RV wall thickness (RVAWd went from 9.0 to 6.3 mm), a lower left ventricular (LV)-eccentricity index (1.83 vs. 2.07, i.e. less LV compression and underfilling), and a concomitant increase in the pulmonary artery acceleration time (PAAT; 85 vs. 63 ms) (Fig. 4). To reduce inter-operator variance in the echocardiographic measurements, pre-defined landmarks were used (RVAWd: M-mode in strict on axis parasternal short axis view, mid-distance between the two papillary muscles; PAAT: PW-Doppler in parasternal short axis view, with probe immediately proximal to the pulmonary valve).

The serum N-terminal pro B-type natriuretic peptide (NT-proBNP) concentration was only 128 ng/L at presentation in our center (on sildenafil + bosentan), which is not unusual for young children with suprasystemic PAH but

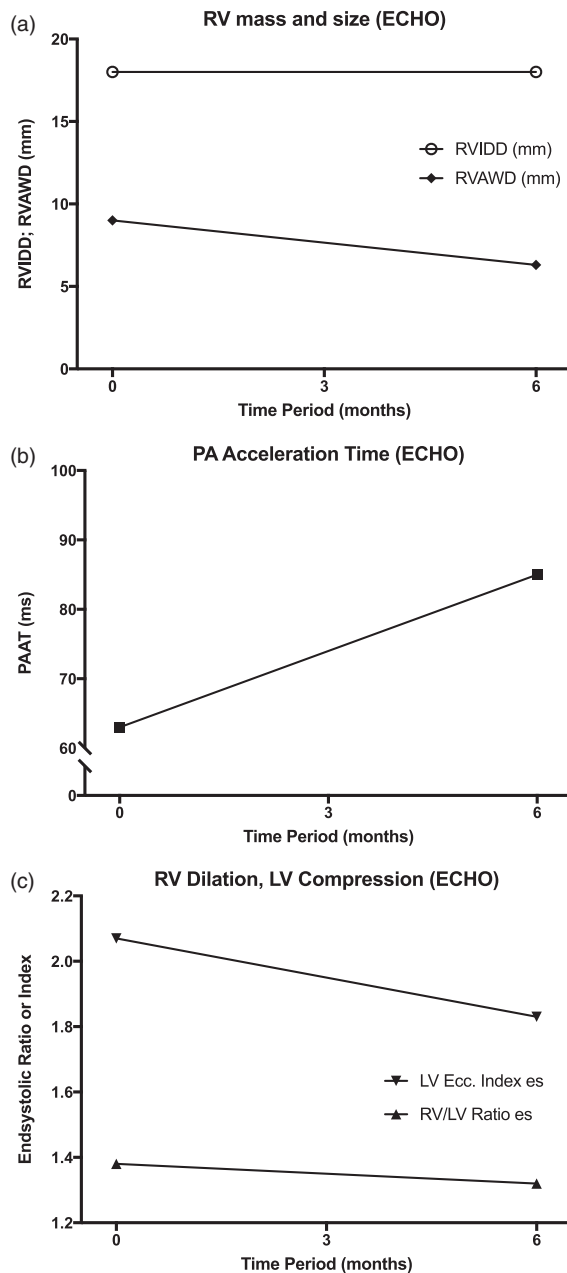


Fig. 4. Hemodynamic and morphological improvement in a four-year-old boy with severe PAH during the first six months after reaching the target dose of riociguat, after switching from sildenafil to riociguat at timepoint 0, and concomitant therapy with bosentan. While RV diameter remained constant, end-diastolic RVAWd decreased (a). PA acceleration time increased (b) while RV/LV ratio as well as LV-eccentricity index in endsystole—as a surrogate for LV compression and underfilling in severe PAH—decreased over the six-month period (c).

qualitatively normal systolic RV function (TAPSE = 1.82 cm, normal range for age = 1.48–2.02 cm¹⁶), and 114 ng/L after six months of riociguat + bosentan (NT-proBNP = –10%; TAPSE = 1.82 cm; normal range = 1.56–2.02¹⁶). Clinically, the patient's mother reported an enhanced daytime activity level, better night sleep, and less

pronounced, palpable RV anterior heave. With riociguat, his pediatric functional class¹³ improved from 2/3 (i.e. marked limitation of physical activity; unduly fatigued/less than ordinary activity causes undue fatigue; quiet and needs frequent naps; poor appetite) to class 1.

To the best of our knowledge, this is the first report on the use of oral riociguat for the treatment of severe PAH in childhood. No adverse effect or event (e.g. systemic hypotension, syncope, nausea/vomiting, hemoptysis¹²) was observed in the titration period and during short-term follow-up on the current dose (currently eight months after start of therapy and five months on the current dosing of riociguat 3 × 1 mg, orally). Repeat cardiac catheterization and echocardiograms revealed promising effects on several hemodynamic and anatomic variables, such as sustained vasoreactivity, decreased PVR/SVR ratio, and reduced RV hypertrophy (RVAWd 9 vs. 6.3 mm, see above); the aforementioned hemodynamic variables have been shown to be associated with better clinical outcome, including survival.

In contrast to PDE5i, sGC stimulators such as riociguat circumvent the need for endogenous NO production for their mode of action, by increasing cGMP levels through a mechanism that is different from that of PDE5i such as sildenafil.¹¹ Our rationale to switch the presented child with suprasystemic PAH and high PVR/SVR from sildenafil to riociguat was based on: (1) the impressive hemodynamic response to iNO+O₂ (vs. O₂ alone) during cardiac catheterization (for PAP reduction, see Fig. 1); and (2) the preceding insufficient response to the combination of ERA and sildenafil despite normal plasma L-arginine concentration.

Our approach is supported by the recently published RESPITE study, i.e. a 24-week, open-label, multicenter, uncontrolled 3b study (NCT02007629) on the switch from sildenafil to riociguat, which was completed by 51 adult PAH patients (50/51 on concomitant ERA).¹⁵ At week 24, mean ± SD 6MWD had increased by 31 ± 63 m, NT-proBNP decreased by 347 ± 1235 pg·mL⁻¹ and WHO functional class improved in 28 patients (54%). Thirty-two patients (52%) experienced study drug-related adverse events and ten (16%) experienced serious adverse events (two [3%] were study drug-related, none during the PDE5i treatment-free period). Six patients (10%) experienced clinical worsening, including death in two (not study drug-related).

A recent Cochrane analysis on sGC stimulators for PH concluded that there was no evidence supporting their use in children; however, this statement resulted from the lack of any clinical data in patients aged less than 18 years.¹⁷ Of note, riociguat must not be used together with PDEi such as sildenafil or tadalafil because severe systemic arterial hypotension may occur.^{3,18} In addition, riociguat is not recommended in severe hepatic or renal impairment.^{19,20}

Based on our very recent, still limited experience, we propose that off-label use of oral riociguat, when carefully dosed, may be considered in selected children with severe

PAH after comprehensive, hemodynamic evaluation in the catheterization laboratory. Riociguat can be of advantage especially when a patient with symptomatic PAH has been not responsive to oral sildenafil (+/- ERA) and thus does not meet treatment goals.^{1,3} However, such a strategy needs to be further studied in larger case series and—even more preferable—in a protocol-driven prospective pediatric PAH study in the future.

Conflict of Interest

TS, CMH, HB, RKF and GH indicate no conflict of interest related to the content of this article. GH is the current chair of the AEPC Working Group “Pulmonary Hypertension and Heart Failure” and the founding chair of the not-for-profit European Pediatric Pulmonary Vascular Disease Network (<http://www.pvdnetwork.org>). GH’s role as chair is just information but no conflict. This paper resulted from a collaboration of two centers which are members of the European Pediatric Pulmonary Vascular Disease Network.

Funding

GH currently receives grant support from the German Research Foundation (DFG; HA 4348/2-1, 4348/6-1) and Kinderherzen e.V. (W-H-001-2014).

References

- Hansmann G, Apitz C, Abdul-Khaliq H, et al. Executive summary. Expert consensus statement on the diagnosis and treatment of paediatric pulmonary hypertension. The European Paediatric Pulmonary Vascular Disease Network, endorsed by ISHLT and DGPK. *Heart* 2016; 102(Suppl 2): ii86–ii100.
- Hansmann G. Pulmonary hypertension in infants, children, and young adults. *J Am Coll Cardiol* 2017; 69(20): 2551–2569.
- Galie N, Humbert M, Vachiery JL, et al. 2015 ESC/ERS Guidelines for the diagnosis and treatment of pulmonary hypertension: The Joint Task Force for the Diagnosis and Treatment of Pulmonary Hypertension of the European Society of Cardiology (ESC) and the European Respiratory Society (ERS): Endorsed by: Association for European Paediatric and Congenital Cardiology (AEPC), International Society for Heart and Lung Transplantation (ISHLT). *Eur Heart J* 2016; 37(1): 67–119.
- Calvier L, Chouvarine P, Legchenko E, et al. PPARgamma links BMP2 and TGFbeta1 pathways in vascular smooth muscle cells, regulating cell proliferation and glucose metabolism. *Cell Metab* 2017; 25(5): 1118–1134 e7.
- Rabinovitch M, Guignabert C, Humbert M, et al. Inflammation and immunity in the pathogenesis of pulmonary arterial hypertension. *Circ Res* 2014; 115(1): 165–175.
- Humbert M and Ghofrani HA. The molecular targets of approved treatments for pulmonary arterial hypertension. *Thorax* 2016; 71(1): 73–83.
- Clapp LH and Gurung R. The mechanistic basis of prostacyclin and its stable analogues in pulmonary arterial hypertension: Role of membrane versus nuclear receptors. *Prostaglandins Other Lipid Mediat* 2015; 120: 56–71.
- Hansmann G and Apitz C. Treatment of children with pulmonary hypertension. Expert consensus statement on the diagnosis and treatment of paediatric pulmonary hypertension. The

- European Paediatric Pulmonary Vascular Disease Network, endorsed by ISHLT and DGPK. *Heart* 2016; 102(Suppl 2): ii67–ii85.
- Ghofrani HA, Galie N, Grimminger F, et al. Riociguat for the treatment of pulmonary arterial hypertension. *New Engl J Med* 2013; 369(4): 330–340.
 - Ghofrani HA, D'Armini AM, Grimminger F, et al. Riociguat for the treatment of chronic thromboembolic pulmonary hypertension. *New Engl J Med* 2013; 369(4): 319–329.
 - Ghofrani HA, Humbert M, Langleben D, et al. Riociguat: mode of action and clinical development in pulmonary hypertension. *Chest* 2017; 151(2): 468–480.
 - Ghofrani HA, Grimminger F, Grunig E, et al. Predictors of long-term outcomes in patients treated with riociguat for pulmonary arterial hypertension: data from the PATENT-2 open-label, randomised, long-term extension trial. *Lancet Respir Med* 2016; 4(5): 361–371.
 - Lammers AE, Apitz C, Zartner P, et al. Diagnostics, monitoring and outpatient care in children with suspected pulmonary hypertension/paediatric pulmonary hypertensive vascular disease. Expert consensus statement on the diagnosis and treatment of paediatric pulmonary hypertension. The European Paediatric Pulmonary Vascular Disease Network, endorsed by ISHLT and DGPK. *Heart* 2016; 102(Suppl 2): ii1–ii13.
 - Apitz C, Hansmann G and Schranz D. Hemodynamic assessment and acute pulmonary vasoreactivity testing in the evaluation of children with pulmonary vascular disease. Expert consensus statement on the diagnosis and treatment of paediatric pulmonary hypertension. The European Paediatric Pulmonary Vascular Disease Network, endorsed by ISHLT and DGPK. *Heart* 2016; 102(Suppl 2): ii23–ii29.
 - Hoeper MM, Simonneau G, Corris PA, et al. RESPITE: switching to riociguat in pulmonary arterial hypertension patients with inadequate response to phosphodiesterase-5 inhibitors. *Eur Respir J* 2017; 50(3): 1602425.
 - Koestenberger M, Ravekes W, Everett AD, et al. Right ventricular function in infants, children and adolescents: reference values of the tricuspid annular plane systolic excursion (TAPSE) in 640 healthy patients and calculation of z score values. *J Am Soc Echocardiogr* 2009; 22(6): 715–719.
 - Wardle AJ, Seager MJ, Wardle R, et al. Guanylate cyclase stimulators for pulmonary hypertension. *Cochrane Database Syst Rev* 2016; (8): CD011205.
 - Galie N, Muller K, Scalise AV, et al. PATENT PLUS: a blinded, randomised and extension study of riociguat plus sildenafil in pulmonary arterial hypertension. *Eur Respir J* 2015; 45(5): 1314–1322.
 - Saleh S, Becker C, Frey R, et al. Population pharmacokinetics of single-dose riociguat in patients with renal or hepatic impairment. *Pulm Circ* 2016; 6(Suppl. 1): S75–85.
 - Frey R, Becker C, Unger S, et al. Assessment of the effects of hepatic impairment and smoking on the pharmacokinetics of a single oral dose of the soluble guanylate cyclase stimulator riociguat (BAY 63-2521). *Pulm Circ* 2016; 6(Suppl. 1): S5–S14.