

Metastatic Crohn's Disease of the Vulva: A Rare Presentation

Abstract

Crohn's disease, a chronic inflammatory granulomatous disease of gastrointestinal tract, may rarely have extra intestinal manifestations. Vulvar Crohn's disease may be contiguous or noncontiguous with the gastrointestinal tract. It can cause significant symptoms and has a major impact on quality of life.

Keywords: Crohn's, gastrointestinal, vulvar

Introduction

Vulvar involvement in Crohn's disease is extremely rare. Involvement of vulva in the absence of gastrointestinal symptoms and signs presents as a diagnostic challenge, leading to patients suffering for years before being correctly diagnosed and treated. We, hereby, report a case of vulvar Crohn's disease which presented with vulvar exophytic outgrowths and discharging sinuses.

Case Report

A 23-year-old female presented with a 3-year history of vulvar edema, pain, ulcerations, and foul-smelling discharge. History of perianal discharging sinuses was also present. Patient had loss of weight and appetite, and intermittent abdominal pain for 3 years. There was no history of oral ulcers, blood in stools, or alteration of bowel habits. She had developed pustular lesions and ulcers in both axillae 4 years back, for which she had been prescribed anti-tuberculous treatment (ATT) for 6 months elsewhere. She improved but lesions appeared in the pubic area upon completion of ATT.

On examination, there was vulvar edema, hyperpigmentation, and thickening along with multiple sinuses discharging pus, linear knife-cut erosions on inguinal folds, and irregular exophytic hypertrophic outgrowths over vulva. The external genitalia was thus disfigured [Figure 1]. Perianal area revealed few pus discharging sinuses and

scars [Figure 2]. There was no inguinal lymphadenopathy. Scarring was observed in bilateral axillae [Figure 3]. Based on the history and examination a differential diagnosis of cutaneous tuberculosis and hidradenitis suppurativa was kept.

Investigations revealed hemoglobin 8.6 g/dl, total leukocyte count $14.3 \times 10^3/L$, differential leukocyte count (neutrophils 74%, lymphocytes 16%, monocytes 6%, eosinophils 2%, basophils 0.5%), platelets $665 \times 10^3/L$, ESR 102 mm/hour (normal 0-20) and CRP 34.7 mg/dl (normal 0-6). Liver function tests and renal function tests were within normal limits. Viral markers for hepatitis B, hepatitis C, and HIV were nonreactive, Mantoux test and stool for occult blood were negative. Chest X-ray did not reveal any abnormality. CBNAAT and interferon gamma release assay performed to rule out tuberculosis were found to be negative. Skin Biopsy revealed multiple epithelioid cell granulomas and a dense chronic inflammatory infiltrate in dermis, without any caseation necrosis [Figure 4]. Ziehl Neelsen and PAS stain were negative. MRI of perineum revealed multiple perianal and sacrococcygeal sinuses and fistulous tracts. Colonoscopy showed two internal openings, one above anal verge with nodular edematous mucosa and another small opening 3-4 cm above anal verge. Rectal biopsy showed foci of ulceration with adjacent mucosa having few epithelioid cell granulomas with Langhans giant cells without caseation necrosis and negative

This is an open access journal, and articles are distributed under the terms of the Creative Commons Attribution-NonCommercial-ShareAlike 4.0 License, which allows others to remix, tweak, and build upon the work non-commercially, as long as appropriate credit is given and the new creations are licensed under the identical terms.

For reprints contact: reprints@medknow.com

Jaskaran Batra,
Sukhjot Kaur
Goraya¹,
Sandeep Grewal²,
Aminder Singh³

Dr. Batra's Skin Clinic,
¹Department of Dermatology,
Dayanand Medical College
and Hospital, Ludhiana, ²Bone
and Skin Clinic ³Department of
Pathology, Dayanand Medical
College and Hospital, Ludhiana,
Punjab, India

Address for correspondence:

Dr. Sukhjot Kaur Goraya,
Department of Dermatology,
Dayanand Medical College,
Ludhiana, Punjab, India.
E-mail: sukhjotgoraya@gmail.
com

Access this article online

Website: www.idoj.in

DOI: 10.4103/idoj.IDOJ_352_19

Quick Response Code:



How to cite this article: Batra J, Goraya SK, Grewal S, Singh A. Metastatic Crohn's disease of the vulva: A rare presentation. Indian Dermatol Online J 2020;11:416-8.

Received: 27-Jul-2019. **Revised:** 14-Sep-2019.

Accepted: 15-Sep-2019. **Published:** 10-May-2020.

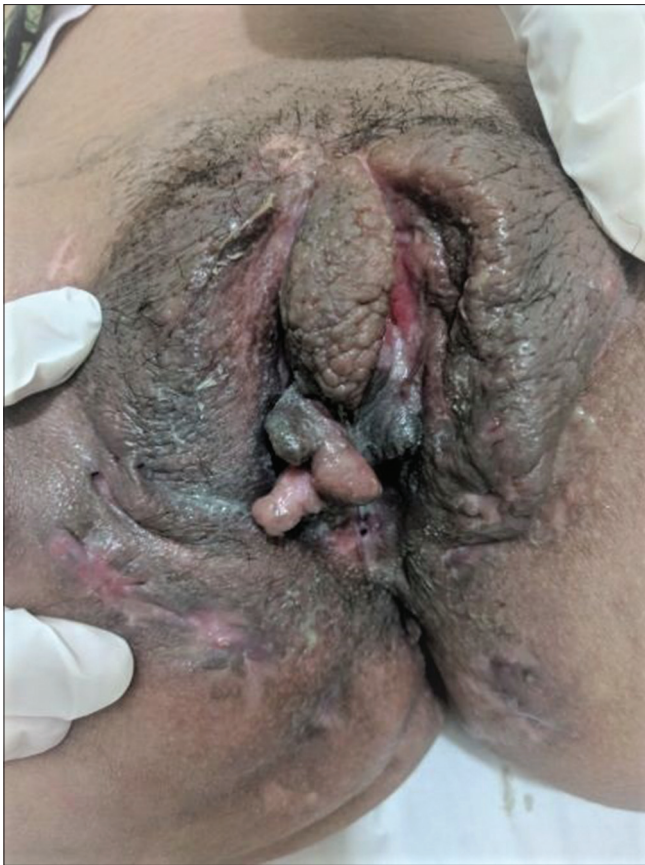

Figure 1: Multiple ulcers, vulvar edema and exophytic outgrowths

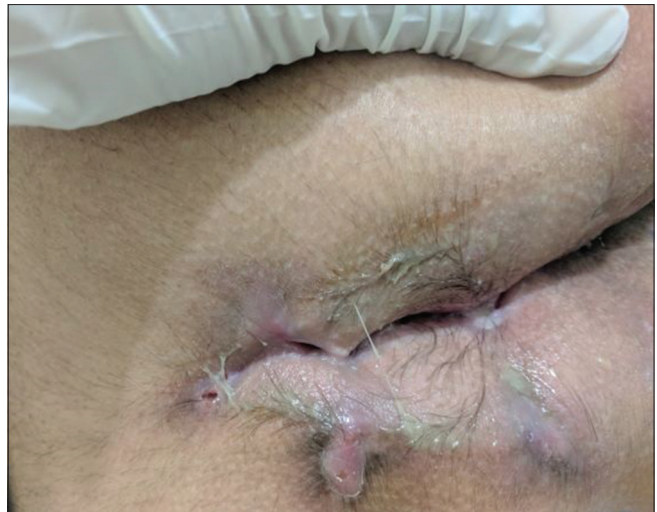

Figure 2: Perianal Pus discharging sinuses

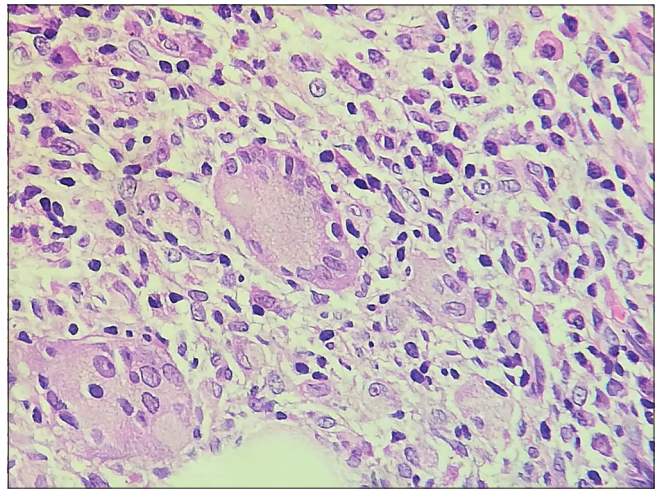


Figure 4: Multiple epithelioid cell granulomas and mixed inflammatory infiltrate (H and E 400x)

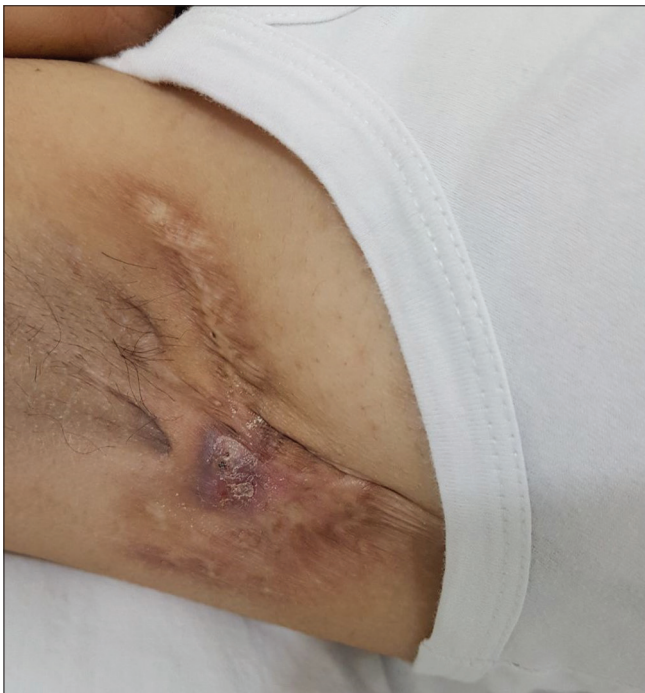

Figure 3: Scarring present in axilla

staining for acid fast bacilli and fungi. Focal cryptitis and occasional crypt abscess was also observed. These findings were consistent with granulomatous inflammation.

In the light of laboratory evidence and clinical findings, a final diagnosis of metastatic Crohn's Disease with rectal Crohn's disease was made and she was started on oral prednisolone 40 mg with gradual tapering and azathioprine 50 mg twice daily for 16 weeks which resulted in significant improvement. Later she was shifted to adalimumab 80 mg initial dose, followed by 40 mg every other week in view of decreasing total leukocyte count due to azathioprine. After an initial response, her disease became resistant to all forms of treatment and she was lost to follow up.

Discussion

Crohn's disease is a chronic granulomatous disorder of unknown etiopathogenesis. It can involve entire length of the bowel from oral cavity to anus, though ileo-caecal junction is the commonest site affected. Cutaneous Crohn's disease is relatively rare with fewer than 100 cases reported in the literature.^[1] Cutaneous manifestations of Crohn's disease are present in 22% to 44% of cases.^[2] Vulvar

lesions occur in approximately 2% of females having Crohn's disease.^[3] Vulvar involvement can be either contiguous (direct extension of intestinal disease) or metastatic in which there is no connection between vulvar involvement and the bowel disease. Metastatic Crohn's disease has no association with disease activity as it can develop during disease remission.^[1] Few cases reported in literature had no intestinal involvement contrary to our case.^[4-6]

Barret *et al.* has described four main types of vulvar Crohn's disease.^[6] Vulvar swelling or edema which is the most common type. Ulceration may develop which can be asymptomatic or painful, single or multiple, aphthoid, and superficial or deep linear knife-like. Lesions may be hypertrophic and exophytic. Hypertrophic and exophytic lesions may result from damage to the lymphatics due to chronic inflammation. The last type of vulvar CD includes chronic abscesses with suppuration.

Various disorders which can create diagnostic confusion include genital tuberculosis, sarcoidosis, hidradenitis suppurativa, syphilis, and lymphogranuloma venereum.

Several treatment options for vulvar Crohn's disease are available. Metronidazole alone or in combination with steroids has a success rate of 87.5%. The recommended dose of metronidazole is 20 mg/kg/d for 12–36 months.^[7,8] Topical glucocorticoids may serve as an adjunct in the management. Other options include infliximab, adalimumab, surgical management including partial or total vulvectomy, laser vaporization, or excision of exophytic lesions.

Conclusion

Metastatic vulvar Crohn's disease may present as a diagnostic challenge as it can mimic many diseases both clinically and histopathologically. Rarer presentation like hypertrophic exophytic variety, as our case, should be

kept in mind while dealing with recalcitrant, long standing diseases of the vulva.

Declaration of patient consent

The authors certify that they have obtained all appropriate patient consent forms. In the form the patient(s) has/have given his/her/their consent for his/her/their images and other clinical information to be reported in the journal. The patients understand that their names and initials will not be published, and due efforts will be made to conceal their identity, but anonymity cannot be guaranteed.

Financial support and sponsorship

Nil.

Conflicts of interest

There are no conflicts of interest.

References

1. Howard A, White CR Jr. Non-infectious granulomas. In: Bologna JL, Jorizzo JL, Rapini PR, editors. *Dermatology*. 2nd ed. Gurgaon: Elsevier India; 2009. p. 1433-5.
2. Criton S. Metastatic Crohn's disease. *Indian J Dermatol Venereol Leprol* 1998;64:80-2.
3. Feller ER, Ribaudo S, Jackson ND. Gynecologic aspects of Crohn's disease. *Am Fam Physician* 2001;64:1725-9.
4. Madhani NA, Desai D, Gandhi N, Khan KJ. Isolated Crohn's disease of the vulva. *Indian J Dermatol Venereol Leprol* 2011;77:342-4.
5. Chalvardijan A, Nethercott JR. Cutaneous granulomatous vasculitis associated with Crohn's disease. *Cutis* 1982;30:645-55.
6. Barret M, de Parades V, Battistella M, Sokol H, Lemarchand N, Marteau P. Crohn's disease of the vulva. *J Crohns Colitis* 2014;8:563-70.
7. Andreani SM, Ratnasingham K, Dang HH, Gravante G, Giordano P. Crohn's disease of the vulva. *Int J Surg* 2010;8:2-5.
8. Brandt LJ, Bernstein LH, Boley SJ, Frank MS. Metronidazole therapy for perineal Crohn's disease: A follow-up study. *Gastroenterology* 1982;83:383-7.