

Hand, Foot and Mouth Disease: A Single Centre Retrospective Study of 403 New Cases and Brief Review of Relevant Indian Literature to Understand Clinical, Epidemiological, and Virological Attributes of a Long-Lasting Indian Epidemic

Abstract

Background: There have been sporadic and periodic large-scale epidemics of hand, foot, and mouth disease (HFMD) with cases at risk for significant morbidity and mortality particularly in Southeast Asia since 1997 and in India since early 2003. **Method:** We retrospectively studied 403 cases recorded from 2009 to 2019 and reviewed relevant Indian literature published between 2004 and 2019 to understand clinical, epidemiological, and virological attributes of this long-lasting Indian epidemic. **Result:** There were 96.8% children and adolescents (M:F 1.6:1) aged 2 months to 18 years and 84% were aged <5 years. Adult family contacts comprised 3.2%. Only 12 sporadic cases occurred during 2009-2011 followed by increased number from 2012 to 2015 peaking with 30.8% cases in 2013 and declining slowly until the year 2019 with small resurgence in 2018. The major peaks occurred during summers with small peaks in autumns. Literature review showed 3332 cases presenting between 2004 and 2019 across Indian states with similar epidemiological trends whereas serotyping identified Coxsackievirus A16 (CV A16) in 83%, Coxsackievirus A6 (CV A6) in 17%, Enterovirus 71 in 4.1%, and multiple strains in 11.7% samples, respectively. **Conclusion:** The overall features of this long-lasting HFMD epidemic; affecting children aged <5 years more often than adults, none or minimum neurological or pulmonary complications in few patients, peaks occurring during summer and autumn months, and identity of the pathogenic virus coincide with global trends. However, the continuous spread of the disease across the country appears in sync with pre-epidemic periods of China and Taiwan. It calls for a continuous surveillance and making HFMD a notifiable disease in India.

Keywords: *Coxsackievirus A16, coxsackievirus A6, epidemic, HFMD, human enterovirus 71, India, onychomadensis, Southeast Asia, viral infection*

**Anuj Sharma,
Vikram K. Mahajan,
Karaninder S.
Mehta,
Pushpinder S.
Chauhan,
Sujaya Manvi,
Amit Chauhan**

*Department of Dermatology,
Venereology and Leprosy,
Dr. Rajendra Prasad
Government Medical College,
Kangra (Tanda), Himachal
Pradesh, India*

Introduction

Hand, foot and mouth disease (HFMD) primarily affects infants and children or occasionally adults. The diagnosis is mainly clinical from characteristic mucocutaneous lesions distributed over hands, feet and oral cavity, and a prodrome of fever, malaise and upper respiratory symptoms. Laboratory diagnosis is from isolation and molecular identification of the virus in culture or from throat swabs, stool or vesicular fluid samples. The disease is caused by Picornaviridae family comprising more than 100 types including poliovirus, coxsackievirus (CV) A and B, echoviruses, and human enteroviruses (EVs).^[1,2] Its clinical course is mainly mild and self-limiting but a severe form of infection and systemic

complications have been attributed to EV 71.^[3] Its transmission is via oro-fecal route from infected patients, or contact with contaminated material surfaces, vesicle fluid, food, or water.^[4] EV71 has been identified in throat swabs or feces of patients even weeks before symptom onset, thus, an asymptomatic person may remain infectious during incubation period and even after symptoms have resolved in a symptomatic patient.^[5,6] The disease occurs worldwide in epidemic or sporadic form. For about 3 decades following its discovery, only small scale outbreaks limited to small geographic areas were reported. HFMD epidemics have been usually because of CV A16 and CV A6 and A10 lead to sporadic cases. As no

Address for correspondence:
*Dr. Vikram K. Mahajan,
Department of Dermatology,
Venereology and Leprosy,
Dr. Rajendra Prasad
Government Medical College,
Kangra (Tanda) - 176 001,
Himachal Pradesh, India.
E-mail: vkml@rediffmail.com*

This is an open access journal, and articles are distributed under the terms of the Creative Commons Attribution-NonCommercial-ShareAlike 4.0 License, which allows others to remix, tweak, and build upon the work non-commercially, as long as appropriate credit is given and the new creations are licensed under the identical terms.

For reprints contact: WKHLRPMedknow_reprints@wolterskluwer.com

How to cite this article: Sharma A, Mahajan VK, Mehta KS, Chauhan PS, Manvi S, Chauhan A. Hand, foot and mouth disease: A single centre retrospective study of 403 new cases and brief review of relevant Indian literature to understand clinical, epidemiological, and virological attributes of a long-lasting Indian epidemic. *Indian Dermatol Online J* 2022;13:310-20.

Received: 26-Nov-2021. **Revised:** 17-Dec-2021.
Accepted: 17-Dec-2021. **Published:** 05-May-2022.

Access this article online

Website: www.idoj.in

DOI: 10.4103/idoj.idoj_701_21

Quick Response Code:



specific treatment or vaccine that is effective, safe and can be used routinely in clinical practice is available, HFMD has become a significant public health problem because of frequent outbreaks and rise in its incidence, severity, and fatal complications in Southeast Asian countries in last few decades with a gradual shift towards EV 71 infection.^[7-11]

The first report of disease outbreak in India was from Calicut in 2004 that was followed by a large scale outbreak in 2007 in and around Kolkata, the capital of West Bengal.^[12,13] Since then, many sporadic cases and epidemic outbreaks have been reported almost from the entire country [Figure 1] until it became sporadic in nature later. However, HFMD is not a mandatory reportable disease in India.

This study presents characteristics of 403 new cases registered in a single center between 2009 and 2019 and briefly reviews relevant Indian literature to understand overall clinical, epidemiological, and virological attributes of this long-lasting Indian epidemic in the context of world trends.

Materials and Methods

Clinical data

The medical records of all patients with HFMD attending the dermatology outpatient clinic between 2009 and 2019 were analyzed retrospectively after approval from institutional ethics committee. This tertiary care institute is located in the Western Himalayas at 2.1°N 76.27°E and an average altitude of 733 meters above sea level. The terrain is mostly semi-foothills or plains with semi-temperate to subtropical weather round the year. This hospital is visited by the patients from the whole district and adjoining areas on their own or they are referred by primary health care centers for specialized services.

The data was analyzed for clinico-epidemiological characteristics such as demographic profile, personal and family history, evolution of skin lesions and systemic features. The diagnosis of HFMD was mainly from clinical presentation of a prodrome of mild to moderate fever and other symptoms and eruption of characteristic 3-7 mm erythematous macules evolving rapidly into pale white, thin-walled oval vesicles with a red areola characteristically distributed over acral areas with or without involvement of oral cavity. These would fade over 2-3 days and heal without crusting or scarring in about 7-10 days. Virological studies were not performed because of financial constraints and for want of in house facility.

Review of literature

Online search using PubMed, MEDLINE, IndMed and Google was performed for English language medical literature, news reports, and state notifications on HFMD published between 2004 and 2019 describing case reports, case series, and epidemiological studies from India. The

search terms included “hand, foot and mouth disease”, “coxsackievirus” and “human enteroviruses” in combination with “India” using comma-separated value function.

Statistical analysis

The MS Office™ Excel® software was used to tabulate and analyze the data pertaining to our patients. The continuous data are presented as means and categorical variables are presented as frequencies and percentages.

The data obtained from review of published reports were tabulated and analyzed for number of the affected individuals, state/region of the outbreak, year and time of the outbreak, and available results of the viral studies.

Results

Clinical, demographic and epidemiological features of new cases

We recorded 403 new cases of HFMD between 2009 and 2019. Only 12 sporadic cases occurred between 2009 and 2011. Thereafter, number of cases increased between 2012 and 2015 peaking with 124 (30.8%) cases in 2013 followed by a slow decline until the year 2019 with small resurgence in 2018 [Figure 2]. One hundred and fifty (37.2%) cases presented during summers (May-June) with other small peaks in autumn (October-November) of 2016 and 2017 [Figure 3]. Table 1 depicts their clinicoepidemiological characteristics. There were 390 (96.8%) children comprising 241 (61.8%) males and 149 (38.2) females (M:F 1.6:1) aged between 2 months and 18 years. The majority, 339 (84.1%) patients were aged 2 months to 5 years. Forty (9.9%) children were from a single kindergarten. Thirty six (8.9%) patients were family members of the affected cases. Thirteen (3.2%) patients were adults and included 5 (38.5%) males and 8 (61.5%) females (M:F 1:1.6) aged between 21 and 37 years. They were mostly family members of the affected children and had minimal symptoms and skin lesions.

Mild fever and constitutional symptoms were first noted 1-2 days prior to characteristic skin and oral lesion in 75 (18.6%) cases. The oral (labial, buccal, tongue, palate) involvement was present in 135 (33.5%) patients and characteristic vesicular lesions involving hands [Figure 4a], feet [Figure 4b], elbows, perioral skin/oral mucosae [Figure 4c], buttocks [Figure 4d] and knees [Figure 4e] occurred variably in all patients. Pruritus/burning sensation (in 15.4%), upper respiratory catarrh (in 12.7%), difficulty in swallowing (in 5.9%), and irritability in 2.9% cases, respectively, were other major symptoms noted in children. Only 12 (2.9%) children needed hospitalization for mild dehydration or fever (>38°C). The manifestations in adults were of minimal skin lesions without systemic symptoms [Figure 5]. Serology report for IgM CV A6 and CV A16 antibody available in three children from our center was negative.

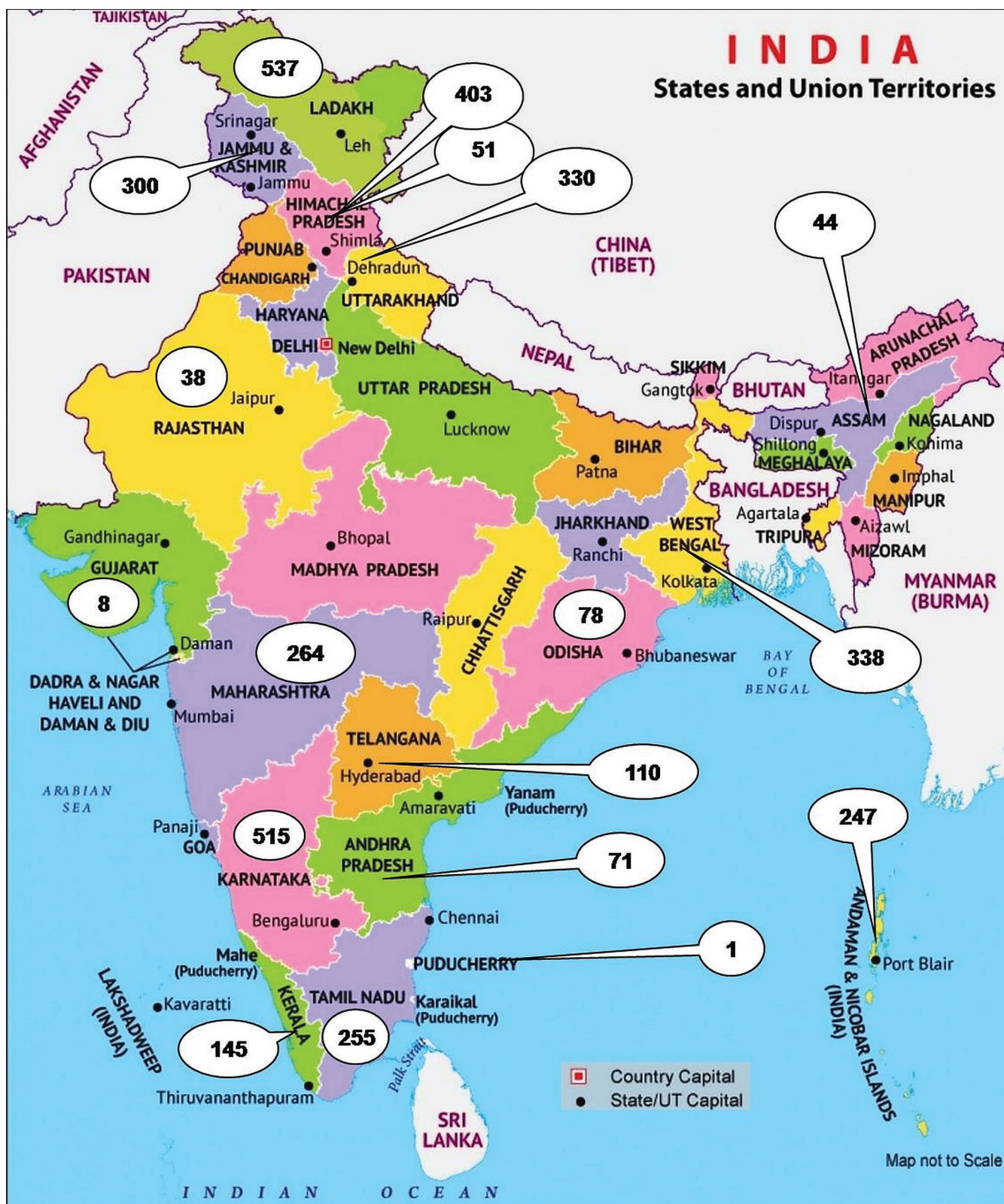


Figure 1: Geographic distribution of hand, foot and mouth disease cases in India (The 403 cases from this study are also shown here together with those reported from Himachal Pradesh in the literature). Note: News papers also reported small outbreaks of HFMD cases between the year 2012 and 2014 from - Delhi, Goa, Srinagar, Arunachal, Meghalaya, Nagaland, Manipur, Tripura, Mizoram, Daman and Diu, Lakshadweep, Punjab, Chandigarh, Haryana, Uttar Pradesh, Bihar, Madhya Pradesh, Chhattisgarh, and Jharkhand

All patients recovered completely after supportive management and none developed neurological or pulmonary complications.

A 6-year-old child was brought back after 2 months with onychomadesis, leukonychia and mild nail dystrophy [Figure 6].

Results of reviewed literature

Three studies could not be retrieved and were excluded from review.^[14-16] The combined review of other 48 publications/reports in the English-language literature

which could be retrieved and considered relevant for clinicoepidemiological and virological features of HFMD are tabulated in Supplementary Table S1.^[12,13,17-62] Ten studies did not mention period of outbreak. Ten publications reported only single cases, 4 studies reported 2-5 cases and 34 were original or hospital based studies, and government reports. Overall, there were 3332 patients with HFMD reported between 2003 and 2019 across the entire country [Figure 1]. There were 3162 (94.9%) children (aged 4 months to 12 years), 132 (4%) adolescents (aged >12-18 years) and 38 (1.1) adults above 18 years of age.

Major outbreaks were during summers and rainy seasons (April to September) of the years 2013, 2015 and 2016 reporting 370 (11.1%), 533 (16%), and 465 (14%) cases, respectively [Figure 7]. However, small outbreaks had also occurred during autumn (October-November) and winter (December-January) months.

Fever and characteristic skin lesions starting on 2nd to 3rd day were the presenting features and were mild in most of the reviewed cases. Severe diarrhea and vomiting,

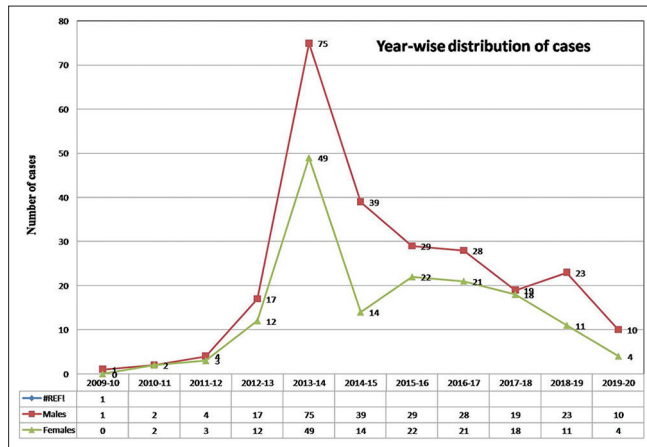


Figure 2: Year wise distribution of HFMD cases from our study centre. The initial number of cases between 2009 and 2011 had increased to peak in 2013. Small peaks occurred in subsequent years

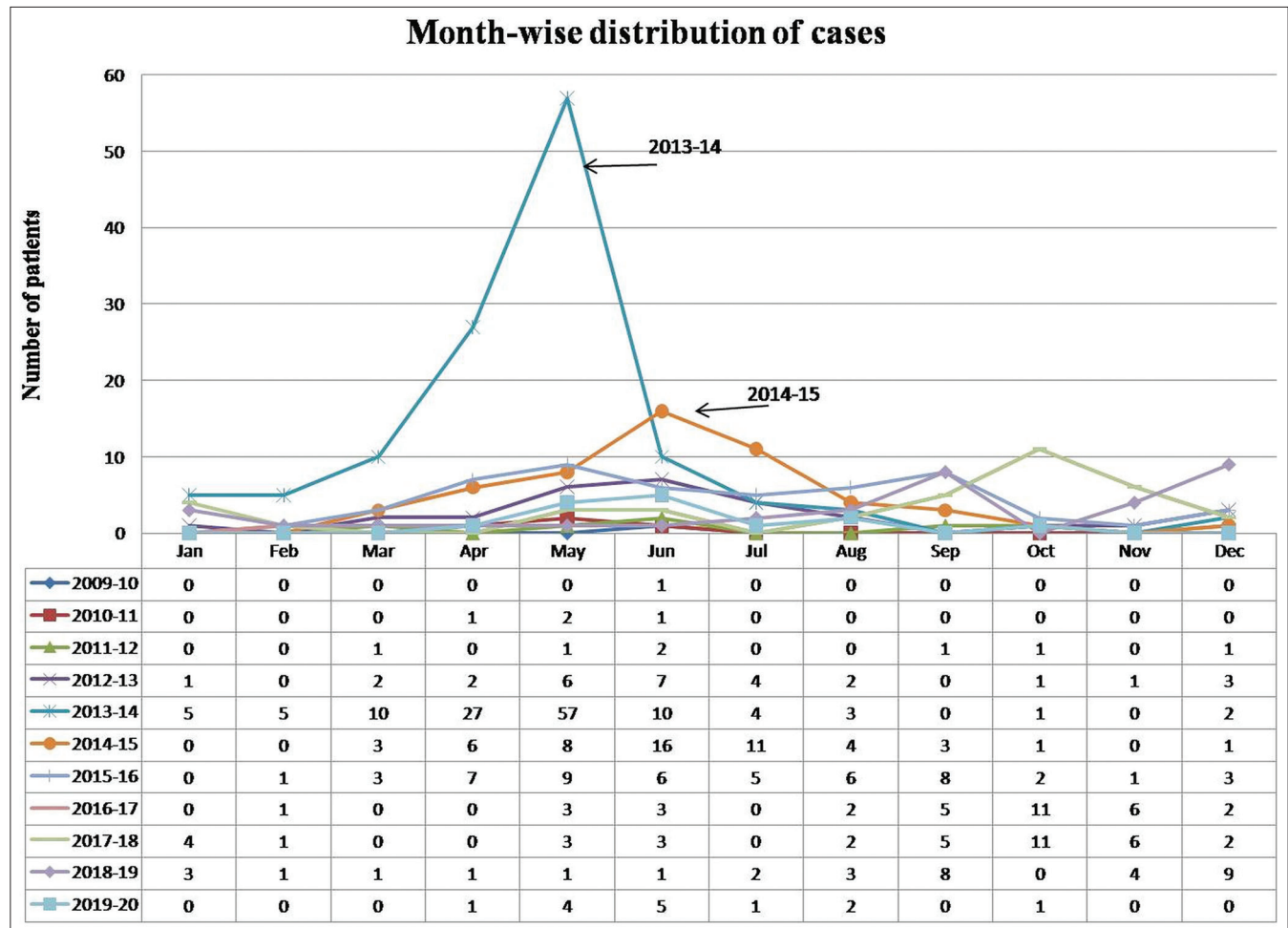


Figure 3: Month wise distribution of HFMD cases from our study centre. The major peaks occurred in 2013-14 during summer months (March to June). Small peaks occurred during autumn months (September to November)

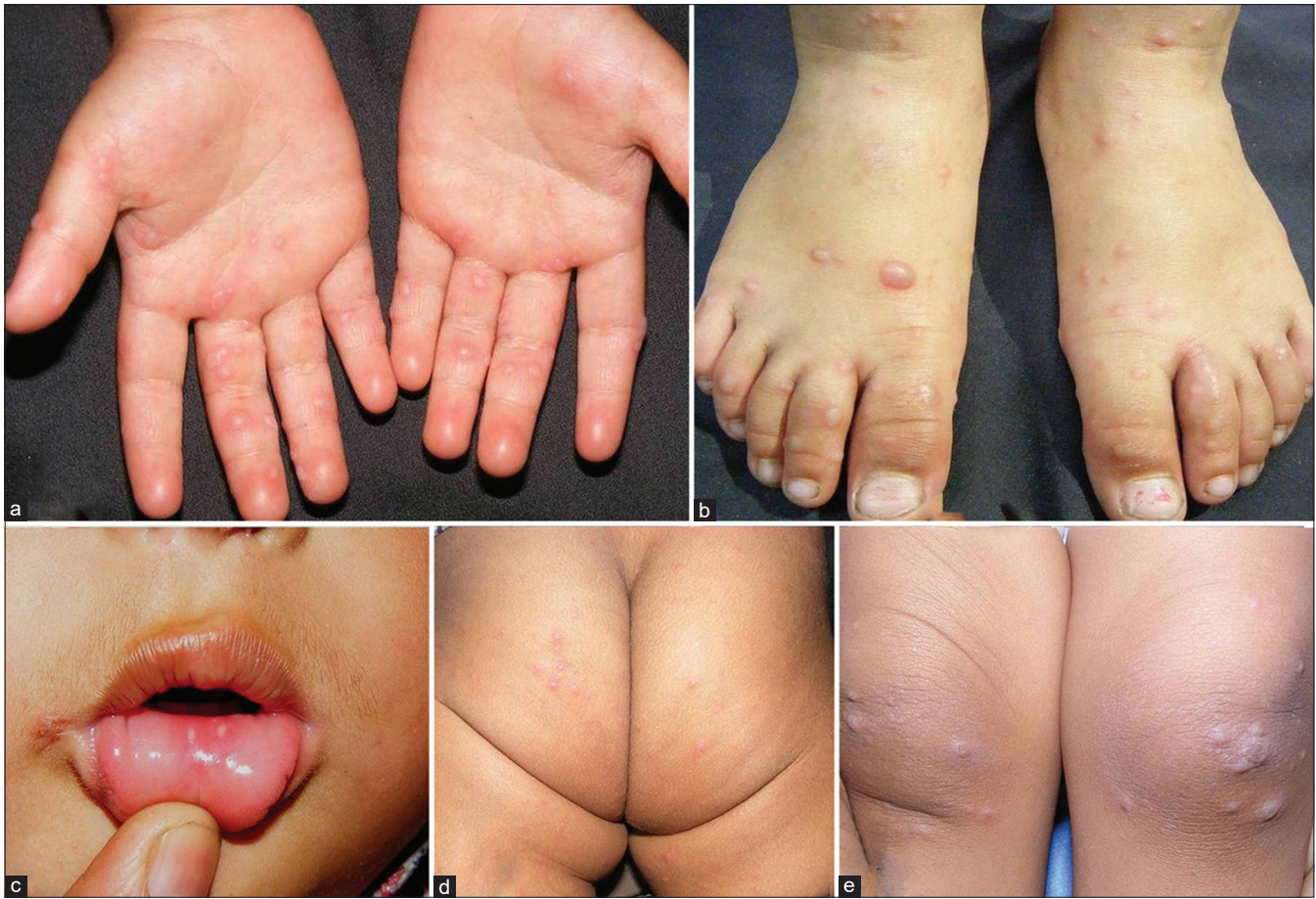

Figure 4: Small multiple round/oval macules and pearly-white vesicles with a red areola over (a) palms and (b) dorsa of feet in a 5-year-old child. Small yellowish-white aphthae-like lesions with surrounding erythematous areola are involving labial mucosa in a 3-year-old child (c). Similar lesions were present over buccal mucosa and anterior palate. Characteristic erythematous macules and pearly-white vesicular lesions are seen over (d) buttocks, and (e) knees in a 3-year-old child

aseptic meningitis, and viral pneumonia in one case each were serious manifestations observed.^[58,59] While one child had febrile convulsions, palmoplantar skin exfoliation in 12.6%, and onychomadesis and other nail changes were other complications in 34% children in a study.^[34] Delayed nail changes were also noted in 26.4% and 48.2% patients in two separate studies.^[28,60] All cases had improved spontaneously requiring only symptomatic treatment and parental counselling. Relapses had occurred within 3-4 weeks and as late as 1-5 years.^[27,29,35,36]

Causative viruses

Only 17 publications had included virus identification studies by reverse transcriptase polymerase chain reaction (RT-PCR) for viral RNA isolation, complement fixation test (CFT), or serology for IgM antibodies [Table 2]. Overall 1142 clinical samples from 1064 patients were tested for causative virus and mainly included throat swabs, vesicular fluid, and stool samples in majority and/or serum for antibody testing (19 samples). Viral RNA or IgM antibody results were positive in 617 (54%) of 1142 clinical samples. Serotyping identified

CV A16 in 512 (83%), CV A6 in 105 (17%), and EV 71 in 25 (4.1%) samples, respectively. Multiple strains were identified in 72 (11.7%) samples. Untyped enteroviruses or EV A&B were identified in 3 (0.5%) samples.

Discussion

In our study, HFMD affected children mostly between 3 and 5 years of age but infection in older children and adults also occurred. Low grade fever and prodrome of upper respiratory catarrh remained the presenting symptoms followed by appearance of oral and skin lesions after 2-3 days with characteristic distribution in its typical form. The majority of the patients in the study had skin involvement starting after 2nd to 3rd day of prodrome while only 77% of our patients had oral lesions. No neurological or pulmonary manifestations were detected and all the cases improved spontaneously after symptomatic treatment in 7-10 days. Similar clinical presentation was also observed in the reviewed cases but with exception of severe diarrhea and vomiting, aseptic meningitis, and viral pneumonia in few cases. The long term complications such as palmoplantar exfoliation and nail changes too were

Table 1: Baseline clinical features of our HFMD patients

Features		Number of patients (%) n=403
Children	Total	390 (96.8)
n=390	Boys	241 (61.8)
Age	Girls	149 (38.2)
Range (Mean)	M:F	1.6:1
2 mo-18 y (3.1 years)	2 mo-3 y	238 (61.0)
	>3-5 y	101 (25.9)
	>5-12 y	36 (9.2)
	>12-18 y	15 (3.9)
Adults	Total	13 (3.2)
n=13	Males	5 (38.5)
Age	Females	8 (61.5)
Range (Mean)	M:F	1:1.6
21 y-37 y (27.3 y)	21-30 y	9 (69.2)
	31 to 40 y	4 (30.8)
Months with peak of HFMD cases	May -June (summers)	150 (37.2)
Family history of HFMD	Present	36 (8.9)
Clinical symptoms/signs*	Characteristic lesions	403 (100)
	Oral lesions	135 (33.5)
	Fever	75 (18.6)
	Pruritus/Burning	62 (15.4)
	Upper respiratory catarrh	51 (12.7)
	Feeding difficulties	24 (5.9)
	Irritability with or without disturbed sleep	12 (2.9)
	Hospitalization	12 (2.9)
	Delayed nail changes	1 (0.3)

mo, months; y, years. * most patients had multiple symptoms

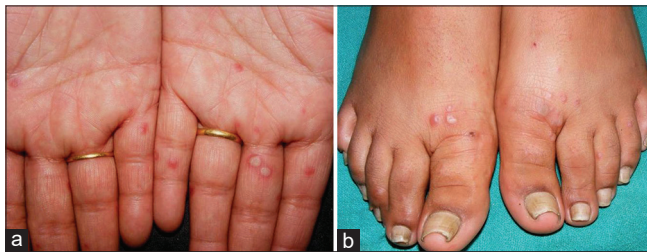


Figure 5: Characteristic skin lesions of hand, foot and mouth disease in mother of an affected child involving palms (a) and feet (b) only. Oral lesions were not perceptible in her

minimal. Overall, all these features in Indian patients with HFMD are in sync with its reported general clinical course.

India has weather conditions varying from arctic to temperate climates in outer Himalayas in the north to subtropical and tropical climates in the sub hills and plains, and coastal regions in the south. Both in terms of proximity and population India is only next to its neighboring China which had been the worst affected country in Southeast Asia. There was no evidence of the disease in India prior to first report of disease outbreak in 2003-2004 from Calicut followed by many outbreaks across regions with more or less similar epidemiological trends.^[12,13] A rising trend in new cases in our center was also seen from 2009 onwards that peaked in 2013 before declining in subsequent years coinciding with general trends of small

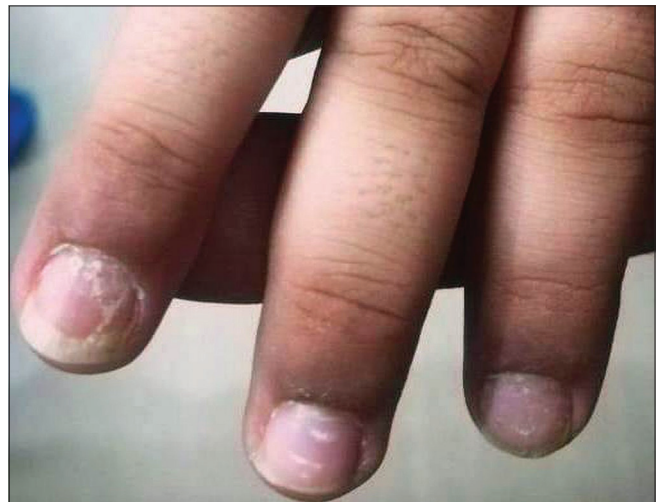

Figure 6: Nail changes of onychomadesis of index fingernail, leukonychia and mild dystrophy of other nails in a 5-yr-old child seen 2 months after HFMD

scale outbreaks reported across almost all Indian states/ union territories. The number of cases had peaked during summer months (May-June) of the years 2013, 2015 and 2016 at majority of the places. Small peaks in number of cases were also reported during autumn months from southern most states of Karnataka, Kerala, Tamil Nadu, Telangana, Andhra Pradesh, and West Bengal mostly

Table 2: Results of literature review for viral studies

Serial no.	Number of cases tested*	Number of positive results	Identity of virus=number of positive samples**	Laboratory Methods	Reference number
1	11	6	CVA-16=6	CFT	28
2	62 (40 samples)	6	CVA 6=3 CVA 16=1 EV 71=2	RT-PCR	29
3	10	6	CVA 6=2 CVA 16=2 EV (un typed) =2	RT-PCR	31
4	78	7	CVA 16=7	RT-PCR	33
5	15	13	CVA 6=10 CVA 16=3	RT-PCR	35
6	7	7	CVA 6=5 CVA 16=2	RT-PCR	36
7	64 (158 samples)	158 samples	CVA 4=44 CVA 6=43 CVA 16=70 EV 71=1	RT-PCR	37
8	68 (93 samples)	93 samples	CVA 6=38 CVA 16=54 EV A & B=1	RT-PCR	39
9	7	2	CV A16=2	RT-PCR	42
10	222	189	CV A 16=189	RT-PCR	43
11	81	19	IgM EV 71=19	Serology	13
12	60	10	CVA 6=3 CA 16=16 EV 71=3	RT-PCR	53
13	1	1	CV A16=1	RT-PCR	54
14	30 (78 Samples from vesicle fluid)	18	CV A16=78	RT-PCR	55
15	101 (34 Samples)	18	CV A16=18	RT-PCR	58
16	246	63	CV A16=63	RT-PCR	62
17	1	1	CV A6=1	RT-PCR	54
Total	1064 (1142 samples)	617 (54.02%)	CV A16=512 (83.0%) CV A6=105 (17.0%) CV A4=44 (7.1%) EV 71=25 (40.1%)*** Others=3 (0.5%) EV (not typed) = 2 EV A & B=1	-	-

*Samples were mainly from throat swabs and stools swabs when not specified. **Some samples were positive for more than one virus type.

***Includes positive results by RT-PCR (6 samples) and Serology for IgM (19 samples). CFT, complement fixation test; CV, Coxsackie virus; EV, Enteroviruses; Ig, immunoglobulin; RT-PCR, reverse transcriptase polymerase chain reaction

with subtropical/tropical climatic conditions year round. In comparison, review of epidemic trends in affected countries across the world showed that its first occurrence was in 1957 as a CV A16-associated mild febrile summer illness in Toronto (Canada) affecting about 60 individuals. Later epidemics had been sporadic and limited to small

geographic areas in Australia, Brazil, Europe, Japan and United States.^[63-68] However with more frequent outbreaks and significantly high mortality among children over the years, it became a substantial public health problem in most Southeast Asian countries (Malaysia, Taiwan, China, Japan, Vietnam, Singapore, South Korea) between 1997 and

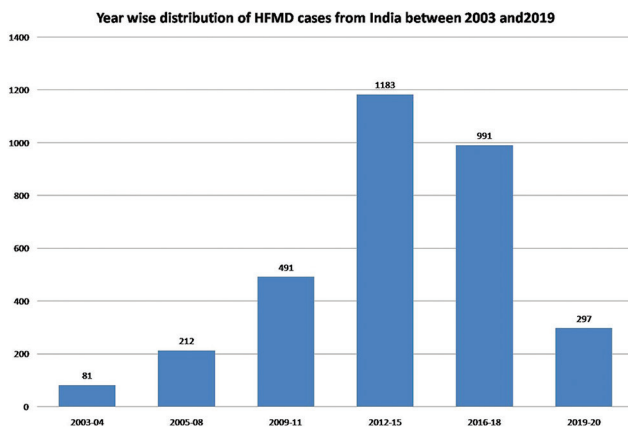


Figure 7: Year wise distribution of cases reported from India between 2003 and 2019. A rising trend in number of cases was seen from 2003 onwards that peaked between 2012 and 2015 before declining in subsequent years. Sporadic cases are still reported

2008.^[1,7-10] Several large outbreaks also happened in Japan during the years 2000 to 2013.^[6,69] All previous severe outbreaks had followed many years of milder attacks, intermittent periods of quiescence and progressively larger areas of involvement. However, epidemic trends of HFMD in general remained variable across countries and regions. Most countries reported single outbreak commonly in summers each year with a tendency to follow seasonal distribution patterns that varied according to the latitude. The first large-scale epidemic in China with a significant number of cases ending fatally occurred in the spring of 2008.^[11] While countries with tropical and subtropical climatic conditions (Taiwan, Singapore, Malaysia) had two peaks in a year, those with higher latitudes (South Korea, Japan, Finland, United States) showed a single yearly peak of the disease.^[7,9,70-75] Similarly, Finland generally had experienced peaks in early autumn.^[71] We also noted almost similar epidemiological trends for major outbreaks during summers and rainy seasons (April to September), and small outbreaks during autumn (October-November) and winter (December-January) months over these years across India having varied topography, geography and climatic conditions.

The disease is most often caused by enteroviruses CV A16, CV A6, CV A10 or EV 71.^[76] Going with the world trends, enteroviruses CV A16 in 83%, CV A6 in 17%, and EV 71 in 4% strains were also responsible for this long lasting Indian epidemic of HFMD. Interestingly, CV A16 and CV A6 strains had exhibited sequence identity with those isolated from Japan, China, and Finland, Taiwan and China, France, China, and Malaysia in three Indian studies indicative of their possible origin.^[37,43,62] Although neurological or pulmonary complications (encephalitis, meningitis, poliomyelitis-like syndromes, and cardiovascular and/or respiratory failure) particularly among children infected with EV71 may complicate otherwise mild disease,^[4,76,77] most patients in this study had improved spontaneously

except for few cases requiring hospitalization due to moderately severe presentation/complications. With some exceptions even patients infected with EV 71 showed no significant complications or fatal outcome, and recurrences were noted in only fewer cases. However, the true outcome perhaps remains unascertained from small number of virology reports.

Limitations

The study is limited by its retrospective design, lack of virological studies at our center, and the reviewed literature by itself may have missed some cases/reports. To delineate role played by global warming in general and changing climatic conditions in prolonging the duration of outbreaks during peak seasons or increased likelihood of its transmission throughout the year and aggravating the problem from public health point was not a part of study.

Conclusion and the Way Forward

The overall features of this long lasting HFMD epidemic affecting children, mild or no neurological or pulmonary manifestations in most patients, peaks of the disease happening during summer months and the causative virus strains appear in sync with global trends of the disease. However, it remains distinctly possible that mild nature of the disease in majority, and low level of awareness both among general public and primary health care providers might have led to continuation of ongoing epidemic at least in some regions. Nevertheless, the continuous spread of the disease across the country reminds of pre-epidemic periods of China and Taiwan. Thus, clinical and molecular research relevant to the disease, development of a safe and effective multivalent vaccine, monitoring of the disease outbreaks, and mass awareness programs for general public are urgent needs. The measures such as provision for clean drinking water, improved sanitation, and stringent hygiene practices remain important preventive measures for this growing public health problem. Strict surveillance for HFMD and making it a notifiable disease in India will perhaps be the first step in that direction.

Declaration

All authors declare that they have no competing interest and therefore nothing else to declare, and have contributed significantly and take full responsibility for the manuscript. The authors of the paper are obliged to confirm that it has not been previously published. The study was not funded by any agency.

Contributors' statement

AS obtained compiled, tabulated all data and helped in literature search and preparing of the initial draft. VKM conceptualized, analyzed and interpreted data, drafted, and critically evaluated the manuscript for important intellectual content. KSM, PSC, SM, AC, MC, YRV, SH, and JS

helped in obtaining, compiling and interpretation of clinical data and literature search. All authors were involved in the preparation and revision of the draft manuscript and have agreed to the final contents.

Statement of ethics

All procedures followed were in accordance with the ethical standards of the responsible committee on human experimentation (institutional and national) and with the Helsinki Declaration of 1975, as revised in 2013.

Acknowledgements

All residents, staff members (past and present) who have been involved in maintenance of records and care of these patients.

Financial support and sponsorship

Nil.

Conflicts of interest

There are no conflicts of interest.

References

1. He SZ, Chen MY, Xu XR, Yan Q, Niu JJ, Wu WH, *et al.* Epidemics and aetiology of hand, foot and mouth disease in Xiamen, China, from 2008 to 2015. *Epidemiol Infect* 2017;145:1865-74.
2. Ogi M, Yano Y, Chikahira M, Takai D, Oshibe T, Arashiro T, *et al.* Characterization of genome sequences and clinical features of coxsackievirus A6 strains collected in Hyogo, Japan in 1999–2013. *J Med Virol* 2017;89:1395-403.
3. Kaminska K, Martinetti G, Lucchini R, Kaya G, Mainetti C. Coxsackievirus A6 and hand, foot and mouth disease: Three case reports of familial child-to-immunocompetent adult transmission and a literature review. *Case Rep Dermatol* 2013;5:203-9.
4. Zhu Z, Zhu S, Guo X, Wang J, Wang D, Yan D, *et al.* Retrospective seroepidemiology indicated that human enterovirus 71 and coxsackievirus A16 circulated widely in central and southern China before large scale outbreaks from 2008. *Virol J* 2010;7:300.
5. Chen B, Sumi A, Toyoda S, Hu Q, Zhou D, Mise K, *et al.* Time series analysis of reported cases of hand, foot, and mouth disease from 2010 to 2013 in Wuhan, China. *BMC Infect Dis* 2015;15:495.
6. World Health Organization (WHO): Western Pacific Region. A guide to clinical management and public health response for hand, foot and mouth disease (HFMD). 2011. Available from: <http://www.wpro.who.int/publications/docs/GuidancefortheclinicalmanagementofHFMD.pdf>. [Last accessed on 2019 Dec 01].
7. Chua K, Kasri A. Hand foot and mouth disease due to enterovirus 71 in Malaysia. *Virol Sin* 2011;26:221-8.
8. Ho M, Chen ER, Hsu K-H, Twu S-J, Chen K-T, Tsai S-F, *et al.* An epidemic of enterovirus 71 infection in Taiwan. Taiwan enterovirus epidemic working group. *N Engl J Med* 1999;341:929-35.
9. Wu Y, Yeo A, Phoon MC, Tan EL, Poh CL, Quak SH, *et al.* The largest outbreak of hand, foot and mouth disease in Singapore in 2008: The role of enterovirus 71 and coxsackievirus A strains. *Int J Infect Dis* 2010;14:e1076-81.
10. Liu WD, Ji H, Shan J, Bao J, Sun Y, Li J, *et al.* Spatiotemporal dynamics of hand-foot-mouth disease and its relationship with meteorological factors in Jiangsu Province, China. *PLoS One* 2015;10:e0131311. doi: 10.1371/journal.pone.0131311.
11. Zhang Y, Zhu Z, Yang W, Ren J, Tan X, Wang Y, *et al.* An emerging recombinant human enterovirus 71 responsible for the 2008 outbreak of hand foot and mouth disease in Fuyang city of China. *Virol J* 2010;7:94. doi: 10.1186/1743-422X-7-94.
12. Sasidhran CK, Sugathan P, Agarwal R, Khare S, Lal S, Jayaram Paniker CK. Hand-foot and mouth disease in Calicut. *Indian J Pediatr* 2005;72:17-21.
13. Sarma N, Sarkar A, Mukherjee A, Ghosh A, Dhar S, Malakar R. Epidemic of hand, foot and mouth disease in West Bengal, India in August 2007: A multicentric study. *Indian J Dermatol* 2009;54:26-30.
14. Dwivedi B, Kar BR, Kar SK. Hand, foot and mouth disease (HFMD): A newly emerging infection in Orissa, India. *National Med J India* 2010;23:313.
15. Dias E, Dias M. Recurring hand foot mouth disease in a child. *Ann Trop Med Public Health* 2012;5:40-41.
16. Thomas J. Hand foot and mouth disease-an overview. *e-J Indian Soc Teledermatol* 2009;3:1-5.
17. Mehta KIS, Mahajan VK. Hand foot and mouth disease. *Indian Pediatr* 2010;47:345-6.
18. Media alert from Media & Verification Cell. Hand-foot and mouth disease cases on rise in Baramulla district, Jammu and Kashmir, 300 children affected. Integrated Disease Surveillance Program-National Centre for Disease Control (IDSP-NCD) report (ID JK/KLM/2-16/18/980) dated 07.05.2016 submitted to Ministry of Health & Family Welfare, Government of India. Available from: https://idsp.nic.in/WriteReadData/Media_Alert_May-2018/4658.pdf.
19. Media alert from Media & Verification Cell. Disease alerts/outbreaks reported and responded to by states/UTs through Integrated Disease Surveillance Programme, Integrated Disease Surveillance Program-National Centre for Disease Control (IDSP-NCD) report (ID JK/LDK/2016/18/981) dated 07.05.2016 submitted to Ministry of Health & Family Welfare, Government of India. Available from: <https://idsp.nic.in/WriteReadData/1892s/72914162941466750136.pdf>.
20. Kadri SM, Kincaid J, Williams L, Riley C, Rehana K, Hinton T, *et al.* Epidemic investigation of the largest outbreak of hand foot and mouth disease (HFMD) in Leh, India. *J Fam Med Primary Care* 2019;8 (only abstract available).
21. Kashyap S, Verma GK. Hand-foot-mouth disease: Outbreak in Shimla. *Indian Pediatr* 2014;51:155.
22. Sharma R, Manvi S. Hand, foot and mouth disease-case reports of familial child to immunocompetent adult transmission. *J Med Sci Clin Res* 2018;6:32085-89.
23. Aggarwal N, Mittal A, Kayal A, Khare AK, Kuldeep CM, Gupta AK. Outbreak of hand, foot, and mouth disease in Udaipur. *Indian J Dermatol* 2015;60:108.
24. Nanda C, Singh R, Rana SK. An outbreak of hand-foot-mouth disease: A report from the hills of northern India. *Natl Med J India* 2015;28:126-8.
25. Sahota R, Kaur N, Singh G, Upadhyay N. Study the current scenario of hand foot mouth disease an Indian prospective. *Int J Contemp Pediatr* 2020;7:1558-60.
26. Ghosh SK, Bandyopadhyay D, Ghosh A, Dutta A, Biswas S, Mandal RK, *et al.* Mucocutaneous features of hand, foot, and mouth disease: A reappraisal from an outbreak in city of Kolkata. *Indian J Dermatol Venereol Leprol* 2010;76:564-6.
27. Sarma N. Relapse in hand, foot and mouth disease: Are we at more risk. *Indian J Dermatol* 2013;58:78-9.

28. Nag SS, Dutta A, Mandal RK. Delayed cutaneous findings of hand, foot, and mouth disease. *Indian Pediatr* 2016;53:42-4.
29. Sarma N, Chakraborty S, Dutta A, Chandra S. Hand, foot and mouth disease in West Bengal, India: A preliminary report on clinicovirological trend over 3 successive years (2013-2015). *Indian J Dermatol* 2017;62:486-90.
30. Arora S, Arora G, Tewari V. Hand foot and mouth disease: Emerging epidemics. *Indian J Dermatol Venereol Leprol* 2008;74:503-6.
31. Borkakoty B, Das M, Jakharia A, Bhattacharya C, Bora C, Baruah PJ, *et al.* Hand, foot and mouth disease caused by Coxsackie viruses A6 and A16 in Assam, Northeast India: A need for surveillance. *Indian J Dermatol Venereol Leprol* 2020;86:105.
32. Singh R, Diwan N, Nair P. Hand, foot, and mouth disease: A case series from rural set up of Gujarat. *Indian J Paediatr Dermatol* 2016;17:290-3.
33. Kar BR, Dwivedi B, Kar SK. An outbreak of hand, foot, and mouth disease in Bhubaneswar, Odisha. *Indian Pediatr* 2013;50:139-42.
34. Sane S, Saboo N, Utage V. Observations regarding outbreak of hand, foot and mouth disease at Thane, Maharashtra. *Pediatr Infect Dis* 2009;1:64-5.
35. Dharmapalan D, Saxena VK, Pawar SD, Qureshi TH, Surve P. Clinical and molecular investigations of hand, foot and mouth disease outbreak in Navi Mumbai, India. *Indian Pediatr* 2019;56:1052-54.
36. Saxena VK, Pawar SD, Qureshi TH, Surve P, Yadav P, Nabi F, *et al.* Isolation and molecular characterization of coxsackievirus A6 and coxsackievirus A16 from a case of recurrent hand, foot and mouth disease in Mumbai, Maharashtra, India, 2018. *Virus Dis* 2020;31:56-60.
37. Ganorkar NN, Fulmali PP, Tikute SS, Gopalkrishna V. Genetic characterization of enterovirus strains identified in hand, foot and mouth disease (HFMD): Emergence of B1c, A, C1 subgenotypes of CVA16, CVA6, and EV71 strains in India. *Infect Genet Evolution* 2017;54:192-9.
38. Damle DK. Oral acyclovir for severe hand, foot and mouth disease. *Indian J Drugs Dermatol* 2018;4:73-5.
39. Gopalkrishna V, Ganorkar NN. Epidemiological and molecular characteristics of circulating Coxsackievirus A16 (CVA16), Coxsackievirus A6 (CVA6) strains and genotype distribution in hand, foot and mouth disease (HFMD) cases in 2017-18 from Western India. *J Med Virol* 2021;93:3572-80.
40. Saoji VA. Hand, foot and mouth disease in Nagpur. *Indian J Dermatol Venereol Leprol* 2008;74:133-5.
41. Kumar VS, Budur SV, Odappa GH, Bankolli SY, Rao AP. Clinical profile of hand, foot, and mouth disease and its associated complications among children in Shimoga City, southern Karnataka: A hospital based study. *Indian J Public Health* 2015;59:141-4.
42. Sinha DP, Raut CG, Jayaprakash H, Hanumaiah H, Shaikh NJ, Manjunatha MJ. Molecular diagnosis of enteroviruses associated with hand, foot and mouth disease (HFMD). *Indian J Pediatr* 2014;81:1242.
43. Durga RC, Jagadeesh NR, Padmanabha MP, Ananda Babu M, Jean-Luc B. Large-scale HFMD epidemics caused by coxsackievirus A16 in Bangalore, India during 2013 and 2015. *Infect Genet Evolution* 2017;55:228-35.
44. Rao PK, Veena KM, Jagadishchandra H, Bhat SS, Shetty SR. Hand, foot and mouth disease: Changing Indian scenario. *Int J Clin Pediatr Dent* 2012;5:220-2.
45. Rao R, Hegde S, Suvarna R, Babu S. Hand foot and mouth disease: A case report from India. *J Cranio Max Dis* 2013;2:75-8.
46. Kashyap R-R, Kashyap RS. Hand, foot and mouth disease - a short case report. *J Clin Exp Dent* 2015;7:e336-8.
47. Sankar AJS, Samatha Y, Ravi Kiran A, Poornachandra N. Hand foot and mouth disease. *J Bioengineer Biomed Sci* 2015;5:137.
48. Vani T, Nageswaramma S, Mudavath SR, Ranen DR, Kumar BS, Sagar GP. Clinico-epidemiological study of hand foot & mouth disease. *Nat J Res Commun Med* 2019;8:70-3.
49. Muppa R, Bhupatiraju P, Duddu M, Dandempally A. Hand, foot and mouth disease. *J Indian Soc Pedod Prev Dent* 2011;29:165-7.
50. Kumar KB, Kiran AG, Kumar BU. Hand, foot and mouth disease in children: A clinico epidemiological study. *Indian J Paediatr Dermatol* 2016;17:7-12.
51. Nagaraju K, Pushkar R, Regalla RR. A Clinico epidemiological study of hand, foot and mouth disease in a tertiary care hospital of tribal area. *J Cont Med A Dent* 2019;7:41-4.
52. Mathew B, Thomas S, Velayudhan V, Prasanna R. Hand, foot, and mouth disease in adults: An enigma among diagnosticians - A case series. *J Indian Acad Oral Med Radiol* 2015;27:616-9.
53. Sabitha S, Sasidharanpillai S, Sanjay RE, Binitha MP, Riyaz N, Muhammed K, *et al.* Clinical profile and virology analysis of hand, foot and mouth disease cases from North Kerala, India in 2015–2016: A tertiary care hospital-based cross-sectional study. *Indian J Dermatol Venereol Leprol* 2018;84:328-31.
54. Nagarajan M, Chaithanya IK, Parvez R, Palani S, Maile A, Matta M, *et al.* Atypical presentation of hand foot mouth disease (HFMD) caused by enterovirus serotype Coxsackievirus A6, in India. *J Health Sci* 2019;9:123-6.
55. Vijayaraghavan PM, Chandy S, Selvaraj K, Pulimood S, Abraham AM. Virological investigation of hand, foot, and mouth disease in a tertiary care center in South India. *J Global Infect Dis* 2012;4:153-61.
56. Thumjaa A. Case series of hand foot mouth disease in children. *Int J Contemp Pediatr* 2014;1:14-6.
57. Sivakumar G, Sathesh C, Prasad VS, Ganesh PR. Hand, foot and mouth disease- A case report. *J Nepal Dental Assoc* 2014;14:60-3.
58. Kumar M, Rigvardhan, Bajpai M. An investigation and management of outbreak of hand foot and mouth disease in southern India. *Med Res Chron* 2015;3:115-23.
59. Ganga N. Hand foot and mouth disease like illness in office practice. *Indian J Pediatr* 2017;84:216-8.
60. Pichaachari S, Subramaniam JN, Sundaram S. Onychomadesis associated with hand, foot, and mouth disease: A prospective observational study from North Chennai. *Int J Res Dermatol* 2020;6:367-70.
61. Haarika V, Soma V, Venkatesh C, Gunasekaran D, Sundararajan P, Srinivasan S. Hand Foot and mouth disease in an infant. *Res J Pharm Biol Chem Sci* 2014;5:761-3.
62. Palani S, Nagarajan M, Biswas AK, Reesu R, Paluru V. Hand, foot and mouth disease in the Andaman Islands, India. *Indian Pediatr* 2018;55:408-11.
63. Gilbert GL, Dickson KE, Waters MJ, Kennett ML, Land SA, Sneddon M. Outbreak of enterovirus 71 infection in Victoria, Australia, with a high incidence of neurologic involvement. *Pediatr Infect Dis J* 1988;7:484-8.
64. Blomberg J, Lycke E, Ahlfors K, Johnsson T, Wolontis S, von Zeipel G. New enterovirus type associated with epidemic of aseptic meningitis and/or hand, foot, and mouth disease. *Lancet* 1974;2:112.
65. Ishimaru Y, Nakano S, Yamaoka K, Takami S. Outbreaks of hand, foot, and mouth disease by enterovirus 71: High incidence of complication disorders of central nervous system. *Arch Dis*

- Child 1980;55:583-8.
66. Melnick JL. Enterovirus type 71 infections: A varied clinical pattern sometimes mimicking paralytic poliomyelitis. *Rev Infect Dis* 1984;6(Suppl 2):S387-90.
 67. Alexander JP, Baden L, Pallansch MA, Anderson LJ. Enterovirus 71 infections and neurologic disease: United States, 1977–1991. *J Infect Dis* 1994;169:905-8.
 68. da Silva EE, Winkler MT, Pallansch MA. Role of enterovirus 71 in acute flaccid paralysis after the eradication of poliovirus in Brazil. *Emerg Infect Dis* 1996;2:231-3.
 69. Tang J-H, Chan T-C, Shigematsu M, Hwang J-S. Latitude-based approach for detecting aberrations of hand, foot, and mouth disease epidemics. *BMC Med Inform Decis Mak* 2015;15:113.
 70. Hii YL, Rocklov J, Ng N. Short term effects of weather on hand, foot and mouth disease. *PLoS One* 2011;6:e16796.
 71. Blomqvist S, Klemola P, Kaijalainen S, Paananen A, Simonen M-J, Vuorinen T, *et al.* Co-circulation of coxsackieviruses A6 and A10 in hand, foot and mouth disease outbreak in Finland. *J Clin Virol* 2010;48:49-54.
 72. Onozuka D, Hashizume M. The influence of temperature and humidity on the incidence of hand, foot, and mouth disease in Japan. *Sci Total Environ* 2011;410:119-25.
 73. Harvell J, Selig D. Seasonal variations in dermatologic and dermatopathologic diagnoses: A retrospective 15-year analysis of dermatopathologic data. *Int J Dermatol* 2016;55:1115-8.
 74. Kim BI, Ki H, Park S, Cho E, Chun BC. Effect of climatic factors on hand, foot, and mouth disease in South Korea, 2010-2013. *PLoS One* 2016;11:e0157500. doi: 10.1371/journal.pone.0157500.
 75. Chen K-T, Chang H-L, Wang S-T, Cheng Y-T, Yang J-Y. Epidemiologic features of hand-foot-mouth disease and herpangina caused by enterovirus 71 in Taiwan, 1998-2005. *Pediatrics* 2007;120:e244-52.
 76. World Health Organization (WHO). Hand, foot and mouth disease. 2012 Available from: http://www.wpro.who.int/mediacentre/factsheets/fs_10072012_HFMD/en/. [Last accessed on 2019 Dec 01].
 77. Seiff A. Cambodia unravels cause of mystery illness. *Lancet* 2012;380:205. doi: 10.1016/s0140-6736(12)61200-8.

Supplementary Table-S1: HFMD cases reported from various states and regions (arranged from north to south) of India

Ref No.	Reference Citation (type of study)	State & UTs (number of cases)	Regions (number of cases)	Year(s) of outbreak	Number of cases				Results of viral studies (if any)	Remarks
					2 mo-3yr	>3-5yr	>5-12yr	>12-18yr		
18	IDSP-NCDC-2018 (Information communication)	Jammu & Kashmir (300)	Baramulla (300)	May 2018	300 (approx)	-	-	-	ND	-
19	IDSP-NCDC-2018 JK/LDK/2016/18/981	Ladakh (537)	Leh (76)	May 2016	76	-	-	-	ND	-
20	Kadri et al 2019 (case series)	Himachal Pradesh (51)	Leh (461)	April-June 2016	104	-	354	-	ND	-
17	Melita et al 2010 (case report)	Himachal Pradesh (51)	Kangra (1)	June 2009	-	-	1	-	ND	-
21	Kashyap and Verma 2014 (case series)	Himachal Pradesh (51)	Shimla (47)	July-August 2013	-	-	36	6	ND	-
22	Sharma and Manvi 2018 (case series)	Himachal Pradesh (51)	Solan (3)	Aug-Nov 2017	-	-	-	1	ND	Adults were contacts of children
23	Agarwal et al 2015 (case series)	Rajasthan (38)	Udaipur (38)	July-Sept 2012	-	-	38	-	ND	-
24	Nanda, et al 2015 (case series)	Uttarakhand (330)	Dehradun (33)	Aug-Oct 2013	-	25	7	1	ND	-
25	Sahota et al 2020 (case series)	West Bengal (338)	Kashipur (297)	2015-2019	89	171	30	7	ND	Adults were contacts of children
13	Sarma et al 2009 (case report)	West Bengal (338)	Bally, Hooghly, and Howrah (38)	Aug-Oct 2007	22	9	7	-	ND	-
26	Ghosh et al 2010 (case series)	West Bengal (338)	Kolkata (62)	June-Aug 2009	-	-	60	2	ND	10 patients were secondary contacts
27	Sarma 2013 (case series)	West Bengal (338)	Kolkata (89)	June 2010 and 2011	6 weeks-32 years (mean 8 years)	3 patients were aged >25 years	-	-	ND	One adult had more severe disease than children. 4 children <6 years had relapsed
28	Nag et al 2016 (case series)	West Bengal (338)	Siliguri (87)	July-Dec 2014	6 mo-1.5 yr = 87	-	-	-	Coxsackie virus (CV) A16 antibody detected in 6 of 11 patients tested by CFT	23(33.8%) patients developed late cutaneous and nail changes
29	Sarma et al 2017 (original report)	West Bengal (338)	Kolkata (62)	Jul-Nov in 2013, 2014, 2015	-	-	62	-	CV A6, CVA16, Enterovirus (EV) 71 identified in 40 of 62 cases by RT-PCR studies for viral RNA	5 patients had previous history of HFMD in past 1-5 years. No correlation was observed with type of virus and clinical severity/course of HFMD
30	Arora et al 2008 (case series)	Assam (44)	Jorhat (34)	Aug-Sept 2007	31	-	3	-	ND	12 patients were siblings
31	Borkakoty et al 2020 (virology investigative study)	Assam (44)	Dibrugarh and Tezpur (10)	2014	-	-	6	4	CV A6, CVA16, identified in 6 of 10 cases by RT-PCR studies for viral RNA	>1000 cases were found in the years 2014 and 2015 on retrospective analysis of hospital records
32	Singh et al 2016 (case series)	Gujarat (8)	Karamsad (8)	Not mentioned	2-16 yr = 8	-	-	-	ND	-
33	Kar et al 2013 (community survey and hospital cases series)	Odisha (78)	Bhubaneswar (78)	Sept-Nov 2009	-	44	32	-	CV A6, identified in 7 cases by RT-PCR studies for viral RNA	-
34	Sane et al 2009 (prospective study)	Maharashtra (264)	Mumbai (Thane) (103)	Aug-Nov 2006	4 mo-6 yr = 103	-	-	-	ND	Febrile convulsion in one case, Palmoplantar exfoliation in 12.6% cases, Late nail changes in 35 children
35	Dharmapalan et al 2019 (research letter)	Maharashtra (264)	Mumbai (Navi Mumbai) (15)	Sept-Oct 2018	aged up to 18 yr = 15	-	-	-	CV-A6 in 10, CV-A16 in 3 cases identified from stool, vesicle fluid and/or throat swabs by RT-PCR studies for viral RNA	Recurrence occurred within 1 month in 2 patients; one each with CV A6 and EV 71 infection. The later child was vaccinated twice against EV 71 a year back
36	Saxena et al 2020 (investigative, short communication)	Maharashtra (264)	Mumbai (7)	May-Jun 2018	9 mo-5 yr = 7	-	-	-	CV-A6 in 5, CV-A16 in 2 cases identified from stool samples by RT-PCR studies for viral RNA	Recurrence noted within 3 weeks in one case
37	Ganofkar et al 2017 (virology investigative study)	Maharashtra (264)	Pune and Ahmedabad (64)	2012-2014	5 mo-10 yr = 64	-	-	-	CV A16, CVA6, CVA4 and Echo12 strains identified by RT-PCR studies for viral RNA (158 clinical samples studied for genotyping of virus causing HFMD)	These CV-A16 strains exhibited 97-99% sequence identity with those reported in Japan and China. The CV-A6 strains exhibited 98-99% sequence identity with those reported in Finland, Taiwan and China.
38	Damle 2018 (Case series)	Maharashtra (264)	Pune (3)	Not mentioned	3	-	-	-	ND	Treated successfully with oral acyclovir (10 mg/kg/dose 4 times/d for 7 days)

39	Gopal Krishna and Ganekar 2020 (epidemiological and Virology study)		Pune and Kolhapur (68)	2017-2018	1 mo-10yr = 68	-	-	-	CV-A16, CVA-6, Echo1 types (EV-A and EV-B species) strains identified by RT-PCR studies for viral RNA (93 throat swab, vesicular fluid and stool samples)	These CV-A16 and CV-A6 strains exhibited 96-99% sequence identity with Indian strains.
40	Saoji 2008, (case series)		Nagpur (4)	Sept 2005-April 2006	-	4	-	-	ND	-
41	Kumar et al 2015 (observational study)	Karnataka (515)	Shimoga City (2/6)	Mar-Aug 2013	217	45	14	-	ND	-
42	Sinha et al 2014 (virology study letter)		Bangalore (7)	Sept-Nov 2013	-	7	-	-	CV-A16 identified in 2 cases by RT-PCR studies for viral RNA	-
43	Durga et al 2017 (virology study)		Bangalore (229)	2013-2015	153	76	-	-	CV-A16 identified in 189 cases by RT-PCR studies for viral RNA	These CV-A16 strains exhibited 98-99% sequence identity with those reported in France and China
44	Rao et al 2012 (case report)		Mangalore (1)	Not mentioned	1	-	-	-	ND	-
45	Rao et al 2012 (case report)		Mangalore (1)	Not mentioned	-	-	1	-	ND	-
46	Kashyap et al 2015 (case report)		Mangalore (1)	Not mentioned	1	-	-	-	ND	-
47	Sankar et al 2015 (case report)	Andhra Pradesh (71)	Guntur (1)	Not mentioned	1	-	-	-	ND	-
48	Vani et al 2019 (observational study)		Guntur (70)	Oct 2017-Apr 2018	15	51	4	-	ND	80% patients had history of contact with HFMD patients
49	Muppa et al 2011 (case report)		Hyderabad (1)	Not mentioned	-	1	-	-	ND	-
50	Kumar et al 2016 (cross-sectional, observational study)	Telangana (110)	Hyderabad (50)	Aug 2013-Jan 2014	40	-	-	10	ND	80% patients had history of contact with HFMD patients
51	Nagaraju et al 2019 (cross-sectional, observational study)		Adilabad (60)	Jan-Dec 2018	48	5	6	-	ND	-
52	Sasidharan et al 2005 (cross-sectional, observational study)		Calicut and suburbs (81)	Oct 2003-Feb 2004	65	14	2	-	Elevated IgM antibody against EV-71 in 19 patients.	-
53	Sabitha et al 2018 (epidemiological and Virology study)	Kerala (145)	Trivandrum (3)	Not mentioned	0	-	-	-	3	-
54	Nagarajan et al 2019 (case report)		Kozhikode (60)	Sept 2015	38	-	16	1	5	Constitutional symptoms were pronounced in adults
55	Vijayaraghavan et al 2012 (virology investigative study)	Tamil Nadu (255)	Kochoi (1)	Aug 2015	-	-	-	-	1	-
56	Thumja 2014 (case series)		Vellore (30)	Nov-Dec 2005, Jan-Feb 2008	30	-	-	-	-	CV-A-16 identified by nested PCR (78 vesicle fluid swabs samples)
57	Sivakumar et al 2014 (case report)		Chennai (27)	Oct-Nov 2013	8	15	4	-	ND	-
58	Kumar et al 2015 (original hospital based and community survey study)		Chennai (1)	Not mentioned	-	1	-	-	ND	-
59	Ganga 2017		Conoor (101) (Wellington)	2010	<5yr = 83	18	18	-	CV-A-16 identified in 18 of 34-samples by	Aseptic meningitis and Viral pneumonia occurred in one case each
60	Pichaachari et al 2020 (observational study)		Kumbakonam (23)	Oct-Nov 2015	18	3	1	1	ND	One child had severe diarrhea and vomiting
61	Haarika et al 2014 (case report)		North Chennai (73)	Apr-Jun 2018	9mo -12 yr = 73	1	-	-	ND	Onychomadesis and nail shedding occurred in 48.2% children
62	Palani, et al 2018 (hospital based study)		Pillairappam (1)	Not mentioned	1	-	-	-	ND	-
54	Nagarajan et al 2019 (case report)		Port Blair (1)	Sept 2011	-	-	-	-	1	These CV-A16 and CV-A6 strains exhibited sequence identity with strains in mainland India and Malaysia

approx. approximately; CFT, complement fixation test; CV, Coxsackievirus; EV, Enterovirus; HFMD, hand, foot and mouth disease; Ig, immunoglobulin; IDSP-NCD/CDC, Integrated Disease Surveillance Programme, National Centre for Disease Control, Delhi (India); ND, not done; RNA, Ribonucleic acid; RT-PCR, reverse transcriptase polymerase chain reaction, -, none; mo, months; Ref no., Reference number; yr, year; UTs, Union territories

Notes: News paper also reported small outbreaks of HFMD cases between the year 2012 and 2014 from -Delhi, Goa, Srinagar, Arunachal, Meghalaya, Nagaland, Manipur, Tripura, Mizoram, Daman and Diu, Lakshadweep, Punjab, Chandigarh, Haryana, Uttar Pradesh, Bihar, Madhya Pradesh, Chhattisgarh, and Jharkhand