

Seasonal Variation in the Incidence of Malignant Glaucoma after Cataract Surgery

Thomas S. Shute¹, MD; Devesh K. Varma², MD; Diamond Tam², MD; Thomas Klein², MD; Prima Moinul³, MD
Iqbal Ike K. Ahmed^{2,4,5}, MD; Arsham Sheybani¹, MD

¹Department of Ophthalmology and Visual Sciences, Washington University, St Louis, MO, USA

²Prism Eye Institute, Department of Ophthalmology and Vision Sciences, University of Toronto, Mississauga, Ontario, Canada

³Department of Ophthalmology, Faculty of Medicine, University of Calgary, Calgary, Alberta, Canada

⁴Department of Ophthalmology and Vision Sciences, University of Toronto, Toronto, Ontario, Canada

⁵Trillium Health Partners, Mississauga, Ontario, Canada

Abstract

Purpose: To investigate a potential link between the incidence of malignant glaucoma after cataract surgery and seasonal variations in daylight.

Methods: In total, 18,374 uncomplicated cataract surgeries were performed between June 2008 and June 2013 at an ambulatory surgery center in Toronto. Toronto’s average monthly daylight over that time period—in hours per day for each month—was determined. The number of malignant glaucoma cases that developed after cataract surgery performed in months with above average daylight was compared to the number of cases that developed after cataract surgery performed in months with below average daylight. Fisher’s exact test was used to analyze the relationship between the development of malignant glaucoma and variation in daylight during the month of cataract surgery.

Results: Malignant glaucoma developed in 16 eyes. Thirteen cases of malignant glaucoma developed in months with above average daylight and three cases developed in months with below average daylight ($P = 0.01$). Eyes that developed malignant glaucoma in months with more daylight were slightly longer (21.95 ± 1.23 mm) than those that developed malignant glaucoma in months with less daylight (21.55 ± 0.88 mm).

Conclusion: Light-induced choroidal expansion may play a major role in the development of malignant glaucoma following cataract surgery.

Keywords: Angle Closure Glaucoma; Aqueous Misdirection; Choroidal Expansion; Malignant Glaucoma; Narrow Angles

J Ophthalmic Vis Res 2019; 14 (1): 32-37

INTRODUCTION

Malignant glaucoma is a challenging entity involving

uniform flattening of the anterior chamber (AC) despite a patent iridotomy in an eye with normal or elevated intraocular pressure (IOP). The term “malignant” denotes an unrelenting course and poor response to traditional glaucoma treatments. Aqueous misdirection, ciliary block glaucoma, ciliolenticular glaucoma, and ciliovitreal block glaucoma are alternative names given

Correspondence to:

Thomas S. Shute, MD. Washington University School of Medicine in St. Louis, 660 South Euclid Ave., Campus Box 8096, St. Louis MO 63110, USA.
E-mail: shutet@wustl.edu

Received: 12-02-2018

Accepted: 16-07-2018

Access this article online

Quick Response Code:



Website:

www.jovr.org

DOI:

10.4103/jovr.jovr_41_18

This is an open access journal, and articles are distributed under the terms of the Creative Commons Attribution-NonCommercial-ShareAlike 4.0 License, which allows others to remix, tweak, and build upon the work non-commercially, as long as appropriate credit is given and the new creations are licensed under the identical terms.

For reprints contact: reprints@medknow.com

How to cite this article: Shute TS, Varma DK, Tam D, Klein T, Moinul P, Ahmed IIK, *et al.* Seasonal variation in the incidence of malignant glaucoma after cataract surgery. *J Ophthalmic Vis Res* 2019;14:32-7.

to the same constellation of clinical findings. While each label hints at a theoretical cause, the etiology of malignant glaucoma remains incompletely understood.

Several hypothetical mechanisms have garnered attention since Von Graefe originally described malignant glaucoma in 1869.^[1] While no single theory clearly establishes a cause, authors agree that the pathophysiology involves accumulation of aqueous within and behind the vitreous. Most recently, Quigley et al postulated that choroidal expansion precipitates malignant glaucoma by creating a substantial posterior-anterior pressure gradient within the eye.^[2] Poor fluid conductivity of the vitreous prevents liquid in the vitreous cavity from achieving the posterior chamber and equalizes this pressure differential. The vitreous, lens, and iris move anteriorly as posterior pressure builds and aqueous is forced out of the AC through the trabecular meshwork.^[2,3]

A relationship between light exposure and iridocorneal angle narrowing has been postulated since the 1960s.^[4] Decades later, avian and primate studies elucidated a central reflexive pathway linking light and choroidal blood flow—a circuit we call the choroidal light reflex.^[5-10]

Here, we present a retrospective case-control study of the incidence of malignant glaucoma in pseudophakic patients after cataract surgery between June 2008 and June 2013 in Toronto, Ontario, Canada. A correlation between malignant glaucoma and seasonal variations in daylight is reported, and a potential mechanism underlying light-induced angle closure—the choroidal light reflex—is explored.

METHODS

Four glaucoma specialists performed 18,374 uncomplicated cataract surgeries at an ambulatory surgery center between June 2008 and June 2013. All procedures involved phacoemulsification and intraocular lens (IOL) implantation into the capsular bag. Ontario billing code E140 was used to determine the number of uncomplicated phacoemulsification each surgeon performed during each month of study. Ethics approval was obtained through the Institutional Review Board Services Ontario (Div. 1373737).

Patient demographics, including age and sex, were recorded. Data obtained preoperatively included axial length (AL), spherical equivalent refraction, and horizontal corneal white-to-white diameter. Complete ocular examination including gonioscopy was performed pre- and postoperatively.

The diagnosis of malignant glaucoma was made using a combination of clinical findings including myopic refractive shift and anterior segment optical coherence tomography (AS-OCT) demonstrating AC shallowing, anterior rotation of the ciliary body, and anterior displacement of the lens-iris diaphragm. B-scan ocular

ultrasound was used to verify absence of choroidal effusion or hemorrhage. AC depth from the corneal endothelium was measured centrally and peripherally 2.0 mm from the limbus using AS-OCT (Visante, Carl Zeiss Meditec AG). The angle was graded 0 to 4 via gonioscopy according to the Shaffer classification system. Presence of synechiae or plateau iris was diagnosed clinically via dynamic compression gonioscopy. Eyes with 180 degrees or more with a grade 1 angle were considered narrow. Those with appositional closure for 180 degrees or more were deemed closed. The contralateral eye was also examined for malignant glaucoma or differences in biometry after cataract surgery.

For eyes with malignant glaucoma, a stepwise treatment approach was followed in accordance with a standard protocol established by the investigators.^[11] If malignant glaucoma did not resolve after the initial step of the protocol, the next was performed within one month. Subsequent interventions were added in sequence as necessary. Briefly, management began with aqueous suppression and cycloplegia, and then neodymium: YAG (Nd:YAG) laser iridodolohyaloidotomy followed by AC reformation with an ophthalmic viscosurgical device (OVD) and IOL pushback. If these interventions did not lead to resolution, surgical iridodolohyaloidovitreotomy was performed. Steps in the treatment protocol were not combined. Refraction and AS-OCT were repeated after each step. Withdrawal of cycloplegics was attempted as early as possible. Upon resolution of malignant glaucoma—defined by stable deepening of the anterior chamber off cycloplegics—no further treatment was undertaken.

Exclusion criteria included complicated cataract surgery and postoperative shallowing of the AC for any reason other than malignant glaucoma. Alternate causes for AC shallowing in this series included pupil block, capsule block syndrome with OVD retained behind the IOL, plateau iris or pseudoplateau phenomenon, marked zonulopathy with anterior iris–lens diaphragm displacement and pseudophacodonesis, and choroidal hemorrhage or effusion. Patients who underwent combined phacoemulsification and glaucoma procedures were also excluded.

The average number of daylight hours per day for each month was calculated using data from the National Research Council of Canada.^[12] Time to onset of malignant glaucoma was defined as the interval between phacoemulsification and diagnosis of malignant glaucoma by tertiary-care glaucoma specialists. The minimum, maximum, mean, and standard deviation of average monthly daylight hours were calculated for malignant glaucoma cases based on the month of surgery.

The number of malignant glaucoma cases that developed in operative months with average or below average daylight was compared to the number of malignant glaucoma cases that occurred in months with

above average daylight. Fisher’s exact test was used to analyze the relationship between hours of daylight and development of malignant glaucoma. ALs were compared between eyes that developed malignant glaucoma during operative months with above or below average hours of daylight.

RESULTS

Monthly averages for daylight in Toronto range from 8.98 hours per day in December to 15.4 hours per day in June, with an average of 12.2 hours per day for all months. Of the 18,374 cataract surgeries performed, 16 eyes developed malignant glaucoma. The mean daylight for all malignant glaucoma cases was 13.47 ± 1.68 hours per day with a range of 9.35 to 15.4 hours per day [Figure 1]. Malignant glaucoma was diagnosed a mean of 3.5 ± 2.7 weeks after cataract surgery.

In total, 9156 cataract surgeries were performed during a month with more than 12.2 hours of daylight per day and 9218 cataract surgeries were performed during a month with fewer than or equal to 12.2 hours of daylight per day. Malignant glaucoma occurred in 13 eyes during months with more than 12.2 hours of daylight per day, while 3 eyes developed malignant glaucoma in months with fewer than or equal to 12.2 hours of daylight per day (*P* = 0.012, odds ratio, 4.36) [Table 1].

All patients who developed malignant glaucoma were women. All eyes that developed malignant glaucoma had been previously diagnosed with narrow angles using the methods outlined above. All patients had preoperative patent PIs. The average AL of eyes that developed malignant glaucoma was 21.88 ± 1.16 mm (range, 19.32 to 24.31). Eyes that developed malignant glaucoma in brighter months were slightly longer than those that developed malignant glaucoma in months with less daylight—21.95 ± 1.23 mm versus 21.55 ± 0.88 mm, respectively [Table 2].

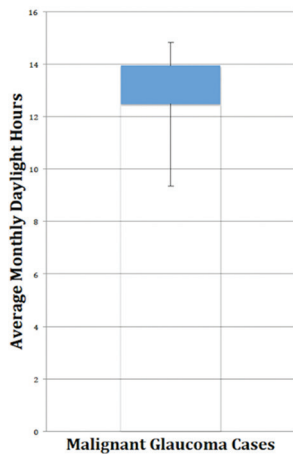


Figure 1. Range of daylight hours for all cases of malignant glaucoma.

DISCUSSION

Malignant glaucoma classically occurs after incisional surgery in eyes predisposed to angle closure with a reported incidence between 0.6 and 4%.^[13-15] It has been described following cataract surgery with or without IOL implantation, pars plana vitrectomy, scleral buckling, laser cyclophotocoagulation, laser capsulotomy, laser suture lysis, and laser peripheral iridotomy.^[16] It is known to occur without clear provocation in unoperated eyes, and bilateral simultaneous cases have been reported.^[16,17] The sheer variety of alleged precipitants and associations has made elucidation of the mechanism responsible for malignant glaucoma difficult.

Quigley et al have suggested that choroidal expansion plays a pivotal role in the pathogenesis of malignant glaucoma by creating a posterior to anterior pressure gradient within the eye.^[2,3] In fact, choroidal expansion has been detected via ultrasound biomicroscopy (UBM) in eyes with malignant glaucoma.^[18,19] Shallowing of the AC as a result of choroidal thickening has been observed with inflammatory and infectious conditions, suprachoroidal hemorrhages, elevated vortex vein pressure, choroidal tumors, nanophthalmos, arterio-venous malformations, and pharmacologic reactions.^[2] Because of its ability to image the ciliary body, lens-iris diaphragm, and posterior chamber, UBM has proven to be a useful adjunct to the clinical examination in cases of suspected malignant glaucoma.^[20]

Table 1. Contingency table for Fisher’s exact test

Daylight	>12.2 hrs	≤12.2 hrs	Total	OR=4.36
MG	13	3		
No MG	9143	9215	18374	<i>P</i> =0.01
	9156	9218		

MG, malignant glaucoma; OR, odds ratio

Table 2. AL for malignant glaucoma cases occurring in operative months with above or below average daylight

Daylight	>12.2 hrs	≤12.2 hrs
AL (mm)	19.32	21.68
	20.89	20.61
	22.36	22.36
	21.71	
	22.53	
	22.33	
	22.63	
	21.9	
	24.31	
	20.69	
	22.53	
	22.9	
	21.27	
Mean±SD	21.95±1.23	21.55±0.88

AL, axial length; hrs, hours; SD, standard deviation

The choroid is responsible for 85% of all ocular blood flow.^[21] A major role for the high flow choroidal vasculature is maintenance of macular temperature. Between 25 and 33% of all light entering the eye is absorbed by the retinal pigment epithelium.^[22,23] A portion of that light energy is converted to heat, which can raise the local retinal temperature above core body temperature. Vos calculated that a rise in retinal temperature of approximately 2 degrees is enough to produce the clinical findings of solar retinopathy.^[24] To mitigate the risk of heat-induced tissue damage, the choroid actively modulates retinal temperature in response to light via a reflexive increase in choroidal blood flow.^[22] This allows convective and conductive heat transfer from the retina to the blood stream, thereby preserving the integrity of the macular architecture.

The neuro-anatomic pathway for the light-induced increase in choroidal blood flow has been studied in pigeons and monkeys.^[5-10] Gamlin et al demonstrated a circuit in pigeons from the supra-chiasmatic nucleus through the contralateral Edinger-Westphal nucleus to the choroid via the ciliary ganglion. Electrical stimulation of this pathway results in increased choroidal blood flow. Other studies have shown that light stimulates the same pathway to produce an increase in choroidal blood flow—the aforementioned choroidal light reflex.^[7,10] Conversely, dim light has been shown to decrease choroidal blood flow, resulting in a posterior shift of the retina and contributing to myopia.^[25] The choroidal light reflex is bilateral, so that a light shined in one eye leads to higher choroidal blood flow in both eyes.^[9,10] This centrally mediated increase in choroidal blood flow in response to light has been observed in humans as well.^[26]

Avian and murine studies have shown that increases in choroidal blood flow result in choroidal thickening.^[10,27,28] If an increase in choroidal thickness plays a pivotal role in angle closure, and light leads to choroidal thickening by raising choroidal blood flow, then eyes exposed to extreme levels of light should develop angle closure. Smith, Becker, and Podos showed that this was indeed the case in 1969. Domestic fowl raised under constant incandescent light developed angle closure and buphthalmos within the first month of life.^[4] The investigators concluded that light—by some unknown mechanism—induced angle closure, which secondarily raised IOP. Importantly, administration of acetazolamide prevented a rise in IOP, but did not alter the shallowing of the AC or narrowing of the angle in response to continuous light, indicating that this occurred as a result of an aqueous-independent mechanism. Lauber had previously shown that unilateral ocular occlusion of chicks reared in continuous light did not prevent the development of angle closure and buphthalmos in the

occluded eye.^[29] This discovery was initially attributed to an elusive systemic process. The studies discussed above suggest that choroidal thickening as a result of the bilateral choroidal light reflex is responsible for the angle closure and elevated IOP observed in the domestic fowl experiments from the 1960s.

A prior study from Croatia analyzed the incidence and seasonal variation of acute primary angle closure glaucoma in hospitalized patients.^[30] While no seasonal association was discovered, the sole inclusion criterion was treatment by laser or surgical iridectomy for acute primary angle closure glaucoma. Since only treated cases of acute angle closure were analyzed, any eye with simple angle narrowing would not have been identified. UBM and gonioscopy were not performed, so alterations in anterior segment configuration below the threshold of an angle closure attack could not have been discovered. A 1985 study from Israel found a higher incidence of acute angle closure glaucoma in the summer and winter months.^[31] As with the more recent Croatian study, the primary focus of the investigation was acute angle closure glaucoma rather than a seasonal change in anterior segment configuration. It is plausible that eyes with normal dimensions would experience angle narrowing without progression to acute primary angle closure glaucoma in months with more mean daylight.

In the current series, the incidence of malignant glaucoma was significantly higher in eyes that underwent cataract surgery in months with more hours of daylight. The odds of developing malignant glaucoma after having cataract surgery in brighter months were more than 4 times those of developing malignant glaucoma in months with less daylight. Since the overall number of malignant glaucoma cases was small, the odds ratio calculated here is unlikely to represent the actual effect daylight has on an individual's risk of developing malignant glaucoma in a given month.

Shorter eyes developed malignant glaucoma in months with less daylight, while more daylight was associated with the development of malignant glaucoma in longer eyes. This is significant since choroidal expansion is expected to have a more pronounced effect in shorter eyes with less intraocular space to spare. Longer eyes should have a higher tolerance for choroidal expansion given their larger physiologic reserve. Malignant glaucoma developing in longer eyes after cataract surgery in months with comparatively more daylight is consistent with light-induced choroidal expansion as a precipitating factor.

The higher incidence of malignant glaucoma after cataract surgery performed in months with more daylight combined with the finding that shorter eyes develop malignant glaucoma in months with relatively less daylight supports the light-induced

choroidal expansion theory of angle closure. Additionally, the mechanism proposed here may explain why malignant glaucoma can occur bilaterally and why it has been reported in unoperated eyes or eyes that have undergone seemingly innocuous procedures.

Undoubtedly, there are confounders in this study, including the number of hours per day each patient was exposed to sunlight in the weeks following cataract surgery, whether sunglasses were worn, pupillary size, severity of postoperative inflammation, and type of IOL inserted. A 1988 study of Cheasepeake Bay waterman found that factors such as facial anatomy and occupation also affects ocular exposure to sunlight.^[32] Future investigations should be designed to address the behavioral aspects of sunlight exposure to more clearly elucidate the relationship between light and angle closure.

These data suggest a potentially important link between light and malignant glaucoma. When combined with earlier studies demonstrating that light leads to choroidal thickening, it becomes apparent that light may play a critical role in forms of angle closure beyond malignant glaucoma. More studies are needed to further assess the role of light in angle closure.

Disclosure statement: This research did not receive any specific grant from funding agencies in the public, commercial, or not-for-profit sectors. No author has financial interest in any material or method discussed.

Financial Support and Sponsorship

This research did not receive any specific grant from funding agencies in the public, commercial, or not-for-profit sectors. No author has financial interest in any material or method discussed.

All authors meet authorship criteria. All have read and approved this manuscript.

Conflicts of Interest

There are no conflicts of interest.

REFERENCES

1. von Graefe A. Beltrage zur pathologie und therapie des glaucomas. *Albert von Graefe Arch Ophthalmol* 1869;15:108.
2. Quigley HA, Friedman DS, Congdon MG. Possible mechanisms of primary angle-closure and malignant glaucoma. *J Glaucoma* 2003;12:167-180.
3. Quigley HA. Angle-closure glaucoma-simpler answers to complex mechanisms. LXVI Edward Jackson Memorial Lecture. *Am J Ophthalmol* 2009;148:657-669.
4. Smith ME, Becker B, Podos S. Light-induced angle-closure glaucoma in the domestic fowl. *Invest Ophthalmol* 1969;8:213-221.
5. Gamlin PD, Reiner A, Karten HJ. Substance P-containing neurons of the avian supra-chiasmatic nucleus project directly to the nucleus of Edinger-Westphal. *Proc Natl Acad Sci* 1982;79:3891-3895.
6. Reiner A, Fitzgerald MEC, Gamlin PDR. Central neural circuits controlling choroidal blood flow: A laser Doppler study. *Invest Ophthalmol Vis Sci* 1990;31:2483-2492.
7. Fitzgerald MEC, Reiner A. Light-mediated reflexive control of choroidal blood flow in the pigeon eye. *Neurosciences* 1990 (Abs).
8. Auker CR, Parver LM, Doyle T, Carpenter DO. Choroidal blood flow: I. Ocular tissue temperature as a measure of flow. *Arch Ophthalmol* 1982;100:1323-1326.
9. Parver LM, Auker CR, Carpenter DO, Doyle T. Choroidal blood flow: II. Reflexive control in the monkey. *Arch Ophthalmol* 1982;100:1327-1330.
10. Fitzgerald ME, Gamlin PD, Zagvazdin Y, Reiner A. Central neural circuits for the light-mediated reflexive control of choroidal blood flow in the pigeon eye: A laser Doppler study. *Vis Neurosci* 1996;13:655-669.
11. Varma DK, Belovay GW, Tam DY, Ahmed II. Malignant glaucoma after cataract surgery. *J Cataract Refract Surg* 2014;40:1843-1849.
12. National Research Council of Canada website: <http://www.nrc-cnrc.gc.ca/eng/services/sunrise/advanced.htm>. [Last accessed on 2016 Aug].
13. Chandler PA, Simmons RJ, Grant M. Malignant glaucoma. Medical and surgical treatment. *Am J Ophthalmol* 1968;66:495-502.
14. Simmons RJ. Malignant glaucoma. *Br J Ophthalmol* 1972;56:263-272.
15. Lowe RF. Malignant glaucoma related to primary angle closure glaucoma. *Aust J Ophthalmol* 1979;7:11-18.
16. Foreman-Larkin J, Netland PA, Salim S. Clinical management of malignant glaucoma. *J Ophthalmol* 2015;2015:283707.
17. Feng L, Roufas A, Healey PR, White AJ. Bilateral spontaneous aqueous misdirection: It can happen! *Clin Exp Ophthalmol* 2015;43:771-773.
18. Liebmann JM, Weinreb RN, Ritch R. Angle-closure glaucoma associated with occult annular ciliary body detachment. *Arch Ophthalmol* 1998;116:731-735.
19. Dugel PU, Heuer DK, Thach AB, Baerveldt G, Lee PP, Lloyd MA, et al. Annular peripheral choroidal detachment simulating aqueous misdirection after glaucoma surgery. *Ophthalmology* 1997;104:439-444.
20. Kaplowitz K, Yung E, Flynn R, Tsai JC. Current concepts in the treatment of vitreous block, also known as aqueous misdirection. *Surv Ophthalmol* 2015;60:229-241.
21. Alm A, Bill A. Ocular and optic nerve blood flow at normal and increased intraocular pressures in monkeys. *Exp Eye Res* 1973;15:15-29.
22. Parver LM, Auker C, Carpenter DO. Choroidal blood flow as a heat dissipating mechanism in the macula. *Am J Ophthalmol* 1980;89:641-646.
23. Parver LM. Temperature modulating action of choroidal blood flow. *Eye* 1991;5:181-185.
24. Vos JJ. A theory of retinal burns. *Bull Math Biophys* 1962;24:115-128.
25. Wallman J, Wildsoet C, Xu A, Gottlieb MD, Nickla DL, Marran L, et al. Moving the retina: Choroidal modulation of refractive state. *Vision Res* 1995;35:37-50.
26. Parver LM, Auker CR, Carpenter DO. Choroidal blood flow: III. Reflexive control in human eyes. *Arch Ophthalmol* 1983;101:1604-1606.
27. Fitzgerald ME, Wildsoet CF, Reiner A. Temporal relationship of choroidal blood flow and thickness changes during recovery from form deprivation myopia in chicks. *Exp Eye Res* 2002;74:561-570.
28. Berkowitz BA, Schmidt T, Podolsky RH, Roberts R. Melanopsin phototransduction contributes to light-evoked choroidal expansion and rod l-type calcium channel function *in vivo*. *Invest Ophthalmol Vis Sci* 2016;57:5314-5319.
29. Lauber JK, McGinnis J, Boyd J. Influence of miotics, diamox, and vision occluders on light-induced buphthalmos in domestic fowl.

- Proc Soc Exper Biol Med* 1965;120:572-575.
30. Ivanisević M, Erceg M, Smoljanović A, Trošić Z. The incidence and seasonal variations of acute primary angle-closure glaucoma. *Coll Antropol* 2002;26:41-45.
31. David R, Tessler Z, Yassur Y. Epidemiology of acute angle-closure glaucoma: Incidence and seasonal variations. *Ophthalmologica* 1985;191:4-7.
32. Taylor HR, West SK, Rosenthal FS, Muñoz B, Newland HS, Abbey H, et al. Effect of ultraviolet radiation on cataract formation. *N Engl J Med* 1988;319:1429-1433.