

**CASE REPORT**

# Vaccine-induced prothrombotic immune thrombocytopenia without thrombosis may not require immune modulatory therapy: A case report

Chieh Min Benjamin Lai MD, PhD, FRCPC  | Agnes Y.Y. Lee MD, MSc, FRCPC   |  
Stephen B.I. Parkin MD, FRCPC 

Division of Hematology, University of British Columbia, Vancouver, British Columbia, Canada

**Correspondence**

Stephen B.I. Parkin, 2775 Laurel St, 10th Floor, Vancouver General Hospital, Vancouver, British Columbia V5Z1M9, Canada.  
Email: [stephen.parkin@bccancer.bc.ca](mailto:stephen.parkin@bccancer.bc.ca)

**Funding information**

No funding was received for this work.

**Handling Editor:** Pantep Angchaisuksiri

**Abstract**

**Background:** Vaccine-induced immune thrombotic thrombocytopenia (VITT) is a rare complication of the ChAdOx1 nCoV-19 and Ad26.COV2.S COVID-19 vaccines. It presents most commonly with severe thrombocytopenia and thrombotic complications with extremely high D-dimer levels 5–30 days after vaccination. We report a patient who presented with mild thrombocytopenia and minimally elevated D-dimer levels without thrombosis, but who tested positive for antiplatelet factor 4 (PF4) platelet-activating antibodies on a PF4-enhanced serotonin-release assay.

**Key Clinical Question:** Is immunomodulation necessary in patients who present without thrombosis?

**Clinical Approach and Conclusions:** Treatment with rivaroxaban alone was followed by platelet normalization despite persistence of anti-PF4 antibodies. This case provides support that vaccination for COVID-19 can induce a broad, heterogeneous prothrombotic disorder characterized by anti-PF4 platelet-activating antibodies that shares features with classical heparin-induced thrombocytopenia (HIT) and autoimmune HIT syndromes and that immunomodulation may not be required in those without thrombosis.

**KEYWORDS**

ChAdOx1 nCoV-19, COVID-19 vaccines, platelet factor 4, thrombocytopenia, thrombosis

**Essentials**

- Vaccine-induced prothrombotic immune thrombocytopenia (VIPIT) can occur without thrombosis.
- VIPIT without clot can occur with elevated D-dimer and platelet-activating anti-PF4 antibodies.
- VIPIT without thrombosis was treated successfully with non-heparin anticoagulant therapy alone.
- VIPIT can present as asymptomatic platelet activation to fulminant coagulopathy.

This is an open access article under the terms of the [Creative Commons Attribution-NonCommercial-NoDerivs](https://creativecommons.org/licenses/by-nc-nd/4.0/) License, which permits use and distribution in any medium, provided the original work is properly cited, the use is non-commercial and no modifications or adaptations are made.

© 2022 The Authors. *Research and Practice in Thrombosis and Haemostasis* published by Wiley Periodicals LLC on behalf of International Society on Thrombosis and Haemostasis (ISTH).

## 1 | INTRODUCTION

Vaccine-induced immune thrombotic thrombocytopenia (VITT) is a well-recognized but rare hypercoagulable condition following administration of the ChAdOx1 nCoV-19 or Ad26.COV2.S vaccines.<sup>1</sup> Patients usually present 5–30 days after vaccination, with moderate to severe thrombocytopenia, marked D-dimer elevation, and venous and/or arterial thrombosis.<sup>1,2</sup> Atypical cases have been reported that present initially without thrombosis.<sup>3–6</sup> These latter presentations may be better described as vaccine-induced prothrombotic immune thrombocytopenia (VIPIT), a broader term that was first proposed to describe this novel syndrome and a term that would include cases with thrombosis (i.e., VITT) and also those without thrombosis.<sup>7,8</sup> The recommended treatment for VIPIT/VITT is anticoagulation with a nonheparin anticoagulant plus immunomodulation with intravenous immunoglobulin (IVIg), with or without corticosteroid therapy.<sup>1,2,9</sup>

Like in heparin-induced thrombocytopenia (HIT), the pathognomonic feature of VIPIT/VITT is the presence of platelet-activating anti-platelet factor 4 (PF4) antibodies.<sup>9,10</sup> However, unlike HIT, VIPIT/VITT antibodies occur in the absence of heparin exposure and have a distinct epitope binding site on PF4.<sup>11</sup> These features make VIPIT/VITT more similar to autoimmune HIT, a spectrum of disorders in which anti-PF4 antibodies are also capable of activating platelets in the absence of heparin and can lead to fulminant coagulation activation through platelet microparticle release and neutrophil extracellular trap formation (NETosis).<sup>1,12,13</sup> Furthermore, a recommended treatment for VIPIT/VITT and autoimmune HIT, including the rare instances of severe or refractory HIT, is IVIg, which is not required in classical HIT.<sup>2,14</sup>

Here, we report a case of serotonin-release assay (SRA)-confirmed VIPIT without thrombosis who was treated successfully with nonheparin anticoagulant therapy alone. This case further expands our understanding of VIPIT and the similarities and contrasts with other anti-PF4 antibody syndromes.

## 2 | CASE DESCRIPTION

A male patient in his late 30s received a first dose of ChAdOx1 nCoV-19 vaccine and developed mild symptoms that fully resolved within 24 h. On day 9 postvaccination, he was found to have incidental, isolated thrombocytopenia with platelets of  $82 \times 10^9/L$  and he was clinically well. His previous platelet count was  $192 \times 10^9/L$  in 2018.

Repeat blood work on day 17 showed worsening thrombocytopenia with platelets of  $69 \times 10^9/L$  and elevation of D-dimer at 1156 ng fibrinogen equivalent units (FEU)/ml (reference range <500 ng FEU/ml). He was directed to the emergency room for suspected VIPIT. His vital signs were normal and his physical examination, including a neurological examination, was unremarkable. Other blood work including peripheral blood film, renal and hepatic function tests, prothrombin time, partial thromboplastin time, and fibrinogen were normal. Computed tomography venography of

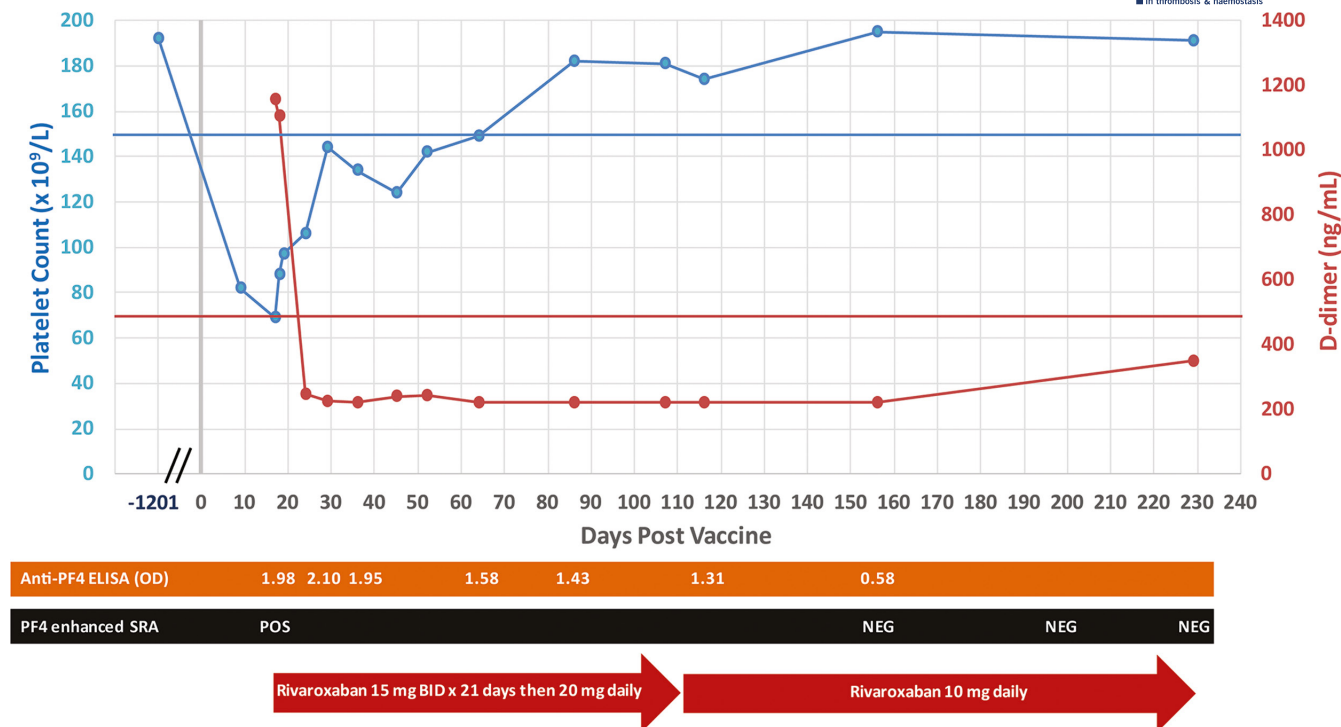
the head, computed tomography pulmonary angiography, and bilateral lower limb Doppler ultrasonography showed no evidence of thrombosis. Enzyme-linked immunosorbent assay (ELISA) for anti-PF4 antibodies (ImmuCor PF4 IgG assay) was positive (optical density [OD] 1.98) and the presence of platelet-activating anti-PF4 antibodies was confirmed later with PF4-enhanced SRA performed at a reference laboratory in Hamilton, Canada.<sup>15</sup> No other cause for thrombocytopenia, including heparin or SARS-CoV-2 exposure, was identified.

After a thorough discussion of the potential diagnosis of VIPIT and the risks and benefits of treatment with the patient, he was started empirically on therapeutic rivaroxaban on day 18. Neither IVIg nor corticosteroid therapy was administered because he had no thrombotic complications. Additionally, the SRA was not readily available at our center and we questioned if the anti-PF4 ELISA gave a false-positive result because his D-dimer level was only mildly elevated. The thrombocytopenia slowly improved, and the platelet count reached  $149 \times 10^9/L$  on day 64, whereas his D-dimer level normalized by day 24 (Figure 1). At 3 months, because anti-PF4 antibodies were still detectable by anti-PF4 ELISA (OD 1.43), rivaroxaban was continued but the dose was reduced to 10 mg daily. At the last follow-up on day 230, he remained asymptomatic with a negative PF4-enhanced SRA result. Rivaroxaban was discontinued. Thrombosis or relapsed thrombocytopenia did not occur during extended follow-up.

## 3 | RESULTS AND DISCUSSION

We report a rare case of SRA-confirmed VIPIT treated with factor Xa inhibition alone (without the use of immune modulatory therapy such as IVIg or corticosteroids) with complete recovery without thrombosis on long-term follow-up. Our case further highlights the clinical and pathophysiological features shared by VIPIT/VITT, autoimmune HIT, and classical HIT, and raises the question whether other VIPIT cases can be treated successfully with nonheparin anticoagulant therapy alone in patients presenting initially without thrombosis.<sup>1,16</sup>

The molecular pathophysiology of VIPIT/VITT is now better understood.<sup>1,10</sup> Investigators have shown that analogous to HIT, in which heparin binding to PF4 initiates anti-PF4 antibody production, VIPIT/VITT is triggered by the binding of polyanionic adenoviral vaccine components to PF4.<sup>10</sup> This immune complex generates the formation of a neoepitope on PF4, which then initiates anti-PF4 VIPIT/VITT antibody production. Experiments have further suggested that viral proteins and small molecules in adenoviral COVID-19 vaccines can act as “danger signals” to promote inflammation. Consequential platelet, granulocyte, and monocyte activation by anti-PF4 VIPIT/VITT antibodies via FcγRIIIa binding then causes platelet microparticle release and NETosis, culminating in fulminant activation of coagulation.<sup>10</sup> Clinically, this manifests as VITT, with multiple sites of venous and/or arterial thrombosis, severe thrombocytopenia from consumption and extremely high levels of D-dimer.



**FIGURE 1** Laboratory findings of a patient with VIPIT without thrombosis. The patient was incidentally noted to have isolated thrombocytopenia 9 days following vaccination with the ChAdOx1 nCoV-19 vaccine. Repeat testing 1 week later showed worsening thrombocytopenia, elevated D-dimer, and positive anti-PF4 ELISA and SRA assays. At that time, therapeutic dose rivaroxaban was started with subsequent normalization of D-dimer and improvement in platelet count, but with persistent anti-PF4 ELISA positivity. Abbreviations: ELISA, enzyme-linked immunosorbent assay; NEG, negative; OD, optical density; PF4, platelet factor 4; POS, positive; SRA, serotonin-release assay; VIPIT, vaccine-induced prothrombotic immune thrombocytopenia

We propose three hypotheses for the lack of thrombosis in our patient. The first possibility is that detection occurred at an early stage when circulating VIPIT antibodies were just starting to induce platelet activation and consumption, and therapeutic anticoagulation prevented development of macrovascular thrombosis. The normalization of the D-dimer level before platelet recovery indicated that fibrin clot formation was effectively suppressed despite ongoing platelet activation with consumption. Others have reported such “pre-VITT” or “early VIPIT” cases but our case did not progress to thrombosis despite withholding immunosuppressive therapy.<sup>3,5,6</sup>

Second, our patient may have had a subclinical phenotype of VIPIT. Such a category has been described in the HIT iceberg model.<sup>17</sup> In this model, some patients have anti-PF4 antibodies capable of activating platelets but are subclinical because they do not present with thrombocytopenia and/or thrombosis. In our patient, thrombocytopenia was identified initially at day 9 through blood work that was done for an unrelated reason. The lack of progression to VITT by day 17 may be due to inadequate “danger signals” related to the vaccine or host factors such as inflammation. According to Greinacher and colleagues, this is an essential step in the development of VITT.<sup>10</sup> Because we intervened with therapeutic anticoagulation, we do not know if the patient would have developed symptoms or recovered without intervention. The high anti-PF4 ELISA OD value (1.98), positive PF4-enhanced SRA, and the timing after ChAdOx1 nCoV-19

vaccination distinguishes our case from those with nonpathological anti-PF4 antibodies following vaccination.<sup>18,19</sup>

The third hypothesis is that our patient has a variant of VIPIT antibody with different epitope-binding sites than those that lead to VITT, and that such differences influence the severity of disease. Indeed, it has been shown in HIT that five amino acids on PF4 are vital to the binding of pathogenic anti-PF4 antibodies and that they are not involved in nonpathogenic antibodies.<sup>20</sup> The same investigators also demonstrated that in autoimmune or delayed HIT, anti-PF4 antibodies are heparin-independent and the epitopes involve an additional set of amino acids at a separate conformational site.<sup>11</sup> Notably, this separate site is very similar to the anti-PF4 antibody binding site reported in VITT.<sup>11</sup> Given the more benign course experienced by our patient, it is possible that his antibody binds to yet a different site or with a lower avidity than VITT antibodies. Further molecular studies are needed to test this hypothesis.

Our patient was treated with empiric therapeutic anticoagulation, in line with guideline recommendations to administer therapeutic anticoagulation in patients with HIT without thrombosis because of their significant hypercoagulable state.<sup>16</sup> His therapeutic response with rapid D-dimer level normalization suggests that inhibition of factor Xa alone was sufficient to suppress thrombin generation that would have provided positive feedback on the coagulation cascade. The gradual rise in his platelet count along with slow attenuation of the anti-PF4 ELISA OD likely reflects the *in vivo* resolution of the

anti-PF4 VITT antibody over a 2-month period. It is possible that platelet recovery could have been accelerated with IVIG treatment.

This case highlights the clinical spectrum of anti-PF4 antibody syndromes, including classic HIT, autoimmune HIT and VIPIT/VITT, and challenges our understanding of their pathophysiological mechanisms. The role of anticoagulation without immunomodulation in those presenting without thrombosis should be further explored.

## AUTHOR CONTRIBUTIONS

Stephen B. I. Parkin provided direct patient care. Chieh M. B. Lai, Agnes Y. Y. Lee, and Stephen B. I. Parkin wrote the manuscript.

## ACKNOWLEDGMENTS

We thank Steven Wong for direct laboratory technical support.

## RELATIONSHIP DISCLOSURE

Stephen B. I. Parkin has received honoraria from Celgene and Janssen. Agnes Y. Y. Lee has received honoraria from Bayer, BMS, LEO Pharma, Pfizer, and Servier. Chieh M. B. Lai declared no conflicts of interest.

## ORCID

Chieh Min Benjamin Lai  <https://orcid.org/0000-0002-4130-9413>

Agnes Y.Y. Lee  <https://orcid.org/0000-0003-1915-6681>

Stephen B.I. Parkin  <https://orcid.org/0000-0003-3232-5574>

## TWITTER

Agnes Y.Y. Lee  @AggieLeeMD

## REFERENCES

1. Klok FA, Pai M, Huisman MV, Makris M. Vaccine-induced immune thrombotic thrombocytopenia. *Lancet Haematol*. 2022;9(1):e73-e80.
2. Pavord S, Hunt BJ, Horner D, Bewley S, Karpusheff J, Guideline Committee. Vaccine induced immune thrombocytopenia and thrombosis: summary of NICE guidance. *BMJ*. 2021;375:n2195.
3. Thaler J, Ay C, Gleixner KV, et al. Successful treatment of vaccine-induced prothrombotic immune thrombocytopenia (VIPIT). *J Thromb Haemost*. 2021;19(7):1819-1822.
4. Pavord S, Scully M, Hunt BJ, et al. Clinical features of vaccine-induced immune thrombocytopenia and thrombosis. *N Engl J Med*. 2021;385(18):1680-1689.
5. Salih F, Schönborn L, Kohler S, et al. Vaccine-induced thrombocytopenia with severe headache. *N Engl J Med*. 2021;385(22):2103-2105.
6. Kennedy VE, Wong CC, Hong JM, et al. VITT following Ad26. COV2.S vaccination presenting without radiographically demonstrable thrombosis. *Blood Adv*. 2021;5(22):4662-4665.
7. Oldenburg J, Klamroth R, Langer F, et al. Diagnosis and management of vaccine-related thrombosis following AstraZeneca COVID-19 vaccination: guidance statement from the GTH. *Hamostaseologie*. 2021;41(3):184-189.
8. Thaler J, Ay C, Knoebl P. The path of uncovering a prothrombotic thrombocytopenic syndrome after viral vector-based COVID-19 vaccination: where there is much light, the shadow is deep. *Res Pract Thromb Haemost*. 2021;5(7):e12609.
9. Greinacher A, Langer F, Makris M, et al. Vaccine-induced immune thrombotic thrombocytopenia (VITT): update on diagnosis and management considering different resources. *J Thromb Haemost*. 2022;20(1):149-156.
10. Greinacher A, Selleng K, Palankar R, et al. Insights in ChAdOx1 nCoV-19 vaccine-induced immune thrombotic thrombocytopenia. *Blood*. 2021;138(22):2256-2268.
11. Huynh A, Kelton JG, Arnold DM, Daka M, Nazy I. Antibody epitopes in vaccine-induced immune thrombotic thrombocytopenia. *Nature*. 2021;596(7873):565-569.
12. Greinacher A. Heparin-induced thrombocytopenia. *N Engl J Med*. 2015;373(3):252-261.
13. Greinacher A, Selleng K, Warkentin TE. Autoimmune heparin-induced thrombocytopenia. *J Thromb Haemost*. 2017;15(11):2099-2114.
14. Warkentin TE. High-dose intravenous immunoglobulin for the treatment and prevention of heparin-induced thrombocytopenia: a review. *Expert Rev Hematol*. 2019;12(8):685-698.
15. Bourguignon A, Arnold DM, Warkentin TE, et al. Adjunct immune globulin for vaccine-induced immune thrombotic thrombocytopenia. *N Engl J Med*. 2021;385(8):720-728.
16. Cuker A, Arepally GM, Chong BH, et al. American Society of Hematology 2018 guidelines for management of venous thromboembolism: heparin-induced thrombocytopenia. *Blood Adv*. 2018;2(22):3360-3392.
17. Warkentin TE. Laboratory diagnosis of heparin-induced thrombocytopenia. *Int J Lab Hematol*. 2019;41(S1):15-25.
18. Sørvoll IH, Horvei KD, Ernsten SL, et al. An observational study to identify the prevalence of thrombocytopenia and anti-PF4/polyanion antibodies in Norwegian health care workers after COVID-19 vaccination. *J Thromb Haemost*. 2021;19(7):1813-1818.
19. Thiele T, Ulm L, Holtfreter S, et al. Frequency of positive anti-PF4/polyanion antibody tests after COVID-19 vaccination with ChAdOx1 nCoV-19 and BNT162b2. *Blood*. 2021;138(4):299-303.
20. Huynh A, Arnold DM, Kelton JG, et al. Characterization of platelet factor 4 amino acids that bind pathogenic antibodies in heparin-induced thrombocytopenia. *J Thromb Haemost*. 2019;17(2):389-399.

**How to cite this article:** Lai CMB, Lee AYY, Parkin SBI. Vaccine-induced prothrombotic immune thrombocytopenia without thrombosis may not require immune modulatory therapy: A case report. *Res Pract Thromb Haemost*. 2022;6:e12716. doi:[10.1002/rth2.12716](https://doi.org/10.1002/rth2.12716)