

Received: 2016.01.10  
Accepted: 2016.03.02  
Published: 2016.10.17

# Three-Dimensional Time-of-Flight Magnetic Resonance Angiography Detection of Duplication of the Vertebral Artery in a Large Chinese Population

Authors' Contribution:  
Study Design A  
Data Collection B  
Statistical Analysis C  
Data Interpretation D  
Manuscript Preparation E  
Literature Search F  
Funds Collection G

ACE **Shuhua Li**  
ABC **Yunyun Li**  
DEF **Min Bai**  
ACDEF **Chuanchen Zhang**

Department of Radiology, Liaocheng People's Hospital, Liaocheng, Shandong, P.R. China

**Corresponding Author:** Chuanchen Zhang, e-mail: zccmr66@sina.cn  
**Source of support:** Departmental sources

**Background:** The aim of this study was to investigate duplication of the vertebral artery (VA) using three-dimensional time-of-flight (3D TOF) magnetic resonance angiography (MRA) in a large study population to further our understanding of vascular variations.





**Material/Methods:** A retrospective analysis of 3D TOF-MRA data in 12 826 cases was performed. The occurrence rate of VA duplication was calculated and accompanied vascular anomalies were recoded.

**Results:** Twenty-one VA duplication patients were found, with an occurrence rate of 0.164%; 12 of them had left VA duplication with 2 branches initially arising from the aortic arch and left subclavian artery; 9 of them were right VA duplication with the branches originating from the right subclavian artery. In the 21 cases, 11 had other vascular abnormalities.

**Conclusions:** VA duplication is very rare and often associated with other vascular abnormalities. 3D TOF-MRA can accurately display the duplication variation. Better understanding of the variation is instrumental for disease diagnosis, interventional therapy, and surgical operation.

**MeSH Keywords:** **Cardiovascular Abnormalities • Magnetic Resonance Angiography • Vertebral Artery**

**Full-text PDF:** <http://www.medscimonit.com/abstract/index/idArt/897503>

 2027  2  5  19



## Background

Acknowledging vessel anatomy and its variations is important in the current era of stents and many new therapeutic interventions. The developmental variants of the vertebral artery (VA) mainly include variations in the origin, path, and vascular abnormalities, and they are highly variable, with a variety of manifestations [1]. VA duplication is very rare, but is occasionally found during digital subtraction angiography (DSA), computed tomography angiography (CTA), magnetic resonance angiography (MRA), or autopsy [2–4]. A better understanding of this variation is important for the diagnosis of cervical vascular disease, as well as cervical and neck vascular intervention surgery. At present, most of the variants are reported as individual cases and few studies have been conducted in large cohort [5]. In this report, we retrospectively analyzed MRA images from 12 826 cases admitted to our hospital for VA duplication and associated abnormal and we discuss the possible development mechanism of the variants and their clinical implications.

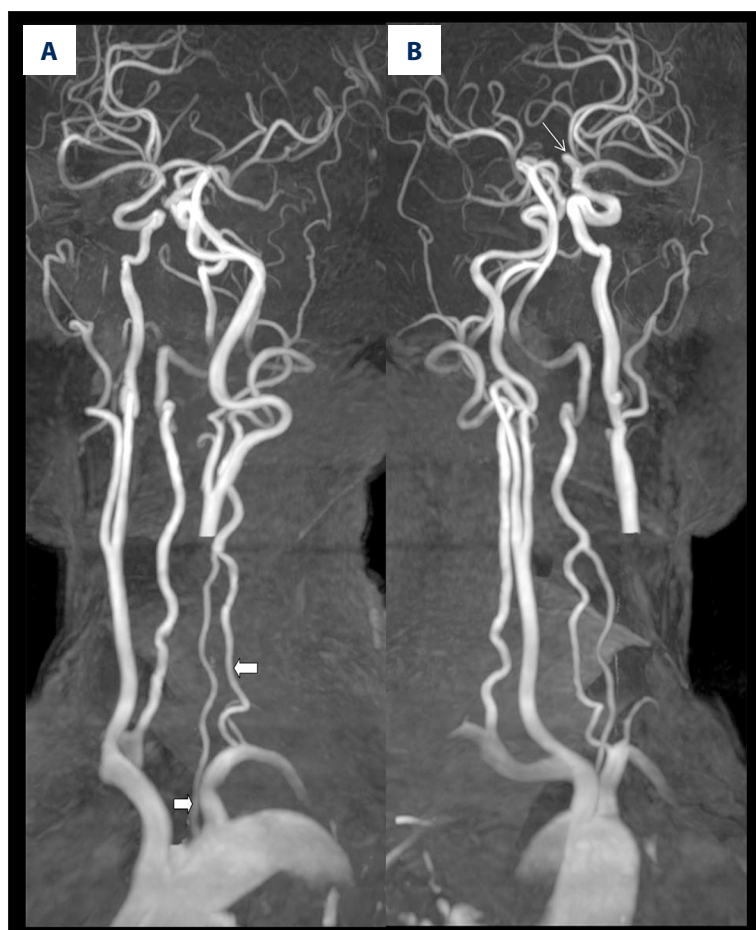
## Material and Methods

### Study population

We examined 12 981 patients with suspected cerebrovascular disease using MRA between January 1, 2010 and December 31, 2014 at our hospital. We analyzed 12 826 patients in this study after excluding 65 patients whose image quality was poor or VA occluded. The age range was 9–92 years, with an average age of 57 years. The main clinical manifestations were dizziness, headache, diplopia, slurred speech, walking instability, or limb weakness. This retrospective study was approved by the Ethics Committee and written informed consent was obtained from all patients.

### MRA

All patients were scanned with a 3T scanner using a 16-channel head coil (Achieva X-Series, Philips Healthcare, Best, the Netherlands). 3D TOF MRA cross-sectional imaging was performed using a 3D fast-field echo sequence and multi-chunk technique from the aortic arch to the Willis ring in 3 segments. The cerebral segment was imaged with repetition time



**Figure 1.** 3D-MIP reconstructed angiogram showing left VA duplication (A) and absence of A1 segment in the right ACA (B) in a 48-year-old male with left limb weakness for 1 day. The left carotid artery was removed using the MobiView post-processing package (Phillips). The 2 branches arise from the aortic arch and left subclavian artery (thick arrow), the left ACA is supplied from the opposite ACA (thin arrow).

(TR)/echo time (TE)/flip angle (FA), 15 ms/3.5 ms/18°; number of slices, 160; field of view (FOV), 220×220×96 mm; matrix, 368×40; sense factor, 2. The neck segment was imaged with TR/TE/FA, 20 ms/3.5 ms/20°; number of slices, 180; FOV, 160×131×135 mm; matrix, 260×84; sense factor, 3. The arch segment was scanned with TR/TE/FA, 22 ms/3.5 ms/22°; number of slices, 120; FOV, 250×238×96 mm; matrix, 260×84; sense factor, 2. The total scanning time was 11 m 39 s. The images were processed by maximum intensity projection (MIP) to obtain 3D displays and assembled using the MobiView Philips software to reconstruct continuous images from the aortic arch to the Willis ring.

### Image analysis

The original images were transmitted to a PACS workstation for MIP, volume rendering (VR), and multiplanar reconstruction (MPR), and evaluated by 2 experienced radiologists for the origin, path, and associated variation of bilateral VAs, with reference to the original images.

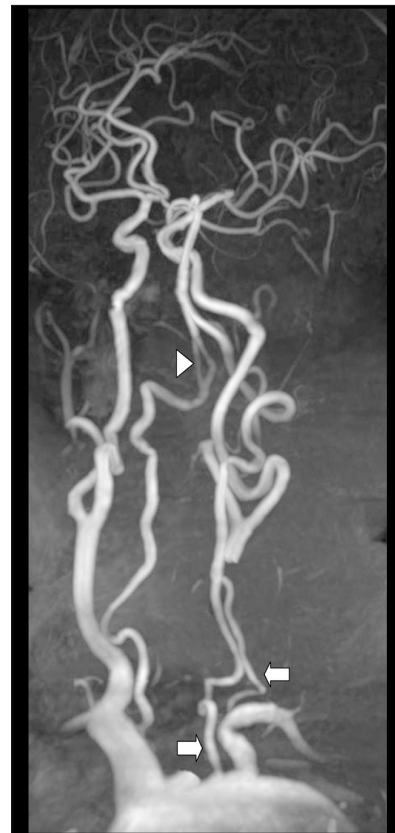Fetal type of posterior cerebral artery (PCA) was judged as defined by Voljevica et al. [6]: If the P1 segment of PCA is absent or the diameter of the P1 segment is smaller than that of the posterior communicating artery (PCOM) on the same side, PCA is mainly supplied by the PCOM.

### Statistical analysis

Data were analyzed using SPSS statistical software (V17.0).  $\chi^2$  was used to test the differences in the occurrence rates of other vascular abnormalities between the patients with and without VA duplication, and in the occurrence rates of VA duplication and other vascular abnormalities between males and females. Values with  $P < 0.05$  were considered statistically significant.

## Results

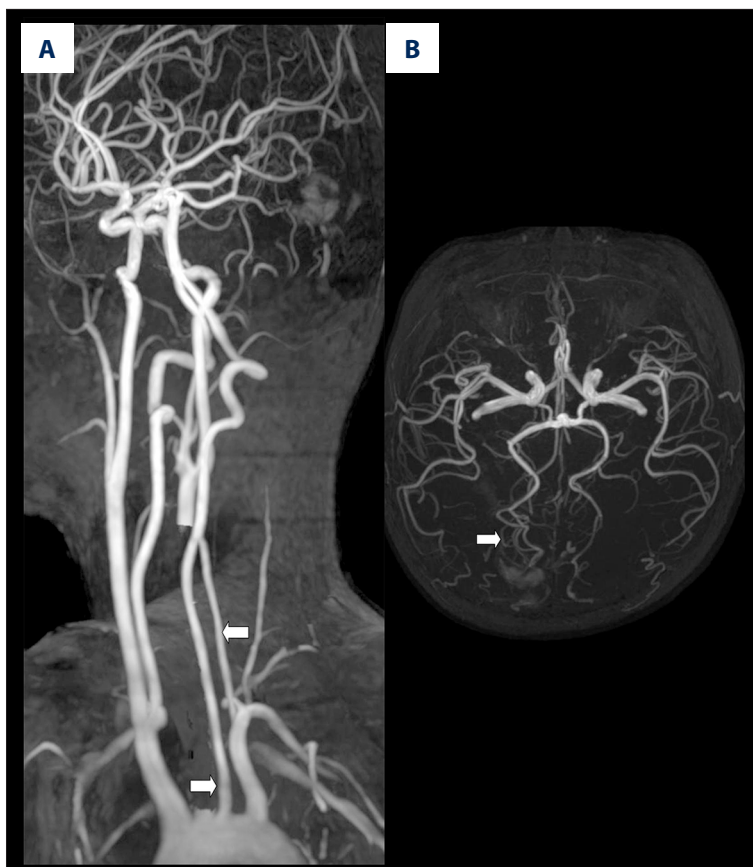In the 12826 cases, 21 (0.164%) were found to be VA duplication variants. Among them, 10 were males and 11 were females, aged 13–69 years, with an average of 59.7 years. In 12 (57.14%) of them, the duplication occurred in the left vertebral artery with 2 branches originated from the aortic arch and the subclavian artery (Figures 1–3); 9 (42.86%) had the duplication in the right VA with 2 branches both coming from the subclavian artery (Figures 4, 5). In the 21 cases, 11 (52.38%) had other vascular abnormalities (including 8 (72.73%) females and 3 (27.27%) males), 3 of which had 2 or more other vascular abnormalities. In 6 of 11 cases showed fetal type of PCA (Figure 4), left VA was from the aortic arch (all of them had the duplication in the right VA, Figure 4), 3 lacked A1 segment



**Figure 2.** 3D-MIP reconstructed angiogram showing left VA duplication in a 68-year-old female with walking instability for 1 day. The left carotid artery was removed using the MobiView post-processing package (Phillips). The 2 branches arise from the aortic arch and left subclavian artery (thick arrow). Triangle symbol indicates fenestration variation on the right VA.

in ACA on 1 side (Figures 4, 5), 1 case was an artery fenestration variant (Figure 2), 1 had 3 pericallosal arteries (Figure 5), and 1 had an arteriovenous abnormality (Figure 3), Table 1.

In 12 805 unduplicated cases, 3801 (29.68%) had vascular anomalies in the head and neck. Among them, 1246 (9.73%) had variations in vascular anomalies in the aortic arch, 457 (3.57%) had fenestration variations in the vertebral basilar artery, 902 (7.04%) had variations in the ACA, and 65 (0.51%), 2956 (23.08%), and 56 (0.44%) had variations in the middle cerebral artery, PCA, and primitive trigeminal artery, respectively. Of these patients, 1881 (14.69%) had 2 or more variations. Analysis also showed that the occurrence rate of other vascular abnormalities was higher in the VA duplicated variants than in the normal subjects (Table 2,  $P < 0.05$ ), while the occurrence rates of VA duplication and other vascular abnormalities was similar between males and females ( $P > 0.05$ ).



**Figure 3.** 3D-MIP reconstructed angiogram showing (A) left VA duplication in a 11-year-old female with headache for 3 days. The left carotid artery was removed using the MobiView post-processing package (Phillips). (A) the 2 branches arise from the aortic arch and left subclavian artery (thick arrow), (B) vascular abnormality in right PCA (thick arrow).

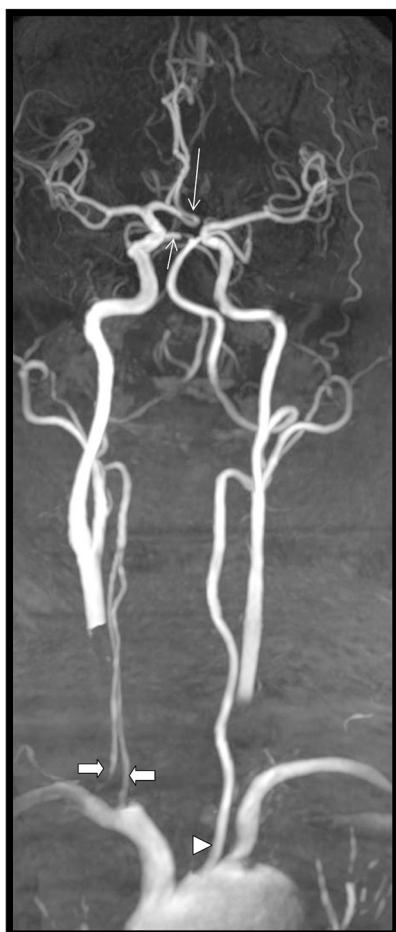## Discussion

### 3D TOF-MRA

In this technique, which was first used for intracranial vascular imaging, the flow-compensated gradient-echo sequences are optimized to enhance the vascular signal, with saturated stationary surrounding tissues with very short TR [7]. In recent years, with the increased use of MRI and improved gradient-echo sequences, the technology has been widely used in clinical studies and diagnosis [8]. In this study, we achieved large-scale brain and neck imaging using multi-chunk technique, and we found that the CHARM algorithm (Philips Medical Systems) can effectively integrate data captured from overlapped parts of the layer to prevent the signal weakening at the edge of the layer. As a result, high-quality images were obtained under high magnetic field and high gradient with greatly shorter imaging time and with reduced artifacts due to respiration and vascular fluctuations. The scan time was further reduced and resolution improved using the sensitivity encoding techniques with the 16-channel neurovascular coil (Philips).

### Embryonic development mechanism of VA duplication

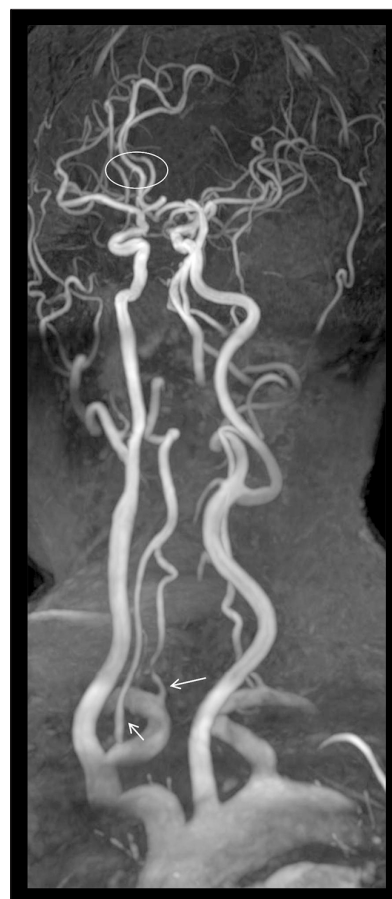
Although VA duplication and fenestration are both derived from incomplete vascular degeneration during embryogenesis, the 2 types of variants are conceptually different and should to be handled differently in clinical work [9]. VA duplication has dual artery origins to form 2 branches, which are then merged into 1 artery to end at 1 point. On other hand, VA fenestration occurs at VA from 1 origin to form 2 branches and then end up at 1 point [2,10]. During embryogenesis, 30 pairs of intersegmental arteries are formed in the dorsal aorta, and the intersegmental arteries in the neck are horizontally oriented and longitudinally coincided. When the embryo is developed to 7–12 mm long, the intersegmental arteries at the 6<sup>th</sup> neck internode are transformed into bilateral VA, while the rest of the intersegmental arteries are completely degenerated, resulting in the transformation of the longitudinally coincided vessels into a single vessel, the VA, to connect to the subclavian artery. However, if 1 intersegmental artery (often the 5<sup>th</sup> intersegmental artery), or the dorsal aorta is not completely degenerated, but transformed into a vessel that is connected to a normal VA, this would result in VA duplication [1,11,12].



**Figure 4.** 3D-MIP reconstructed angiogram showing right VA duplication in a 40-year-old female with dizziness for 3 days. The middle segment of the bilateral carotid artery was removed using the MobiView post-processing package (Phillips). The 2 branches arise from the right subclavian artery (thick arrow), left VA is directly from the aortic arch (triangle), A1 segment of left ACA is absent, and the left ACA is supplied from the opposite ACA (thin and long arrow). Short and thick arrow indicates the embryogenic PCA.

#### Occurrence of VA duplication and imaging manifestations

Most VA duplication variants are reported as single cases and very few studies have investigated the occurrence rate using larger populations. Bergman et al. found 5 VA duplication variants (0.72%) in 693 bodies [5]; Uchino et al. identified 2 VA duplication variants in 2287 CTA [13]. In the present study, 21 VA duplications were found in 12826 cases (0.164%) of head and neck MRA. The difference between our results and previous work may result from different populations studied and methods used. Furthermore, it is also worth noting that the study populations in this study consisted of patients with suspected cerebrovascular disease, and we are therefore likely to have overestimated the occurrence rate at which VA duplication occurs



**Figure 5.** 3D-MIP reconstructed angiogram showing right VA duplication in a 59-year-old female with dizziness for 7 days. The 2 branches arise from the right subclavian artery (thin arrow). Oval symbol indicates 3 pericallosal arteries.

in the general population. This further demonstrates that the disease occurs at very low frequency. Studies have shown that the variations are more often on the left side [1,12]. For example, the 5 variants found by Bergman et al. were all on the left side [5]. We found that in our study population, the variants are slightly more on the left than right side (57.14% vs. 42.86%). There is also a report showing bilateral VA duplication [2]. For the duplicated branches, one may arise from the subclavian artery, and the other from the subclavian artery [4], or from the aortic arch (between the left common carotid artery and subclavian artery) [12] or anomya [3]. When VA is duplicated on the left side, one of the branches is often from the aortic arch; when VA is duplicated on the right side, 1 of the branches is often from the subclavian artery [9]. In our study, 11 out of the 21 VA duplication variants were on the left side with branches arising from the subclavian artery and the aortic arch and 9 were on the right side with both branches issuing from the subclavian artery. These results are consistent with previous reports.

**Table 1.** Summary of VA duplication variants and their associated abnormalities in brain and neck.

Case No.	Gender	Age	Side	Branch origin	Accompanied abnormality
1 (Figure 1)	Female	40	Right	Subclavian artery	Fetal sort of right PCA with absence of A1 segment in left anterior cerebral artery (ACA) and left VA from the aortic arch
2 (Figure 2)	Male	48	Left	Aortic arch and subclavian artery	Fetal type of left PCA with absence of A1 segment in right ACA
3 (Figure 3)	Female	68	Left	Aortic arch and subclavian artery	Fenestration in V5 segment of right VA
4 (Figure 4)	Female	59	Right	Left subclavian artery	Three pericallosal arteries
5 (Figure 5)	Female	11	Left	Aortic arch and left subclavian artery	Arteriovenous abnormalities in PCA
6	Female	22	Left	Aortic arch and left subclavian artery	Fetal sort of left PCA
7	Male	54	Right	Aortic arch and left subclavian artery	Fetal sort of left PCA
8	Male	74	Left	Aortic arch and left subclavian artery	Fetal sort of left PCA
9	Female	46	Right	Right subclavian artery	Left VA from the aortic arch Fenestration in V5 segment of right VA
10	Female	66	Left	Aortic arch and left subclavian artery	Fetal sort of left PCA with absence of A1 segment in left ACA
11	Female	29	Right	Right subclavian artery	Fetal sort of left PCA with left VA from the aortic arch

**Table 2.** Comparison of other vascular abnormalities in patients with and without VA duplication.

	Cases with other vascular abnormalities	Cases without vascular abnormalities	Total
VA duplication variant	11	10	21
Normal people	3801	9004	12805
Total	3812	9014	12826

$\chi^2=5.184, P=0.023$ .

**Clinical significance**

Accurate diagnosis of VA duplication is important for diagnosis of clinical disease, radiological diagnosis, head and neck vascular intervention, and surgical procedures. For example, dizziness caused by the duplicated VA is because the diameter of branches in the VA duplication variant is smaller than that of a normal VA, resulting in insufficient blood supply in the posterior circulation [2]. Nishijima et al. reported a patient with dizziness that was clearly improved after surgical correction of the tortuous and duplicated VA [14]. Melki et al. and Polguy et al. found VA duplication variations in patients with aneurysm in the dissection between the spontaneous carotid artery and VA, suggesting that VA duplication is a risk factor in head and neck artery dissection [4,15]. A number of cases have been presented where VA duplication is accompanied with head and

neck aneurysm inside internal carotid [12], basilar artery [16], or PCA [17]. However, these are all case reports without statistical consideration. In the 21 VA duplication patients identified in this study, over half (52.38%) are accompanied with other vascular abnormalities, mostly fetal type PCA, followed by the absence of A1 segment in 1 side of the ACA and origination of the left VA from the aortic arch. However, no aneurysm or arterial dissection was found. These findings suggest that VA duplication is most often associated with other vascular abnormalities, but the relationship between VA duplication and vascular abnormality is not clear. No difference between sexes was found in the VA duplication patients. Although in the 11 bilateral VA duplication variants with other vascular abnormalities, 72.73% was female, they were not statistically more numerous than the males, suggesting that female VA duplication variants are not more prone to other vascular

abnormalities. However, more samples are needed to confirm this conclusion. Furthermore, among the patients, there was an 11-year-old girl with intracranial arteriovenous malformations. This may be the first report of a young girl with VA duplication.

During intervention, if not enough contrast agent is injected, VA duplication may be misdiagnosed as dissection or aneurysm [18,19]. If only 1 branch in a duplicated VA is exposed, it may also result in misdiagnosis as VA dysplasia or pathological stenosis. Therefore, knowing of the presence of VA duplication variations before intervention would avoid misdiagnosis and help develop a rational plan to shorten operation time and reduce postoperative complications. During cervical and thoracic surgery or puncture, the clinician must be careful in dealing with these abnormal VAs to avoid injury leading to complications.

## References:

1. Goddard AJ, Annesley-Williams D, Guthrie JA, Weston M: Duplication of the vertebral artery: report of two cases and review of the literature. *Neuroradiology*, 2001; 43(6): 477–80
2. Ionete C, Omojola MF: MR angiographic demonstration of bilateral duplication of the extracranial vertebral artery: Unusual course and review of the literature. *Am J Neuroradiol*, 2006; 27(6): 1304–6
3. Kiss J: Bifid origin of the right vertebral artery: A case report. *Radiology*, 1968; 91(5): 931
4. Polgaj M, Jedrzejewski K, Topol M et al: Duplication of the left vertebral artery in a patient with dissection of the right internal carotid artery and Ehlers-Danlos syndrome: Case report and review of the literature. *Anat Sci Int*, 2013; 88(2): 109–14
5. Bergman RA, Thompson SA, Aww AK, Saadeh FA: *Cohavt, atlas, and world literature Compendium of human anatomic variation: text, atlas, and world literature*. Baltimore, 1988; 71–72. Baltimore: Urban & Schwarzenberg, 1988; 71–72
6. Voljevica A, Kulenovic A, Kapur E, Vuckovic I: Angiography analysis of variations of the posterior segment of the circle of willis. *Bosn J Basic Med Sci*, 2005; 5(3): 30–34
7. Wikstrom J, Ronne-Engstrom E, Gal G, Enblad P, Tovi M: Three-dimensional time-of-flight (3D TOF) magnetic resonance angiography (MRA) and contrast-enhanced MRA of intracranial aneurysms treated with platinum coils. *Acta Radiol*, 2008; 49(2): 190–96
8. Sadikin C, Teng MM, Chen TY et al: The current role of 1.5T non-contrast 3D time-of-flight magnetic resonance angiography to detect intracranial steno-occlusive disease. *J Formos Med Assoc*, 2007; 106(9): 691–99
9. Polgaj M, Podgorski M, Jedrzejewski K et al: Fenestration and duplication of the vertebral artery: the anatomical and clinical points of view. *Clin Anat*, 2013; 26(8): 933–43
10. Harnier S, Harzheim A, Limmroth V et al: Duplication of the common carotid artery and the ipsilateral vertebral artery with a fenestration of the contralateral common carotid artery. *Neurol India*, 2008; 56(4): 491–93
11. Kau T, Sinzig M, Gasser J et al: Aortic development and anomalies. *Semin Intervent Radiol*, 2007; 24(2): 141–52
12. Kendi AT, Brace JR: Vertebral artery duplication and aneurysms: 64-slice multidetector CT findings. *Br J Radiol*, 2009; 82(983): e216–18
13. Uchino A, Saito N, Takahashi M et al: Variations in the origin of the vertebral artery and its level of entry into the transverse foramen diagnosed by CT angiography. *Neuroradiology*, 2013; 55(5): 585–94
14. Nishijima M, Harada J, Akai T et al: Operative correction of a kinked duplicate origin of the vertebral artery in a patient with dizziness. Case report. *Surg Neurol*, 1989; 32(5): 356–59
15. Melki E, Nasser G, Vandendries C et al: Congenital vertebral duplication: A predisposing risk factor for dissection. *J Neurol Sci*, 2012; 314(1–2): 161–62
16. Thomas AJ, Germanwala AV, Vora N et al: Dual origin extracranial vertebral artery: Case report and embryology. *J Neuroimaging*, 2008; 18(2): 173–76
17. Koenigsberg RA, Pereira L, Nair B et al: Unusual vertebral artery origins: Examples and related pathology. *Catheter Cardiovasc Interv*, 2003; 59(2): 244–50
18. Nogueira TE, Chambers AA, Brueggemeyer MT, Miller TJ: Dual origin of the vertebral artery mimicking dissection. *Am J Neuroradiol*, 1997; 18(2): 382–84
19. Kim DW: Concomitant dual origin and fenestration of the left vertebral artery resembling dissection. *J Korean Neurosurg Soc*, 2009; 46(5): 498–500

## Conclusions

Our study shows that 3D TOF-MRA is a suitable technique for precise diagnosis of VA duplication. It is safe and noninvasive, without need of contrast agent, and can be performed repeatedly. Occurrence of VA duplication is very rare and often accompanied with other vascular abnormalities. A better understanding of this variation would help the diagnosis and treatment of clinical diseases, vascular interventional surgery, and surgical operations.

## Conflict of interest

None.