

ORIGINAL ARTICLE

# An easy and secure pancreaticogastrostomy after pancreaticoduodenectomy: transpancreatic suture with a buttress method through an anterior gastrotomy

Tae Ho Hong, Young Chul Youn<sup>1</sup>, Young Kyoung You, Dong Goo Kim

Division of Hepatobiliary-Pancreas Surgery, Department of Surgery, Seoul St. Mary's Hospital, The Catholic University of Korea School of Medicine, Seoul, <sup>1</sup>Division of Hepatobiliary-Pancreas Surgery, Department of Surgery, Incheon St. Mary's Hospital, The Catholic University of Korea School of Medicine, Incheon, Korea

**Purpose:** The aim of this report was to describe a new reconstructive technique of pancreaticogastrostomy and to also discuss this procedure's effectiveness for reducing the incidence of postoperative complications. **Methods:** We retrospectively analyzed early surgical outcomes in 21 consecutive patients who underwent this novel pancreaticogastrostomy after pancreaticoduodenectomy. Pancreaticogastrostomy was completed with 2 transpancreatic sutures with buttresses on both the upper and lower edges of the implanted pancreas through the retracted anterior gastrotomy. **Results:** Operative mortality was zero and morbidity was 23.8%. A significant pancreatic fistula occurred in 1 patient (4.7%; grade B). **Conclusion:** This technique is very easy to perform, less traumatic to the pancreatic stump, can be performed through a mini-laparotomy due to good vision and straight sutures, and it is secure owing to anchoring of the invaginated pancreatic stump to the stomach's posterior wall with buttresses. The results of this pilot study indicate that the technique may provide a favorable outcome and could be an alternative method of pancreatoenteric anastomosis. However, to determine its superiority over the conventional procedures, this operative technique should be evaluated more comprehensively in a larger series.

**Key Words:** Pancreatic fistula, Pancreatoenteric anastomosis, Anterior gastrotomy

## INTRODUCTION

Pancreatic anastomotic failure is the most important determinant for morbidity and mortality following pancreaticoduodenectomy (PD). Many reconstruction techniques have been extensively studied in the last two decades in an attempt to reduce the incidence of pancreatic fistula [1-12].

Pancreaticogastrostomy (PG) has recently been reappraised as a more secure procedure over pancreaticojejunostomy (PJ) and many reports support the lower rates of pancreatic anastomotic failure with PG than with PJ [13-16]. Several different methods of anastomosing the pancreas to the stomach have also been introduced with greatly improved results [5,12,15,17,18].

In the present report, we describe our reconstructive

Received May 30, 2011, Revised July 4, 2011, Accepted July 28, 2011

Correspondence to: Young Kyoung You  
Division of Hepatobiliary-Pancreas Surgery, Department of Surgery, Seoul St. Mary's Hospital, The Catholic University of Korea School of Medicine, 505 Banpo-dong, Seocho-gu, Seoul 137-701, Korea  
Tel: +82-2-2258-6102, Fax: +82-2-595-2992, E-mail: yky602@catholic.ac.kr

© Journal of the Korean Surgical Society is an Open Access Journal. All articles are distributed under the terms of the Creative Commons Attribution Non-Commercial License (<http://creativecommons.org/licenses/by-nc/3.0/>) which permits unrestricted non-commercial use, distribution, and reproduction in any medium, provided the original work is properly cited.

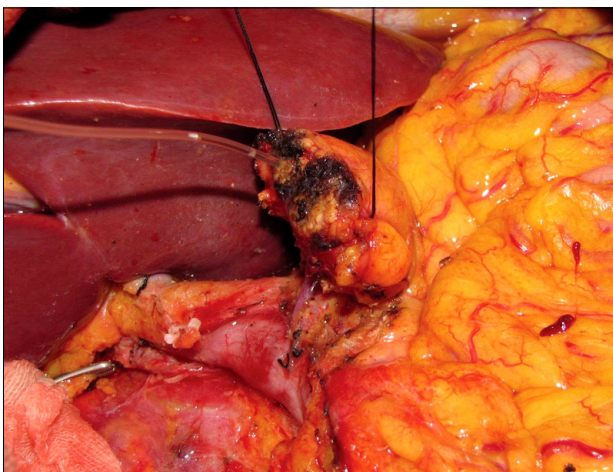
technique of PG after PD: transpancreatic suture with a buttress method through an anterior gastrotomy, and this can provide an easy, secure pancreatoenteric anastomosis. We also discuss this procedure's effectiveness for reducing the incidence of postoperative complications.

## METHODS

### Patients and methods

The study was approved by Institutional Review Board of the Ethical Committee of hospital. This novel PG has been used in 21 consecutive patients by two surgeons at two institutions between May 2010 and January 2011. The data was prospectively collected and then retrospectively reviewed. Reviewed data included patient demographics (age, sex, and diagnosis), type of operation (standard PD or PPPD), a texture of pancreas, operating time, blood loss, postoperative hospitalization, operative mortality, and complications.

We defined a pancreatic fistula as a drain output of any measurable volume of fluid on or after postoperative day 3 with an amylase content greater than 3 times the serum amylase activity, according to the International Study Group on Pancreatic Fistula (ISGPF) recommendations.

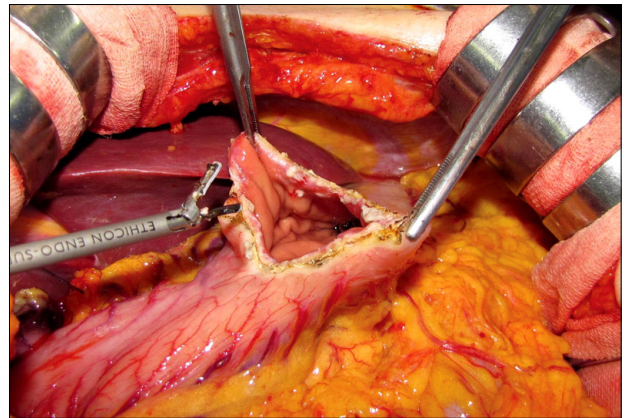


**Fig. 1.** Two stay sutures on both ends of the pancreatic stump. After resection of the pancreatic head and duodenum, the pancreatic stump is freed about 4 cm from all retroperitoneal attachments. The duct of Wirsung is incannulated with a short stent tube and 2 stay sutures on both ends of the pancreatic stump are applied for traction.

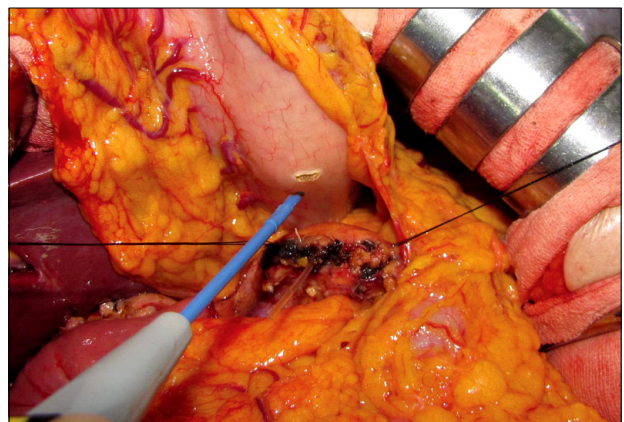
However a simply biochemical pancreatic fistula, which was classified into grade A, was not defined as a pancreatic fistula in this report. Delayed gastric emptying was defined as being present when postoperative nasogastric suction was required for more than 10 days combined with a failure to progress with oral feeding.

### Surgical techniques

After resection of the pancreatic head and duodenum with or without preservation of the pylorus, the pancreatic stump is freed from retroperitoneal attachments for about 4 cm. The duct of Wirsung is identified and incannulated



**Fig. 2.** A longitudinal gastrotomy in the anterior gastric wall just above the presumed site of the pancreaticogastrostomy in the posterior gastric wall is performed with an ultrasound scissors (Harmonic Scalpel UltraCision, Ethicon Endo-Surgery Inc., Cincinnati, Ohio, USA).



**Fig. 3.** A transverse gastrotomy was made on the serosal surface of the posterior gastric wall with electrocautery in accordance with the 3/4 diameter of the pancreatic stump.

with a short stent tube in order to avoid being sutured during anastomosing the pancreatic remnant to the stomach. Hemostasis on the cross-section of the pancreas was done by electrocautery or 4-0 monofilament suturing. Two stay sutures on both ends of the pancreatic stump are applied for traction of it into the gastric cavity (Fig. 1).

The stomach is approximated to the pancreatic stump, and a longitudinal gastrotomy in the anterior gastric wall just above the presumed site of the PG in the posterior gastric wall is performed with an ultrasound scissors (Harmonic Scalpel UltraCision, Ethicon Endo-Surgery Inc., Cincinnati, OH, USA) (Fig. 2). Then, in accordance with the 3/4 diameter of the pancreatic stump, a transverse gastrotomy was made via electrocautery on the serosal surface of the posterior gastric wall (Fig. 3). At this point, care was taken to avoid extending the incision and making it too large and there was no need to incise deeply into the mucosa layer, which was easily punctured with a Kelly clamp and it adapted to the dimensions of the pancreas stump due to the great elasticity. Two stay sutures were brought anteriorly through the small hole in the mucosa layer of the posterior gastric wall. Applying slight traction on the sutures, the pancreatic stump was inserted into the gastric lumen and implanted approximately 2 cm.

PG was completed with 2 transpancreatic sutures with buttresses on both the upper and lower edges of the implanted pancreas through the retracted anterior gastrotomy. Fig. 4 shows the performance of this suture, which

needs two 4-0 monofilament polypropylene threads with a straightened needle at each end (4-0 Prolene, Ethicon Inc., Somerville, NJ, USA) and four buttresses (TFE Polymer Pledget, Ethicon Inc.). The suture first passed straightly from the proximal mucosal surface of the posterior gastrotomy and it passed the full-thickness of the posterior gastric wall, and then it penetrated from the dorsal surface to the ventral surface of the pancreas at a point 1.5 cm below from the cut end and it next passed the distal full-thickness of the posterior gastric wall. These simple sutures were performed at the both corners of the gastro-

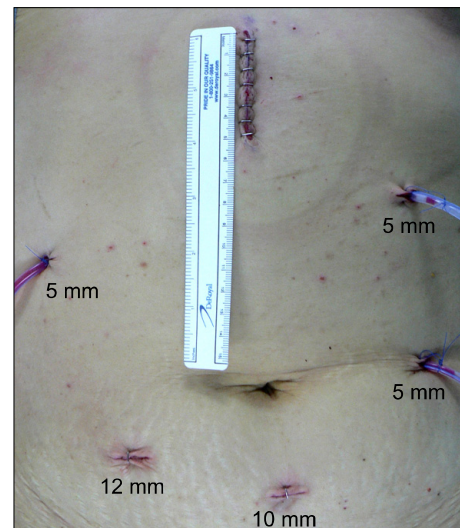


Fig. 5. The location of trocar placement and the mini-laparotomy in laparoscopy-assisted pancreatoduodenectomy at our institution.

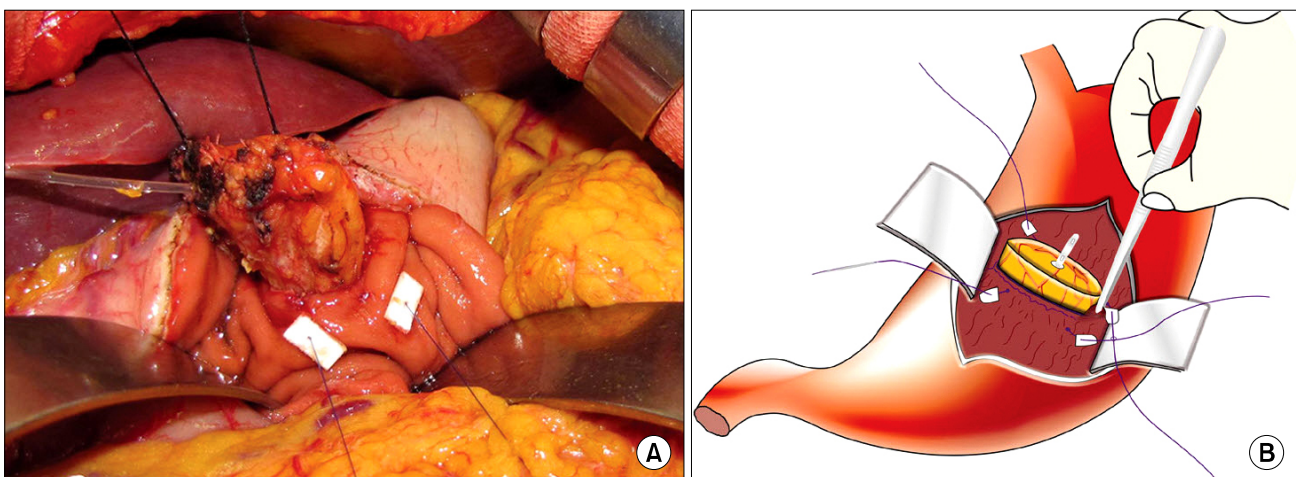


Fig. 4. Two transpancreatic sutures with buttresses on both the upper and lower edges of the implanted pancreas through the retracted anterior gastrotomy. Operative view (A) and schema (B) of this suture.

tomy incision. Then, a suture buttress was inserted through each needle and finally a knot was made that included the stomach wall on the corner of the gastrotomy incision, with the aid of tissue forceps grasping the edges of the stomach wall upward (Fig. 4).

A nasogastric tube was positioned alongside the anastomosis and the anterior gastrotomy was closed in two layers. The PG is drained with two Jackson-Pratt drains positioned in the retrogastric region in all cases. The volume and amylase content of the drainage fluid were measured every day. Octreotide is not routinely used intraoperatively or in the postoperative period, but H2 blocker is generally administered as prophylaxis for stress and marginal ulceration.

We applied laparoscopy-assisted pylorus-preserving PD for the patients who had the preoperative diagnosis of benign or low-grade malignant periampullary disease. In this procedure, the choledochojejunostomy as well as the whole resection phase were performed with laparoscopy. A mini-laparotomy on an upper median abdominal wall was then performed and this was covered using a wound protector (Alexis Wound Protector/Retractor, Applied Medical Resources Co., Rancho Santa Margarita, CA, USA). Through the incision, the specimen was delivered and the PG in the manner explained above and an end-to-side duodenojejunostomy were performed sequentially. Fig. 5 shows the location of trocar placement and the mini-laparotomy in the laparoscopy-assisted PD at our institution.

**Table 1.** Pathological diagnosis in 21 patients

Diagnosis	Patients	Laparoscopy-assisted PD (n)
Pancreatic adenocarcinoma	6	
Ampullary adenocarcinoma	5	3
Distal cholangiocarcinoma	1	
Duodenal adenocarcinoma	1	
Pancreatic endocrine tumor	2	2
Intraductal papillary mucinous neoplasm	5	4
Pancreatic trauma	1	
Total	21	9

PD, pancreatoduodenectomy.

## RESULTS

The patients consisted of 17 men and 4 women, with an average age of 55.1 years (range, 35 to 69 years) and their average body mass index was 23.9 kg/m<sup>2</sup> (range, 20.8 to 27.8 kg/m<sup>2</sup>). The standard Whipple procedure was performed in only 1 case and the other 20 patients underwent a pylorus-preserving modification. Concomitant mesentericoportal vein resection was performed in 2 patients with pancreatic adenocarcinomas in this series. Nine patients underwent laparoscopy-assisted pylorus preserving PD and they had 4 intraductal papillary mucinous adenomas, 3 ampullary adenocarcinomas and 2 pancreatic endocrine tumors. The other 12 patients had various indications for PD (Table 1). Of the 21 patients, 11 (52.3%) patients had a soft pancreatic texture and the remaining 10 (47.6%) had a firm pancreatic texture. The median estimated pancreatic duct size was 4 mm (range, 2 to 14 mm). The mean operating time was 378 minutes (range, 290 to 410 minutes) in the open PD cases and 418 minutes (range, 310 to 450 minutes) in the laparoscopy-assisted PD cases. The mean blood loss was 1,640 mL (range, 1,300 to 1,800 mL) in the open PD cases and 300 mL (range, 100 to 800 mL) in the laparoscopy-assisted PD cases. The mean duration of postoperative hospitalization was 18.2 days (range, 9 to 28 days) in the open PD cases and 14.3 days (range, 8 to 16 days) in the laparoscopy-assisted PD cases.

There were no operative or hospital deaths. Five complications (23.8%) occurred in 4 patients (Table 2). A pancreatic fistula occurred in 1 patient (4.7%; grade B). He subsequently developed peripancreatic abscess, which was controlled by ultrasound-guided percutaneous drainage beside the operatively-placed drains, and delayed gastric emptying. Two patients experienced hemorrhage from the

**Table 2.** Operative complications in 21 patients

Complications	Value
Pancreatic fistula	1 (4.7)
Delayed gastric emptying	1 (4.7)
Bleeding from the pancreatic stump	2 (9.5)
Wound infection	1 (4.7)
Total	5 (23.8)

Values are presented as number (%).

cross-section of the pancreatic stump and they were successfully treated by endoscopy. One patient developed wound infection and this resolved with conservative treatment.

## DISCUSSION

Pancreatoenteric anastomosis is quite different from the anastomosis between hollow viscera such as gastrojejunostomy, jejunojejunostomy or colocolostomy. First of all, the nature of the two organs in pancreatoenteric anastomosis is disparate. One is solid and the other is tubular with a lumen. So, there is no landmark for the adequate thickness of the suture 'bites' between the two organs. Secondly, this solid organ has numerous accessory pancreatic ducts as well as a main pancreatic duct on the cross-section planes, and these ducts secrete pancreatic juice and this might account for breaking down of the anastomosis if left undrained. Also, if these ducts are occluded while performing anastomosis, then postoperative pancreatitis in the pancreatic remnant might occur, and this can contribute to the anastomotic failure. Third, the normal pancreas is so soft and fragile that pancreatic laceration is inevitable during suturing with a needle or during tightening of the suture thread. This is more evident when a suture made with a curved needle traps only a small amount of pancreatic parenchyma. Fourth, among the two organs in the pancreatoenteric anastomosis, one is fixed and the other is relatively movable. So, the pancreatoenteric anastomosis could be more vulnerable to disruption than others between hollow viscera.

For these reasons, the management of a pancreatic remnant after PD has been of great concern to pancreatic surgeons and numerous techniques to reduce the pancreatic fistula have been described such as PJ or PG, end-to-end or end-to-side anastomosis, invagination or duct-to-mucosa anastomosis, the use of an isolated Roux-en-Y limb, binding PJ, the pancreatic duct stenting methods, application of topical adhesives and duct occlusion without pancreatoenteric anastomosis [1,4-11,19]. We started to adapt PG after PD in 2001 because of the superiority of PG over the PJ: the proximity of the stomach and the pancreas, the

thick posterior wall and excellent blood supply of the stomach, a lack of enzyme activation in the stomach and finally less tension on the anastomosis through the nasogastric continuous decompression of the stomach.

We then revised the previous PG method based on the above mentioned analysis of the pancreatic anastomosis. In order to minimize the pancreatic laceration during suturing with a needle or tightening of the suture thread, we introduced transpancreatic suture with a straightened needle instead of the conventional circumferential suture with a curved needle around the stump of the pancreas. This maneuver can also prevent full disruption of the pancreas stump from the stomach by any possibility that there is a partial breakdown in the anastomosis. Moreover, in this improved PG method, only two sutures are applied on both edges of the pancreatic stump, which enabled further reducing the suture damage to the pancreatic parenchyma and shortening the overall time required for this anastomosis. Instead, this simplified PG method is compensated by including the stomach wall in both edges of the gastrotomy with buttresses during tightening of the suture thread, and this firmly anchors the gland to the stomach. Ohigashi et al. [12] also used straight sutures penetrating the pancreas in a U-like fashion and they reported a 0% pancreatic leakage rate with a shortened time required for the anastomotic procedure. They placed 4 to 8 pancreas-penetrating sutures (2 to 4 U-like loops) in accordance with the diameter of the pancreatic stumps. These sutures are not tied promptly, but instead they are left loose until all of the U-like loops have been performed and tied. So, it seems very embarrassing if an unexpected bleeding occurs while the needle is penetrating the pancreas before the completion of the U-like loops because the bleeding would stop when the sutures are firmly tied.

The approach via the gastrotomy in the anterior gastric wall provides an excellent field of vision and consequently much easier performance of the anastomosis. The direct vision of the surgical field and only two straight sutures for the completion of this anastomosis enabled us to more decrease the size of the laparotomy in the cases of laparoscopy-assisted PD. Further, the full-thickness suturing of the stomach wall from the inside spontaneously prevents the protrusion of gastric mucosa, which is very cumbersome.

some in a conventional procedure, that is, the procedure that anastomoses the pancreatic stump to the posterior wall of the stomach from the outside.

As shown in Fig. 4, the pancreatic stump is sufficiently invaginated into the gastric lumen, and this guarantees adequate drainage of the pancreatic juice secreted from the accessory pancreatic ducts on the cross-section planes. The main pancreatic duct was incannulated using a short internal stent and then fixed with an absorbable suture. This is principally for facilitating identification of the Wirsung duct and avoiding inadvertently suturing it during the anastomosis.

With regard to the pancreatic fistula observed in the present study, it occurred in the early phase of our experience and in the case with a very soft pancreatic texture. Excessive traction to the stay sutures in order to insert the pancreatic stump into the gastric lumen damaged the soft pancreas and this resulted in partial amputation in the pancreatic stump. We estimated that this damaged portion of the pancreas slipped down out of the stomach and evoked leakage. This pancreatic fistula was resolved with conservative therapy and it was classified as grade B according to the ISGPF criteria. Afterward, this excessive traction was prevented by obtaining an adequate length of the posterior gastrotomy (3/4 the length of the pancreatic stump) and sufficient mobilization of the pancreatic stump (at least 4 cm) and pancreatic leakage never happened again after this.

In conclusion, this is a novel PG using two trans-pancreatic sutures with buttresses, and this procedure is performed through an anterior gastrotomy. We believe this technique is simple, secure and it possesses several advantages over the conventional PG: it is very easy to perform, it is less traumatic to the pancreatic stump, it can be performed through a mini-laparotomy due to the good vision and straight sutures and it is secure owing to anchoring the invaginated pancreatic stump to the stomach posterior wall with buttresses. However, to determine its superiority over the conventional procedures, this operative technique should be more comprehensively evaluated in a larger series.

## CONFLICTS OF INTEREST

No potential conflict of interest relevant to this article was reported.

## REFERENCES

1. Chen HW, Lai EC, Su SY, Cai YF, Zhen ZJ, Lau WY. Modified technique of pancreaticojejunal anastomosis with invagination following pancreaticoduodenectomy: a cohort study. *World J Surg* 2008;32:2695-700.
2. Zeng Q, Zhang Q, Han S, Yu Z, Zheng M, Zhou M. Efficacy of somatostatin and its analogues in prevention of post-operative complications after pancreaticoduodenectomy: a meta-analysis of randomized controlled trials. *Pancreas* 2008;36:18-25.
3. Birkmeyer JD, Siewers AE, Finlayson EV, Stukel TA, Lucas FL, Batista I. Hospital volume and surgical mortality in the United States. *N Engl J Med* 2002;346:1128-37.
4. Sledziński Z, Kostro JZ, Zadrozny D, Pirski I, Lukiański M, Głowacki J. Results of pancreaticogastrostomy after pancreaticoduodenectomy in 159 consecutive cases. *Pancreatology* 2008;8:36-41.
5. Payne RF, Pain JA. Duct-to-mucosa pancreaticogastrostomy is a safe anastomosis following pancreaticoduodenectomy. *Br J Surg* 2006;93:73-7.
6. Aranha GV, Aaron JM, Shoup M. Critical analysis of a large series of pancreaticogastrostomy after pancreaticoduodenectomy. *Arch Surg* 2006;141:574-9.
7. Yang YL, Xu XP, Wu GQ, Yue SQ, Dou KF. Prevention of pancreatic leakage after pancreaticoduodenectomy by modified child pancreaticojejunostomy. *Hepatobiliary Pancreat Dis Int* 2008;7:426-9.
8. Lai EC, Lau SH, Lau WY. Measures to prevent pancreatic fistula after pancreatoduodenectomy: a comprehensive review. *Arch Surg* 2009;144:1074-80.
9. Kleespies A, Albertsmeier M, Obeidat F, Seeliger H, Jauch KW, Bruns CJ. The challenge of pancreatic anastomosis. *Langenbecks Arch Surg* 2008;393:459-71.
10. Grobmyer SR, Kooby D, Blumgart LH, Hochwald SN. Novel pancreaticojejunostomy with a low rate of anastomotic failure-related complications. *J Am Coll Surg* 2010;210:54-9.
11. Peng SY, Wang JW, Li JT, Mou YP, Liu YB, Cai XJ. Binding pancreaticojejunostomy-a safe and reliable anastomosis procedure. *HPB (Oxford)* 2004;6:154-60.
12. Ohigashi H, Ishikawa O, Eguchi H, Sasaki Y, Yamada T, Kishi K, et al. A simple and safe anastomosis in pancreaticogastrostomy using mattress sutures. *Am J Surg* 2008;196:130-4.
13. Aranha GV, Hodul P, Golts E, Oh D, Pickleman J, Creech S. A comparison of pancreaticogastrostomy and pancreaticojejunostomy following pancreaticoduodenectomy.

- J Gastrointest Surg 2003;7:672-82.
14. Bassi C, Falconi M, Molinari E, Salvia R, Butturini G, Sartori N, et al. Reconstruction by pancreaticojejunostomy versus pancreaticogastrostomy following pancreatectomy: results of a comparative study. *Ann Surg* 2005;242:767-71.
  15. Murakami Y, Uemura K, Hayashidani Y, Sudo T, Hashimoto Y, Nakagawa N, et al. No mortality after 150 consecutive pancreatoduodenectomies with duct-to-mucosa pancreaticogastrostomy. *J Surg Oncol* 2008;97:205-9.
  16. Rosso E, Bachellier P, Oussoultzoglou E, Scurtu R, Meyer N, Nakano H, et al. Toward zero pancreatic fistula after pancreatoduodenectomy with pancreaticogastrostomy. *Am J Surg* 2006;191:726-32.
  17. Shinchi H, Takao S, Maemura K, Aikou T. A new technique for pancreaticogastrostomy for the soft pancreas: the transfixing suture method. *J Hepatobiliary Pancreat Surg* 2006;13:212-7.
  18. Bassi C, Butturini G, Salvia R, Crippa S, Falconi M, Pederzoli P. Open pancreaticogastrostomy after pancreatoduodenectomy: a pilot study. *J Gastrointest Surg* 2006;10:1072-80.
  19. Tran K, Van Eijck C, Di Carlo V, Hop WC, Zerbi A, Balzano G, et al. Occlusion of the pancreatic duct versus pancreaticojejunostomy: a prospective randomized trial. *Ann Surg* 2002;236:422-8.